Ruptured Basilar Artery Perforator Aneurysm Definitely Diagnosed With Intraoperative Microsurgical Findings: Case Report and Literature Review

Takahiro Kumagawa (kumagawa.takahiro@nihon-u.ac.jp)
Nihon University
Naoki Otani
Nihon University
Yuzo Kakei
Nihon University
Ryo Otaki
Nihon University
Hiroshi Negishi
Nihon University
Takeshi Suma
Nihon University
Atsuo Yoshino
Nihon University

Case Report

Keywords: Subarachnoid hemorrhage, Repeat angiography, Basilar artery perforator aneurysm, Intraoperative findings

Posted Date: March 21st, 2022

DOI: https://doi.org/10.21203/rs.3.rs-1464238/v1

Abstract

Background: Initial three-dimensional computed tomography angiography and cerebral angiography fail to identify any aneurysm in 20% of cases of subarachnoid hemorrhage. Basilar artery (BA) perforator aneurysm is rare and about 30–60% were not identified by initial angiography.

Case presentation: A 71-year-old male was transferred with sudden onset of headache and loss of consciousness. Computed tomography demonstrated subarachnoid hemorrhage, but no ruptured aneurysm was detected. Repeat preoperative cerebral angiography indicated bifurcation aneurysm of the circumflex branch of the superior cerebellar artery perforator but microsurgical observation identified BA perforator aneurysm.

Conclusions: If the location of the BA perforator aneurysm cannot be clearly identified, as in this case, repeat angiography should be considered, and the treatment strategy should be decided based on detailed consideration of the site of the aneurysm.

Background

Subarachnoid hemorrhage (SAH) of unknown etiology is classified into perimesencephalic and non-perimesencephalic types based on the findings of computed tomography (CT). Since non-perimesencephalic SAH is often caused by rupture of a cerebral aneurysm and carries a poor prognosis due to rebleeding, identifying the rupture point is important. No aneurysm is detected in about 20% of cases of SAH by the initial three-dimensional CT angiography (3DCTA) or cerebral angiography [1]. In particular, aneurysms of the perforator of the basilar artery (BA) are difficult to diagnose because of the small size and the shape may undergo changes caused by thrombosis [2]. We experienced a rare case of SAH in which repeat preoperative angiography showed aneurysm of the superior cerebellar artery (SCA) perforator, but the actual aneurysm location was on the BA perforator in the intraoperative findings.

Case Presentation

A 71-year-old male was transferred to our hospital after sudden onset of headache and loss of consciousness. Consciousness level was Glasgow Coma Scale (GCS) 12 (E3V4M5) and blood pressure was 210/120 mmHg on admission. Laboratory evaluations did not show any abnormalities. He had a medical history of hypertension and angina after percutaneous coronary intervention. Head CT demonstrated SAH (Hunt and Kosnik grade IV, World Federation of Neurosurgical Societies grade IV) extending from the premedullary cisterns superiorly into the bilateral sylvian fissures and interhemispheric fissure (Fisher group 3) (Fig. 1a). However, 3DCTA of the cerebral vessels demonstrated no clear evidence of ruptured cerebral aneurysm.

Digital subtraction angiography (DSA) performed on the day after admission found no cerebral aneurysm (Fig. 1b). Repeat conventional angiography showed no obvious aneurysm on day 5, but multi-planar reconstruction (MPR) angiography showed a tiny aneurysm between the BA and the left SCA (Fig. 1c). However, since the origin of the aneurysm was not clear, no treatment strategy could be established. MPR angiography on day 14 showed an aneurysm with a neck on the SCA, which was slightly different from the findings on day 5 (Fig. 1d). Sedative and analgesic care was performed for 14 days after the onset. The patient's level of consciousness improved to GCS14 (E4V4M6) on day 18. Selective angiography of the distal side of BA was performed using a microcatheter to examine the origin of the aneurysm in more detail on day 21. These findings suggested a diagnosis of bifurcation aneurysm between the SCA and the circumflex branch of the SCA perforator (Fig. 1e). The aneurysm of the SCA perforator was judged as difficult for endovascular intervention, so neurosurgical treatment was planned.

A subtemporal transtentorial approach was planned based on the height relationship between the aneurysm and the posterior clinoid process (Fig. 1f). Cerebral aneurysm clipping was performed on day 42. The intraoperative findings showed that the aneurysm neck originated from the BA perforator. The location of the aneurysm was different from that of bifurcation aneurysm of the circumflex branch of the SCA perforator detected by preoperative cerebral angiography (Fig. 2a, b). However, clipping of the neck of the aneurysm was not possible due to the location on the BA perforator, and the need to preserve this vessel. Consequently, the rupture point was clipped (Fig. 2c, d). The postoperative course was uneventful, but follow-up CT demonstrated hydrocephalus. The patient underwent ventriculoperitoneal shunting on day 63. The patient was transferred to another hospital to continue rehabilitation from the SAH on day 85 with modified Rankin Scale (mRS) grade 2. His final consciousness level was GCS 14 (E4V4M6). Three months after rehabilitation, his mRS had improved to grade 0 with no neurological disability.

Discussion

BA perforator aneurysm is rare and the pathophysiology is unknown. BA perforator aneurysms tend to be small with fusiform type, and the angiographical findings change over time [2]. The size of BA perforator aneurysm is often 3 mm or less in diameter, and the maximum may be 7 mm [3]. Most BA perforator aneurysms are located on the BA perforator and not on the BA trunk. The first case was reported in 1996 [4], and numbers have increased over the last few years due to the evolution of diagnostic technologies such as 3DCTA, magnetic resonance angiography, and angiography. BA perforator aneurysm may have been treated as SAH of unknown etiology before 1996. Our review identified 19 papers and 54 cases, and analyzed 55 cases including this case. Initial angiography failed to identify about 30–60% of BA perforator aneurysm

[3]. Our analysis found that the initial angiography failed in 34 cases (62%) [2, 4–15] (Table 1). Therefore, repeat angiography is recommended within 7 days [14]. In our case, repeat angiography was performed on day 5, and MPR angiography demonstrated the aneurysm. Since the origin of the aneurysm was unclear and could change, treatment was not performed at this point and angiography was repeated in this case. However, the aneurysm was identified within 7 days in only 12 of the 26 cases (46%), excluding 8 of the 34 cases in which the time to identify the aneurysm was unknown. Aneurysms were identified within 1 month in 18 cases (69%). No significant difference in outcome was observed between the groups in which the aneurysm was identified and not identified within 1 month. Therefore, angiography must be repeated to make a diagnosis if the aneurysm cannot be identified at an early stage.

Table 1
Clinical characteristics of 34 patients with ruptured BA perforator aneurysms diagnosed as unverified aneurysm on initial angiography

Case No.	Author/year	Age (yrs)	Location of aneurysm origin on BA[a]	Time until aneurysm detection
1	Ghogawala et al./1996 [4]	56	Distal	9 days
2	Hamel et al./2005 [5]	51	Middle	N/A
3	Sanchez-Mejia and Lawton/2007 [6]	27	Distal	2 months
4		68	Proximal	2 months
5	Mathieson et al./2010 [7]	51	Middle	N/A
6	Nyberg et al./2013 [8]	45	Middle	2 months
7		65	Middle	9 weeks
8		62	Distal	2 weeks
9		55	Distal	7 days
10	Apok et al./2013 [9]	65	Distal	5 days
11	Chavent et al./2014 [2]	55	Distal	8 days
12		39	Distal	8 days
13		56	Distal	8 days
14	Chalouhi et al./2014 [10]	N/A	Middle	3 days
15	Sivakanthan et al./2015 [11]	45	Distal	N/A
16		N/A	Distal	N/A
17		N/A	Distal	N/A
18	Forbrig et al./2016 [12]	72	Distal	18 days
19		59	Distal	13 days
20		65	Middle	8 days
21		53	Distal	47 days
22	Satti et al./2017 [13]	52	Middle	8 days
23	Buell et al./2018 [14]	N/A	Middle	6 days
24		N/A	Middle	5 days
25		N/A	Distal	7 days
26		N/A	Distal	5 days
27		N/A	Middle	5 days
28		59	Distal	5 days
29		69	Distal	2 months
30		65	N/A	N/A
31		57	Distal	N/A
32		62	N/A	N/A
33	Enomoto et al./2020 [15]	60	Distal	39 days
34	Present case	71	Distal	5 days

[a]Location of aneurysm origin on BA defined as proximal from vertebral artery union to anterior inferior cerebellar artery, middle from anterior inferior cerebellar artery to SCA, and distal from SCA to BA top.

N/A, not available

No optimal treatment strategy has been accepted for BA perforator aneurysms. Conservative treatment was given in 23 of the 55 cases (42%). Surgical treatment and endovascular treatment (EVT) prevented rebleeding, but conservative treatment resulted in rebleeding in 4 cases (17%). EVT was performed in 2 of the 4 cases after rebleeding. The 2 cases with EVT had good outcomes, but 2 cases without EVT had poor outcomes (mRS 5 and 6).

The shape of BA perforator aneurysm changes over time, so the pathology is considered to be pseudoaneurysm. Aneurysms that are imaged in the late arterial phase of angiography are said to have a high possibility of thrombosis, so such findings are considered to indicate conservative treatment [15]. Our analysis found that 23 cases (85%) with conservative treatment had good outcomes (mRS 0 or 1), so conservative treatment should be one of the treatment policy options based on the patient's condition and angiography findings.

Surgical treatment was performed in 10 cases (18%) and EVT in 22 cases (40%) [3–14, 16–20] (Table 2). The surgical treatment approach depended on the location of the aneurysm. The frontozygomatic approach was used for distal BA aneurysm, and the retrosigmoid approach or subtemporal approach was selected for middle BA aneurysm. In our present case, the location of the aneurysm was judged to lie between the distal and middle BA based on the preoperative imaging findings, and the subtemporal transtentorial approach was selected. EVT used coil, stent, Onyx, and flow diverter techniques. The perforator was preserved in 33% of cases of surgical treatment and 25% of EVT.

Table 2
Previous and the present cases of surgical treatment and EVT for BA perforator aneurysms

Case No.	Author/year	Age (yrs)	Location of aneurysm origin on BA[a]	Detection on initial angiogram	Time until aneurysm detection	Treatment	Rebleeding	Perforator preserved	Ischemic complication	Outcome
1	Ghogawala et al./1996 [4]	56	Distal	N	9 days	Surgery	N	Y	N	GOS 5
2	Hamel et al./2005 [5]	51	Middle	N	N/A	Surgery	N	N	N	N/A
3	Sanchez-Mejia and Lawton/2007 [6]	27	Distal	N	2 months	Surgery	Y	N	N	mRS 0
4		68	proximal	N	2 months	Surgery	Y	N	N	N/A
5		2	Middle	N/A	N/A	Surgery	N	N/A	N	mRS 0
6	Mathieson et al./2010 [7]	51	Middle	N	N/A	Surgery	N	N	N	mRS 0
7	Chen et al./2012 [16]	66	Middle	Y	N/A	EVT	N	N	N	GOS 4
8	Nyberg et al./2013 [8]	45	Middle	N	2 months	EVT	N	Y	N	GOS 5
9		65	Middle	N	9 weeks	EVT	N	N	N	GOS 5
10	Ding et al./2013 [17]	58	Middle	Y	N/A	EVT	N	N	Y	GOS 3
11		62	Distal	N	2 weeks	EVT	N	N	Y	GOS 3
12	Gross et al./2013 [18]	52	Distal	Y	N/A	Surgery	N	N	N	mRS 1
13	Apok et al./2013 [9]	65	Distal	N	5 days	Surgery	N	N	Y	mRS 4
14	Chavent et al./2014 [2]	NA	Middle	N	3 days	EVT	N	Y	N	mRS 0
15	Sivakanthan et al./2015 [11]	45	Distal	N	N/A	Surgery	N	Y	N	mRS 1
16	Peschillo et al./2016 [19]	NA	Distal	Y	N/A	EVT	N	N	Y	mRS 2
17		NA	Distal	N	N/A	EVT	N	Y	N	mRS 0
18		N/A	Distal	N	N/A	EVT	N	N/A	N	mRS 2
19	Forbrig et al./2016 [12]	72	Distal	N	18 days	EVT	N	N	N	mRS 2
20	Satti et al./2017 [13]	52	Middle	N	8 days	EVT	N	N	Y	mRS 0
21	Buell et al./2018 [14]	NA	Middle	N	6 days	EVT	N	Y	N	mRS 1
22		NA	Middle	N	5 days	EVT	N	Y	N	mRS 1
23		NA	Distal	Y	N/A	EVT	Y	N/A	N	mRS 6

[a]Location of aneurysm origin on BA defined as proximal from vertebral artery union to anterior inferior cerebellar artery, middle from anterior inferior cerebellar artery to SCA, and distal from SCA to BA top.

GOS, Glasgow Outcome Scale; N, no; N/A, not available; Y, yes.

Case No.	Author/year	Age (yrs)	Location of aneurysm origin on BA[a]	Detection on initial angiogram	Time until aneurysm detection	Treatment	Rebleeding	Perforator preserved	Ischemic complication	Outcome
24	Chau et al./2018 [20]	53	Distal	Y	N/A	EVT	N	N	Y	mRS 0
25		59	Distal	N	5 days	EVT	N	Y	N	mRS 0
26	Bhogal et al./2019 [3]	55	Distal	Y	N/A	EVT	N	N	N	mRS 1
27		65	N/A	N	N/A	EVT	N	N	N	mRS 2
28		66	Distal	Y	N/A	EVT	N	N	N	mRS 3
29		41	Middle	Y	N/A	EVT	N	N	Y	mRS 0
30		52	Distal	Y	N/A	EVT	N	N	N	mRS 0
31		39	Middle	Y	N/A	EVT	N	N	N	mRS 2
32	Present case	71	Distal	N	5 days	Surgery	N	Y	N	mRS 0

[a]Location of aneurysm origin on BA defined as proximal from vertebral artery union to anterior inferior cerebellar artery, middle from anterior inferior cerebellar artery to SCA, and distal from SCA to BA top.

GOS, Glasgow Outcome Scale; N, no; N/A, not available; Y, yes.

Ischemic complication due to perforator disruption occurred in 1 case (10%) after surgical treatment and 6 cases (27%) after EVT. Since BA perforator aneurysm has a broad neck and fusiform type, surgical clipping is difficult and carries the risk of perforator obstruction. Even in the present case, neck clipping was difficult so only dome clipping was performed at the rupture point. The perforator was preserved and no ischemic complication was observed after surgery. Ischemic complication occurred after EVT using any of the coil, stent, flow diverter, and Onyx, so the specific device was not considered as contributory. Good outcomes of mRS 0 and 1 were obtained in 6 cases (66%) of surgical treatment and 13 cases (60%) of EVT.

In our present case, preoperative angiography initially indicated SCA-SCA perforator aneurysm. The SCA was identified by microsurgical observation, but no aneurysm was found. Consequently, the aneurysm was considered to be located on a more proximal middle BA perforator than the SCA. The aneurysm was thought to have adhered to the SCA, so appeared as an SCA-SCA perforator on angiography. As mentioned above, BA perforator aneurysms are small and not easy to diagnose even by angiography. In our case, the definitive diagnosis was obtained based on the microsurgical observation, but the true nature of the aneurysm was unknown when EVT was selected. Therefore, such a difference between the actual location of the aneurysm and the angiographical findings may have occurred among the previously reported cases of EVT, implying that EVT using the flow diverter or Onyx may have impaired normal reflux and increased the risk of ischemic complication. Our analysis found no difference in outcomes between surgical treatment and EVT, so we cannot conclude which treatment is better. If the aneurysm can be clearly identified by angiography, EVT presents no problem, but if the origin of the aneurysm cannot be clearly identified or if change over time occurs, surgical treatment should also be considered.

Conclusion

The present case of BA perforator aneurysm was identified by repeated DSA, but was only definitely diagnosed under intraoperative microsurgical observation. The accuracy of angiography has definitely improved, but accurate diagnosis for small, shape-changing aneurysms such as BA perforator aneurysm is difficult to establish. If the location of the aneurysm cannot be clearly identified, repeat angiography should be considered and the treatment strategy should be decided based on detailed consideration of the site of the aneurysm and the patient's condition.

Abbreviations

BA: Basilar artery; CT: Computed tomography; 3DCTA: Three-dimensional computed tomography angiography; DSA: Digital subtraction angiography; EVT: Endovascular treatment; GCS: Glasgow Coma Scale; MPR: Multi-planar reconstruction; mRS: Modified Rankin Scale; SAH: Subarachnoid hemorrhage; SCA: Superior cerebellar artery

Declarations

Ethics approval and consent to participate: Not applicable

Consent for publication: Written informed consent was obtained from the patient's guardian for publication of this case report and any accompanying images. A copy of the written consent is available for review by the Editor of this journal.

Availability of data and materials: All data related to this case report are contained within the manuscript.

Competing interests: The authors declare that they have no competing interests.

Funding: None of the authors have received any financial assistance for this manuscript.

Authors' contributions: TK and NO contributed to the manuscript concept and drafted the manuscript. AY and TS revised the manuscript and contributed the manuscript concept. YK, RO, and HN have contributed to the acquisition and interpretation of clinical information. All authors have read and approved the final version of the manuscript.

Acknowledgements: Not applicable

References

1. Maslehaty H, Barth H, Petridis AK, Doukas A, Maximilian Mehdorn H. Special features of subarachnoid hemorrhage of unknown origin: a review of a series of 179 cases. Neurol Res. 2012;34:91-7.
2. Chavent A, Lefevre PH, Thouant P, Cao C, Kazemi A, Mourier K, et al. Spontaneous resolution of perforator aneurysms of the posterior circulation. J Neurosurg. 2014;121:1107-11.
3. Bhogal P, AlMatter M, Hellstern V, Pérez MA, Lehmberg J, Ganslandt O, et al. Basilar artery perforator aneurysms: Report of 9 cases and review of the literature. J Clin Neurosci. 2019;63:122-9.
4. Ghogawala Z, Shumacher JM, Ogilvy CS. Distal basilar perforator artery aneurysm: case report. Neurosurgery. 1996;39:393-6.
5. Hamel W, Grzyska U, Westphal M, Kehler U. Surgical treatment of a basilar perforator aneurysm not accessible to endovascular treatment. Acta Neurochir (Wien). 2005;147:1283-6.
6. Sanchez-Mejia RO, Lawton MT. Distal aneurysms of basilar perforating and circumferential arteries. Report of three cases. J Neurosurg. 2007;107:654-9.
7. Mathieson CS, Barlow P, Jenkins S, Hanzely Z. An unusual case of spontaneous subarachnoid haemorrhage–a ruptured aneurysm of a basilar perforator artery. Br J Neurosurg. 2010;24:291-3.
8. Nyberg EM, Chaudry MI, Turk AS, Spiotta AM, Fiorella D, Turner RD. Report of two cases of a rare cause of subarachnoid hemorrhage including unusual presentation and an emerging and effective treatment option. J Neurointerv Surg. 2013;5:e30.
9. Apok V, Tarnaris A, Brydon HL. An unusual aneurysm of a basilar perforating artery presenting with a subarachnoid haemorrhage. Br J Neurosurg. 2013;27):105-7.
10. Chalouhi N, Jabbour P, Starke RM, Zanaty M, Tjoumakaris S, Rosenwasser RH, et al. Treatment of a basilar trunk perforator aneurysm with the pipeline embolization device: case report. Neurosurgery. 2014;74:E697-701; discussion 701.
11. Sivakanthan S, Carlson AP, van Loveren H, Agazzi S. Surgical clipping of a basilar perforator artery aneurysm: a case of avoiding perforator sacrifice. J Neurol Surg A Cent Eur Neurosurg. 2015;76:79-82.
12. Forbrig R, Eckert B, Ertl L, Patzig M, Brem C, Vollmar C, et al. Ruptured basilar artery perforator aneurysms–treatment regimen and long-term follow-up in eight cases. Neuroradiology. 2016;58:285-91.
13. Satti SR, Vance AZ, Fowler D, Farmah AV, Sivapatham T. Basilar artery perforator aneurysms (BAPAs): review of the literature and classification. J Neurointerv Surg. 2017;9:669-73.
14. Buell TJ, Ding D, Raper DMS, Chen CJ, Hixson HR, Crowley RW, et al. Posterior circulation perforator aneurysms: a proposed management algorithm. J Neurointerv Surg. 2018;10:55-9.
15. Enomoto N, Shinno K, Tamura T, Shikata E, Shono K, Takase K. Ruptured basilar artery perforator aneurysm: a case report and review of the literature. NMC Case Rep J. 2020;7:93-100.
16. Chen L, Chen E, Chotai S, Tian X. An endovascular approach to ruptured aneurysms of the circumferential branch of the basilar artery. J Clin Neurosci. 2012;19:527-31.
17. Ding D, Starke RM, Jensen ME, Evans AJ, Kassell NF, Liu KC. Perforator aneurysms of the posterior circulation: case series and review of the literature. J Neurointerv Surg. 2013;5:546-51.
18. Gross BA, Puri AS, Du R. Basilar trunk perforator artery aneurysms. Case report and literature review. Neurosurg Rev. 2013;36:163-8; discussion 168.

19. Peschillo S, Caporlingua A, Cannizzaro D, Resta M, Burdi N, Valvassori L, et al. Flow diverter stent treatment for ruptured basilar trunk perforator aneurysms. J Neurointerv Surg. 2016;8:190-6.
20. Chau Y, Sachet M, Sédat J. Should we treat aneurysms in perforator arteries from the basilar trunk? Review of 49 cases published in the literature and presentation of three personal cases. Interv Neuroradiol. 2018;24:22-8.

Figures

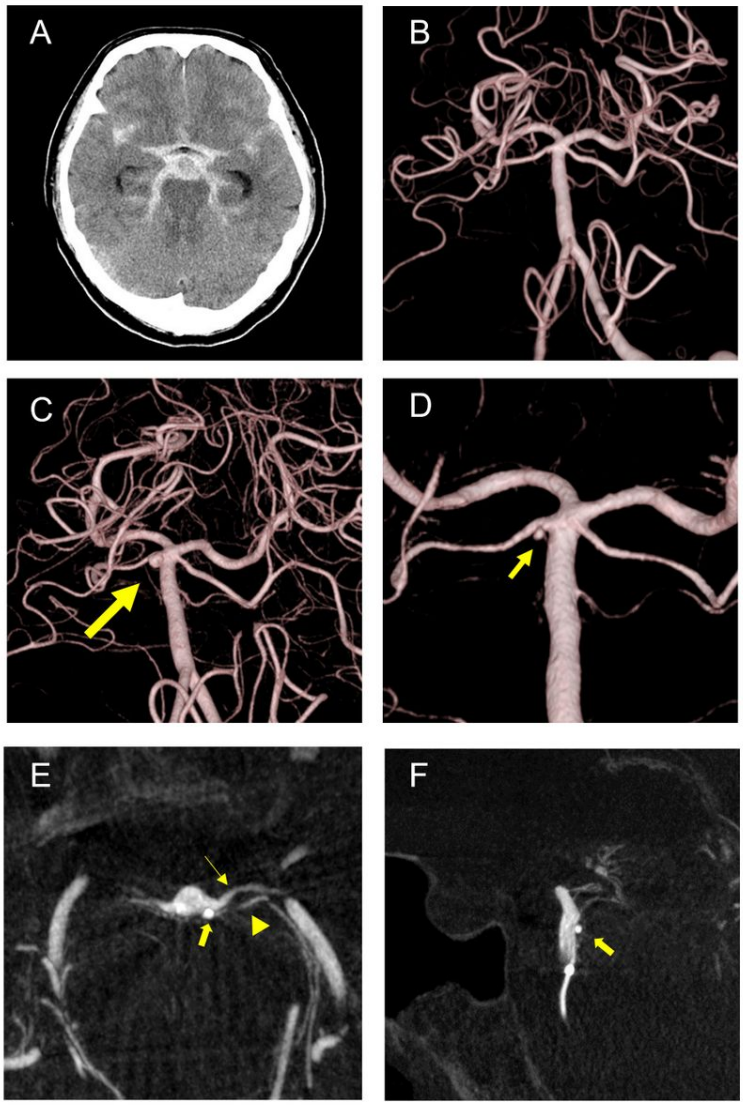

Figure 1

a: Head CT scan demonstrating diffuse SAH in the perimesencephalic cistern (Fisher group 3). **b**: DSA showing no cerebral aneurysm on day 1. **c**: MPR angiogram on day 5 showing a tiny aneurysm between the BA and the left SCA. **d**: MPR angiogram on day 14 showing an aneurysm with a neck on the SCA, which was slightly different from the findings on day 5. **e**: Selective angiogram (maximum-intensity projection, axial view) using a microcatheter on day 21 revealing the aneurysm between the SCA and the circumflex branch of the SCA perforator. **f**: The aneurysm was located below the posterior clinoid process.

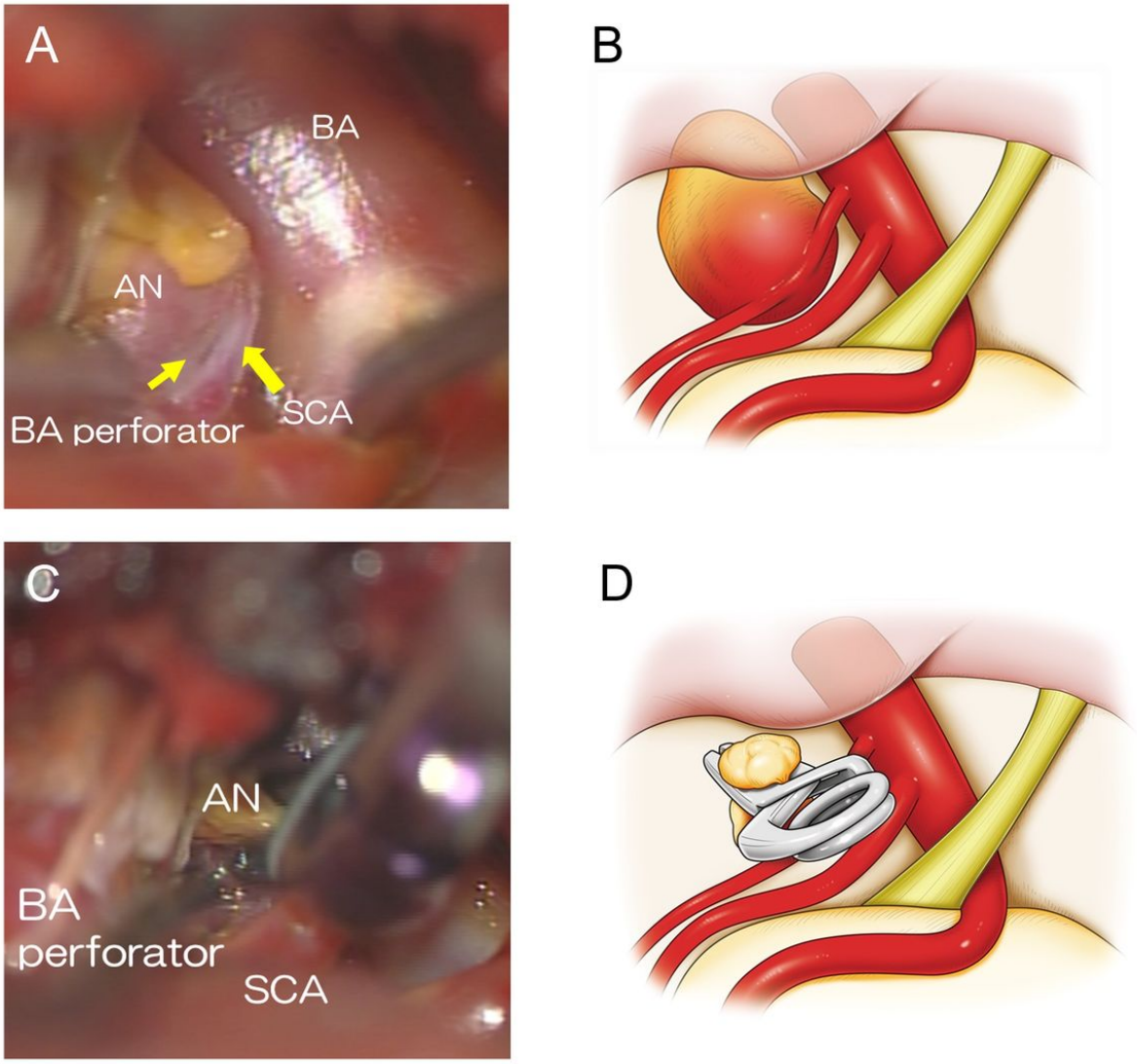

Figure 2

a, b: Pre-clipping surgical views showing that the neck of the aneurysm was located on the BA perforator. **c, d**: Post-clipping surgical views showing that only the rupture point was clipped.