Clinical Significance of Extra-Thyroid99mTc-Pertechnetate Uptake Before Initial Radioiodine Therapy For Differentiated Thyroid Carcinoma

bin long
Zhejiang University School of Medicine Sir Run Run Shaw Hospital
lifang yao
Zhejiang University School of Medicine Sir Run Run Shaw Hospital
shoucong chen
Zhejiang University School of Medicine Sir Run Run Shaw Hospital
jin shui
Zhejiang University School of Medicine Sir Run Run Shaw Hospital
xuemei ye
Zhejiang University School of Medicine Sir Run Run Shaw Hospital
heqing yi
Zhejiang University School of Medicine Sir Run Run Shaw Hospital
cen lou (cenlou2020@126.com)
Zhejiang University School of Medicine Sir Run Run Shaw Hospital

---

Research

Keywords: 99mTc-pertechnetate, radioactive iodine, differentiated thyroid carcinoma, initial radioiodine therapy, stimulated thyroglobulin (sTg) level

Posted Date: January 18th, 2021

DOI: https://doi.org/10.21203/rs.3.rs-146985/v1

Abstract

Background: Over the last few decades, extra-thyroid 99mTc-pertechnetate uptake has rarely been reported. The clinical characteristics of extra-thyroid 99mTc-pertechnetate uptake were retrospectively analysed to explore the effect of the phenomenon on RAI therapy for DTC and its clinical significance.

Methods: In this study, we retrospectively analysed 4930 RAI-treated DTC patients who had undergone ^{99m}Tc-pertechnetate scanning. Thirty-eight cases with extra-thyroid ^{99m}Tc-pertechnetate uptake were selected. The clinical features, location, location count and extra-thyroid ^{99m}Tc-pertechnetate uptake distribution were analysed, combined with the uptake rate, stimulated thyroglobulin (sTg) level, post-therapy whole-body scan and curative effect.

Results: The results showed that sixty-five extra-thyroid ^{99m}Tc-pertechnetate foci were detected in 38 patients. The proportions of patients with abnormal uptake in the lymph nodes, lungs and bones were 68.4%, 10.5% and 10.5%, respectively. The corresponding uptake rates were 0.2%, 0.2% and 0.8%. The uptake rate was significantly lower in the lymph nodes than in the bones ($Z = -2.722$, $p = 0.019$). The uptake rate and sTg were positively correlated ($r = 0.36$, $p = 0.027$). ^{131}I uptake was found in 36 cases at the technetium uptake site, and the number of iodine uptake foci was significantly higher than that of ^{99m}Tc-pertechnetate uptake foci. The sTg value and pathological staging significantly differed between the excellent and nonexcellent response groups ($Z = 2.947$, $p = 0.003$ and $Z = 2.348$, $p = 0.019$, respectively).

Conclude: Extra-thyroid ^{99m}Tc-pertechnetate uptake mostly indicated metastases with specific clinical features, which may have prognostic value for the judgment of iodine uptake function and the RAI therapy plan.

1. Introduction

Differentiated thyroid carcinoma (DTC) is the most common malignant tumour of the head and neck that is formed from thyroid follicular cells, and mainly includes papillary carcinoma, follicular carcinoma, Hürthle cell carcinoma and poorly differentiated carcinoma, accounting for more than 90% of thyroid cancers in total. According to the 2015 American Thyroid Association (ATA) guidelines, radioactive iodine (RAI) therapy is recommended for all high-risk and selective intermediate-risk patients with DTC [7]. ^{99m}Tc-pertechnetate has long been used in clinical practice as an imaging agent for evaluating thyroid diseases, and is cheap, widely available, has ideal imaging characteristics and favourable dosimetry. ^{99m}Tc-pertechnetatescanning is commonly used todetect any thyroid remnants following thyroidectomy, and may provide beneficial data on the extent of remnant tissue without the need for ^{131}I or ^{123}I.The ^{99m}Tc-pertechnetate uptake of the thyroid bed can be used as a marker of thyroid remnants, and negative uptake does not indicate the absence of thyroid remnants, suggesting a small volume. Over the last few decades,extra-thyroid ^{99m}Tc-pertechnetate uptake has rarely been reported [10, 11, 3]. Furthermore, almost all available literature includes case reports [14, 5, 9, 8, 2], most of which confirm DTC metastases.

In the present study, the clinical characteristics of extra-thyroid ^{99m}Tc-pertechnetate uptake were retrospectively analysed to explore the effect of the phenomenon on RAI therapy for DTC and its clinical significance.

2. Materials And Methods

2.1Study population

In this retrospective study, we screened 4930 patients with DTC who underwent total/near-total thyroidectomy with central and/or lateral cervical lymph node dissection, and who received the initial RAI therapy following ^{99m}Tc-pertechnetate scanning between January 2007 and January 2017 at our hospital. Out of these patients, 43 with extra-thyroid ^{99m}Tc-pertechnetate uptake were selected, four of whom were reoperated on due to cervical lymph node metastases indicated by ultrasound and fine-needle aspiration (FNA) before RAI therapy, and one of whom did not receive RAI therapy due to primary liver cancer (confirmed by ultrasound). Thirty-eight patients who had received RAI therapy were included in this study. All patients met the following criteria: (1) Patients had undergone total/near-total thyroidectomy and had a postoperative pathology test that indicated DTC; (2) patients whose thyrotropin (TSH), stimulated thyroglobulin (sTg) and Tg autoantibodies (TgAbs)were measured after being on a low-iodine diet and thyroid hormone withdrawal (THW) for 3–4 weeks, and whose thyroid function was re-measured after 1 week if the TSH level was lower than 30 mIU/l; (3) patients who had ^{99m}Tc-pertechnetatescanning with additional single-photon emission computed tomography/computed tomography (SPECT/CT) following THW, which revealed at least one region of extra-thyroid ^{99m}Tc-pertechnetate uptake; and (4) patients with no history of a second primary tumour.

2.2 Imaging protocol and image analyses

Thirty minutes after intravenous administration of approximately 185 MBq of ^{99m}Tc-pertechnetate, anterior images of the neck were acquired using a gamma-camera equipped with low-energy and high-resolution collimators (Discovery NM/CT670, GE Healthcare, USA), with a 20% window centred around the 140 KeV peak and a 256×256 computer matrix. The radioactivity counts of full and empty needles were performed before and after injection, and the ^{99m}Tc-pertechnetate uptake rate was determined using the region-of-interest technique as previously described [6]. Uptake rate (%) = (counts over remnant thyroid tissue or extra-thyroid focus – background counts)/Counts of injected activity×100%[1].^{99m}Tc-pertechnetate whole-body scanning (^{99m}Tc-WBS) was performedafter obtaining anterior images with a scanning speed of 15 cm/min, and additional SPECT/CT was performed to evaluate extra-thyroid ^{99m}Tc-pertechnetate uptake. The post-treatment whole-body scan (Rx-WBS) and SPECT/CT were conducted 5 days after the administration of ^{131}I with the same technique using a high-energy collimator.

The results of ^{99m}Tc-WBS combined with SPECT/CT were analysed separately by two experienced nuclear medicine physicians who were unaware of the Rx-WBS/SPECT/CT results. All images were

evaluated qualitatively as negative or positive.A clearly visible focus of ^{99m}Tc-pertechnetate uptake above the background level within the neck and upper mediastinum was defined as positive. A positive focus limited to the thyroid bed was defined as remnant thyroid tissue, while a positive focus outside the thyroid bed was defined as extra-thyroid ^{99m}Tc-pertechnetate uptake. Unidentifiable thyroid residue or suspected metastatic lesions with anatomical findings from CT such as upper and lower thyroid ^{99m}Tc-pertechnetate uptake were excluded in this study. The performance of ^{99m}Tc-WBS/SPECT/CT in detecting the lesions was compared with that of Rx-WBS/SPECT/CT, which is considered to be the gold standard, excluding physiological uptake.The increased uptake and uniform distribution of ^{99m}Tc-pertechnetate in the lungs was defined as diffuse uptake, and localised distribution and accumulation of ^{99m}Tc-pertechnetate in the lungs was referred to as nodular uptake.

2.3 Follow-up and response assessment

A regular follow-up was performed after the initial RAI therapy and the follow-up duration was 12–108 months. The response was classified as excellent response (ER), biochemical incomplete response (BIR), structural incomplete response (SIR) and indeterminate response (IDR), according to the serological examination and imaging technique described in the 2015 ATA guidelines [7]. The latter three are collectively referred to as non-excellent response (NER). ER was defined as negative imaging along with either suppressed Tg up to 0.2 ng/ml or sTg up to 1 ng/ml with the absence of TgAb.

2.4 Statistical analysis

All statistical analyses were conducted using SPSS software (version 26.0, Inc., Chicago, IL). Descriptive statistics were shown as mean ± standard deviation values for continuous variables, and as the number of cases and percentages for nominal variables. The ^{99m}Tc-pertechnetate uptake rates of the lymph nodes, lungs and bones were evaluated using the Kruskal-Wallis test. Spearman's rho was used to analyse the correlation between ^{99m}Tc-pertechnetate uptake and parameters such as sex, age, sTg, TgAbs, TSH level, pathological type and TNM stage.The correlation parameters between the ER and NER groups were compared using the Mann-Whitney U test. A p value of less than 0.05 was considered to indicate statistical significance.

3. Results

3.1 Patients' demographic and baseline characteristics

Patients' demographic, clinical and pathological data are summarised in Table 1.There were 15 (39.5%) men and 23 (60.5%) women, with the mean age being 45.6 ± 12.3 years (range: 20–67 years). The distribution of patients (based on the eighth edition of the TNM staging system) was as follows: stage I: 18 (47.4%), stage II: 13 (34.2%), stage III: 1 (2.6%) and stage IV: 6 (15.8%). The TSH level in eight patients was lower than 30 mIU/l after 4 weeks of THW for the initial RAI therapy.Out of these eight patients, ^{99m}Tc-pertechnetate scans of the neck showed that there was no accumulation of radioactivity in the

thyroid bed in 4 patients. The other 4 patients had radioactive uptake in the thyroid bed with uptake rates of 0.1–0.3%, which were lower than those of the extra-thyroid lesions, suggesting that there were only a small number of thyroid residuals. Among these patients, one patient's TSH level at the second RAI therapy was higher than that at the time of the previous treatment; however, it still did not reach the treatment standard. In another patient, the TSH level only increased to above 30 mIU/l at the fourth RAI therapy. Among the 38 DTC patients, 35 (92%) had an sTg level higher than 10 ng/mlduring the first ^{131}I treatment.

Table 1
Demographics, clinical, and pathological data for 38 patients

Characteristic	No. of patients	Percentage of patient
Sex		
Female	23	60.5
Male	15	39.5
Age		
< 55y	29	76.3
≥ 55y	9	23.7
Histology		
Papillary	26	68.4
Follicular	8	21.1
Mixed papillary-follicular*	3	7.9
Poorly differentiated	1	2.6
TNM		
T		
T1a	6	15.8
T1b	8	21.1
T2	3	7.9
T3	8	21.1
T4a	3	7.9
Tx	10	26.2
N		
N0	7	18.4
N1a	12	31.6
N1b	13	34.2
Nx	6	15.8
M		
M0	23	60.5

* refer to papillary carcinoma and follicular carcinoma in the different lobe of the thyroid

Characteristic	No. of patients	Percentage of patient
M1	15	39.5
AJCC stage		
I	18	47.4
II	13	34.2
III	1	2.6
IVA	0	0
IVB	6	15.8
TSH (mIU/l)		
30	8	21.1
≥30	30	78.9
sTg(ng/mL)		
1	1	2.6
1–10	2	5.3
10–100	13	34.2
≥100	22	57.9
TgAb(IU/mL)		
negative(115)	37	97.4
positive (≥ 115)	1	2.6
* refer to papillary carcinoma and follicular carcinoma in the different lobe of the thyroid		

3.2 Distribution of extra-thyroid ^{99m}Tc-pertechnetate uptake

A total of 65 extra-thyroid ^{99m}Tc-pertechnetate uptake foci were detected in 38 patients, of which 50.77% (33/65), 38.46% (25/65) and 7.69% (5/65) were in the lymph nodes, lungs and bones, respectively. The distribution characteristics are summarised in Table 2. In the per-patient analysis, 34 showed abnormal ^{99m}Tc-pertechnetate uptake in the lymph nodes (26; 68.4%), lungs (4; 10.5%) and bones (4; 10.5%), and the corresponding uptake rates were 0.2% (0.1–0.35%), 0.2% (0.1–0.68%), and 0.8% (0.45–1.6%). Data on the relationship between the three subgroups showed that the uptake rate in the lymph node subgroup was significantly lower than that in the bone subgroup ($Z = 2.722$, $p = 0.019$), as shown in Table 3 and Fig. 1. Seven patients showed extra-thyroid ^{99m}Tc-pertechnetate uptake in two or more sites, five of whom showed simultaneous uptake in two or more lymph nodes, and each of the remaining two patients showed uptake in the lymph nodes and lung tissue (Figs. 2–4) and the lymph nodes and bone tissue.

One patient with superior vena cava ^{99m}Tc-pertechnetate uptake underwent chest MRI scanning before ^{131}I therapy and this showed that the superior vena cava was significantly enlarged, with abnormal mass in the blood vessels, high signal on T2-weighted images, enhanced scan lesions significantly enhanced and ^{131}I uptake by Rx-WBS/SPECT/CT in this area, which was considered to be tumour thrombus. Another patient showed ^{99m}Tc-pertechnetate uptake in the supraclavicular vessel, but no abnormality was found on ultrasound, MRI or Rx-WBS/SPECT/CT. The distribution and uptake rates are shown in Table 3. Correlation analyses between the extra-thyroid ^{99m}Tc-pertechnetate uptake rate and sex, age, sTg, TgAb and TSH levels, pathological type and TNM stage showed a definite positive correlation between the sTg level and the uptake rate in Fig. 5 ($r = 0.36$, $p = 0.027$).

Table 2
Distribution of 65 extra-thyroid ^{99m}Tc-pertechnetate uptake lesions in 38 DTC patients

Organs	No. of lesions	Percentage of lesions(%)
Lymph node(LN)		
mediastinum	18	27.69
lateral cervical	9	13.85
clavicular region	5	7.69
axilla	1	1.54
Lung		
nodular	24	36.92
diffuse	1	1.54
Bone		
sternum	2	3.08
rib	1	1.54
femur	1	1.54
humerus	1	1.54
Blood vessel	1	1.54
Superior vena cava tumor thrombus	1	1.54

Table 3
Distribution and ^{99m}Tc-pertechnetate uptake rate of extra-thyroid in 38 patients

Organs	No. of patients (Percentage, %)	^{99m}Tc-pertechnetate uptake rate (%)	z	p
Lymph node (LN)	26(68.4)	0.20(0.10–0.35)	-2.722	0.019
Lung	4(10.5)	0.20(0.10–0.68)		
Bone	4(10.5)	0.80(0.45–1.60)		
LN + Lung	1(2.6)	0.20		
LN + Bone	1(2.6)	0.35		
Superior vena cava tumor thrombus	1(2.6)	2.60		
Blood vessels	1(2.6)	0.15		

3.3 ^{99m}Tc-pertechnetate uptake and its relationship with ^{131}I uptake

^{99m}Tc-WBS/SPECT/CT did not show ^{99m}Tc-pertechnetate uptake in the thyroid bed in 9 patients before the first RAI therapy, but RxWBS showed thyroid bed iodine uptake in 8 cases (indicating a small amount of thyroid residue), and only one case showed no obvious radioactive uptake in the thyroid bed in both examinations. The sensitivity and specificity of the ^{99m}Tc-pertechnetate scan in evaluating thyroid residue were 82.22% and 100%, respectively. One patient showing ^{99m}Tc-pertechnetate uptake in the axillary lymph node, and another patient showing uptake in blood vessels, both showed no obvious ^{131}I uptake on RxWBS/SPECT/CT imaging. The other 36 patients showed ^{131}I uptake at the extra-thyroid ^{99m}Tc-pertechnetate uptake foci, with the number of ^{131}I uptake foci being significantly more than the foci showing ^{99m}Tc-pertechnetate uptake. 37.5% (39/104 foci) showed metastases with ^{131}I uptake but without ^{99m}Tc-pertechnetate uptake (diffuse ^{131}I uptake in the lungs was defined as a lesion), and there were no instances of ^{99m}Tc-pertechnetate uptake in the liver, kidneys or brainindicating ^{131}I-avid metastases. Excluding physiological uptake, the presence of extra-thyroid^{131}I uptake foci was used as the criterion for judging the presence of metastases, and 94.7% (36/38) of extra-thyroid ^{99m}Tc-pertechnetate uptake foci were DTC metastases.^{99m}Tc-pertechnetate scans were performed on all patients during the second ^{131}I treatment, and only one patient showed a small amount of ^{99m}Tc-pertechnetate uptake in the extra-thyroid bed.

3.4 Evaluation of RAI therapy response

All patients underwent ^{131}I therapy 1 to 10 times, with a cumulative dose of 3.7 to 57 GBq, and a single dose of 3.7–7.4 GBq. The initial evaluation of RAI therapy response indicated ER in 15 cases (39.5%), IDR

in 4 cases (10.5%), BIR in 3 cases (7.9%) and SIR in 16 cases (42.1%). A statistically significant difference was found between the ER and NER groups for sTg level (Z = -2.947, p = 0.003) and pathological stage (Z = -2.348, p = 0.019), but not for age, sex, pathological type, TSH and TgAb levels and extra-thyroid ^{99m}Tc-pertechnetate uptake site and rate.

4. Discussion

Evaluation of the postoperative disease status before RAI therapy is extremely important for DTC patients [7]. The ^{99m}Tc-pertechnetate scan is often used to evaluate thyroid residue before the initial RAI therapy, but it is rarely used to detect suspected DTC metastases. The main reason is that although ^{99m}Tc-pertechnetate and iodine form monovalent anions, have similar physical and chemical properties and can be accumulated by sodium iodide symporter (Na+/I-symporter, NIS) located in the membrane of thyroid cells, ^{99m}Tc-pertechnetate cannot further participate in thyroid hormone synthesis after entering thyroid cells (and has faster elution) so the metastases from DTC generally do not show ^{99m}Tc-pertechnetate uptake [16]. Only a few papers have reported ^{99m}Tc-pertechnetate uptake in metastases. Ryo et al. [12] analysed the thyroid scans of 7800 patients, and only 4 cases with lymph node metastases showed ^{99m}Tc-pertechnetate uptake. Our results showed that the vast majority of cases showing extra-thyroid ^{99m}Tc-pertechnetate uptake involved lymph node, lung and bone metastases, especially lymph node metastases, but the reason for this is not clear. We suspect that a large number of thyroid cancer cells can secrete some substances, which is similar to the ability of normal thyroid follicular cells to absorb ^{99m}Tc-pertechnetate.

However, our observations suggest that extra-thyroid ^{99m}Tc-pertechnetate uptake does not always indicate metastases. Our study included two false-positive patients. One patient showed ^{99m}Tc-pertechnetate uptake in the axillary lymph nodes. No abnormality was found on other imaging examinations (including RxWBS/SPECT/CT) before RAI therapy, or on follow-up assessments after RAI therapy. We believe that this finding may be related to transient radioactive accumulation due to extravasation and the subsequent lymphatic drainage to axillary lymph nodes during the injection of ^{99m}Tc-pertechnetate. Another patient showed ^{99m}Tc-pertechnetate uptake in blood vessels. In vitro experimental studies have shown that erythrocytes can show non-specific uptake of ^{99m}Tc-pertechnetate. It is presumed that ^{99m}Tc-pertechnetate can be absorbed by deep venous thrombosis. Sen et al. [13] reported one case of gastric cancer complicated by hyperthyroidism, in which a ^{99m}Tc-pertechnetatescan revealed strip radioactive accumulation in the left upper limb, and ultrasound confirmed deep venous thrombosis. However, we could not confirm whether ^{99m}Tc-pertechnetate uptake in this case indicated thrombosis.

The expression of NIS in thyroid carcinoma is 10 to 1200 times lower than in normal tissue [4]. Therefore, to improve the ability of ^{131}I uptake by DTC metastases, total/near total thyroidectomywith TSH greater than 30 mIU/l is necessary (Tg is the primary biochemical tumour marker for DTC patients and is

influenced by circulating serum TSH concentrations; the cut-off value for adequate sTg is a TSH value of ≥ 30 mIU/l, through THW or the use of human recombinant TSH). In our retrospective study, 21% (8/38) of the patients showed no significant increase in TSH levels during the initial ^{131}I treatment, which may be related to the good ^{99m}Tc-pertechnetate uptake and thyroid hormone secretion of the metastases. To some extent, this explains the higher sTg level before the first RAI therapy and positive correlation with the extra-thyroid ^{99m}Tc-pertechnetate uptake rate.

Diagnostic whole-body scanning (DxWBS) is often used to evaluate thyroid residue and suspected metastases after total/subtotal thyroidectomy, but its clinical application remains debatable due to the possible influence of the stunning effect [15]. In this study, not all patients underwent DxWBS examination before ^{131}I treatment, and the evaluation of metastases was mainly based on neck ultrasound and other imaging examinations such as chest CT scanning. However, lymph node metastases were found in six patients with ^{99m}Tc-pertechnetate uptake, but not by routine ultrasonography, which may be related to the specificity of ultrasound diagnosis and the limitations of the scanning range. Along with routine ^{99m}Tc-pertechnetate scans, we added ^{99m}Tc-WBS/SPECT/CT for extra-thyroid ^{99m}Tc-pertechnetate uptake foci. This improved the accuracy and specificity of the diagnosis of metastases to a certain extent, making up for the lack of evaluation before RAI therapy and playing an important role in the development of treatment plans.

In our study, the bone metastasis group showed stronger ^{99m}Tc-pertechnetate uptake than the lymph node metastasis group. The uptake rate was 0.8% (0.45–1.6%) vs 0.2% (0.1–0.35%), which may be related to the larger range of bone lesions and more ^{99m}Tc-pertechnetate uptake lesions, or to the partial volume effect. In addition, our results showed similarities with some previous studies. There was high consistency between extra-thyroid ^{99m}Tc-pertechnetate uptake foci and ^{131}I uptake foci, and the latter were greater in number. Chantadisai et al. [3] prospectively compared ^{99m}Tc-WBS combined with neck and chest SPECT/CT and RxWBS in 56 patients with post-surgical DTC, and found that the coincidence rate of the two scans was 84%. In the four subgroups of the thyroid bed, lymph nodes, lungs and bones, the coincidence rates of the two scans were 89.5%, 55%, 82.6% and 50%, respectively. In our study, 8 patients showed false-negative results for the detection of residual thyroid tissue in ^{99m}Tc-WBS/SPECT/CT imaging. The possible reasons were as follows: (1) the thyroid tissue uptake ability of ^{99m}Tc-pertechnetate was weaker than that of ^{131}I; (2) the ^{131}I dose was much higher than that of ^{99m}Tc-pertechnetate; and (3) the ^{99m}Tc-pertechnetate scan was performed earlier than the ^{131}I scan, resulting in a low target/background count. A comparative analysis of the ER and NER groups provided the preliminary finding that the higher the sTg level at the first RAI therapy, the later the pathological stage, possibly indicating a poor curative effect and prognosis. However, the subjects of our study were unique patients with extra-thyroid ^{99m}Tc-pertechnetate uptake, which is a relatively rare clinical presentation. Therefore, the sample size was small, and the results cannot necessarily be applied to all metastatic patients undergoing RAI therapy. Thus, future studies should be performed with larger sample sizes.

5. Conclusions

Our results showed that in DTC patients after thyroidectomy, although the sensitivity of ^{99m}Tc-pertechnetate scans in detecting metastases is low, extra-thyroid ^{99m}Tc-pertechnetate uptake mostly indicated metastases with specific clinical features. Additional ^{99m}Tc-WBS/SPECT-CT offers incremental value over planar scans in increasing diagnostic accuracy and reducing pitfalls, which may have prognostic value for the judgment of iodine uptake function and the RAI therapy plan.

Declarations

Ethics approval and consent to participate

This study was conducted in accordance with the Declaration of Helsinki and approved by the ethics committee of Zhejiang University School of Medicine.

Consent for publication

All authors agree to publish this article

Availability of data and materials

The datasets used and/or analysed during the current study are available from the corresponding author on reasonable request.

Conflict of interest

The authors declare that they have no potential conflict of interest relevant to this article.

Funding

This paper was partially supported by the Natural Science Foundation of Zhejiang Province of China (LY17H180005).

Acknowledgement

Not applicable.

Author contributions

(I)Conception and design:Bin Long, Lifang Yao

(II) Administrative support:Cen Lou

(III) Provision of study materials or patients:Xuemei Ye, Heqing Yi

(IV) Collection and assembly of data:Shoucong Chen , Jin Shui

(V) Data analysis and interpretation:Shoucong Chen ,Jin Shui

(VI) Manuscript writing: All author

(VII) Final approval of manuscript:All author

References

1. Biersack HJ, Freeman LM. Clinical Nuclear Medicine. Berlin Heidelberg: Springer; 2008. pp. 287–303.
2. Campenni A, Ruggeri RM, Santoro D, et al. Accidental discovery of lung metastases from differentiated thyroid cancer by 99mTc sodium pertechnetate scan in a patient with secondary hyperparathyroidism. Clin Nucl Med. 2012;37(9):895–6.
3. Chantadisai M, Kingpetch K. Usefulness of (99 m)Tc-pertechnetate whole body scan with neck and chest SPECT/CT for detection of post-surgical thyroid remnant and metastasis in differentiated thyroid cancer patients. Ann Nucl Med. 2014;28:674–82.
4. Filetti S, Bidart JM, Arturi F, et al. Sodium/iodide symporter: a key transport system in thyroid cancer cell metabolism. Eur J Endocrinol. 1999;141:443–57.
5. Gil Martinez E, Calvo Moron MC, Ruiz Franco-Baux JV, et al. [Lung accumulation of 99mTc-pertechnetate in thyroid scintigraphy]. Rev Esp Med Nucl. 2002;21:435–6.
6. Giovanella L, Suriano S, Ricci R, et al. Postsurgical thyroid remnant estimation by ((9)(9)m) Tc-pertechnetate scintigraphy predicts radioiodine ablation effectiveness in patients with differentiated thyroid carcinoma. Head Neck. 2011;33:552–6.
7. Haugen BR, Alexander EK, Bible KC, et al. 2015 American Thyroid Association Management Guidelines for Adult Patients with Thyroid Nodules and Differentiated Thyroid Cancer: The American Thyroid Association Guidelines Task Force on Thyroid Nodules and Differentiated Thyroid Cancer. Thyroid. 2016;26:1–133.
8. Khan SU, Khan AU, Khan A, et al. Extrathyroidal uptake from thyroid carcinoma on 99mTc-pertechnetate scintigraphy. J Coll Physicians Surg Pak. 2011;21:772–4.
9. Kiratli PO, Kara PP, Ergun EL, et al. Metastatic insular thyroid carcinoma: visualized on Tc-99m pertechnetate, Tc-99m MDP and iodine-131 scintigraphy; a review of the literature for other radionuclide agents. Ann Nucl Med. 2004;18:443–6.
10. Liu M, Chai L, Luo Q, et al. 99mTc-pertechnetate-avid metastases from differentiated thyroid cancer are prone to benefit from 131I therapy: A prospective observational study. Medicine (Baltimore). 2017;96:e7631.
11. Lou K, Gu Y, Hu Y, et al. Technetium-99m-pertechnetate whole-body SPET/CT scan in thyroidectomized differentiated thyroid cancer patients is a useful imaging modality in detecting remnant thyroid tissue, nodal and distant metastases before (131)I therapy. A study of 416 patients. Hell J Nucl Med. 2018;21:121–4.

12. Ryo UY, Stachura ME, Schneider AB, et al. Significance of extrathyroidal uptake of Tc-99m and I-123 in the thyroid scan: concise communication. J Nucl Med. 1981;22:1039–42.
13. Sen F, Ogur U, Akpinar AT, et al. Incidental detection of upper extremity deep venous thrombosis on a Technetium-99m pertechnetate thyroid scan. J Postgrad Med. 2011;57:53–5.
14. Yamamoto Y, Nishiyama Y, Ono Y, et al. Accumulation of technetium-99m pertechnetate in a patient with metastases of thyroid carcinoma. Ann Nucl Med. 1999;13:357–9.
15. Yin Y, Mao Q, Chen S, et al. A quantitative study about thyroid stunning after diagnostic whole-body scanning with 74 MBq 131I in patients with differentiated thyroid carcinoma. Q J Nucl Med Mol Imaging. 2015;59:455–61.
16. Zuckier LS, Dohan O, Li Y, et al. Kinetics of perrhenate uptake and comparative biodistribution of perrhenate, pertechnetate, and iodide by NaI symporter-expressing tissues in vivo. J Nucl Med. 2004;45:500–7.

Figures

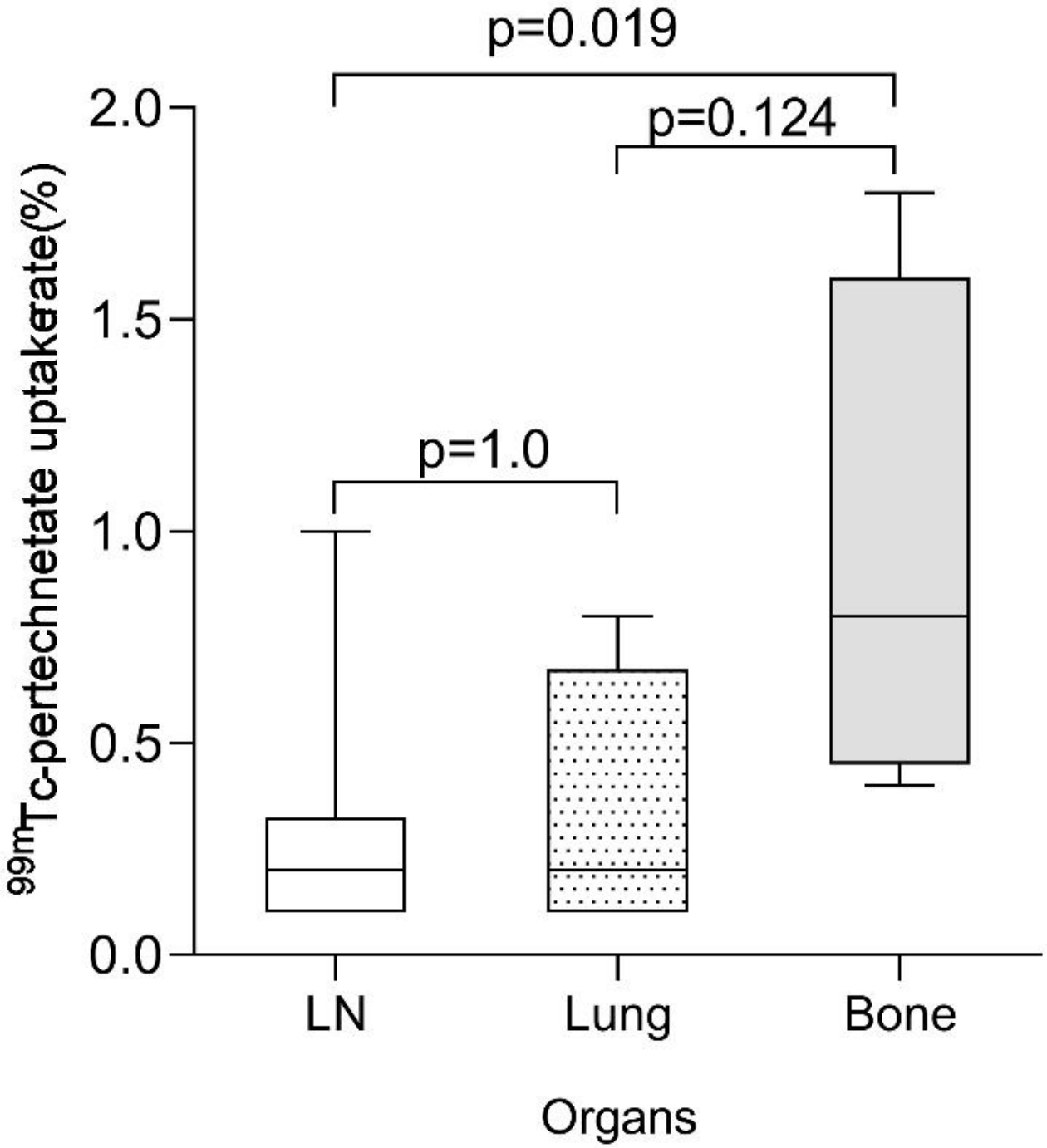

Figure 1

Comparison of 99mTc-pertechnetate uptake rates of extra-thyroid in 38 patients.Data on the relationship among the three subgroups showed that the 99mTc pertechnetate uptake rate in the lymph node subgroup was significantly lower than that in the bone subgroup (Z = 2.722, p = 0.019).

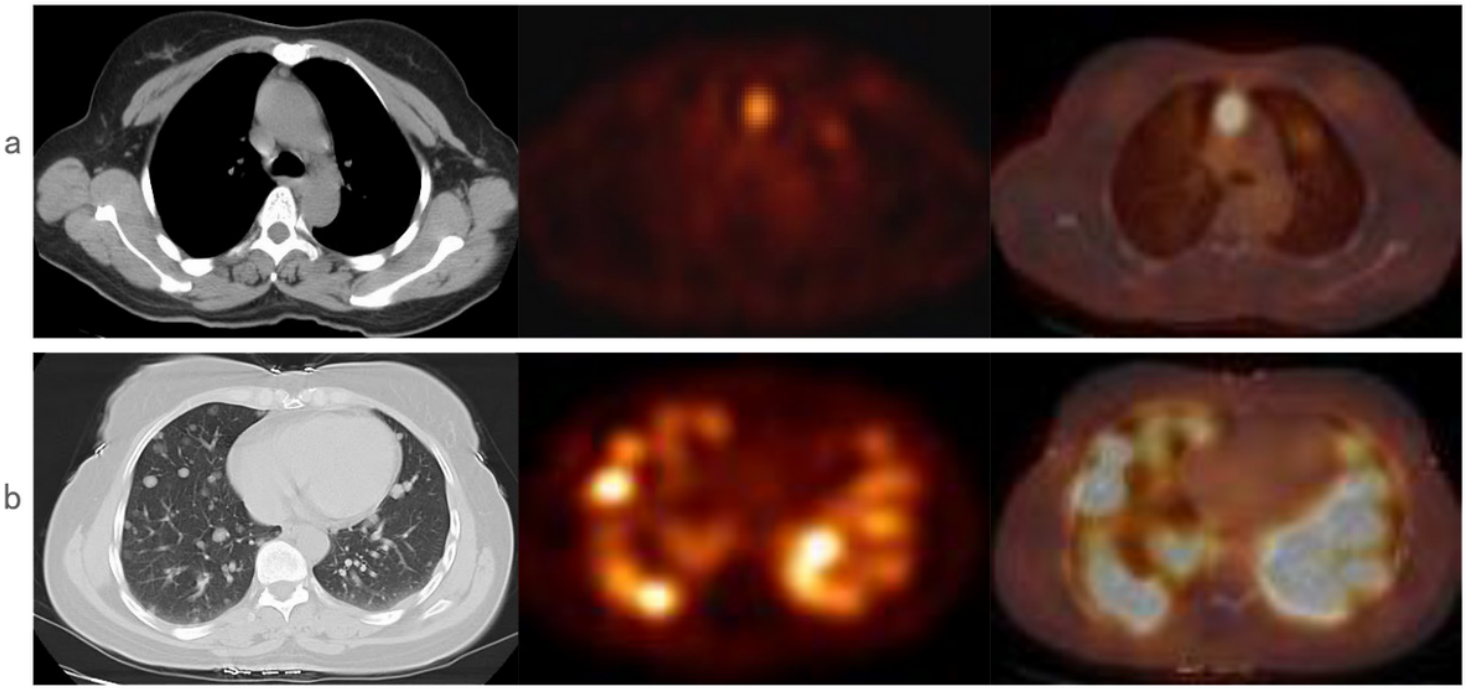

Figure 2

99mTc pertechnetate was taken up by lung and anterior mediastinal lymph node metastases. a 99mTc pertechnetate scan of the anterior mediastinal lymph node metastases. Left, CT scan; middle, 99mTc pertechnetate scan; right, CT and 99mTc pertechnetate image fusion. b 99mTc pertechnetate scan of the lung metastases. Left, CT scan; middle, 99mTc pertechnetate scan; right, CT and 99mTc pertechnetate image fusion.

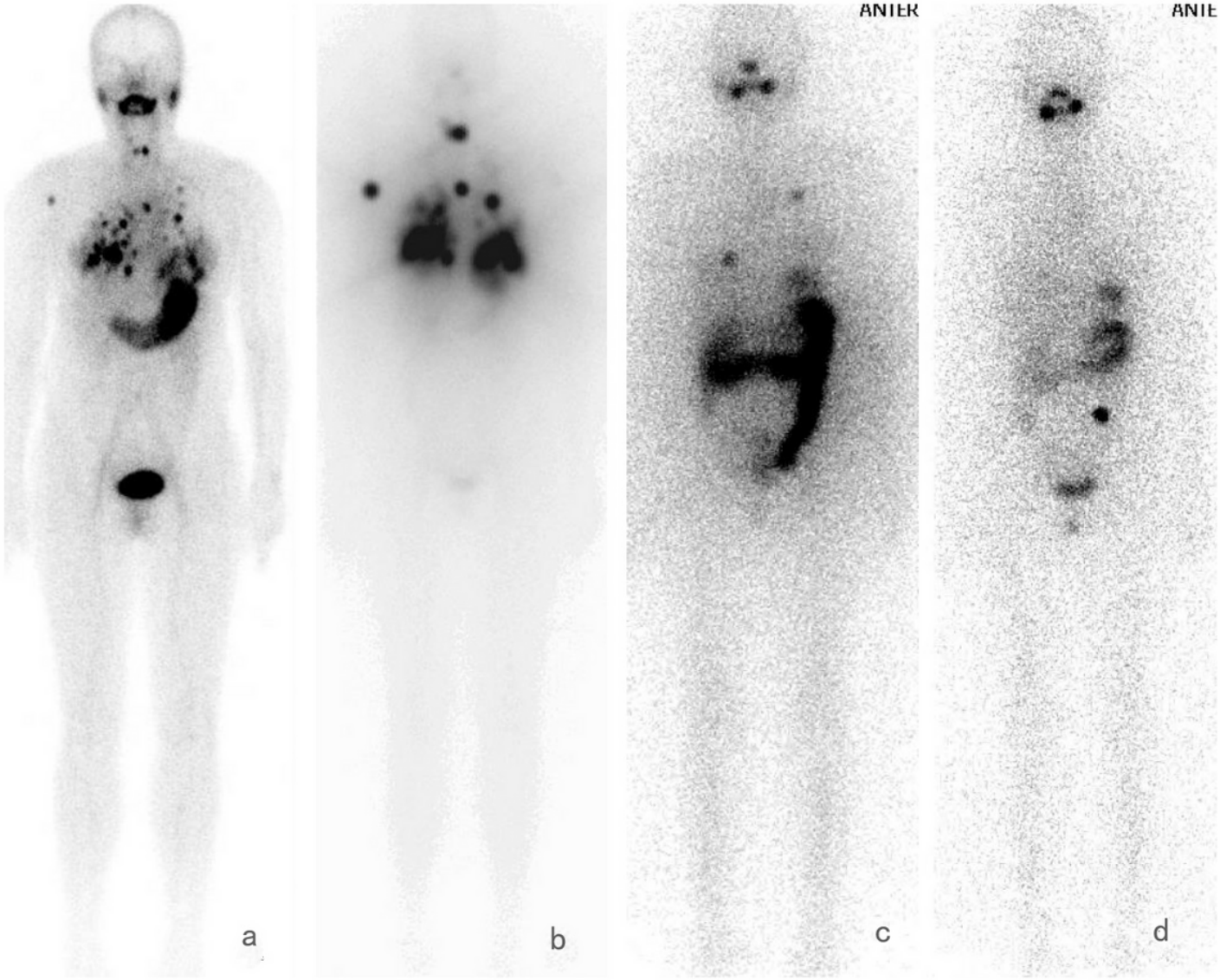

Figure 3

Pulmonary and anterior mediastinal lymph node metastases receded after three cycles of treatment with radioactive iodine (RAI). a a 99mTc pertechnetate whole-body scan showed multiple radioactive nodules on both sides of the chest and mediastinum.before the initial RAI treatment. b 131I whole-body scans (Rx-WBS) showed almost the same metastatic lesions as the Tc-99m pertechnetate scan after the first cycle of RAI therapy. c Rx-WBS scans showed decreased uptake in the metastases after the second cycle of RAI therapy in comparison with b. d Rx-WBS scans after the third cycle of RAI therapy, which indicated complete remission of the multiple metastases.

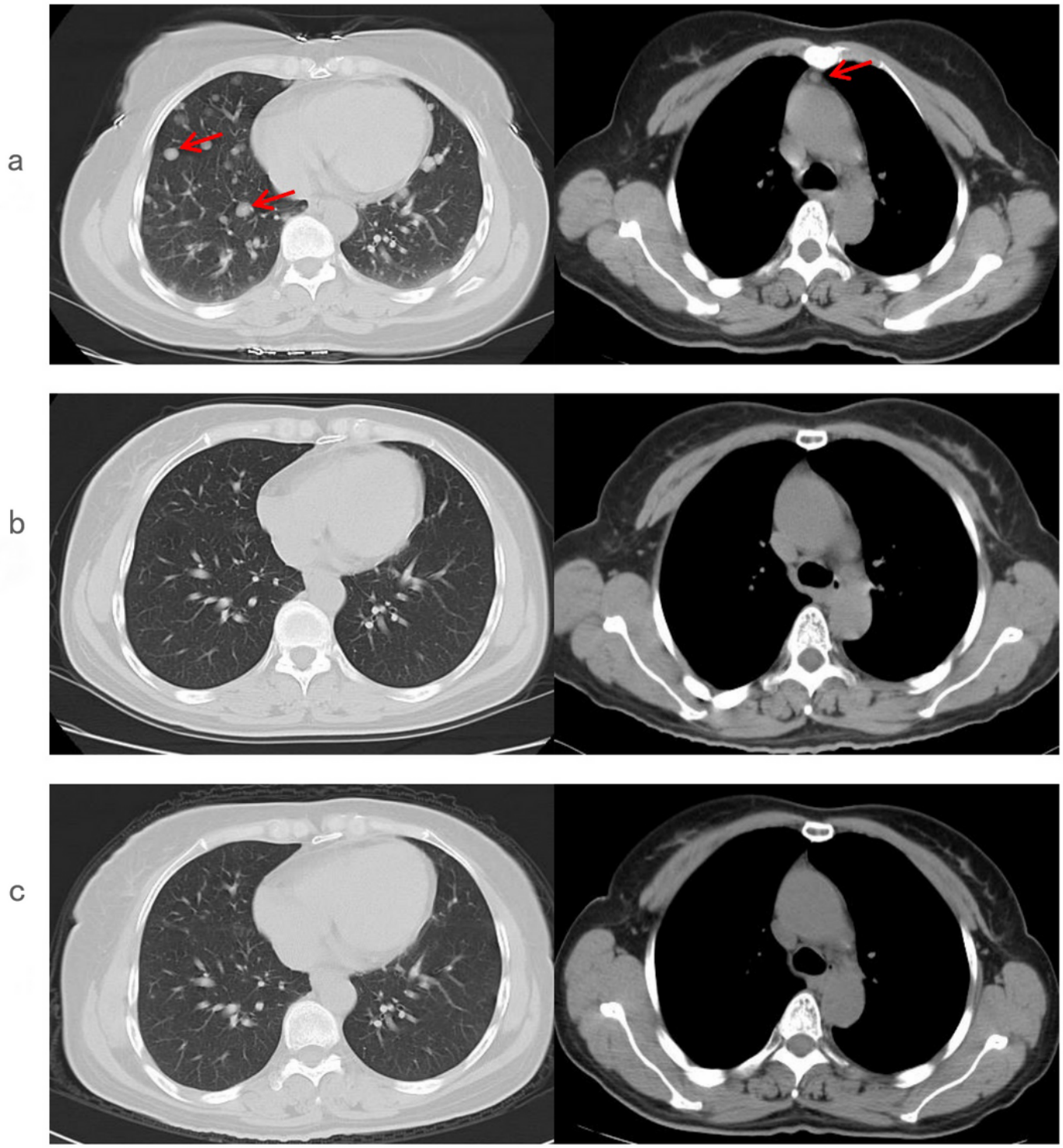

Figure 4

Lung and anterior mediastinal lymph node metastases receded after three cycles of RAI therapy. a Chest CT scans before the initial RAI therapy. Red arrow indicated metastases. b Chest CT scans after the second cycle of RAI therapy. c Chest CT scans after the third cycle of RAI therapy.

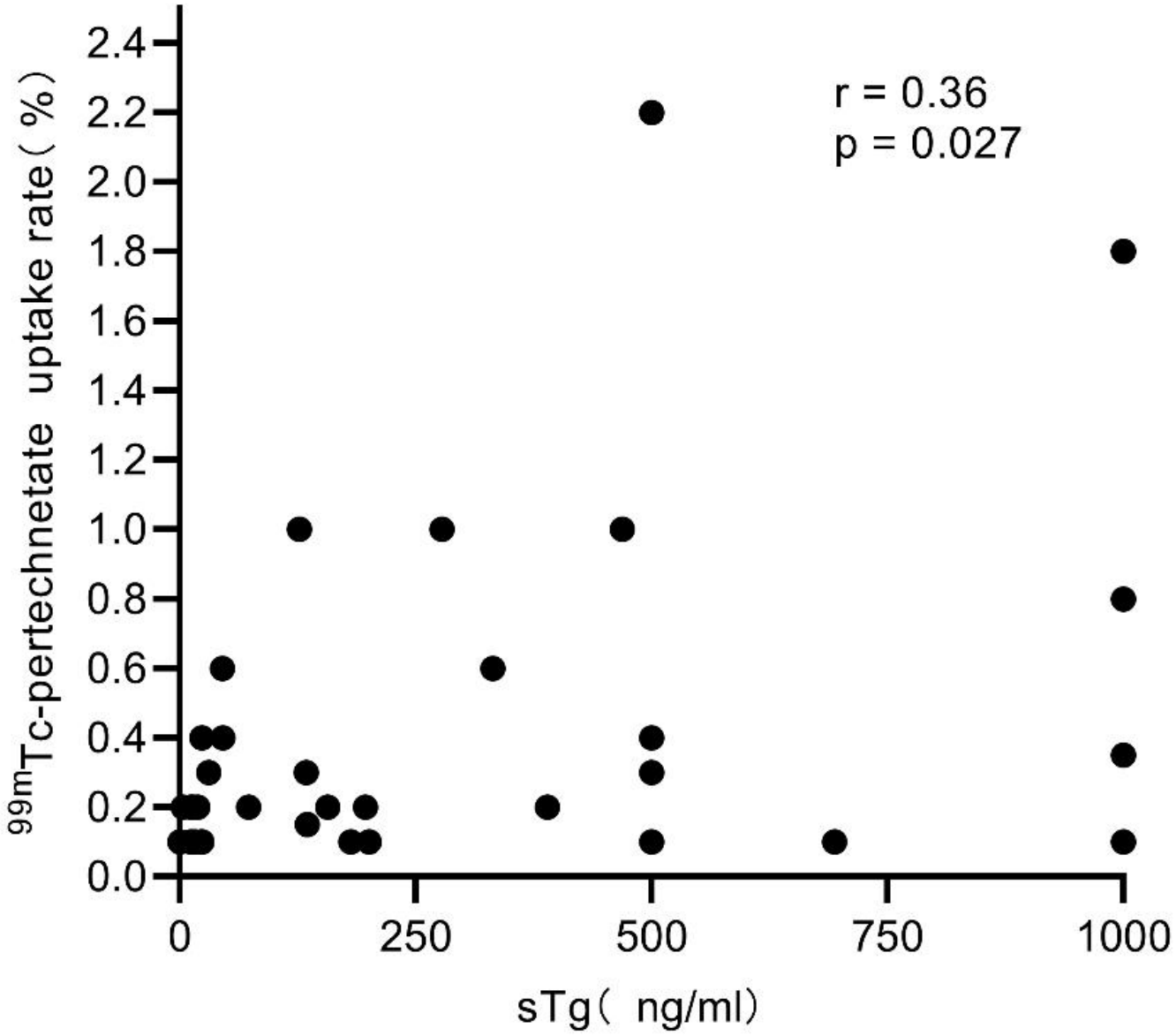

Figure 5

Correlation analyses between sTg and 99mTc-pertechnetate uptake rate of extra-thyroid in 38 patients.The relationship between the two groups had a certain positive correlation (r = 0.36, p = 0.027).