Comparative Efficacy of Intraoperative Extracorporeal Irradiated and Alcohol Inactivated Autograft Reimplantation in Management of Osteosarcomas– A Multicentre Retrospective Study.

Meitao Xu
Third Military Medical University Southwest Hospital
Ming Xu
General Hospital of Jinan Military Command: PLA 960th Hospital
Shuai Zhang
Third Military Medical University Southwest Hospital
Hanqing Li
Third Military Medical University Southwest Hospital
Qiuchi Al
Third Military Medical University Southwest Hospital
Xiuchun Yu
General Hospital of Jinan Military Command: PLA 960th Hospital
xuquan wang (wangxq65@sina.cn)
the fist affiliated hospital of Army Medical University https://orcid.org/0000-0001-9646-160X

Research

Keywords: Osteosarcomas, Bone defects, Inactivated, Autograft, Reimplantation

Posted Date: January 20th, 2021

DOI: https://doi.org/10.21203/rs.3.rs-146990/v1

Abstract

Background: The biologic bone reconstruction in the treatment of malignant bone tumours for the limb salvage surgery has always been a controversial strategie. Vary inactivation methods, convenient, stable, curative effect and economy need to be considered. This study aims to compare the clinical efficacy between intraoperative extracorporeal irradiated and alcohol inactivated autograft reimplantation methods for limb salvage surgery with osteosarcomas.

Methods: We retrospectively analysed 28 patients with osteosarcomas, 14 patients treated with intraoperative cobalt 60 irradiation and reimplantation treatment (Group A), 14 patients treated by alcohol-inactivated autograft reimplantation (Group B). The postoperative complications and clinical efficacy was compared by statistical analysis.

Results: The local recurrence rate was 14.3% in each group. Complete bony union was achieved in 64.3% in group A and 71.4% in group B. The overall 5-year survival rate was 71.4% in group A and 78.6% in group B. The mean MSTS score was 25.33 ± 4.72 (range 15–30) in group A and 24.00 ± 5.85 (range 15–30) in group B. The mean ISOLS score was 25.79 ± 5.13 (range 20–36) in group A and 26.14 ± 5.33 (range 20–30) in group B. $P < 0.05$ was considered to indicate a significant difference, there was no difference in the long-term clinical efficacy between the extracorporeal irradiation and alcohol-inactivated methods.

Conclusions: For limb salvage surgery with osteosarcomas, either intraoperative extracorporeal irradiation or alcohol-inactivated autograft repimlantation had equivalent outcomes for biological reconstruction. The alcohol-inactivated technology could be a much more convenient and cheap treatment to reconstruct bone defects. Additional studies and more case studies are needed to fully evaluate the clinical efficacy and safety of the alcohol-inactivated surgical approach.

Background

Osteosarcoma is the most common primary malignant bone tumour in adolescents [1]. The combination of surgical treatment and neoadjuvant chemotherapy is currently recognized in the past few decades [2]. Many clinical trials are focusing on treating osteosarcoma using a variety of strategies, including osteoarticular or intercalary allografts, allograft prosthetic composites, custom-made or modular prostheses, distraction osteogenesis, and arthrodesis with autogenous or allogenic bone [3–6], for comprehensive treatment with limb salvage surgery and systemic chemotherapy.

Currently, 90–95% of patients with malignant bone tumours can be safely treated with limb salvage surgery. The postoperative recurrence rate is low, and the survival rate is equivalent to amputation. But, the reconstruction of bone defects after resection has always been a great challenge [4].

Through a literature review and in an effort to summarise our relevant clinical experience with biologic bone reconstruction in the treatment of malignant bone tumours in the limb, we conducted a retrospective

case-control study to compare the clinical efficacy between intraoperative extracorporeal irradiated and alcohol inactivated treatment in the management of osteosarcomas.

Methods

Intraoperative cobalt 60 extracorporeal irradiated autograft reimplantation (group A): The soft tissues of Autogenous tumour segment were thoroughly removed and the bone segment was aseptically packed and delivered for cobalt 60 irradiation immediately (group A). After 30 min and 50 Gy dose irradiation, the inactivated autogenous bone segment was returned immediately for the reconstruction surgery. Medullary bone tissue of the extracorporeal irradiated autograft was scraped off for pathological diagnosis to confirm negative findings. Multiple samples were collected from the surgical area and sent for frozen pathological examination to observe whether there was tumour residue at the cutting edge to ensure the safety of resection boundaries at least marginal or extensive. Meanwhile, the surgical wound was completely stop bleeding, immersed and washed repeatedly with normal saline to keep clean and sterile. Finally, the inactivated segment was send back to the operating room for reimplantation by internal fixation (Fig. 1a–h). Bone cement was used to fill any significant bone lacunar defects if necessary.

Alcohol inactivated autograft reimplantation (group B): The surgical resection of the tumour was performed according to the standard principle of resection of malignant tumour segments. Soft tissue and extraosseous tumor were cleared off. The medullary cavity of the autograft bone tumour segment was drilled through. Screw holes for the intended fixation method were preliminary. The tumour segment was inactivated by soaking with 99% alcohol for 30 min retrieved and flushed with 3000 ml physiological saline. Bone cement was pressurized into the inactivated bone segment marrow cavity or bone defect. The excess or leaking bone cement was removed. Then, the autograft segment was re-implanted into the limb defect with solid and effective internal fixation. Screws through previously prepared screw route, and intramedullary screws or steel plates were selected for internal fixation (Fig. 2a–h).

During and after the operation, pathology confirmed that there was no tumour at the edge of the tumour segment and no live tumour cells in the inactivated bone. Routine prophylactic administration of antibiotics was used for 48 h, incision indwelling drainage postoperative. Rehabilitation brace procted if necessary. Patients had bed rest with 4 to 6 weeks of non-weight-bearing activity, after which the patient was allowed to carry out partial load by both crutches, gradually transition to complete load weight-bearing within 3 to 6 months after the operation. All patients received nutritional supportive treatment and were told to avoid strenuous exercise.

The study was approved by the Institutional Ethics Review Board of the First Affiliated Hospital, Third Military Medical University(KY201779) and the Ethics Committee of the 960th Hospital of Chinese People's Liberation Army Joint Logistic Support Force. Written informed consent was obtained from all patients or their guardians and retrospectively registered.

We retrospectively reviewed the charts of 28 patients with osteosarcomas of the limbs between February 2004 and October 2012 according to the biological reconstruction methods of bone defects in limb salvage surgery, including intraoperative cobalt 60 irradiation and reimplantation of the involved bone (group A) and alcohol-inactivated autograft reimplantation (group B). Radiographs and magnetic resonance imaging (MRI) scans of the affected limb were reviewed. Pulmonary computed tomography and Tc-99 bone scintigraphy (ECT) were performed to define metastasis. Pathological diagnosis was confirmed by a needle biopsy at the initial visit. All 28 patients accepted neoadjuvant chemotherapy through two to four sessions of preoperative chemotherapy with the cisplatin, ifosfamide and adriamycin (DIA) chemotherapy regimen [5]. This programme usually takes 6–8 weeks. The tumour boundary was determined by MRI, ECT, and X-ray before and after chemotherapy.

Inclusion criteria: From February 2004 to October 2012, osteosarcoma of the limb treated with cobalt 60 irradiation and reimplantation or alcohol-inactivated autograft reimplantation; In terms of imaging, osteogenesis, sclerosis or small bone dissolution range; The resection boundaries of the tumour at stage IIb according to Enneking staging [6]; Neoplasm did not invade the articular surface, with at least 2 cm of healthy bone remaining for proper internal fixation or bone cement filling; The patient and his family members voluntarily accepted the surgical plan. Exclusion criteria: Neoplasm is mainly invasion of the articular surface; Distant metastases; Criteria for extensive resection or boundary resection cannot be obtained; Patients and their families choose tumour prosthesis reconstruction, allograft reimplantation or amputation surgery.

All the patients were followed up 1, 3, 6, 9 and 12 months after surgery, and then once a year thereafter. Death or loss of follow-up were defined as the end of follow-up. Clinical complications and function were observed. Radiology (X-ray and CT) was used to evaluate the conditions of distant metastasis, local recurrence, bone healing, limb function, and internal fixation. Limb function was evaluated according to the functional score of the Musculoskeletal Tumor Society (MSTS) system. The condition of inactivated bones was assessed according to the International Society of Limb Salvage (ISOLS) image scoring criteria [7].

All analyses were performed using the SPSS statistical software package (version 14.0, SPSS Inc, Chicago, IL, USA). Continuous variables were analysed by a t-test, and categorical variables were compared using a chi-square test. The MSTS and ISOLS scores were compared in the two groups. $P < 0.05$ was considered to indicate a significant difference. The complications were characterized by descriptive statistics in the current version of the ISOLS classification system [8]. Overall survival rate was determined and compared using the Kaplan-Meier method.

Results

Between February 2004 and October 2012, 28 cases were confirmed in this research, including 14 males and 14 females with an average age of 16.36 ± 7.03 (7–38) years old (range 7–38 years). Eleven neoplasms were located in the distal femur, 11 in the proximal tibia and six in others locations (four in the

distal tibia, one in the proximal humerus and one in the proximal radius). All patients were followed up for 98.07 ± 55.29 months (range 6–182 months). In group A, the mean follow-up time at the last visit was 133.43 ± 20.55 months (range 6–182) months. In group B, the mean follow-up time at the last visit was 122.50 ± 14.06 months (range 16–150). In total, 25 patients were treated with wide resection and three patients with marginal resection. The average length of the extracorporeal irradiated autograft was 17.64 ± 4.77 cm (range 12–29) and alcohol-inactivated autograft was 16.00 ± 4.08 cm (range 12–24 cm) (Table 1).

Table 1
Demographic characteristics of the patients

Group	**Group A (n = 14)** **Extracorporeal irradiation**	**Group B (n = 14)** **Alcohol inactivated**	**P value**
Gender			0.706[a]
Male	6	8	
Female	8	6	
Age, years (mean)	17.14 ± 8.87	15.57 ± 4.78	0.564[b]
Tumour location			0.291[c]
Distal femur	5	6	
Proximal tibia	4	7	
Others	5	1	
Autograft length (mean, cm)	17.64 ± 4.77	16.00 ± 4.08	0.336[d]
Follow-up (mean, months)	133.43 ± 20.55	122.50 ± 14.09	0.590[e]
[a] There was no difference in gender between the two groups (Analysis of Fisher's Exact Test, P > 0.05).			
[b] There was no difference in tumour location between the two groups (Analysis of Independent-Samples t test, P > 0.05).			
[c] There was no difference in age between the two groups (Analysis of Fisher's Exact Test, P > 0.05).			
[d] There was no difference in autograft length between the two groups (Analysis of Independent-Samples t Test, P > 0.05).			
[e] There was no difference in follow-up between the two groups (Analysis of Kaplan-Meier Test, P > 0.05).			

The postoperative complications of the autograft included soft tissue failure 7.1% (1/14), aseptic loosening 28.6% (4/14), structural failure 14.3% (2/14), and infection 14.3% (2/14) in each group.

Complete bony union was achieved in 64.3% (9/14) of patients in group A and 71.4% (10/14) of patients in group B. Most bone healing occurred within 8 to 14 months after surgery, which was the same as in the study by Wu et al. [9]. The limb salvage rate was 78.6% (11/14) in group A. One patient with right proximal tibia osteosarcoma had a serious purulent infection 2 months after surgery and underwent treatment with surgical debridement followed by sensitive antibiotics for 6 weeks, with a poor curative effect and amputation surgery was carried out. one local recurrence due to adjacent soft tissue not originating from the transplanted autograft was observed and further amputation was carried out at the patient's insistence at 5 months after surgery. Another patient with osteosarcoma of the left distal tibia, local recurrence occurred in the soft tissue of the ankle at 62 months after surgery. As a result, lower leg amputation was carried out. The limb salvage rate was 85.8% (12/14) in group B. One patient with left distal femur osteosarcoma underwent amputation because of locally recurrent soft tissue tumours, and the graft was invaded at 29 months after surgery. Another patient with left distal femur osteosarcoma with persistent postoperative infection, poor MSTS score and structural failure at 36 months after surgery was treated by lower thigh amputation. Regarding tumour progression, all patients were without bony progression. Two cases of soft tissue local recurrence were observed in each group, with a local recurrence rate 14.3% (2/14).

At the end of follow-up, the mean MSTS score was 25.33 ± 4.72 (range 15–30) in group A and 24.00 ± 5.85 (range 15–30) in group B. The mean ISOLS score was 25.79 ± 5.13 (range 20–36) in group A and 26.14 ± 5.33 (range 20–30) in group B. Comparing the extracorporeal irradiation and alcohol-inactivated methods, there was no significant difference in the incidence of tumour recurrence and no difference in the long-term clinical efficacy between the two biological reconstruction treatments of limb salvage surgery for osteosarcomas (Table 2).

Table 2
Comparison of MSTS score and ISOLS score between two groups at last follow-up

Group	**Group A (n = 14)**	**Group B (n = 14)**	**P value**
	Extracorporeal irradiation	**Alcohol inactivated**	
MSTS score	25.33 ± 4.72	24.00 ± 5.85	0.539[a]
ISOLS score	25.79 ± 5.13	26.14 ± 5.33	0.858[b]
[a] There was no difference in MSTS score between the two groups (Analysis of Independent-Samples t Test, P > 0.05).			
[b] There was no difference in ISOLS score between the three groups (Analysis of Independent-Samples t Test, P > 0.05).			

The total mortality rate was 25.0% (7/28). The seven cases all died of pulmonary metastases, with a metastasis rate of 28.6% (4/14) in group A and 21.4% (3/14) in group B. Ten patients survived for more than 5 years, and the overall 5-year survival rate was 71.4% (10/14) in group A and 78.6% (11/14) in group B. The 5-year survival rate was calculated according to the Kaplan-Meier survival curve, and there

was no difference in the 5-year survival rate between the extracorporeal irradiation and alcohol-inactivated treatments (Fig. 3).

Discussion

Osteosarcoma is the most common highly malignant bone tumour in adolescent patients, with high mortality and disability rates. With the progress of neoadjuvant chemotherapy, imaging techniques and continuous development of reconstruction methods, limb salvage is always the preferred treatment model. Compared with amputation, limb salvage can achieve a similar 5-year survival rate and disease-free survival rate, and it can also obtain better psychological acceptance of patients [10]. Advances in chemotherapy and surgery have taken osteosarcoma from an almost universally fatal disease to one in which the majority of patients will survive with a meaningful quality of life [11].

How to choose the appropriate treatment program for bone defect reconstruction is a problem faced by surgeons. The reconstruction methods for bone defects after resection of malignant bone tumours include manufactured tumour-type artificial joints, biological constructs, bulk allografts, combinations of allograft-prosthetic composites and bone autografts to provide a stable reconstruction [12, 13]. Although prosthesis replacement is widely used at present, there are many complications, such as infection, loosening and fracture, especially in young adult patients who have high functional requirements. Furthermore, patients with high/intense activity have a higher failure rate. 3D-printed prostheses can also be used but much more expensive and complicated procedure [14]. In 2019, Zhao et al. [15], reported a systematic review of 33 studies with tumours affecting the distal tibia by searching the PubMed and EMBASE databases. In the 337 cases, biological reconstruction methods showed a better functional outcome (78.4% vs. 72.2%, P = 0.017) than non-biological prosthetic reconstruction methods. There are many problems with the use of allografts, such as the spread of infectious diseases, immune responses and social or religious beliefs, especially in Asian countries [16, 17]; a high incidence of complications (70%); and graft rejection (60%) in patients with limb sarcoma following allograft reconstruction for more than 10 years [18]. Furthermore, biological reconstruction might be the optimal reconstructive method. The patient’s own resected tumour segment after inactivation and reimplantation was considered to be an interesting idea for autografts used in bone defect reconstruction after resection of the malignant bone tumour. This technique will probably have a role in the management of osteosarcoma, and allograft use could be replaced in some settings [15], which is especially suitable for countries where foreign bone is difficult to obtain [19].

Extracorporeal irradiation and freezing are two common techniques used to eliminate residual tumour cells for autografts in limb salvage surgery with biological reconstruction of bone defects. Acceptable survival rates and satisfying function have been shown in some of the literature. In 1968, Spira and Lubin [20] first reported the application of extracorporeal irradiation in limb salvage treatment of malignant bone tumours. Compared with prosthetic reconstruction, this method is more economical and biological reconstruction is more acceptable to patients and their families [21, 22]. During the past 50 years, several oncologists have reported this inactivation method, but with the popularity of limb salvage surgery for

malignant bone tumours, there are still many scholars who insist on and have interest in this technique [12, 23, 24]. A comparative study was performed to observe the effect of intraoperative extracorporeal irradiation and freezing treatments of tumour-bearing autografts, and no differences were found in the accumulated proportion of patients achieving union between the groups at 6, 9, 12, and 18 months [9]. Radiographic evaluation did not show differences in the average scores of the compared criteria. Tsuchiya et al. [25] applied liquid nitrogen freeze inactivation of autologous tumour bone in 28 cases of malignant bone tumours. The average follow-up time was 28.1 months (range 10–54), with bony union at a mean of 6.7 months after the operation in 26 patients (92.8%) and non-union occurring in two patients. Heat treatment would reduce bone strength but would lead to a loss of bone induction ability. Jeon et al. [26] treated 15 patients with distal femoral osteosarcoma with high-pressure steam inactivation of autologous bone reimplantation and followed them up for an average of 56 months (35–78 months). After surgery, five patients presented with non-union of bone, three patients presented with a loose prosthesis and no patients had an infection.

As a traditional biological bone reconstruction model, extracorporeal irradiation for limb salvage therapy has been widely reported, while the alcohol-inactivated technique has been rarely reported. Complications, such as graft fracture, infection, and non-union, must have an obviously negative effect on whole graft survivorship. The effectiveness of tumour eradication with the alcohol-inactivated technique has not yet been clearly revealed. We have developed a joint-preserving limb salvage approach for the treatment of osteosarcoma of the distal femur that involves reimplantation of alcohol-inactivated bone based on findings from a previous study. Alcohol might play a double role in the autograft: one is its killing effect on microbes, as well as tumour cells, and the other is its non-interference in the process of creeping substitution from the host [27]. Ten patients with Enneking stage IIb osteosarcoma were treated by alcohol-inactivated autograft reimplantation with joint preservation. The patients were followed up for an mean of 34 months, and all patients obtained first-stage healing, with a mean MSTS function score of 23 (77%) [28]. Our preliminary findings indicate that alcohol inactivation is a feasible approach that may help preserve the important structures of the joint and avoid long-term complications that can occur with endoprosthetic replacement [29]. Additional studies are needed to fully evaluate the efficacy and safety of this surgical approach. Our study provides a valuable reference for the clinical treatment of malignant bone tumours by comparing the clinical efficacy of the two methods. In this study, in the group of 14 osteosarcoma patients with alcohol inactivated autograft reimplantation, the 5-year survival rate was 71.4% (10/14), which is less than extracorporeal irradiation at 82.8% and frozen treatment at 84.4% [12].

Compared with other biological bone reconstruction methods, the alcohol-inactivated method is not only safe and effective in killing tumour cells but also more economical and convenient, with same shape matching for reimplantation. The disadvantage is that it takes a long time to complete the revascularization and to achieve normal bone union with the surrounding bone tissue. The adjacent joint may have cartilage degeneration and joint relaxation complications. The healing process of autograft bone reimplantation is the result of absorb, crawl and supersede and may be the main osteogenic pathway at the bone junction, and femur healing time is faster than tibia healing time [30]. In our study, most unions were detected within 8–14 months after surgery, which is similar to that of the research by

Wu et al. [9] who performed a comparative study to observe the effect of intraoperative extracorporeal irradiation and freezing treatments. Ogura et al. [31] conducted a retrospective review of 11 patients undergoing reconstruction using a devitalized autograft, deep freezing and a vascularized fibula graft composite for lower extremity malignant bone tumours. A shorter union time (7 months) was reported for the autografts treated with freezing. The advantage of freezing may associated with the preservation of bone morphogenetic protein (BMP) in inactivated bone [32], which is superior to heat treatment, including extracorporeal irradiation, autoclaving, and pasteurization., Whether there is any difference in the efficacy of the three methods of autologous bone inactivation (extracorporeal irradiation, freezing or alcohol inactivation) has not been reported in a controlled study of clinical literature. Besides the influence factor of different inactivation methods, many other variable factors, such as the damage or quality of grafts, sites of tumour, reconstruction methods, stabilization during reconstruction, tumour local recurrence and infectious complications, may affect the process of graft osteogenic healing. All these relevant factors need to be considered and incorporated into the design of future studies.

The total complication rate (including tumour progression) was 42.9% (6/14) for irradiation treatment in the study, and Wu et al. [9], in an early, large sample size and controlled study, reported a complication rate of 44% (35/79). For the patients receiving alcohol inactivated autografts, we found a complication rate of 42.79% (6/14) that was a little higher than our previously reported 40% rate (4/10, with one local recurrence and three fractures of the inactivated bone or bending or breakage of the intramedullary nail [31]. Infections occurred in 14.3% (2 /14) of patients in each of our groups, which is higher than Wu et al. [9] who reported an infection rate of 8% (6/79) in the irradiation group and 5% (4/85) in the frozen autografts. The main worry about the alcohol inactivation technique is related to safety and the potential risk of recurrence, although its safety and effectiveness at killing tumour cells has been proven before in our preliminary findings the outcome in the management of osteosarcoma of the distal femur [28] and alcohol inactivated autograft-prosthesis composite for grade III giant cell tumor treatment [30]. Even with the clinical application of neoadjuvant chemotherapy and technical improvements in limb salvage surgery, local recurrence occurred in 11.6% of all patients and 12.4% of patients presented with distant metastases of osteosarcoma in a study by Bielack et al. [33]. Local recurrence presented at the same rate 14.3% (2/14) between the irradiation group and the alcohol inactivation group in our study, respectively, and the overall tumour recurrence rate was 15%(12/79) in the group treated with extracorporeal irradiation and 11% (9/85) in the group treated with freezing in the study by Wu et al. [9]. No tumour recurrence originating from inactivated bone was observed. It proved that either 50 Gy irradiation or 30 minutes of alcohol inactivation in autografts could achieve similar and reliable efficacy in eradicating tumour cells. Implantation of the tumour cells at the time of surgery is thought to be one of the causes of local recurrence [34]. In terms of survival, there was no difference between reconstructions receiving composites and intercalary grafts [35], which is similar to what we found in our study.

Although satisfactory outcomes were obtained in this study, several limitations exist. First, this was a retrospective study with a short follow-up period and small sample size, which may affect the reliability of the results. Further studies involving a larger cohort of patients and longer follow-up are needed to fully evaluate the efficacy and safety of this treatment approach. Second, the selection bias associated with

surgical methods may affect the clinical outcomes. Alcohol-inactivated bone requires a longer time to accomplish revascularization and to integrate with the surrounding bone, which leads to greater length of time required for bone healing after surgery.

Conclusions

For patients with osteosarcomas in this study, either intraoperative extracorporeal irradiation or alcohol-inactivated autograft reimplantation had similar outcomes. For biological reconstruction, except the usually choose of traditional irradiation inactivation and freezing using liquid nitrogen therapy, the alcohol-inactivated technology could be a further more convenient and economical treatment to reconstruct bone defects for osteosarcomas. Additional studies and more case and longer followed-up studies are needed to fully evaluate the clinical efficacy and safety of the alcohol-inactivated treatment.

Declarations

Acknowledgments

We thank the data collectors and the study participants of Department of Orthopaedics, the 960th Hospital of Chinese People's Liberation Army Joint Logistic Support Force, Jinan, 250031, China. For their altruistic assistance during the research.

Funding

All authors declare that no payments or services have been received from any third party or institution, either directly or indirectly. Neither the authors nor their institution(s) have received any financial or material support from any arena that could be perceived to influence or have the potential to influence this work.

Availability of data and materials

All data used in the study are available at the request of editors and reviewers.

Authors’ contributions

Meitao Xu and Ming Xu contributed equally to this work and should both be considered first authors, they did the study design and case review as well as this article writing. **Xiuchun Yu and XuQuan Wang** be considered corresponding authors, responsible for performing the operation, and monitoring this test. **Shuai Zhang, Hanqing Li and Qiuchi Al** made contribution to case follow-up, data collation and statistics to this work. All authors familiar with the contents of the final draft and take responsibilities for the authenticity of data used in the paper. All authors read and approved the final manuscript.

Ethics approval and consent to participate

All patients consented to the data of their conditions being used in this study. The data of intraoperative cobalt 60 extracorporeal irradiated autograft reimplantation used were obtained from the the First Affiliated Hospital, Third Military Medical University. The data of alcohol inactivated autograft reimplantation used were obtained from the

department of Orthopaedics, the 960th Hospital of Chinese People's Liberation Army Joint Logistic Support Force.

The study was approved by the Institutional Ethics Review Board of the First Affiliated Hospital, Third Military Medical University(KY201779) and the Ethics Committee of the 960th Hospital of Chinese People's Liberation Army Joint Logistic Support Force. Written informed consent was obtained from all patients or their guardians and retrospectively registered.

Consent for publication

All patients consented to the publishing of the results of this study.

Competing interests

The authors declare that they have no competing of interests.

References

1. Mirabello L, Troisi RJ, Savage SA. Osteosarcoma incidence and survival rates from 1973 to 2004: data from the Surveillance, Epidemiology, and End Results Program. Cancer. 2009;115(7):1531-43.
2. Link MP, Goorin AM, Miser AW, Green AA, Pratt CB, Belasco JB, et al. The effect of adjuvant chemotherapy on relapse-free survival in patients with osteosarcoma of the extremity. N Engl J Med. 1986;314(25):1600-06.
3. Rose PS. What's New in Musculoskeletal Tumor Surgery. J Bone Joint Surg Am. 2019;101(24):2159-66.
4. Hoefkens F, Dehandschutter C, Somville J, Meijnders P, Van Gestel D. Soft tissue sarcoma of the extremities: pending questions on surgery and radiotherapy. Radiat Oncol. 2016;11(1):136.
5. Xu M, Xu S, Yu X. Marginal resection for osteosarcoma with effective neoadjuvant chemotherapy: long-term outcomes. World J Surg Oncol. 2014;12:341.
6. Enneking WF, Spanier SS, Goodman MA. A system for the surgical staging of musculoskeletal sarcoma. 1980. Clinical orthopaedics and related research. 2003;415:4-18.
7. Poffyn B, Sys G, Van Maele G, Van Hoorebeke L, Forsyth R, Verstraete K, et al. Radiographic analysis of extracorporeally irradiated autografts. Skeletal Radiol. 2010;39(10):999-1008.
8. Henderson ER, O'Connor MI, Ruggieri P, Windhager R, Funovics PT, Gibbons CL, et al. Classification of failure of limb salvage after reconstructive surgery for bone tumours : a modified system Including biological and expandable reconstructions. Bone Joint J. 2014;96-b(11):1436-40.

9. Wu PK, Chen CF, Chen CM, Cheng YC, Tsai SW, Chen TH, et al. Intraoperative Extracorporeal Irradiation and Frozen Treatment on Tumor-bearing Autografts Show Equivalent Outcomes for Biologic Reconstruction. Clinical orthopaedics and related research. 2018;476(4):877-89.
10. Jauregui JJ, Nadarajah V, Munn J, Pivec R, Kapadia BH, Lerman DM, et al. Limb Salvage Versus Amputation in Conventional Appendicular Osteosarcoma: a Systematic Review. Indian J Surg Oncol. 2018;9(2):232-40.
11. Durfee RA, Mohammed M, Luu HH. Review of Osteosarcoma and Current Management. Rheumatol Ther. 2016;3(2):221-43.
12. Campanacci L, Alì N, Casanova JM, Kreshak J, Manfrini M. Resurfaced allograft-prosthetic composite for proximal tibial reconstruction in children: intermediate-term results of an original technique. J Bone Joint Surg Am. 2015;97(3):241-50.
13. Grimer RJ. Surgical options for children with osteosarcoma. Lancet Oncol. 2005;6(2):85-92.
14. Wei R, Guo W, Ji T, Zhang Y, Liang H. One-step reconstruction with a 3D-printed, custom-made prosthesis after total en bloc sacrectomy: a technical note. Eur Spine J. 2017;26(7):1902-09.
15. Zhao Z, Yan T, Guo W, Yang R, Tang X, Wang W. Surgical options and reconstruction strategies for primary bone tumors of distal tibia: A systematic review of complications and functional outcome. J Bone Oncol. 2019;14:100209.
16. Gilbert NF, Yasko AW, Oates SD, Lewis VO, Cannon CP, Lin PP. Allograft-prosthetic composite reconstruction of the proximal part of the tibia. An analysis of the early results. J Bone Joint Surg Am. 2009;91(7):1646-56.
17. Gautam D, Malhotra R. Megaprosthesis versus Allograft Prosthesis Composite for massive skeletal defects. J Clin Orthop Trauma. 2018;9(1):63-80.
18. Ogilvie CM, Crawford EA, Hosalkar HS, King JJ, Lackman RD. Long-term results for limb salvage with osteoarticular allograft reconstruction. Clinical orthopaedics and related research. 2009;467(10):2685-90.
19. Muramatsu K, Ihara K, Miyoshi T, Yoshida K, Iwanaga R, Hashimoto T, et al. Stimulation of neo-angiogenesis by combined use of irradiated and vascularized living bone graft for oncological reconstruction. Surg Oncol. 2012;21(3):223-29.
20. Spira E, Lubin E. Extracorporeal irradiation of bone tumors. A preliminary report. Isr J Med Sci. 1968;4(5):1015-19.
21. Singh VA, Nagalingam J, Saad M, Pailoor J. Which is the best method of sterilization of tumour bone for reimplantation? A biomechanical and histopathological study. Biomed Eng Online. 2010;9:48.
22. Puri A, Gulia A, Agarwal M, Jambhekar N, Laskar S. Extracorporeal irradiated tumor bone: A reconstruction option in diaphyseal Ewing's sarcomas. Indian J Orthop. 2010;44(4):390-96.
23. Agarwal MG, Gundavda MK, Gupta R, Reddy R. Does Extracorporeal Irradiation and Reimplantation After Acetabular Resections Result in Adequate Hip Function? A Preliminary Report. Clin Orthop Relat Res. 2018;476(9):1738-48.

24. Tang X. CORR Insights®: Does Extracorporeal Irradiation and Reimplantation After Acetabulum Resections Result in Adequate Hip Function? A Preliminary Report. Clin Orthop Relat Res. 2018;476(9):1749-50.
25. Tsuchiya H, Wan SL, Sakayama K, Yamamoto N, Nishida H, Tomita K. Reconstruction using an autograft containing tumour treated by liquid nitrogen. J Bone Joint Surg Br. 2005;87(2):218-25.
26. Jeon DG, Kim MS, Cho WH, Song WS, Lee SY. Pasteurized autograft-prosthesis composite for distal femoral osteosarcoma. J Orthop Sci. 2007;12(6):542-49.
27. Sung HW, Wang HM, Kuo DP, Hsu WP, Tsai YB. EAR method: an alternative method of bone grafting following bone tumor resection (a preliminary report). Semin Surg Oncol. 1986;2(2):90-98.
28. Yu XC, Xu SF, Xu M, Liu XP, Song RX, Fu ZH. Alcohol-inactivated autograft replantation with joint preservation in the management of osteosarcoma of the distal femur: a preliminary study. Oncol Res Treat. 2014;37(10):554-60.
29. Xu S, Yu X, Xu M, Fu Z, Chen Y, Sun Y, et al. Limb function and quality of life after various reconstruction methods according to tumor location following resection of osteosarcoma in distal femur. BMC Musculoskelet Disord. 2014;15:453.
30. Xu S, Yu X, Xu M, Fu Z. Inactivated autograft-prosthesis composite has a role for grade III giant cell tumor of bone around the knee. BMC Musculoskelet Disord. 2013;14:319.
31. Ogura K, Miyamoto S, Sakuraba M, Fujiwara T, Chuman H, Kawai A. Intercalary reconstruction after wide resection of malignant bone tumors of the lower extremity using a composite graft with a devitalized autograft and a vascularized fibula. Sarcoma. 2015;2015:861575.
32. Takata M, Sugimoto N, Yamamoto N, Shirai T, Hayashi K, Nishida H, et al. Activity of bone morphogenetic protein-7 after treatment at various temperatures: freezing vs. pasteurization vs. allograft. Cryobiology. 2011;63(3):235-39.
33. Bielack SS, Kempf-Bielack B, Delling G, Exner GU, Flege S, Helmke K, et al. Prognostic factors in high-grade osteosarcoma of the extremities or trunk: an analysis of 1,702 patients treated on neoadjuvant cooperative osteosarcoma study group protocols. J Clin Oncol. 2002;20(3):776-90.
34. Kundu ZS, Gupta V, Sangwan SS, Goel S, Rana P. Iatrogenic giant cell tumor at bone graft harvesting site. Indian J Orthop. 2013;47(1):107-10.
35. Igarashi K, Yamamoto N, Shirai T, Hayashi K, Nishida H, Kimura H, et al. The long-term outcome following the use of frozen autograft treated with liquid nitrogen in the management of bone and soft-tissue sarcomas. Bone Joint J. 2014;96-b(4):555-61.

Figures

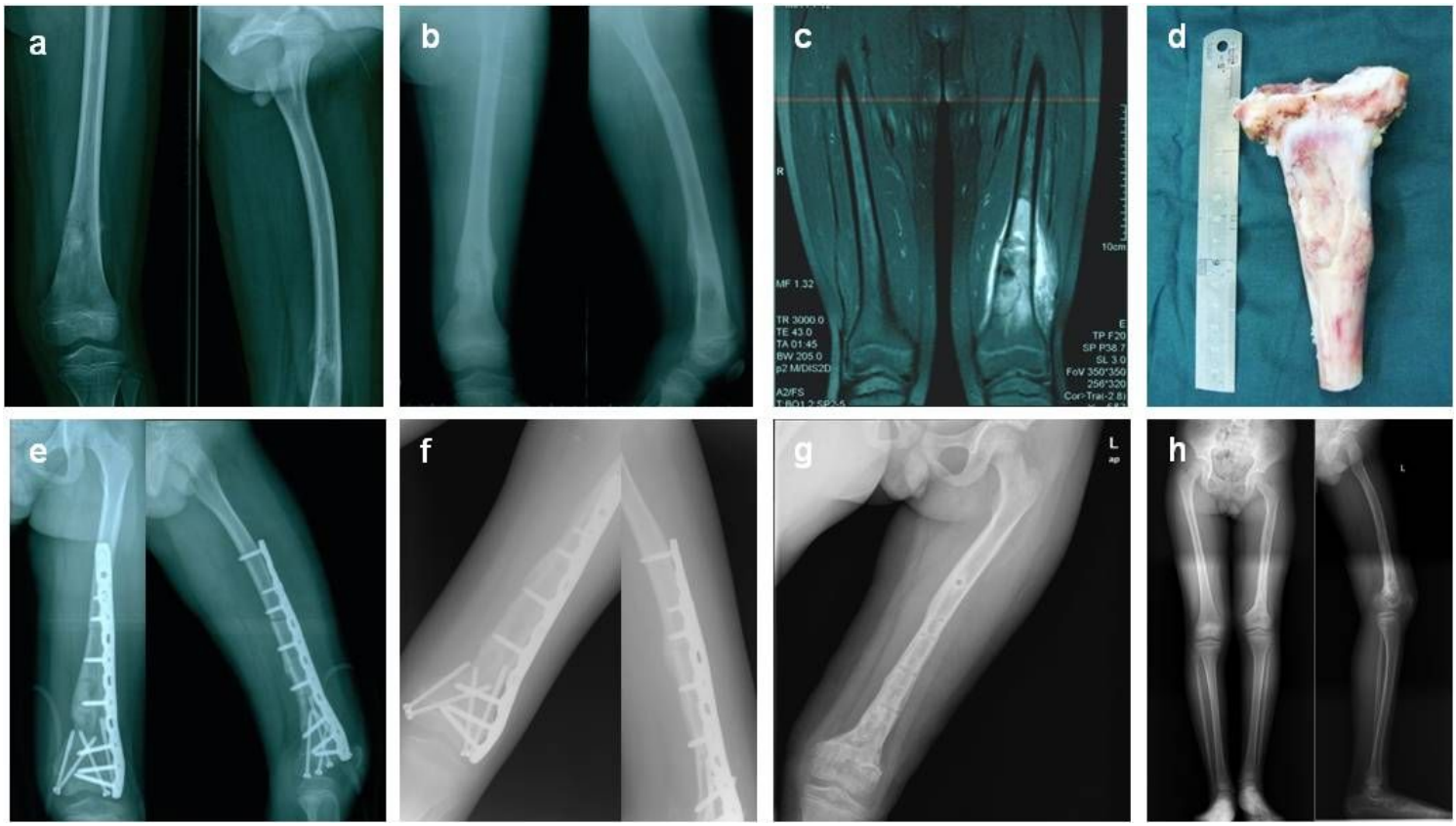

Figure 1

a The pre-chemotherapy X-ray examination showing osteolytic bone destruction in the left distal femur of a 7-year-old male patient who underwent joint preservation intraoperative extracorporeal inactivated autograft replantation for osteosarcoma of the distal femur. Bone destruction on the medial side, with a local soft tissue mass and periosteal reaction was apparent. b Two months after chemotherapy, X-ray examination revealed that osteolytic bone destruction had markedly decreased in the distal femur. The soft tissue mass had disappeared. c The post-chemotherapy coronal MRI shows mixed high and low signals inside the medullary cavity. The surrounding soft tissue and bone marrow response area were clearly demarcated. d After 30 min and 50 Gy dose irradiation by cobalt 60, the 13 cm length of inactivated autogenous segment was returned for reconstruction. e Radiographs, 1 week after surgery, showed apparent reduction of the distal femur by solid internal fixation and joint preservation. f Four months after surgery, the X-ray examination revealed bone healing and a normal joint space. g The X-ray examination showed excellent bone healing, and the internal fixation was removed 2 years after the limb salvage surgery. h At 4 years follow-up, the full-length X-ray of the left lower extremity showed it was about 5 cm shorter than normal.

Figure 2

a The pre-chemotherapy X-ray examination showing osteolytic bone destruction in the right proximal tibia of a 18-year-old male patient who underwent joint preservation alcohol inactivated autograft replantation for osteosarcoma. b The pre-chemotherapy coronal and sagittal MRI shows mixed high and low signals inside the medullary cavity of the tibia and surrounding soft tissue. c Two months after chemotherapy, X-ray examination revealed that osteolytic bone destruction had markedly decreased. d The photo during surgery showed the alcohol inactivated autograft segment was filled with bone cement in the bone defect of the medial tibial plateau and replanted for reconstruction was firmly fixed by intramedullary nail fixation. e Radiographs, 1 week after surgery, showed solid internal fixation and joint preservation of the knee. f At 1 year after surgery, the X-ray examination revealed bone healing but articular space narrowing can be seen. g The X-ray examination showed 3 years after the limb salvage surgery. h At 7 years follow-up, the X-ray examination of the right knee showed condition of the alcohol inactivated autograft segment. Subchondral bone was partially resorbed and fractured, space narrowing, arthrosis indicated.

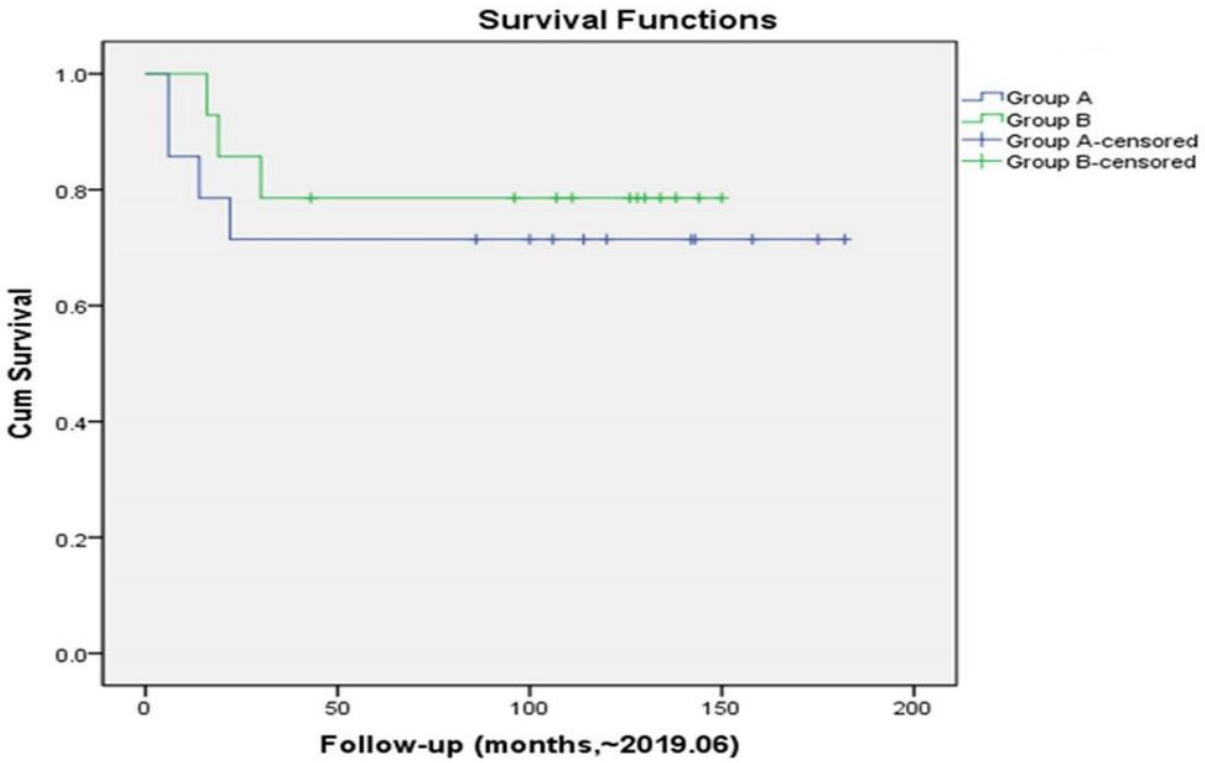

Fig. 3 Kaplan-Meier modeling for 5-year overall survival rate

Figure 3

Kaplan-Meier modelling for 5-year overall survival rate is shown.