Mid-term results of bilateral synchronous total hip arthroplasty for bony ankylosis in patients with ankylosing spondylitis

Lei Han (hallen505@163.com)
Institute of Orthopaedics https://orcid.org/0000-0001-5338-9820

Jing Jing Liu
Rheumatology Research Center

Zhen le Pei
Rheumatology Research Center

Guo ping Cao
Institute of Orthopaedics

Yun gen Hu
Institute of Orthopaedics

Ren fu Quan
Institute of Orthopaedics

Research article

Keywords: arthroplasty, replacement, hip, spondylitis, ankylosing spondylitis

Posted Date: February 21st, 2020

DOI: https://doi.org/10.21203/rs.2.24231/v1

Version of Record: A version of this preprint was published at Journal of Orthopaedic Surgery and Research on February 2nd, 2021. See the published version at https://doi.org/10.1186/s13018-021-02258-z.

Mid-term results of bilateral synchronous total hip arthroplasty for bony ankylosis in patients with ankylosing spondylitis

Author names:[1] Lei Han, MD,[2] Jingjing Liu,MD,[3]Zhenle Pei,[1]Guoping Cao, MD, [1]Yungen Hu, MD，[1]Renfu Quan, MD, PhD

Lei Han and Jingjing Liu contributed to the work equllly and should be regarded as co-first authors

1.Department of Orthopaedics Institute, Xiaoshan Traditional Chinese Medical Hospital，No.152 Yucai Road,XiaoShan District Hangzhou,311201,Zhejiang Province, China.

2.Department of Rheumatology and Immunology,The Third Affiliated Hospital of Zhejiang Chinese Medical University,No.219 Moganshan Road ,Xihu District Hangzhou 310005,Zhejiang Province,China.

3.Department of Medical Center of Fudan University,No.305 Fenglin Road,XuHui District Shanghai,200433,Shanghai City, China.

Corresponding Author：

Lei Han, MD, PhD, Department of Orthopaedics Institute,

Xiaoshan Traditional Chinese Medical Hospital, 152 Yucai Rd., Xiaoshan District, Hangzhou, Zhajiang Province, China 311201; e-mail: hallen505@163.com.

Mid-term results of bilateral synchronous total hip arthroplasty for bony ankylosis in patients with ankylosing spondylitis

Abstract

Background: Total hip arthroplasty (THA) for bony ankylosis is technically challenging in patients with ankylosing spondylitis (AS). This study aimed to determine the mid-term results of bilateral synchronous THA for bony ankylosis in patients with AS.

Methods: Nineteen cases of bony ankylosis in patients with AS who received bilateral synchronous THA were included in this study (17 males and 2 females, mean age 49.2 years). Disease duration was 5–38 years (mean 18 years and 6 months). All patients received cementless THA. Intraoperative blood loss, visual analogue scale (VAS) score, and complications were assessed. Harris hip scores evaluated the clinical effect.

Results: Patients were followed up for 62–98 months (mean 82.5 months). VAS score decreased from 7.42±0.92 to 2.42±0.83, Harris hip score improved from 21.8±7.2 to 80.3±6.5, and the flexion-extension range of the hip improved from 0° to 142.3±6.2°. One patient with septum bronchiale had a fracture intraoperatively and was treated with wire strapping. One patient had a traction injury of the femoral nerve postoperatively and recovered 1 year after the operation. Loosening and subsidence were not observed in all patients. Heterotopic bone formation was noted in 3 patients. No complications such as joint dislocation, acute infection, and deep vein thrombosis were found.

Conclusion： Bilateral synchronous THA was effective for bony ankylosis of the hip in patients with AS because it improved patients' quality of life, and had satisfactory mid-term outcomes.

Keywords: arthroplasty, replacement, hip, spondylitis, ankylosing spondylitis

Background

Ankylosing spondylitis (AS) is a chronic progressive autoimmune disease involving medial axis joints. It mainly includes the sacroiliac joint, spinal process, and soft tissues beside the spine and could cause spinal deformity and hip ankylosis [1]. Approximately 25% to 50% of patients with AS have hip involvement, and 50% to 90% of hip involvement is bilateral [2].

Recently, several studies within the clinical setting on the application of total hip arthroplasty (THA) for the treatment of hip ankylosis in AS patients have been reported. THA has been shown to be the most effective treatment method for hip joint ankylosis in patients with AS [3,4]. Moreover, THA could help AS patients with osseous ankylosis by reconstructing the anatomical structure of the hip joint, restoring hip joint function, and thus significantly improving their survival and quality of life.

Hip joint ankylosis could influence the extent of surgical exposure [5]. Contracture of muscle tissue and heterotopic ossification results in further trauma and difficulties during surgery, thereby limiting the choice of surgical approach [6]. In addition, the patient's mobility is limited after unilateral hip arthroplasty. In cases with bilateral involvement, the subsequent surgery could affect joint function recovery and the second administration of anesthesia could increase the risk of complications.

In this study, we retrospectively analyzed the data of AS patients with hip ankylosis treated by bilateral synchronous THA in our hospital, and we evaluated hip joint function

and postoperative complications. The purpose of this study was to discuss the surgical sequence of spinal osteotomy and hip replacement, and determine the mid-term results of bilateral synchronous THA for bony ankylosis in patients with AS.

Methods

All study participants provided informed consent. From January 2008 to January 2013, 19 patients (38 hips) with AS were treated with bilateral THA (17 males and 2 females). Patient ages ranged from 41 to 68 years (mean age 49.2 years), and the disease duration was 5–38 years (mean 18 years and 6 months). All patients had different degrees of ankylosis and dysfunction of the hip; 12 patients completely lost their self-care ability, 3 needed a walking device, and 4 required a walking stick. Ankylosis of the hip was defined by physical examination as a total loss of hip motion. Average angle of hip flexion deformity was 17.8° (fourteen hips 20–30°, sixteen hips 10–20°, eight hips <10°).Twelve patients had difficulty with horizontal vision due to severe spinal kyphosis and hip flexion. The preoperative visual analogue scale (VAS) [7] score was 7.42±0.92 and Harris hip score [8] was 21.8±7.2. Bilateral total hip replacement was performed simultaneously. Eight patients first completed the spinal osteotomy. All patients received uncemented THAs: ceramic-on-polyethylene (friction interface) was used in 3 patients (6 hips) and ceramic on ceramic in 16 patients (32 hips). Zimmer, Link, and Stryker prostheses were used in 10, 7, and 2 patients, respectively.

Perioperative preparation

99 Risk assessment was performed preoperatively according to the American Standards
100 Association to understand the patient's surgical tolerance. The general condition and
101 nutritional status, cardiopulmonary function, erythrocyte sedimentation rate, c-reactive
102 protein, X-ray, bone density, muscle strength, and the muscle and surrounding soft tissue
103 of the hips were evaluated; the anesthesia method, prosthesis type, and operation
104 sequence were determined accordingly. Measurements were performed using a special
105 template based on the patient's hip X-ray to determine the size, type, and position of the
106 implant during surgery. Immunosuppressive drugs were discontinued 2 weeks before the
107 surgery, and anti-inflammatory and analgesic drugs 1 week before the surgery to reduce
108 the incidence of postoperative gastrointestinal bleeding and infection. Prophylactic
109 antibiotics were administered 30 min before the surgery.
110
111 Surgical methods
112 *Surgical approach and exposure*
113 Bilateral sequential operations were performed under general anesthesia under the
114 guidance of a fiberoptic bronchoscope. The surgical areas were disinfected accordingly,
115 the patient was placed in the lateral position, and the incision was via the posterolateral
116 approach to fully expose the hip joint and release the soft tissue of the contracture.
117
118 *Osteotomy*
119 Osteotomy of the femoral neck was performed twice [5]. First, the osteotomy was
120 performed perpendicular to the femoral neck at 10 mm from the posterior acetabular wall.
121 Second, wedge osteotomy was performed; the base of the wedge osteotomy was 5 mm

(Figure 1a). During osteotomy, careful attention should be paid to the junction of the femoral neck and acetabulum. Homann hooks were placed in front and at the back of the femoral neck to protect the femoral artery and the adjacent sciatic nerve(Figure 1b). Osteotomy was near the acetabulum outer edge (15° front lean angle) to prevent posterior acetabular defects. In cases where the femoral neck was not completely cut off, fracture depth was gradually increased using a pendulum saw and bone knife under direct vision until the hip joint fusion statement was cut off.

Acetabular formation and acetabular prosthesis placement

Although the hip had bony fusion, there remained incomplete ossifying cartilage.at the location of the original joint plane. In some instances, intraoperative radiographs were taken to identify the original joint plane, which proved useful. The abduction and forward tilt of the acetabulum were adjusted according to the spinal and pelvic deformities. The position of the acetabulum could be identified based on the iliac ischium, iliac pubic branch, and the lower margin of the iliac crest. Moreover, osteoporosis is common in AS patients. In cases with acetabular defects due to acetabular hole, the femoral neck that was removed could be put at the bottom of the acetabulum after dressing or bone graft could be added to reconstruct the bottom of the acetabulum.

Organizational slack

During hip arthroplasty, the anterior soft tissues of the joint were released. The released tissues included iliopsoas, sartorius, and rectus femoris tendons, and sometimes adductor tendons. After completing the operation on one side, abduction and rotation of

145 the contralateral lower limbs were avoided to prevent joint dislocation. For those with
146 mild hip flexion, hip straightening was achieved immediately after the release (Figure 2a,
147 b). Soft tissue releases were performed in 11 patients (22 hips), including 6 (12 hips)
148 adductor releases and 5 (10 hips) iliopsoas releases.
149
150 Postoperative treatment
151 Postoperative negative pressure drainage was performed for 24–48 h, and
152 broad-spectrum antibiotics were routinely administered to prevent infection. Occurrence
153 of wound, swelling, and peripheral blood circulation were closely monitored, and
154 low-molecular-heparin calcium or rivaroxaban was administered to prevent deep vein
155 thrombosis during the perioperative period. For those who were taking hormones for
156 long-term, hormone therapy was allowed during the perioperative period. Oral
157 indomethacin 25 mg/day was administered postoperatively to prevent heterotopic
158 ossification. Isometric contraction of the lower limb muscles was performed 1 day
159 postoperatively. Standing exercise began on day 3 after the operation at the bedside, and
160 further exercise was performed with the help of double crutches at approximately 1 week
161 postoperatively. For those with severe osteoporosis, weight-bearing exercises were
162 delayed, and postoperative anti-osteoporosis treatment was continued.
163
164 Follow-up and evaluation of efficacy
165 The patients were followed up at 1, 3, and 6 months and once a year thereafter for the
166 clinical evaluation of their hip function and to assess their X-ray films. The patients'
167 X-ray films were sent to the examiners who were unable to come to the hospital, and the
168 examiners completed the functional evaluation by telephone.

169

170 Radiographic assessment

171 *Acetabular lateral stability assessment*

172 According to Kawamura [9], the assessment criteria for acetabular prosthesis loosening
173 are as follows: stable fixation, no displacement of acetabular prosthesis, and no line of
174 illumination; stable fiber fixation, no displacement of acetabular prosthesis, and presence
175 of light line <1 mm; suspected loosening, no displacement of acetabular prosthesis, and
176 presence of progressive, discontinuous light line >2 mm during follow-up; and definite
177 loosening, displacement of acetabular prosthesis, or the occurrence of >2-mm continuous
178 bright band or screw fracture.

179

180 *Joint prosthesis stability assessment*

181 Prosthesis fixation was evaluated based on a previous study [10]; the following were
182 assessed: bone growth stability (i.e., no subsidence, little or no hardening line formation
183 of the prosthesis, and stability of most of the bone-prosthesis interface); fiber fixation
184 stability (i.e., formation of a continuous bright band of no more than 1 mm around the
185 prosthesis parallel to the prosthesis handle, but no progressive subsidence and
186 displacement occurs); and prosthesis instability (i.e., progressive subsidence (≥2 mm)
187 with new (varus or porous) surface separation or prosthesis fracture occurs).

188

189 *Heterotopic ossification assessment*

190 The Brooker classification [11] was adopted for the imaging evaluation of heterotopic
191 ossification: grade I, 1 or 2 ossification areas with a diameter <1 cm; grade II, isolated

192 ossification or ossification at the end of the femur or the margin of the acetabulum,
193 covering less than half the distance between the femur and the hip; grade III, less than
194 half the distance between the femur and the hip bone without bone bridge formation; and
195 grade IV, bridge formation between the femur and the hip bone. Data collection and
196 evaluation were performed by independent examiners.
197
198 **Results**
199
200 General conditions of the operation
201 The operation time was 140–240 min (mean 180.8 min). The total amount of blood
202 loss was 1080–1880 ml (mean 1262.5 ml). The intraoperative autologous return was
203 500–750 ml (mean 650.6 ml). The amount of postoperative allogeneic blood transfused
204 was 500–1000 ml (mean 725.2 ml).
205
206 Clinical efficacy evaluation
207 The patients were followed up for 62–98 months (mean 82.5 months). The VAS score
208 decreased from 7.42±0.92 (preoperative) to 2.42±0.83 (postoperative) points (t=25.83,
209 P<0.001). Joint function based on Harris hip score improved (from 21.8±7.2 to 80.3±6.5)
210 (t=-73.50, P<0.001); among which 3 were excellent cases (6 hips) and 12 were good
211 cases (24 Hip), 3 were medium cases (6 hips), and the excellent and good rate was 78.9%.
212 The range of hip motion (sum of flexion, extension, adduction, abduction, internal
213 rotation, external rotation, etc.) increased from 0° to 142.3±6.2° (t=-71.42, P<0.001).
214 Four patients could walk with a single crutch, and the rest could walk unassisted. Six

patients underwent a second treatment with spinal osteotomy. Two patients had knee pain postoperatively, and the pain was relieved after total knee replacement.

Imaging evaluation of stability

Postoperative X-ray images showed that both the acetabulum and the femoral stem prosthesis had a good biological pressure coordination effect, and the femoral stem prosthesis was fixed at a neutral position or everted position. Acetabulum abduct angles were (40.2±10.2)° and the anteversion was (13.5±5.8)°. Radiographic images showed extensive bone growth on the surface of the prosthesis 6 months after the operation. The femoral stem prosthesis and bone interface were assessed as bone fixation according to the standards of Engh [10], and acetabular prosthesis was assessed as stable according to the standards of Kawamura [9] with no visible lines. Moreover, X-ray showed no subsidence of the femoral prosthesis at 1 year follow-up postoperation. Heterotopic ossification occurred in 3 cases (6 hips). According to Brooker classification, there were 2 cases (4 hips) in grade I and 1 cases (2 hips) in grade II.

Complications

Intraoperative femoral neck osteotomy was successfully completed. Two patients developed hypoproteinemia and occurred incision seepage at postoperative days 2 and 3. After multiple dressing changes and albumin supplementation, the incision was healed. A patient with a flexion deformity >60° had femoral nerve traction injury after surgery but recovered a year thereafter. One patient had femoral condyle fracture; weight bearing was delayed, and bone healing was noted at 8 weeks after surgery. No complications, such as

238 joint dislocation, acute infection, or deep vein thrombosis of the lower extremities,
239 occurred.
240
241 **Discussion**
242
243 In this study, bilateral THA was performed first in 11 patients, and 5 patients did not
244 undergo spinal osteotomy because they could meet daily activities. In addition, 6 patients
245 who underwent spinal osteotomy showed improvement in gait and maintained an
246 effective range of hip joint motion.
247
248 Studies have shown that THA is the best treatment method for advanced hip bony
249 ankylosis in patients with AS. Bilateral synchronous hip replacement for hip ankylosis in
250 patients with AS, shortens the length of hospital stays and avoids the risks of multiple
251 operations and anesthesia. Moreover, rehabilitation could be performed simultaneously,
252 which in turn reduces the incidence of complications and maximizes recovery of function.
253 The incidence of complications after bilateral THA is much lower than that after
254 two-stage replacements [12]. However, AS is often accompanied by spine or pelvic
255 deformity, severe osteoporosis, and tissue contracture. Thus, a bilateral simultaneous
256 operation is extremely difficult to perform in patients with AS and has higher
257 requirements for operation sequence, surgical operation, and postoperative rehabilitation.
258
259 Currently, there is no definite surgical sequence for kyphosis or hip ankylosis in
260 patients with AS[13]. The operation sequence is not important in cases with mild flexion

261 deformity of the hip joint. For those with severe flexion deformity of the hip, THA could
262 be performed first as the hip joint could partly compensate for the kyphosis and the
263 placement of the body position can make it easier to determine the kyphosis angle, which
264 is beneficial for the further precise spinal osteotomy[5, 14]. In addition, shear strength of
265 the spine in the standing position is minimal, and the incidence of spondylolisthesis and
266 kyphosis recurrence is reduced . Other scholars believe that the first spinal surgery could
267 affect the range of hip joint movement, avoid the wrong direction of prosthesis placement,
268 and reduce the incidence of hip dislocation [15]. Nevertheless, the best surgical plan is that
269 which considers both the spine and the hip joints. Moreover, surgery should follow the
270 following principles:

271 (1) The spine surgeon determines the direction of the trunk axis that is changed by
272 spinal osteotomy, and the joint surgeon determines the range of motion of the hip after
273 THA; the two coordinate with each other to match the effective range of motion of the
274 hip to the new trunk axis.
275 (2) Based on the information in (1), THA is performed first followed by spinal
276 osteotomy. The acetabular prosthesis should be placed according to the functional
277 position and conforming to the direction of the trunk axis that was changed by spinal
278 osteotomy.

279 (3) Postoperative exercise can not only be satisfied with being able to sit, but also for
280 different degrees of squatting, to ensure that there is enough space for the spinal
281 osteotomy.

282 (4) After 3 months of stable hip function, spinal osteotomy orthopedic surgery should
283 be performed. Hip range of motion should be evaluated again before surgery to determine

284 the extent of spinal osteotomy.

285

286 Accurate placement of the acetabular component is one of the difficulties in AS
287 patients with hip bony ankylosis. Generally, the foveal soft tissue can be identified in the
288 location of the original joint plane [5]. The pelvis has three bony landmarks that determine
289 the guide and accurate placement of the acetabular cup [16]. In this study, these landmarks
290 were used during the operation and the postoperative acetabular cup position was
291 satisfactory and no dislocation occurred. In addition, intraoperative fluoroscopy could be
292 useful for identifying the exact location of the acetabulum [5,17]. Since kyphosis is often
293 present in AS, pelvic posterior tilt compensation mechanism should be considered in the
294 placement of acetabulum during the operation. If the acetabulum is tilted forward and the
295 abduction angle is normal, the pelvis should be tilted backward when the patient is
296 standing to increase the anteversion and abduction angles of the acetabular prosthesis.
297 Hence, the anteversion and abduction angles of the acetabulum should be reduced during
298 the operation to offset the anteversion and abduction angles resulting from pelvic recline;
299 however, pelvic recline decreases or disappears after spinal orthopedic surgery [18,19],
300 and the original suitable acetabular abduction and anteversion angles are extremely small,
301 which could in turn result in complications such as frontal impact and limited hip flexion.
302 Subsequent spinal osteotomy reduces partial motion of hip flexion after THA. The
303 acetabulum should be placed according to the functional position of the trunk after spinal
304 orthosis. For the functional exercise after THA, hip flexion range of motion should be
305 monitored closely, and excessive extension should be avoided. Correction surgery for
306 kyphosis could make up for the lack of straightening.

Osteoporosis not only increases the difficulty of surgery but also affects the stability of the prosthesis. Although cemented prosthesis has good early stability, it is more difficult for revision. Nevertheless, restoring joint function and resumption of weight bearing could improve osteoporosis. Thus, if the bone condition permits, the cementless prothesis should be selected as far as possible for revision THA later. During follow-up, no patients in this study experienced loosening of the prosthesis due to osteoporosis.
Moreover, because of the gradual recovery of joint function, the bone density of the acetabulum and femur gradually increased, and the postoperative biological bone ingrowth was satisfactory. For the chimney-shaped medullary cavity, we used a tapered femoral stem, and a sagittal three-point fixation in the chimney-shaped wide medullary cavity was achieved using a longer shank, which is beneficial to the initial stability of the prosthesis, the double-sided tapered design can obtain a secondary sinking to make the handle body firmer and facilitate the growth of the proximal bone.

Heterotopic ossification is an important factor affecting joint mobility in patients with AS after total hip arthroplasty [20,21]. The incidence of heterotopic ossification in patients with AS after THA treatment is as high as 40%–76% [22]. Severity of heterotopic ossification complications varies, and severe cases are often prone to joint function alterations and can affects postoperative outcomes. Intraoperative osteotomy, organization of hematoma, soft tissue injury, and residual bone debris could influence the formation of heterotopic ossification [23]. In this study, repeated washing with a large amount of normal saline was performed during operation to completely remove the

330 residual bone and minimize the damage to soft tissues around the hip. After routine oral
331 administration of indomethacin (25 mg/day) for 15 days, heterotopic ossification was
332 effectively reduced postoperatively. Mild heterotopic ossification was noted in 3 patients
333 (6 hips) (Brooke I and II), and hip activity was not affected. The postoperative irradiation
334 is effective in preventing the occurrence of heterotopic ossification after THA in patients
335 with AS [24].
336
337 Most of the patients remain in bed for a long time; thus, their muscles could undergo
338 severe atrophy. Hence, a practical rehabilitation plan is needed after the operation that
339 includes passive and active range of motion, physical exercise, muscle and joint
340 coordination exercise, and normal gait practice. Passive activity could increase the
341 stretchability of the soft tissue around the joint, thereby increasing the coordination of
342 movements in active range of motion. Therefore, early postoperative rehabilitation
343 exercises require both passive and active range of motion but within a safe range.
344 However, for patients with severe flexion deformity before surgery, excessive passive
345 extension of the hip joint must be avoided to prevent nerve and blood vessel traction
346 injury. This study of patients with mild hip flexion obtained straight hips immediately
347 postoperation. The hip can be stretched straight by functional exercise after 3 days for the
348 seriously flexed hips.
349
350 Although the short-term outcome after THA in patients with AS is satisfactory, the
351 mid- and long-term results vary [25]. In the early stage, because of osteoporosis, loosening
352 and displacement of the prosthesis after surgery are highly possible.The longer the course

353 of AS, the more severe the hip joint involvement and the slower the recovery after
354 surgery; moreover, the recovery was relatively poor. In addition, the longer the course of
355 AS, the more severe the deformity of the hip joint, the ankylosis, the atrophy of the
356 muscle, and even the fibrosis, which could in turn result in operation difficulties,
357 operation trauma, and prolonged operation time and could directly affect recovery speed
358 and postoperative satisfaction. In this study, we found that the bilateral hip joints
359 improved, and early rehabilitation exercises could be performed. Moreover, postoperative
360 synchronous rehabilitation exercises were performed to improve operative outcomes.
361

362 **Conclusion**

363 THA is an effective treatment method for hip ankylosis in patients with AS and thus
364 could improve the hip joint function and the quality of life. Bilateral synchronous THA
365 shortens the time of hospitalization, reduces the risk of anesthesia and relieves patients'
366 cost burden. The mid-term results of bilateral synchronous THA are satisfactory. This
367 study lacks a control group, and needs a multi-center, large sample study to confirm its
368 exact effect.
369

370 **Abbreviations:**

371 Ankylosing spondylitis (AS), Total hip arthroplasty (THA), Visual analogue scale
372 (VAS)

Declarations

Ethics approval and consent to participate

This study was conducted in accordance with the Declaration of Helsinki. This study was conducted with approval from the Ethics Committee of Xiaoshan District Hospital of TCM. Written informed consent was obtained from all participants.

Consent for Publication

Written informed consent was obtained from all participants.

Availability of data and material

This data will not be shared, because in recent years, although many scholars have explored this in various aspects, its pathological mechanism remains unclear and there are no standard diagnostic criteria. In order to determine the effective method for preventing and treating this disease, it is necessary to proceed with more large-scale and clinical studies.

Competing interests

The authors declare that they have no competing interests. There is no funding source.

Funding

There is no funding source.

Authors' contributions

HL and LJJ were accountable for the integrity and analysis of the data, and the writing

of the manuscript. ZLP and CGP was accountable for the integrity and analysis of the data. HYG was accountable for the analysis of the data. QRF was accountable for the conception of the research. All authors read and approved the final manuscript.

Acknowledgements

The authors would like to thank all participating patients, as well as the study nurses, co-investigators, and colleagues who made this trial possible.

References

[1] S.E. Putnis,G.K.Wartemberg, W.S. Khan,S.Agarwal (2015) A literature review of total hip arthroplasty in patients with ankylosing spondylitis: perioperative considerations and outcome.The Open Orthopaedics Journal 9, (Suppl 2: M5) 483-488

[2] Ulucay C, Ozler T, Güven M, Akman B, Kocadal AO, Altıntas F (2013) Etiology of coxarthrosis in patients with total hip replacement. Acta Orthop Traumatol Turc 47:330e333

[3] Xu J, Zeng M, Xie J, Wen T, Hu YH (2017) Cementless total hip arthroplasty in patients with ankylosing spondylitis A retrospective observational study. Medicine 96(4):e5813

[4] Chuan Y, Riguang L, Changying S, Jianhao L, Hu Li, Houxiang R, Bo S, Qi S, Long Y (2014) Cementless bilateral synchronous total hip arthroplasty in ankylosing spondylitis with hip ankylosis. Int Orthop,38:2473–2476

[5] He BJ, Tong PJ, Li J (2012) Bilateral synchronous total hip arthroplasty for ankylosed hips. Int Orthop 36:697–701

[6] Jian L,Zhiwei W, Ming L, Yuesong W, Weidong X, Zimin W (2013) Total hip arthroplasty using a combined anterior and posterior approach via a lateral incision in patients with ankylosed hips. Can J Surg 56(5):332-340.

[7] Jensen MP, Karoly P, Braver S (1986) The measurement of clinical pain intensity: a comparison of six methods.Pain 27(1): 117-126.

[8] Harris WH (1969) Traumatic arthritis of the hip after dislocation and acetabular fractures:treatment by mold arthroplasty.An end-resuhstudy using a new method of result evaluation.J Bone Joint Surg (Am) 51(4):737-755.

[9] Latimer HA,Lachiewicz PF (1996) Porous-coated acetabular components with screw fixation.Five to ten year results.J Bone Joint Surg(Am) 78(7):975-981

[10] Engh CA,Massin P,Suthers KE (1990) Roentgenographic assessment of the biologic fixation of porous-surfaced femoral components.Clin Orthop Relat Res 257:107-128.

[11] Brooker AF, Bowerman JW, Robinson RA, Riley LH (1973) Ectopic ossification following total hip replacement Incidence and a method of classification.J Bone Joint Surg(Am) 55:1629-1632.

[12] Trojani C, d'Ollonne T, Saragaglia D, Vielpeau C, Carles M, Prudhon JL (2012) One-stage bilateral total hip arthroplasty: functional outcomes and complications in 112 patients.Orthop Traumatol Surg Res 98(6 Suppl):S120-3

[13] Zeng Y,He R,Li Q,Shi H,Ma H (2014) Spinal wedged osteotomy combined with total hip arthroplasty for kyphosis and severe hip flextion contracture caused by ankylosing spondylitis.Chinese Journal of Reparative and Reconstructive Surgery28(8): 942-6.

[14] Guan M, Wang J, Zhao L,Xiao J, Li Z, Shi Z (2013) Management of hip involvement in ankylosing spondylitis. Clin Rheumatol 32(8): 1115-1120.

[15] Zheng GQ,Zhang YG,Chen JY,Wang Y (2014) Decision making regarding spinal osteotomy and total hip replacement for ankylosing spondylitis:experience with 28 patients.Bone Joint J 96-B(3):360-365

[16] Sotereanos NG,Mil|er MC,Smith B, Hube R, Sewecke JJ, Wohlrab D (2006) Using intraoperative pelvic landmarks for aeetabular component placement in total hip arthmplasty. J Arthroplasty 21(6):832-840

[17] Feng DX,Zhang K,Zhang YM,Nian YW,Zhang J,Kang XM,Wu SF,Zhu Yj (2016) Bilaterally primary cementless total hip arthroplasty for severe hip ankylosis with ankylosing spondylitis. Orthopaedic Surgery 8:352-359

[18] Song K,Zheng G,Zhang Y, Cui G, Zhang X, Mao K, Wang Y (2014) Hilus pulmonis as the center of gravity for AS thoraeolumbar kyphosis.Eur Spine J 23(12): 2743-2750

[19] Song K,Zheng G,Zhang Y, Zhang X, Mao K, Wang Y (2013) A new method for calculating the exact angle required for spinal osteotomy.Spine 38(10):E616-620

[20] Tippets DM, Zaryanov AV, Burke WV, Patel PD, Suarez JC, Ely EE, Figueroa NM (2014) Incidence of heterotopic ossification in direct anterior total hip arthroplasty: a retrospective radiographic review.J Arthroplasty 29(9):1835-1838

[21] Beckmann JT, Wylie JD, Potter MQ, Maak TG, Greene TH, Aoki SK (2015) Effect of naproxen prophylaxis on heterotopic ossification following hip arthroscopy: A double-blind randomized placebo-controlled trial. J Bone Joint Surg Am (24): 2032-2037

[22] Bhan S, Eachempati KK, Malhotra R (2008) Primary cementless total hip arthroplasty for bony ankylosis in patients with ankylosing spondylitis. J Arthoplasty 23(6): 859-866

[23] Thilak J, Panakkal JJ, Kim TY, Goodman SM, Lee SS, Salvati EA (2015) Risk factors of heterotopic ossification following total hip arthroplasty in patients with ankylosing spondylitis.J Arthroplasty 30(12):2304-7

[24] Weng HK, Wu PK, Chen CF, Chung LH,Liu CL,Chen TH,Chen WM (2015) Total hip arthroplasty for patients who have ankylosing spondylitis: Is postoperative irradiation required for prophylaxis of heterotopic ossification? J Arthroplasty 30(10): 1752-6

[25] Guo HZ,Yang CX,Tang ZP,Wang CX (2019) The effects of total hip arthroplasty in treating hip bony fusion in young and middle-aged patients with ankylosing spondylitis.J Orthop Surg Res 14(1):253-259

487 **Figure Legends**

488 **Fig1a-3d**

489 **Fig.1a** Delineation of two-step system:Osteotomy perpendicular to femoral neck 10
490 mm from the posterior wall of acetabulum（a）；Next, wedge osteotomy was performed.
491 （b），The bottom edge of wedge osteotomy is 5 mm（c）.

492 **Fig.1b** Homann hooks were placed in front and rear of femoral neck, and osteotomy
493 was performed at the junction of femoral neck and acetabulum.

494

495 **Fig2a.** The perioperative photo showed that the patient flexion deformity bilateral hips
496 were over 45°.

497 **Fig2b.**The Postoperative photo showed that the hip straightening was achieved
498 immediately.

499

500 **Fig.3a-3b** Three-dimensional reconstruction showing AS with hip flexion ankylosis
501 and kyphosis deformity.

502 **Fig.3c** The radiographs showing bilateral bony ankylosis with 0° range of motion.

503 **Fig.3d** Postoperative radiograph of the patient 5 years after cementless THA.

504

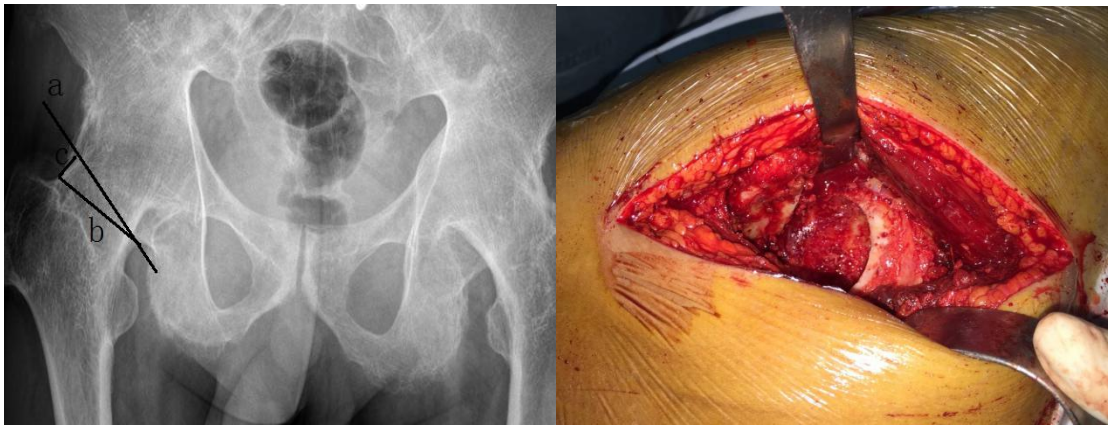

505

506

507

508

509 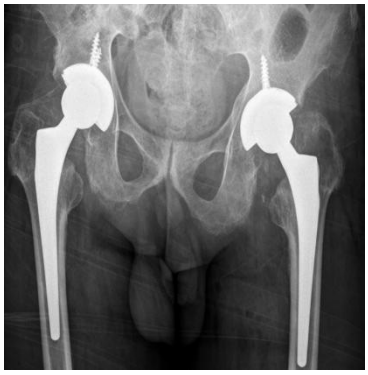

Figures

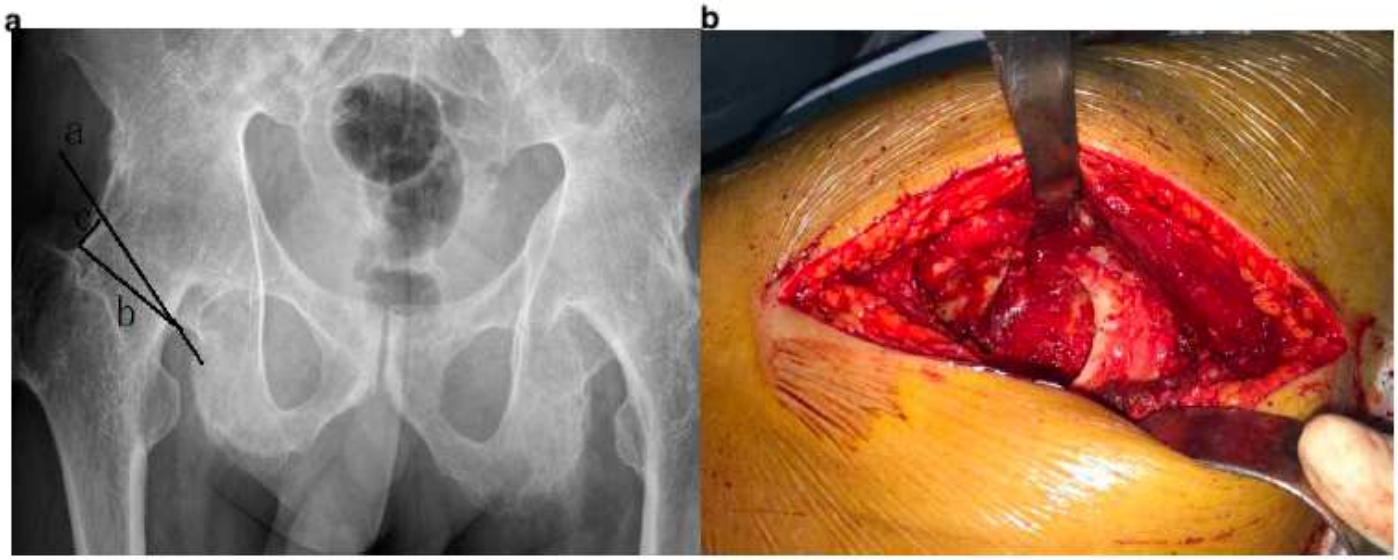

Figure 1

a. Delineation of two-step system:Osteotomy perpendicular to femoral neck 10 mm from the posterior wall of acetabulum a) Next, wedge osteotomy was performed. b) The bottom edge of wedge osteotomy is 5 mm c). b. Homann hooks were placed in front and rear of femoral neck, and osteotomy was performed at the junction of femoral neck and acetabulum.

Figure 2

a. The perioperative photo showed that the patient flexion deformity bilateral hips were over 45°. b. The Postoperative photo showed that the hip straightening was achieved immediately.

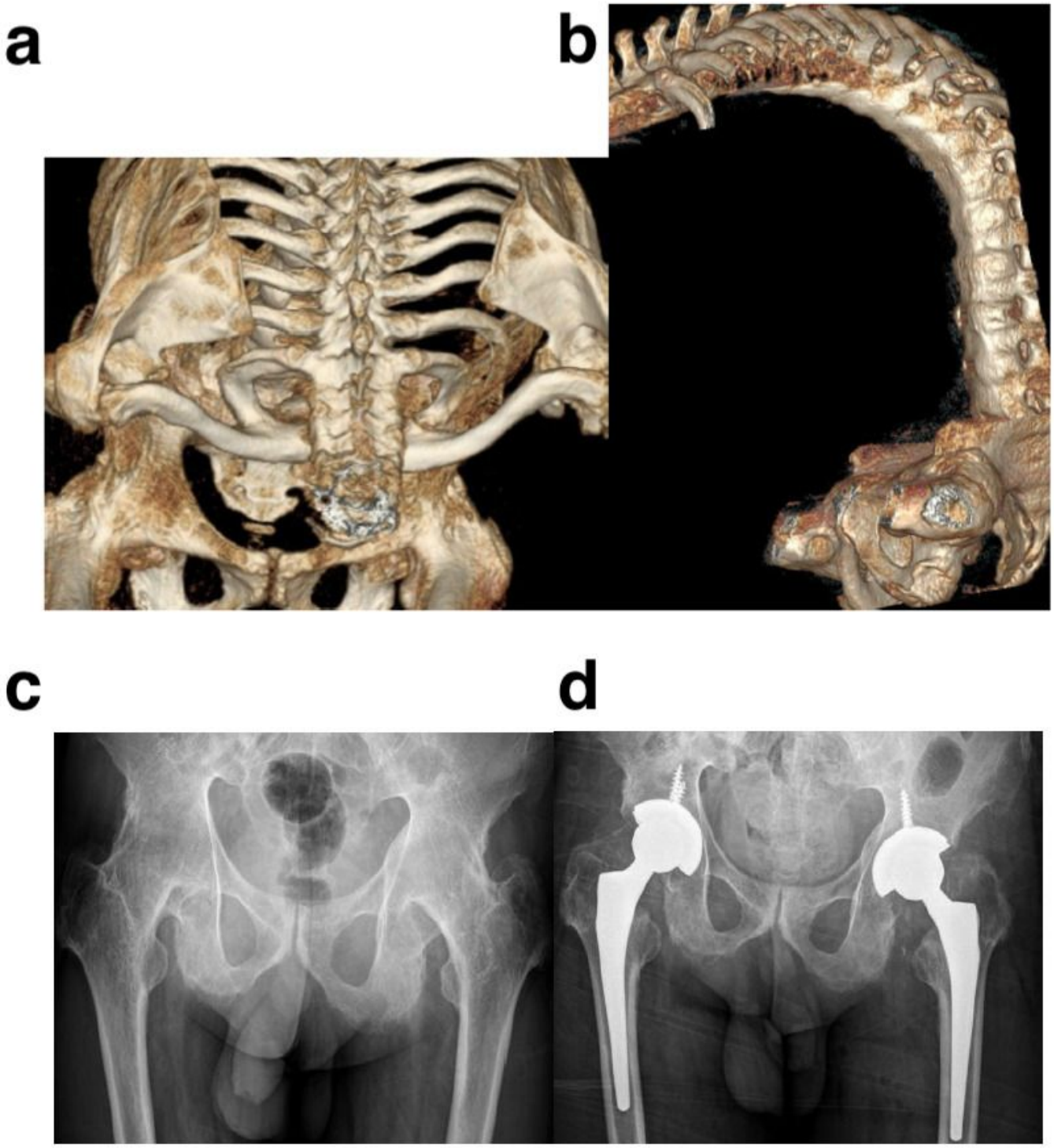

Figure 3

a-b. Three-dimensional reconstruction showing AS with hip flexion ankylosis and kyphosis deformity. c. The radiographs showing bilateral bony ankylosis with 0°range of motion. d. Postoperative radiograph of the patient 5 years after cementless THA.