Detection of angiolipoma nuclei in H&E staining image by tissue segmentation using tissue filters

Mahyar Radak (m_radak@physics.iust.ac.ir)

1. Department Physics Iran University of Science and Technology, Tehran https://orcid.org/0000-0002-9655-8396

Research Article

Keywords: angiolipoma, HE stains, algorithms, tissue, angiolipoma nuclei

Posted Date: March 28th, 2022

DOI: https://doi.org/10.21203/rs.3.rs-1489230/v1

Detection of angiolipoma nuclei in H&E staining image by tissue segmentation using tissue filters

Mahyar Radak[1*]

1. Department Physics Iran University of Science and Technology, Tehran

- Responsible author: m_radak@physics.iust.ac.ir

ABSTRACT

Angiolipoma is an unusually benign neoplasm composed of mature lipocytes mixed with abnormal blood vessels. In this paper, we used cellular tissue segmentation using an intelligent tissue filtering algorithm to identify tissue-based image regions containing thick-walled capillaries with fibrin clots, between mature lipocytes and fibrin septum, and HE angiolipoma stains. Our algorithm was able to detect and extract angiolipoma tissue nuclei. The image in question is 591 X 800 pixels, which is stained with HE, which we use to detect. There are many algorithms, techniques and applications for dividing the nucleus of a tissue tumor, but in the proposed algorithm method, it can be extracted with high accuracy and sensitivity. This method can also be used to detect other angiolipoma tissue nuclei stained with HE variable stains.

Keywords: angiolipoma, HE stains, algorithms, tissue, angiolipoma nuclei

INTRODUCTION

For diagnosis, hematoxylin and eosin (H&E) are commonly used by pathologists to view details of tissue structure. Because this color represents a wide range of cytoplasmic, nuclear, and extracellular matrix properties, almost all educational texts use H&E images [1], [2], [3]. Hematoxylin and eosin staining [4] principally stains the nuclei of cells blue or dark-purple [5],[6],[7] along with a few other tissues, such as keratohyalin granules and calcified material. Eosin stains the cytoplasm and some other structures including extracellular matrix such as collagen [8],[9],[7] in up to five shades of pink [10]. The eosinophilic [8] structures are generally composed of intracellular or extracellular proteins. The Lewy bodies and Mallory bodies are examples of eosinophilic structures. Most of the cytoplasm is eosinophilic and is rendered pink [11][6]. Red blood cells are stained. Angiolipomas (also sometimes referred to as hemangiolipomas, vascular lipomas, and fibromyolipomas) are rare soft-tissue tumors made up of mature fat cells and blood vessels. They can occur virtually anywhere and can be classified into intrusive and non-intrusive types [12]. Angiolipomas differ from lipomas in that more blood vessels pass through and are more likely to be painful [13]. incidence of angiolipoma is 5 to 17%

of all lipomas [14],[15]. Patients are between 16 and 58 years old, with a mean age of 24 years, and are mostly male [14]. Chest wall angiolipoma is very rare [16], [17], [18].

MATERIALS AND METHODS

In this paper, we use an image of tissue angiolipoma labeled with HE. Each image of angiolipoma with these features can be examined with our algorithm.

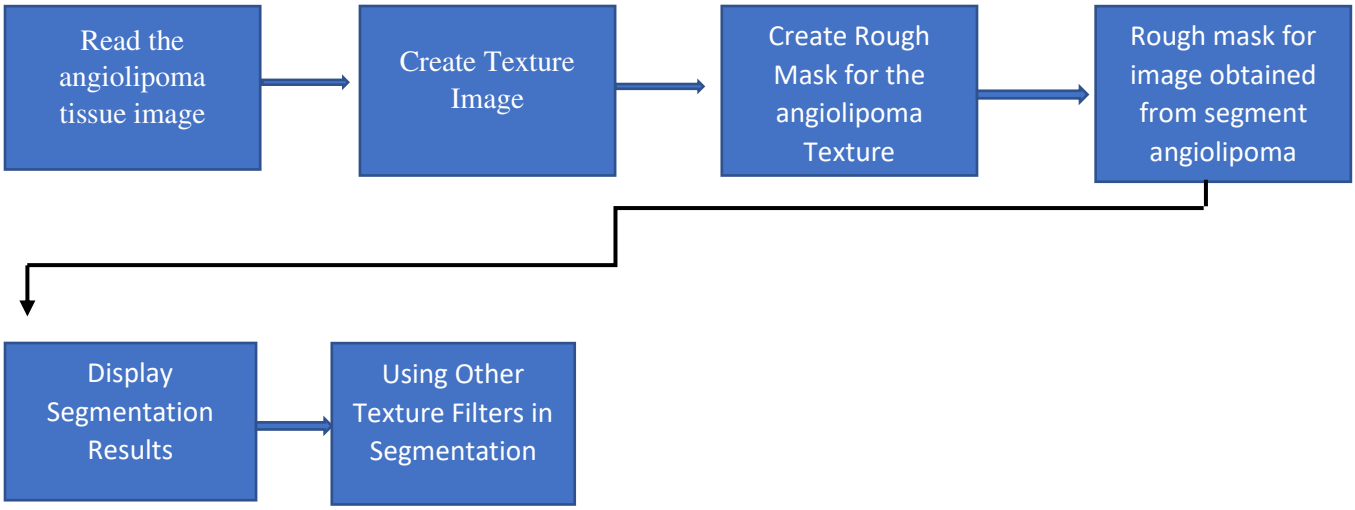

Figure 1. System flowchart of angiolipoma nuclei tissue detection

RESULTS AND DISCUSSIONS

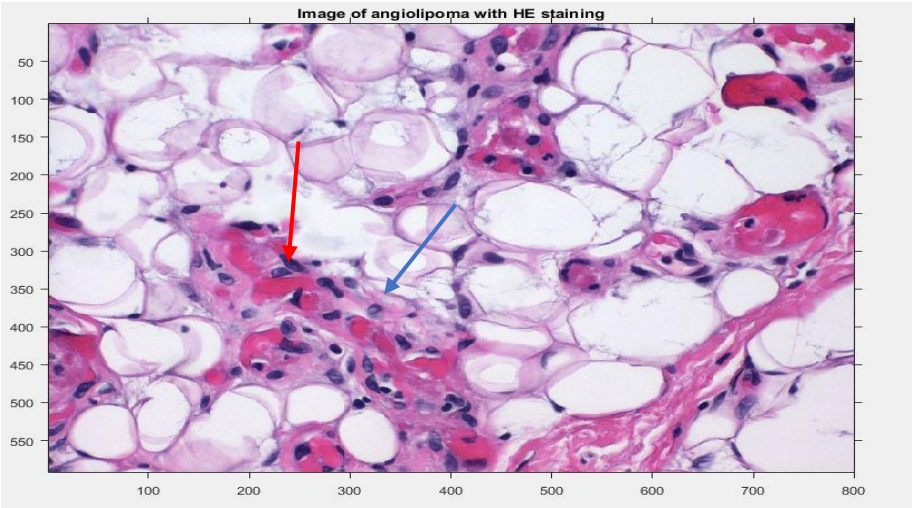

Figure 2. Histopathology of angiolipoma, high magnification, showing thick-walled capillaries with fibrin thrombi, among mature lipocytes and fibrin septa. HE stain [19]. Glomerulus (red

arrow) and tubules (blue arrow) displayed using H&E. The nuclei are stained purple, while the cytoplasmic components are pink.



Figure 3. Resize the image and return the image array using the entropy statistical function

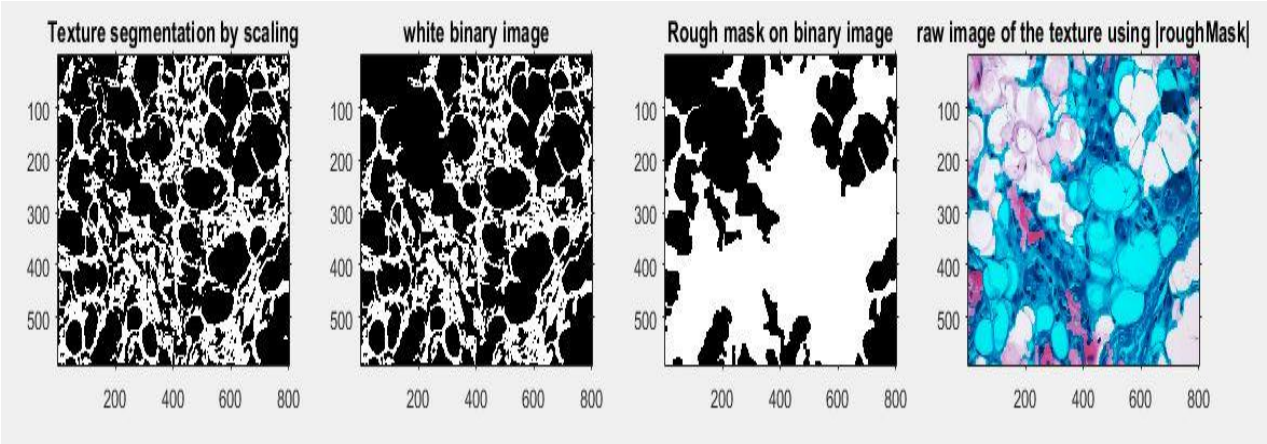

A **B** **C** **D**

Figure 4. A) In the first image, we have placed the statistically scaled image on the threshold to segment the textures. The threshold value of 0.8 has been selected because it is approximately the value of the pixel intensity along the boundary between the textures. **B)** We obtained the split objects in image A as a binary image. **C)** We used an algorithm to smooth the edges and close any

open holes in the object in the binary, and a 9 X 9 neighborhood was selected. **D)** We used the algorithm to fill the holes in the object in Figure C and the rough mask to split the texture.

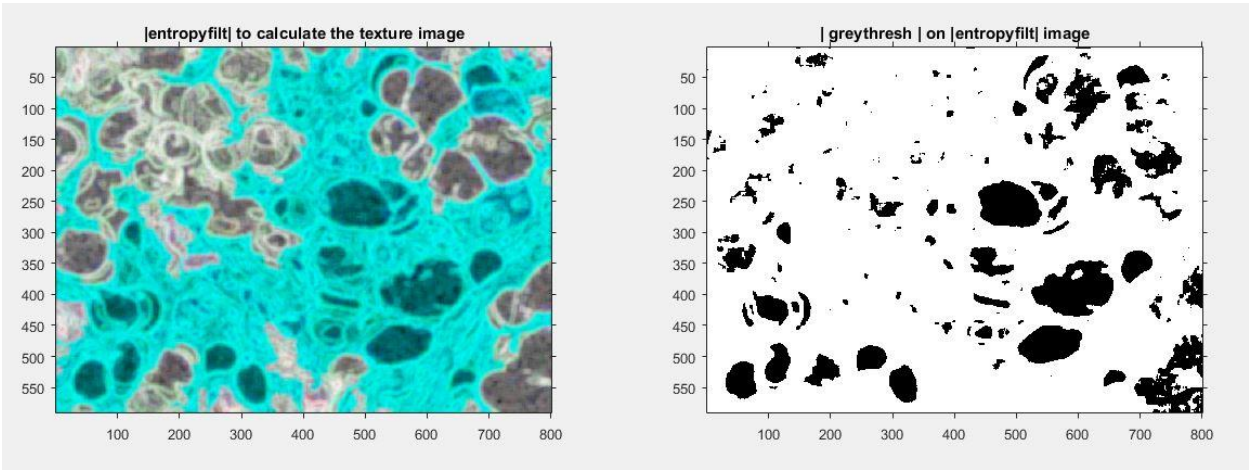

A B

Figure 5. A) We applied the | entropyfilt | algorithm to calculate the texture image on the previous part D image. **B)** Image threshold A with algorithm | greythresh | it shows.

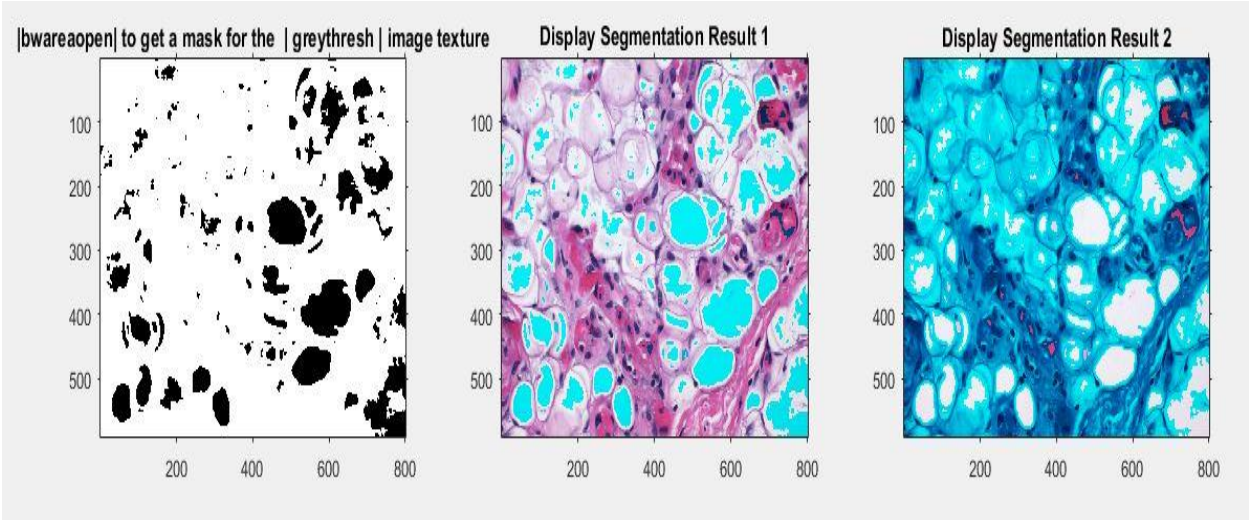

A B C

Figure 6. Using the algorithm | mask2 | For extraction of the upper and lower tissue of Figure 2, results B and C are obtained.

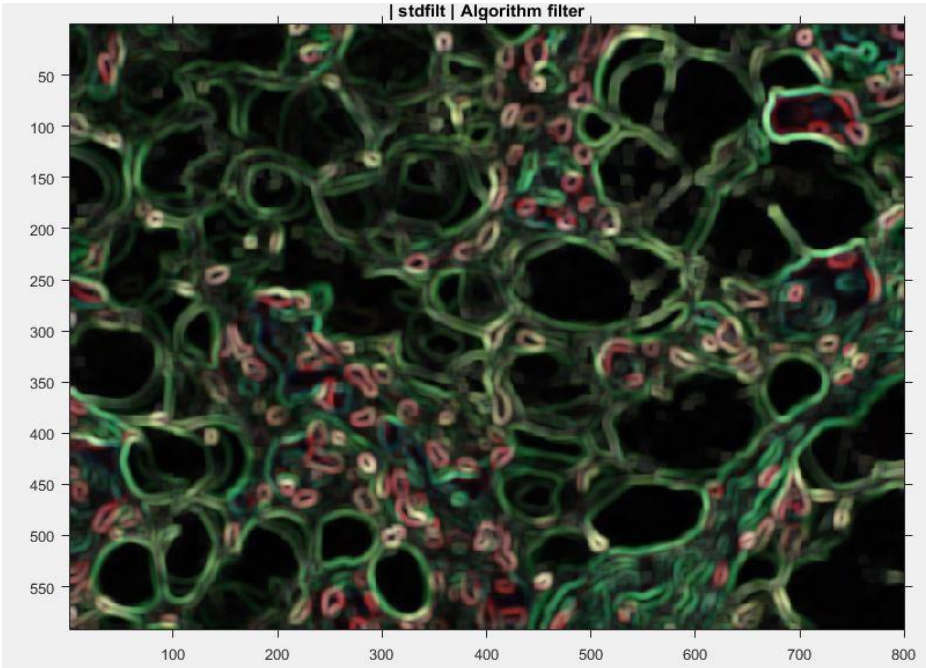

Figure 7. Use the filter stdfilt | The segmented image shows the result of detecting the nucleus of the angiolipoma in red and the cytoplasmic tissue in green.



Figure 8. The resulting image has little noise and low quality with | rangefilt | filtered for better quality detection and extraction.

CONCLUSIONS

Angiolipoma is a type of lipoma. They are slightly stiffer than lipomas, contain more blood vessels, and are more likely to be painful. In this paper, we used the tissue segmentation algorithm to detect and segment the HE stained image of the tissue of an angiolipoma. We were able to segment and differentiate the nucleus and cytoplasm of angiolipoma tissue and to image tissue nuclei with distinct colors.

ACKNOWLEDGEMENT

Simulations and algorithms were implemented in MATLAB software.

Competing interests

There is NO Competing Interest.

REFERENCES

[1] Titford, M. (2005). "The long history of hematoxylin". Biotechnic & Histochemistry. 80 (2): 73–80.

[2] Smith C (2006). "Our debt to the logwood tree: the history of hematoxylin". *MLO Med Lab Obs*. **38** (5): 18, 20–2. PMID 16761865

[3] Dapson RW, Horobin RW (2009). "Dyes from a twenty-first century perspective". *Biotech Histochem*. **84** (4): 1357. doi:10.1080/10520290902908802. PMID 19384743. S2CID 28563610.

[4] Llewellyn BD (2009) Nuclear staining with alum-hematoxylin. Biotech. Histochem. 84: 159–177.

[5] Stevens, Alan (1982). "The Haematoxylins". In Bancroft, John; Stevens, Alan (eds.). The Theory and Practice of Histological Techniques (2nd ed.). Longman Group Limited. p. 109.

[6] Leeson, Thomas S.; Leeson, C. Roland (1981). Histology (Fourth ed.). W. B. Saunders Company. p. 600. ISBN 978-0721657042.

[7] Kiernan JA (2018). "Does progressive nuclear staining with hemalum (alum hematoxylin) involve DNA, and what is the nature of the dye-chromatin complex?". Biotech Histochem. **93** (2): 133–148. doi:10.1080/10520295.2017.1399466. PMID 29320873. S2CID 13481905.

[8] Chan JK (2014). "The wonderful colors of the hematoxylin-eosin stain in diagnostic surgical pathology". IntJSurgPathol. **22** (1):1232. doi:10.1177/1066896913517939. PMID 24406626. S2CID 26847314.

[9] Wittekind D (2003). "Traditional staining for routine diagnostic pathology including the role of tannic acid. 1. Value and limitations of the hematoxylin-eosin stain". Biotech Histochem. **78** (5):26170. doi:10.1080/10520290310001633725. PMID 14989644. S2CID 10563849.

[10] Titford, Michael (2009). "Progress in the Development of Microscopical Techniques for Diagnostic Pathology". Journal of Histotechnology. 32 (1): 9–19. doi:10.1179/his.2009.32.1.9. ISSN 0147-8885. S2CID 26801839.

[11] Ross, Michael H.; Pawlina, Wojciech (2016). Histology : a text and atlas : with correlated cell and molecular biology (7th ed.). Wolters Kluwer. pp. 984p. ISBN 978-1451187427.

[12] Finberg HJ, Levin DC. Angiolipoma: a rare benign soft tissue tumor with a malignant arteriographic appearance. AJR Am J Roentgenol. 1977;128 (4): 697-8. doi:10.2214/ajr.128.4.697 - Pubmed citation

[13] Medically reviewed by Elaine K. Luo, M.D. — Written by Rachel Nall, MSN, CRNA on May 16, 2018.

[14] Howard WR, Helwig EB. Angiolipoma. Arch Dermatol. 1960;82:924–31.

[15] Lin JJ, Lin F. Two entities in angiolipoma: a study of 459 cases oflipoma with review of literature on infiltrating angiolipoma. Cancer.1974;34:720–7.

[16] Biondetti PR, Fiore D, Perin B, Ravasini R. Infiltrative angiolipoma of thethoracoabdominal wall. J Comput Assist Tomogr. 1982;6:847.

[17] eviri E, Levinsky L, Shaklai M, Lavie G, Levy MJ. Total excision of a giantangiolipoma of chest wall with A-V malformation and with the use of anautotransfusion system. J Cardiovasc Surg. 1987;28:546–8 (3) (PDF) Angiolipoma of the chest wall: a case report. Available from: https://www.researchgate.net/publication/358767269_Angiolipoma_of_the_chest_wall_a_case_report [accessed Mar 25 2022].

[18] Mayooran N, Tarazi M, O'Brien O, Hinchion J. Infiltrating angiolipoma ofthe chest wall: a rare clinical entity. J Surg Case Rep. 2016;1:1–3.

[19] Mikael Häggström,. (9 September 2020). "Histopathology of angiolipoma.jpg". https://upload.wikimedia.org/wikipedia/commons/thumb/4/44/Histopathology_of_angiolipoma.jpg/800px-Histopathology_of_angiolipoma.jpg?20200909203948

Supplementary Files

This is a list of supplementary files associated with this preprint. Click to download.

- Angiolipomatexturesegmentationusingtexturefilters.docx