Acetabular defects reconstruction with tantalum constructions.

Artak Galstyan (a_galstyan2003@yahoo.com)
Yerevan State Medical University Named after Mkhitar Heratsi https://orcid.org/0000-0002-5030-1405
Yulin Wu
The Second Military Medical University, Shanghai, China
Peiliang Fu
The Second Military Medical University, Shanghai, China

Research article

Keywords: acetabular defect, hip replacement, Paprosky classification, AAOS classification, tantalum construction

Posted Date: February 25th, 2020

DOI: https://doi.org/10.21203/rs.2.24406/v1

Abstract

Background Total hip replacement (THR) is a common procedure that is performed increasingly often. Although most patients have satisfactory long-term stability, approximately 17% of prosthetic hips fail, thus requiring revision. Frequently, when hip prosthesis revision is undertaken, there is significant acetabular bone deficiency present; this clinical setting presents one of the most challenging circumstances in hip surgery. There is a variety of surgical hardware and strategies available to address this problem. Preoperative planning is a critical aspect of any reconstructive hip surgery but is particularly important in revision surgery. The surgeon must anticipate instrument, bone graft, and implant requirements for the surgery, as well as which reconstructive options may be needed, based on what may be found intraoperatively. The purpose of this study was to evaluate early functional results of hip arthroplasty with acetabular defects, pelvic bone loss revised with porous tantalum acetabular components.

Methods 56 patients were operated during research period with different kind of acetabular defects. W.G. Paprosky classification was used to classify existing acetabular defect. From 56 patients 26 was primary hip replacement and 30 – revision.

Results Different kind of tantalum constructions were used to reconstruct acetabular defects during replacement surgery. During research period three patient had complications: two cases of dislocation after revision replacement (3,6%) and one – after primary replacement (1,8%), one suppuration case (1,8%).

Conclusions According research results possible to make conclusion: using tantalum augments during acetabular region reconstruction allow to avoid non-biological fixators – support rings and structural grafts; tantalum augments are successfully applicable during all kinds of acetabular defects reconstruction, in primary and revision replacement; using tantalum augments during acetabular region reconstruction allow to achieve components stable primary fixation.

Introduction

Total hip replacement (THR) is a common procedure that is performed increasingly often. Although most patients have satisfactory long-term stability, approximately 17% of prosthetic hips fail, thus requiring revision. Frequently, when hip prosthesis revision is undertaken, there is significant acetabular bone deficiency present; this clinical setting presents one of the most challenging circumstances in hip surgery. There is a variety of surgical hardware and strategies available to address this problem.

Indications for acetabular revision include symptomatic aseptic loosening, failure of fixation, infection, wear, osteolysis, and instability. Bozic and associates, using the Healthcare Cost and Utilization Project Nationwide Inpatient Sample database, recently found that the most common cause of revision hip surgery was instability or dislocation (22.5%).[1]

1. Acetabular Defects Classification Systems

1.1. AAOS Classification

The American Academy of Orthopaedic Surgeons (AAOS) classification of bone defects, as described by D'Antonio and associates, identifies the pattern and location of bone loss but does not quantify the defect.[2,3] This system, which was developed by evaluating AP and lateral hip radiographs and comparing results intraoperatively, is probably the most commonly used classification in the literature.

1.2. Paprosky Classification

The Paprosky classification system is based on the severity of bone loss and on the ability to obtain cementless fixation for a given bone loss pattern.[4-6] It was initially developed by evaluating the AP pelvis radiograph and comparing this information with intraoperative findings.

Careful interpretation of the AP radiograph can predict the type of defect and can allow the surgeon to plan for the acetabular reconstruction. Four criteria are used to assess the preoperative radiograph: (1) superior migration of the hip center, (2) ischial osteolysis, (3) teardrop osteolysis, and (4) position of the implant relative to Kohler's line.

1.3. Preoperative Planning

Preoperative planning is a critical aspect of any reconstructive hip surgery but is particularly important in revision surgery. The surgeon must anticipate instrument, bone graft, and implant requirements for the surgery, as well as which reconstructive options may be needed, based on what may be found intraoperatively.

Every patient undergoing revision surgery should be screened for infection with at least an erythrocyte sedimentation rate and C-reactive protein. The erythrocyte sedimentation rate should be less than 30 mm/hr and the C-reactive protein less than 10 mg/L.

2. Treatment Options For Acetabular Defects

Several options are available for acetabular revision. These options are divided into two major categories based on the type of fixation. *Biological fixation* refers to any surgical option that requires direct contact with host bone and osteointegration into the acetabular shell to provide long-term fixation. Biological fixation techniques include the use of a hemispherical uncemented cup at the anatomic hip center or a high hip center (>2 cm superior to the native hip center), a jumbo cup (66 to 80 mm), a bilobed or oblong cup, an uncemented hemispherical cup supported by structural allograft, and a modular cementless implant system. *Nonbiological fixation* refers to any method of reconstruction that achieves stability of the acetabular component through a mechanical construct without the need for osteointegration between the acetabular shell and the host bone. Nonbiological fixation techniques include cementing of a polyethylene cup, use of a superior structural allograft and a cemented polyethylene cup with or without

an antiprotrusio cage, impaction grafting with or without an antiprotrusio cage, and application of a total acetabular allograft.

3. Own Experience For Acetabular Defects Reconstruction

This chapter presented our own experience for acetabular defects reconstruction. 56 patients were operated during the research period: 26 - primary hip replacement and 30 patients with revision hip (Fig 3.1).

Only W.G. Paprosky classification was used to classify acetabular defects during our investigation (Fig. 3.2).

Different kind of tantalum constructions were used to reconstruct existing acetabular defects during replacement surgery.

Porous tantalum is an alternative metal for total joint arthroplasty components that offers several unique properties. Its high volumetric porosity (70% to 80%), low modulus of elasticity (3 MPa), and high frictional characteristics make it conducive to biologic fixation. Tantalum has excellent biocompatibility and is safe to use in vivo. The low modulus of elasticity allows for more physiologic load transfer and relative preservation of bone stock. Because of its bioactive nature and ingrowth properties, tantalum is used in primary as well as revision total hip arthroplasty components, with good to excellent early clinical results. In revision arthroplasty, standard and custom augments may serve as a structural bone graft substitute.

Now some patients' X-rays will be presented before and after operation and we will try to make a conclusion according to this experience.

In the Fig. 3.3 was presented the patient with II B acetabular defect (cavitary acetabular defect) according W.G. Paprosky - primary hip replacement. In the preoperative X-Ry and 3D picture possible to see bone deficiency in superiorlateral part of acetabulum. In the postoperative X-Ry and 3D picture (Fig. 3.4) existing defect was covered with tantalum augment. Between augment and cup bone cement was used.

In the Fig. 3.5, 3.6 again possible to see II B defect (segmental acetabular defect) according Paprosky classification, before and after operation. This case presented revision hip replacement. In preoperative X-Ry we can see acetabular cup failure after cemented fixation.

Next patient, Z.D.Y., 47 years old, was operated with III A defect (extensive segmental acetabular defect) – primary hip replacement. In the Fig. 3.7, Fig. 3.8 possible to see preoperative and postoperative X-Rys, 3D pictures.

In next case also possible to see III A acetabular defect (Fig. 3.9). Patient had bone deficiency in the central part of acetabulum.

During next three cases we want to present patients with III A and B acetabular defects with severe bone loosening.

The first patient had dislocation after replacement surgery and instability for all component of endoprosthesis. In Fig. 3.10 we can see X-Ry before operation and after the first operation. Aim of the first operation was removing previous prosthesis and putting spacer. There was huge bone defect in acetabular region, III B (Fig. 3.10 **B,** Fig. 3.11). In Fig. 3.12 possible to see acetabular defect reconstruction with tantalum augment, during the surgery **A** (intraoperative pictures) and after surgery **B** (postoperative X-Ry).

The second case – 32 years old patient, Y.W.Z., after acetabular region plating operation. Patient had deformity in the hip joint and severe pain. In Fig. 3.13 possible to see preoperative X-Rys, III A defect according to W.G. Paprosky classification and in Fig. 3.14 – postoperative X-Rys, after the reconstraction surgery with tantalum construction.

The third patient – 73 years old female, H.Y.Z., after bilateral hip replacement (Fig. 3.15). In the right side possible to see huge bone defect (III B) in the acetaular region, cup loosening and fracture, in the left side also bone defect and cup loosening. Fig. 3.16 presented tantalum augments preparation with using bone cement. In the Fig. 3.17 we can see postoperative X-Rys, after the right acetabulum reconstruction with augments and in the Fig. 3.18 possible to compare difference between using cup cage technic and tantalum augment.

During research period we had three patients with complications (Fig. 3.19): two cases of dislocation after revision replacement (3,6%) and one - after primary replacement (1,8%) (Fig. 3.20), one suppuration case (1,8%) (Fig. 3.21).

Conclusion

1. **Using tantalum augments during acetabular region reconstruction allow to avoid non-biological fixators - support rings and structural grafts.**
2. **Augments selection is conducted according to preoperative planning, in which is necessary performing CT with 3D reconstruction.**
3. **Tantalum augments are successfully applicable during all kinds of acetabular defects reconstruction, in primary and revision replacement.**
4. **For augments successful osseointegration is necessary close contact between tantalum and bone.**
5. **Using tantalum augments during acetabular region reconstruction allow to achieve components stable primary fixation.**

Abbreviations

1. THR - Total hip replacement

2. AAOS - American Academy of Orthopaedic Surgeons

Declarations

Ethics approval and consent to participate - Not applicable

Consent for publication - Not applicable

Availability of data and materials - The data that support the findings of this study are available from The Second Military Medical University, PRC, Shanghai; Yerevan State Medical University, Yerevan, Armenia; Artmed MRC, Yerevan, Armenia but restrictions apply to the availability of these data, which were used under license for the current study, and so are not publicly available. Data are however available from the authors upon reasonable request and with permission of mentioned institutions. This study includes materials from Master Degree research has been done in The Second Military Medical University, PRC, Shanghai from 2013 to 2015 and materials from Yerevan State Medical University, Yerevan, Armenia; Artmed MRC, Yerevan, Armenia.

Competing interests - The authors declare that they have no competing interests

Funding - There aren't special sources of funding for the research. The research has been done in The Second Military Medical University, Yerevan State Medical University and Artmed MRC.

Authors' contributions - Artak S. Galstyan analyzed and interpreted the patient data, evaluated functional results of hip arthroplasty with acetabular defects, pelvic bone loss revised with porous tantalum acetabular components, performed or took part in primary or revision hip replacement surgeries. Yulin Wu and Peiliang Fu performed primary or revision hip replacement surgeries and were a major contributors in writing the manuscript. All authors read and approved the final manuscript.

Acknowledgements - Not applicable

Authors' information (optional) -

Artak S. Galstyan

YEREVAN STATE MEDICAL UNIVERSITY

Republic of Armenia, Yerevan, Koryun street 2, 0025

Tel. (+37410)529605

(+37493)085121

a_galstyan2003@yahoo.com

info@ysmu.com

Yulin Wu

Peiliang Fu

THE SECOND MILITARY MEDICAL UNIVERSITY

PRC, Shanghai

fupeiliang@163.com

webmaster@smmu.edu.cn

References

1. **BozicKJ, Kurtz SM, Lau E, et al.**: The epidemiology of revision total hip arthroplasty in the United States. *J Bone Joint Surg Am.* 91:128-133 200919122087
2. **D'AntonioJA, Capello WN, Borden LS, et al.**: Classification and management of acetabular abnormalities in total hip arthroplasty. *Clin Orthop Relat Res.* 243:126-137 1989 2721052
3. **D'AntonioJA**: Periprosthetic bone loss of the acetabulum: classification and management. *Orthop Clin North Am.* 23:279-290 1992 1570140
4. **PaproskyWG, Burnett RS**: Assessment and classification of bone stock deficiency in revision total hip arthroplasty. *Am J Orthop.* 31:459 200212216969
5. **PaproskyWG, Perona PG, Lawrence JM**: Acetabular defect classification and surgical reconstruction in revision arthroplasty: a 6-year follow-up evaluation. *J Arthroplasty.* 9:33-44 1994 8163974
6. **SporerSM, Paprosky WG, O'Rourke MR**: Managing bone loss in acetabular revision. *Instr Course Lect.* 55:287-297 2006 16958464
7. **Sporer SM, Paprosky WG, O'Rourke MR**: Managing bone loss in acetabular revision. Instr Course Lect 55:290, 2006.

Figures

1.4. Algorithmic Approach

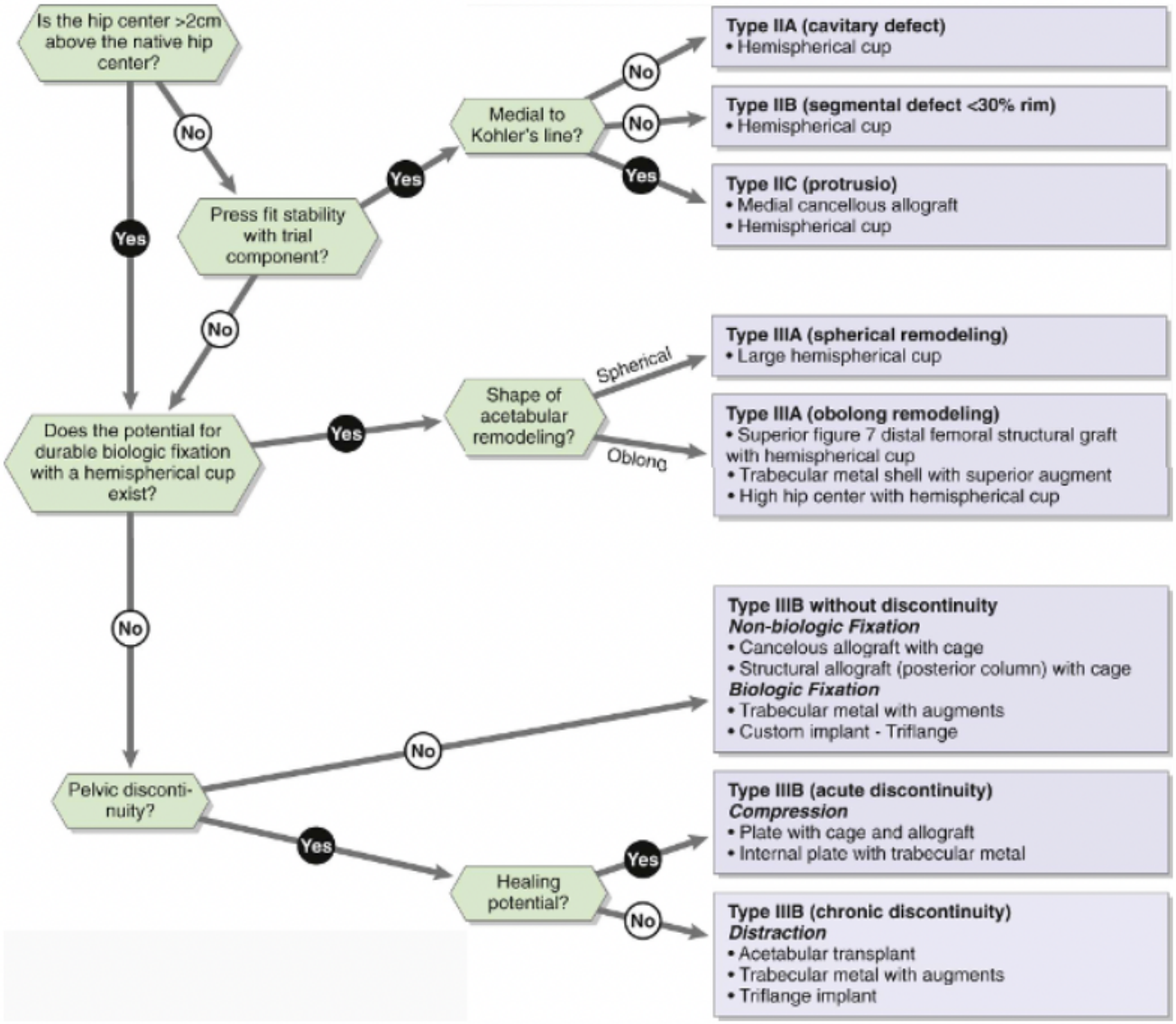

Figure 1

1.9. Algorithmic approach to acetabular reconstruction. (Redrawn from Sporer SM, Paprosky WG, O'Rourke MR: Managing bone loss in acetabular revision. Instr Course Lect 55:290, 2006.7)

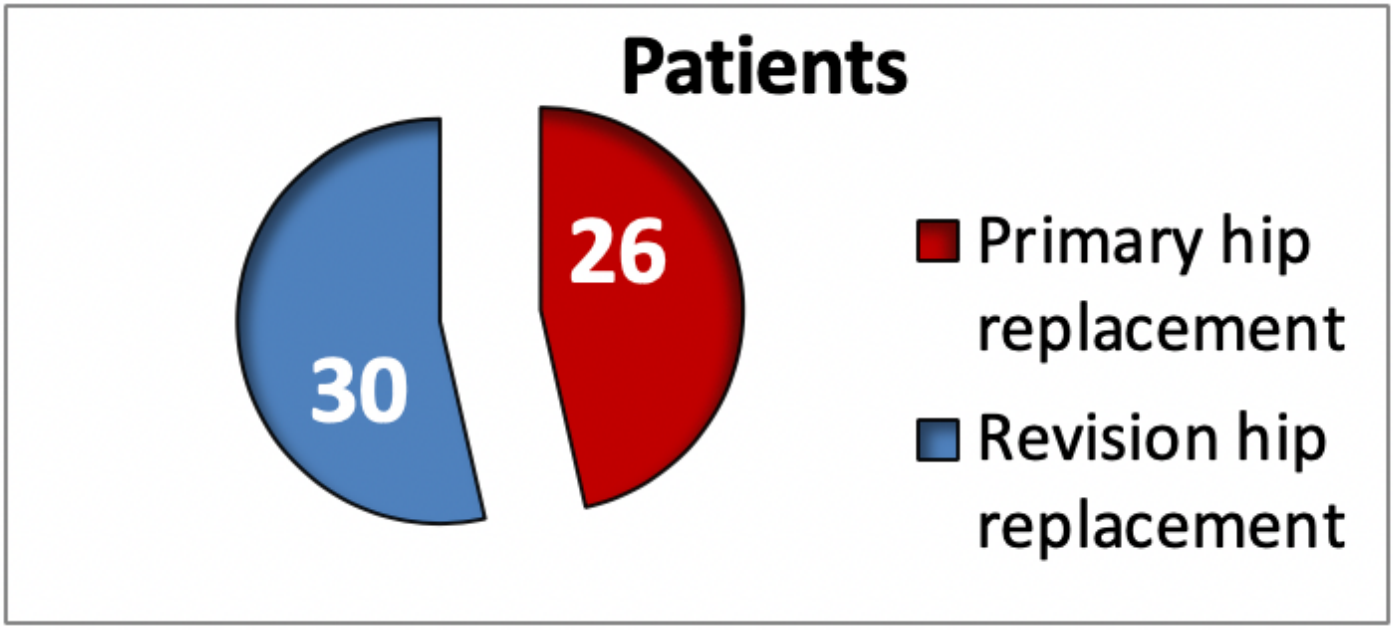

Figure 2

3.1. Patients with primary and revision hip replacement.

Type of operation	Defect type according to W.G. Paprosky classification	Amount of patients
Primary hip replacement	II B	12
	II C	2
	III A	9
	III B	3
Revision hip replacement	II C	3
	III A	17
	III B	10
All operations		56

Figure 3

3.2. Patients' distribution according to the type of acetabular defect (W.G. Paprosky classification).

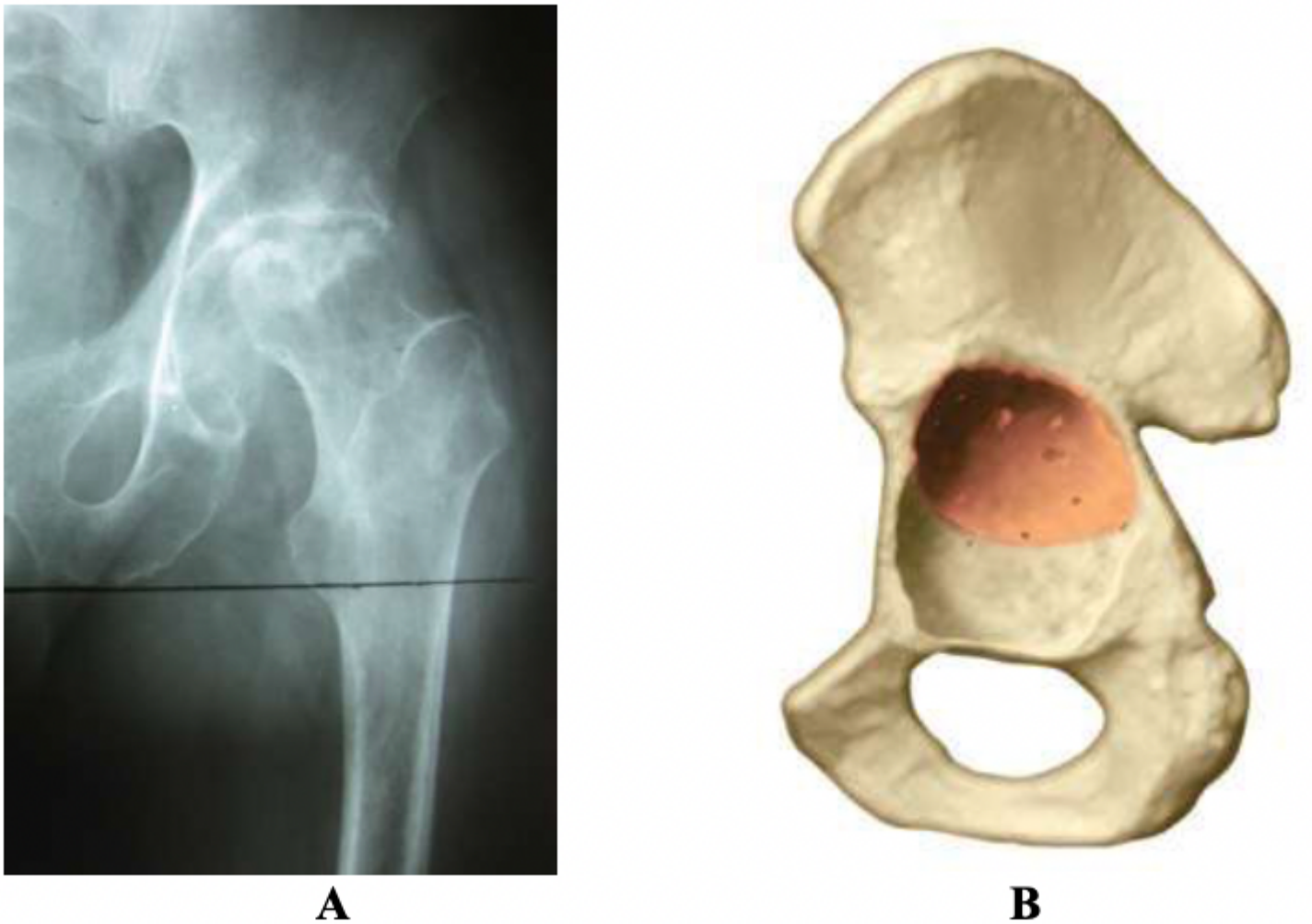

Figure 4

3.3. A Preoperativ X-ry II B acetabular defect (cavitary superiorlateral defect). B Same defect 3D picture.

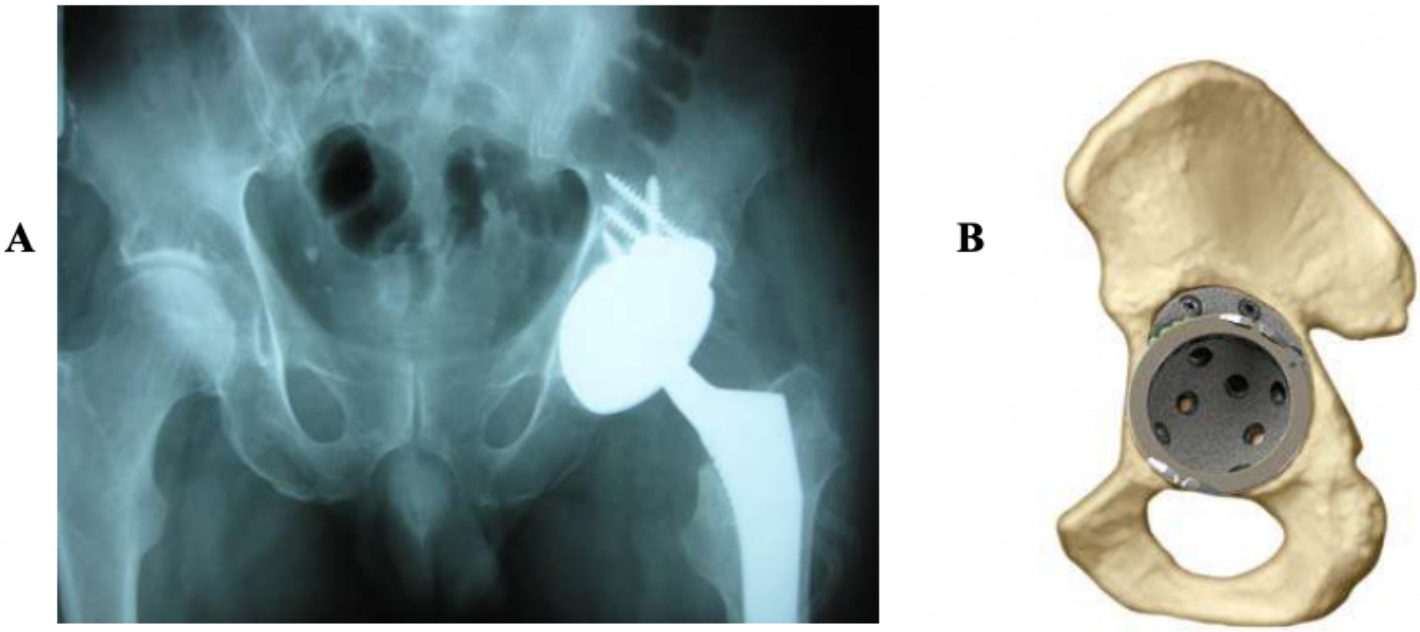

Figure 5

3.4. A X-Ry after replacement surgery. Existing defect covered with tantalum augment. B 3D picture after operation.

A

B

Figure 6

3.5. A Preoperative X-Ry after acetabular cup cemented fixation failure. B Acetabular defect 3D picture.

Figure 7

3.6. A Postoperative X-Ry after revision hip replacement, existing defect covered with augment. B Postoperative 3D picture.

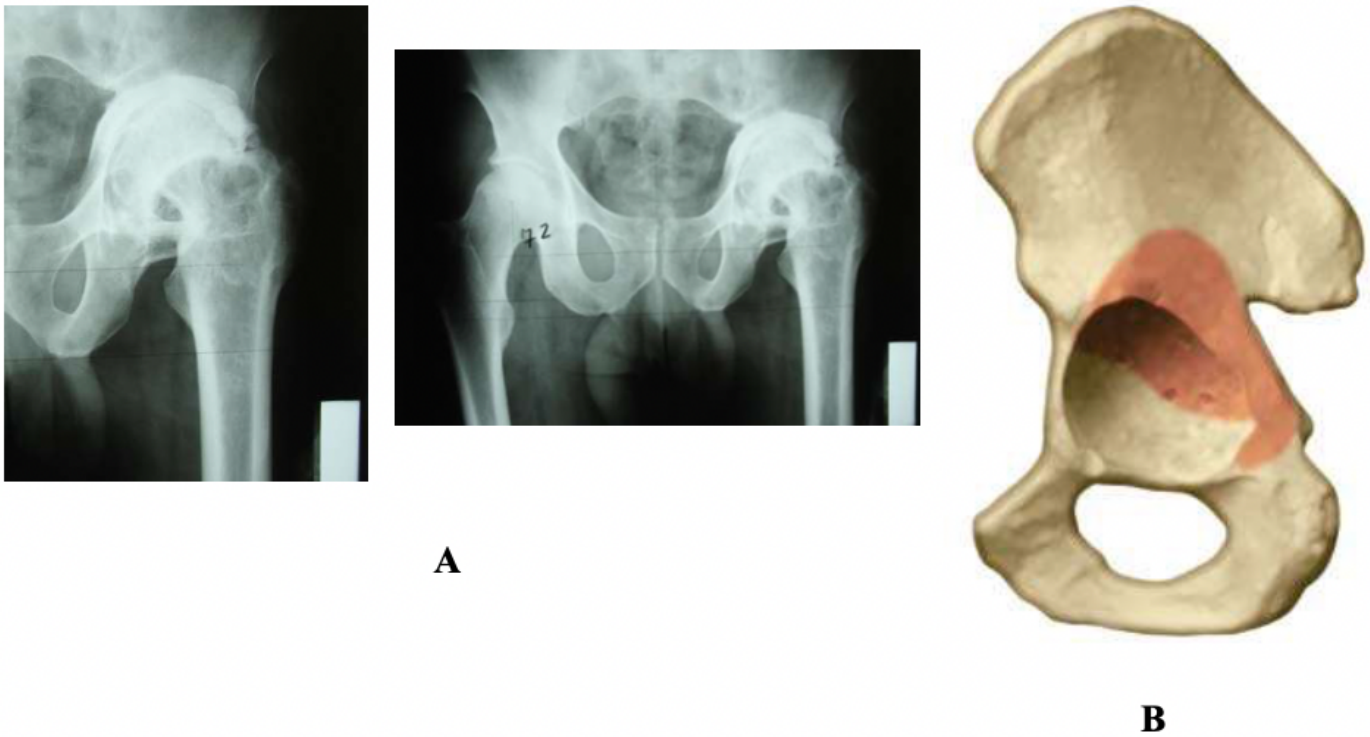

Figure 8

Fig. 3.7. A, B III A acetabular defect according W.G. Paprosky classification – preoperative X-Rys and 3D picture.

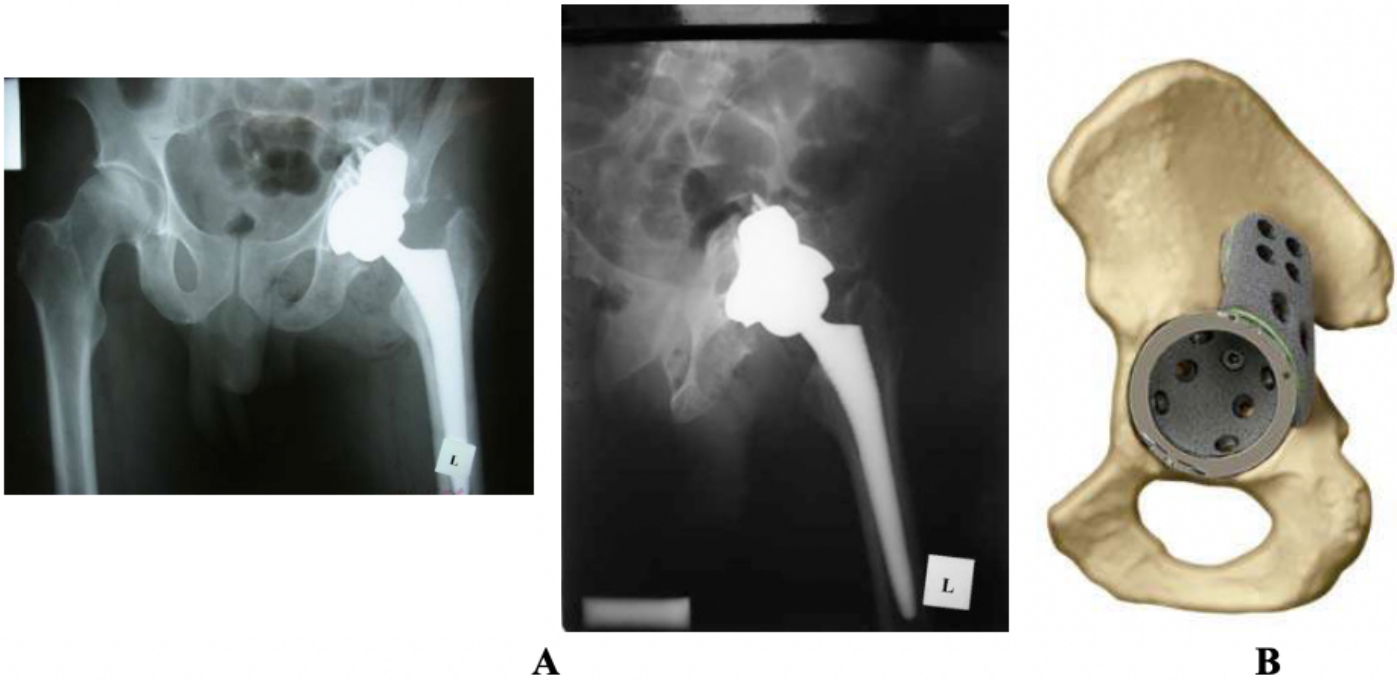

Figure 9

3.8. A, B Same patient, postoperative X-Rys and 3D picture. Existing defect covered with tantalum construction.

Figure 10

3.9. A III A defect 3D picture. B Postoperative X-Ry, acetabular defect covered with augment.

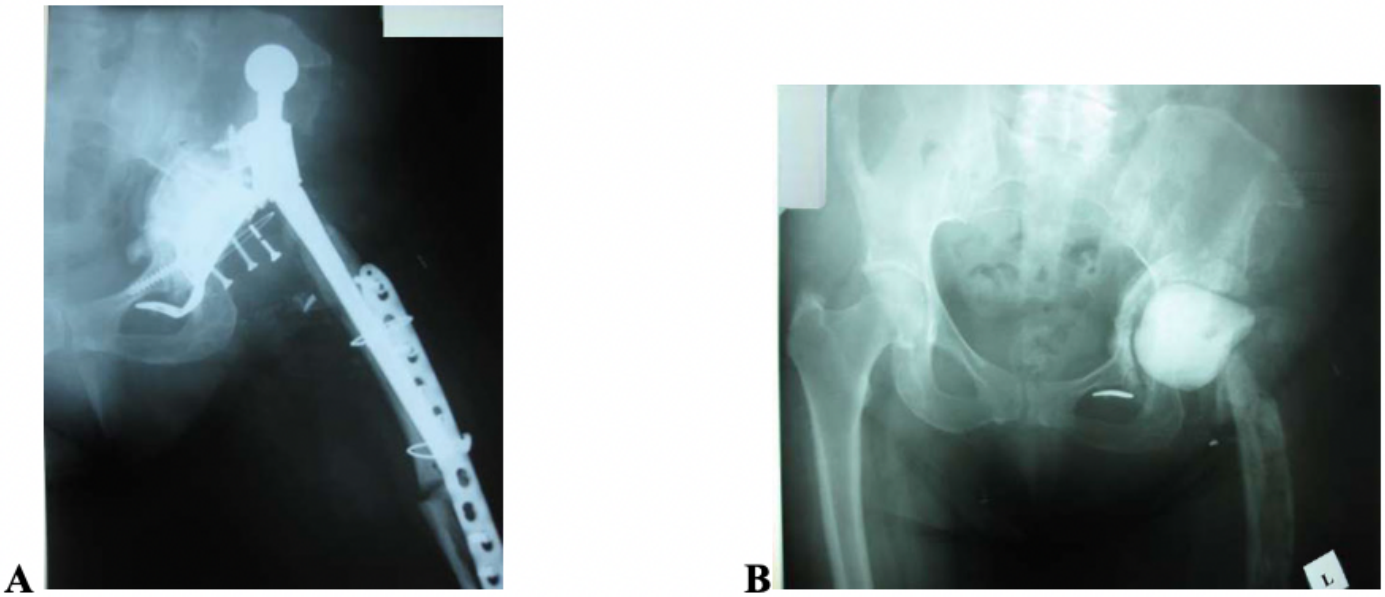

Figure 11

3.10. A Preoperative X-ry with dislocation and instability. B X-Ry after the first operation.

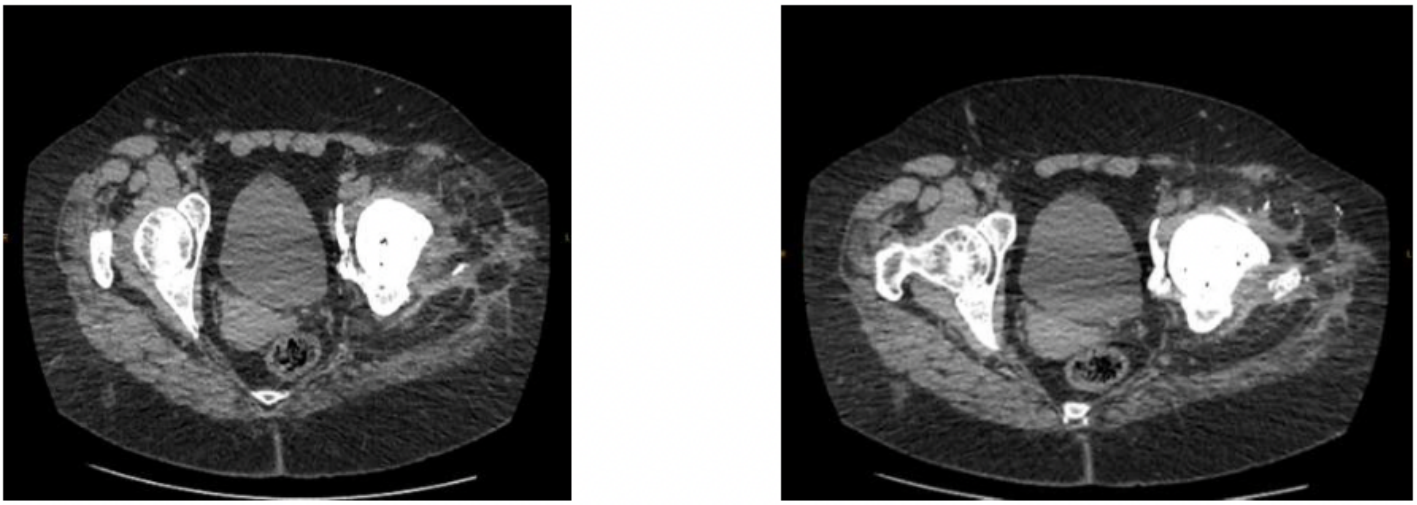

Figure 12

3.11. In CT possible to see huge bone defect in acetabular region, III B defect according to W.G. Paprosky.

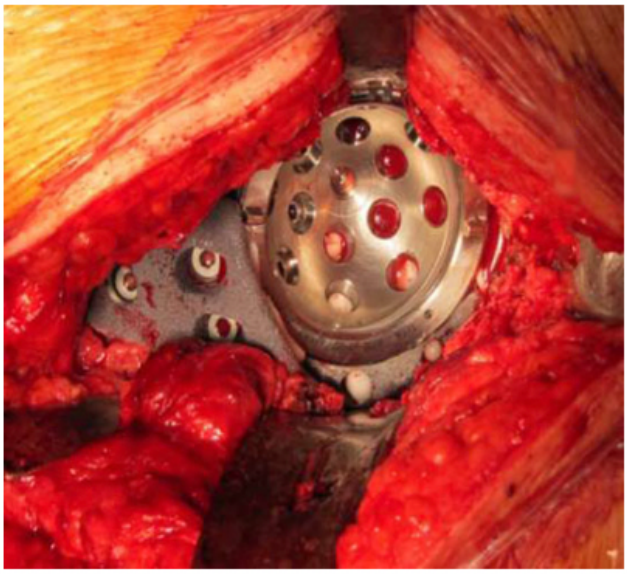

A

B

Figure 13

3.12. Acetabular defect reconstruction with tantalum augment during the surgery A (intraoperative pictures) and after surgery B (postoperative X-Ry).

Figure 14

3.13. In preoperative X-Rys possible to see deformity in the hip joint and bone loosening, acetabular region III A defect according to W.G. Paprosky.

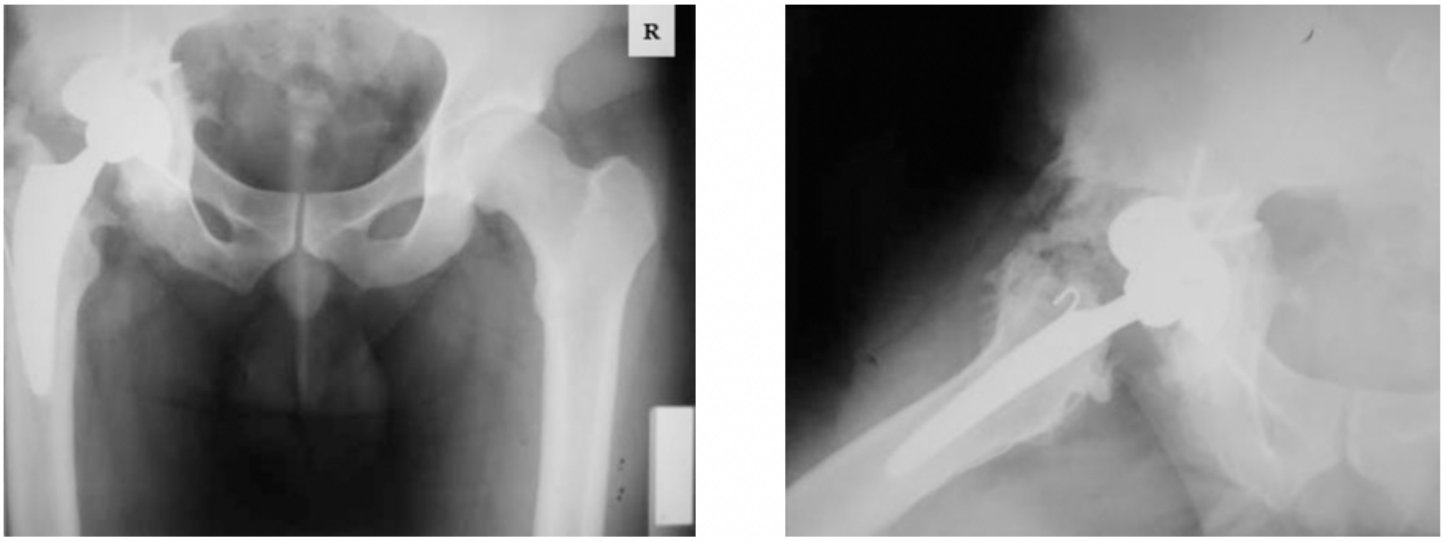

Figure 15

3.14. Postoperative X-Rys, after the reconstruction surgery with tantalum augment.

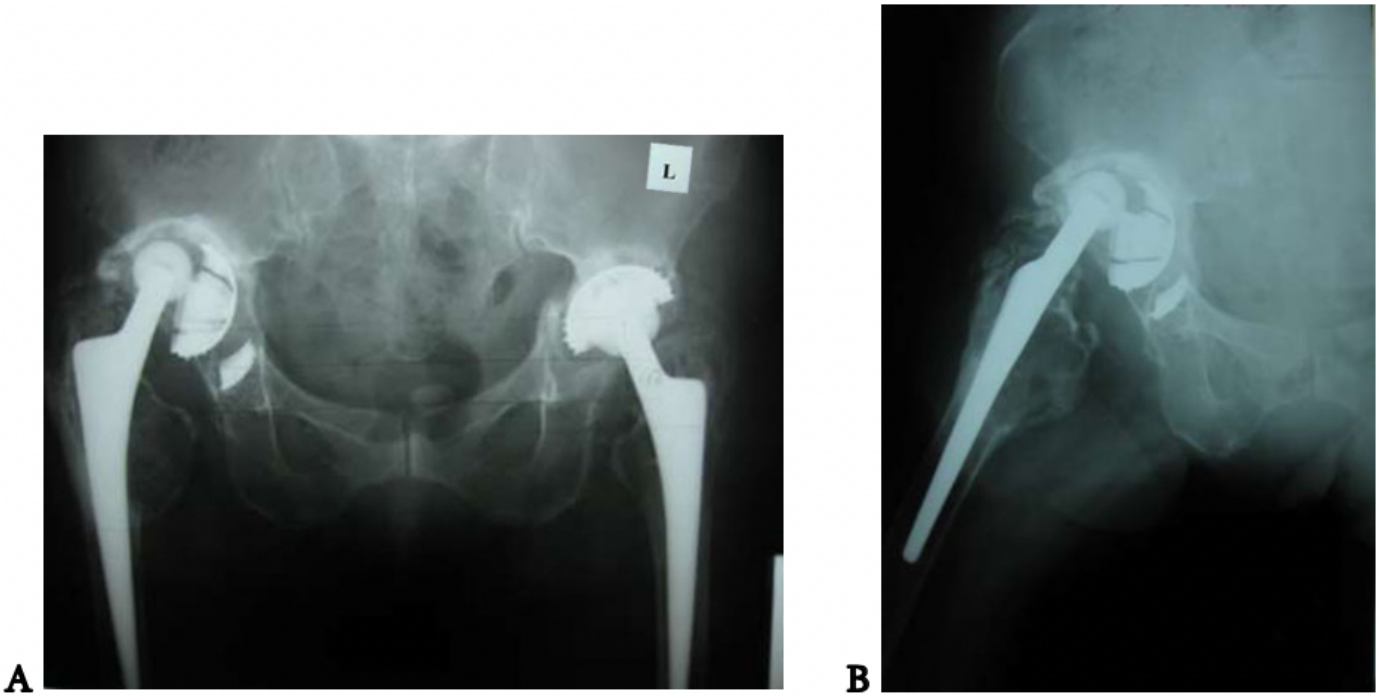

Figure 16

3.15. A Bilateral hip replacement. In the right side huge bone defect (III B) in the acetabular region with cup loosening and fracture, left side also bone defect and cup loosening. B Right side X-Ry.

Figure 17

3.16. Tantalum augments preparation with using bone cement.

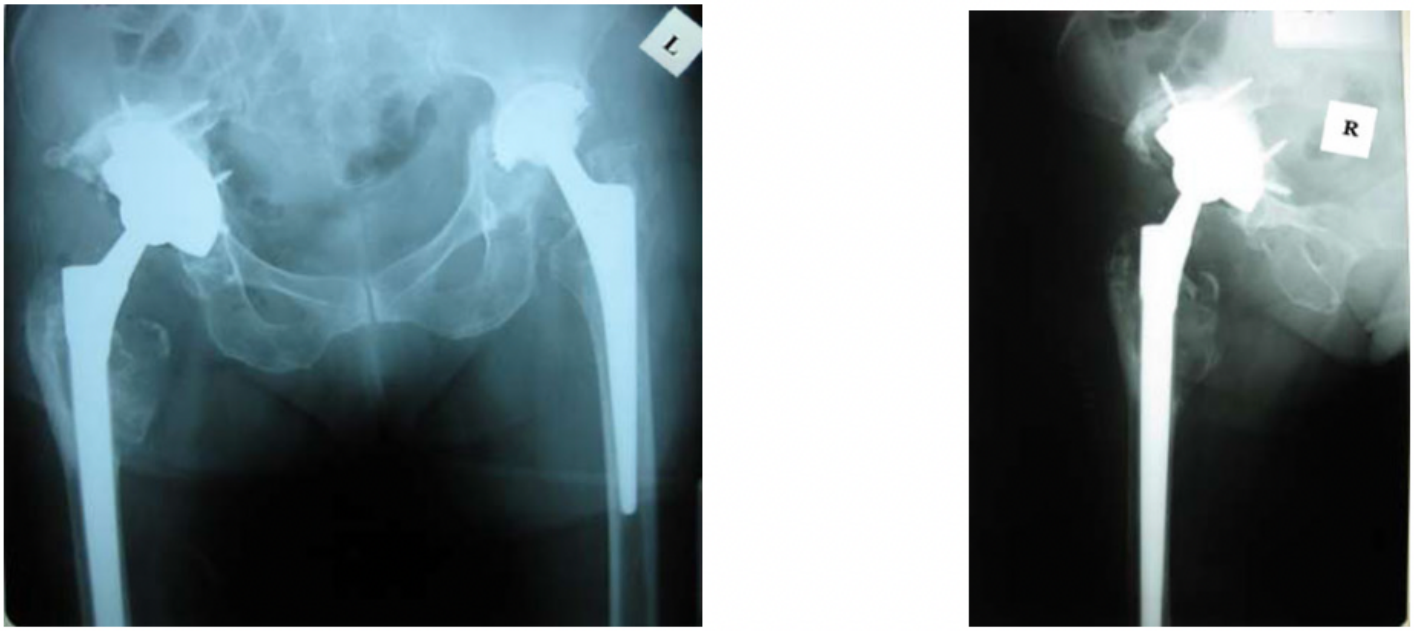

Figure 18

3.17. Postoperative X-Rys, after the right acetabulum reconstruction with augments.

Figure 19

3.18. In these X-Rys possible to compare deferens between augment reconstruction (right side) and cup cage technic (left side).

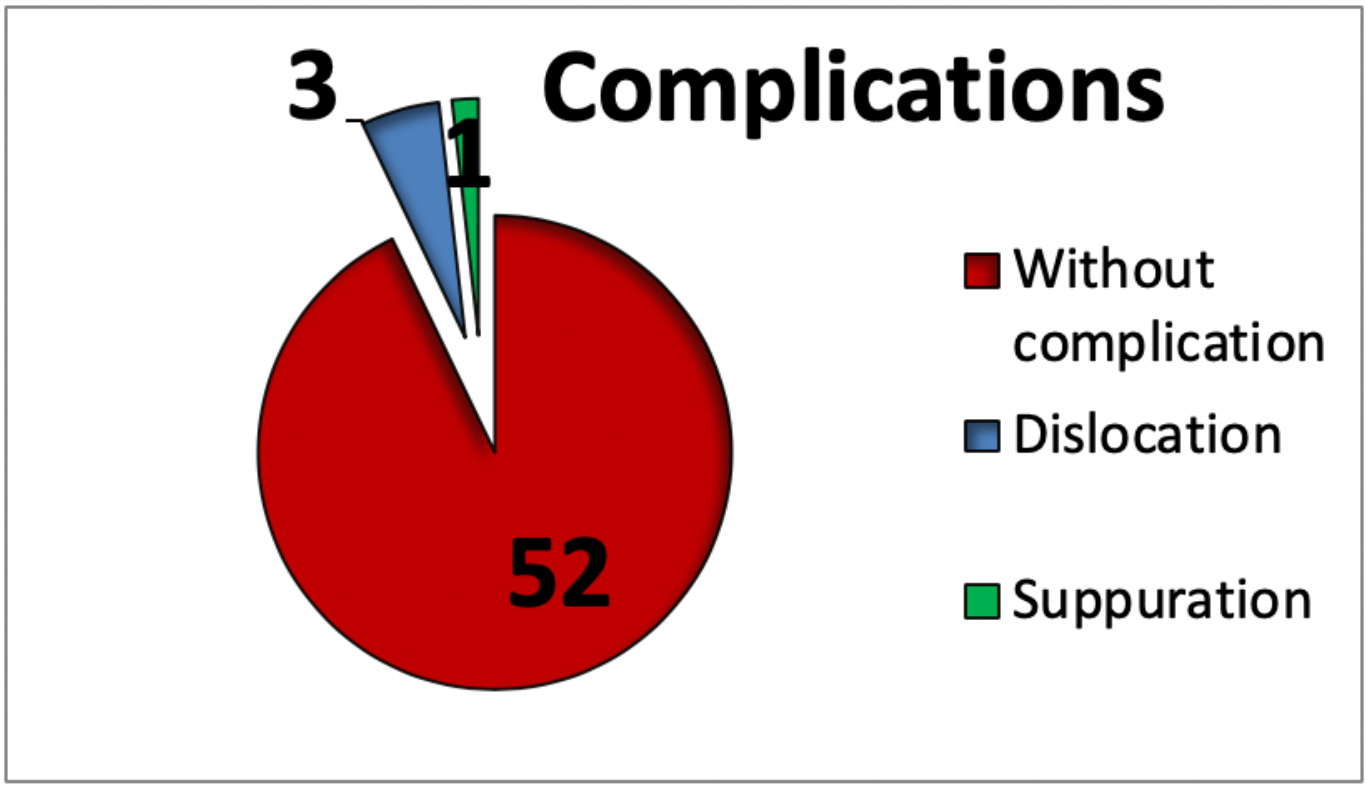

Figure 20

3.19. Complications during the research period.

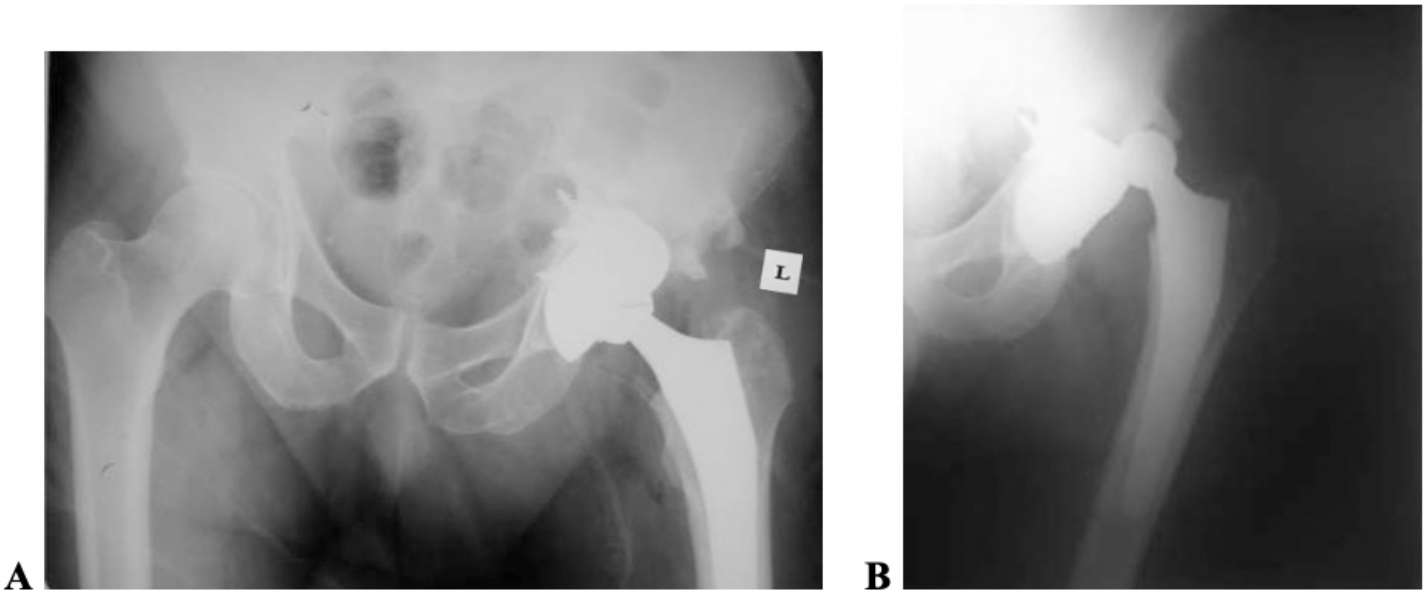

Figure 21

3.20. Dislocation case after reconstruction surgery. A Before dislocation, B after dislocation.

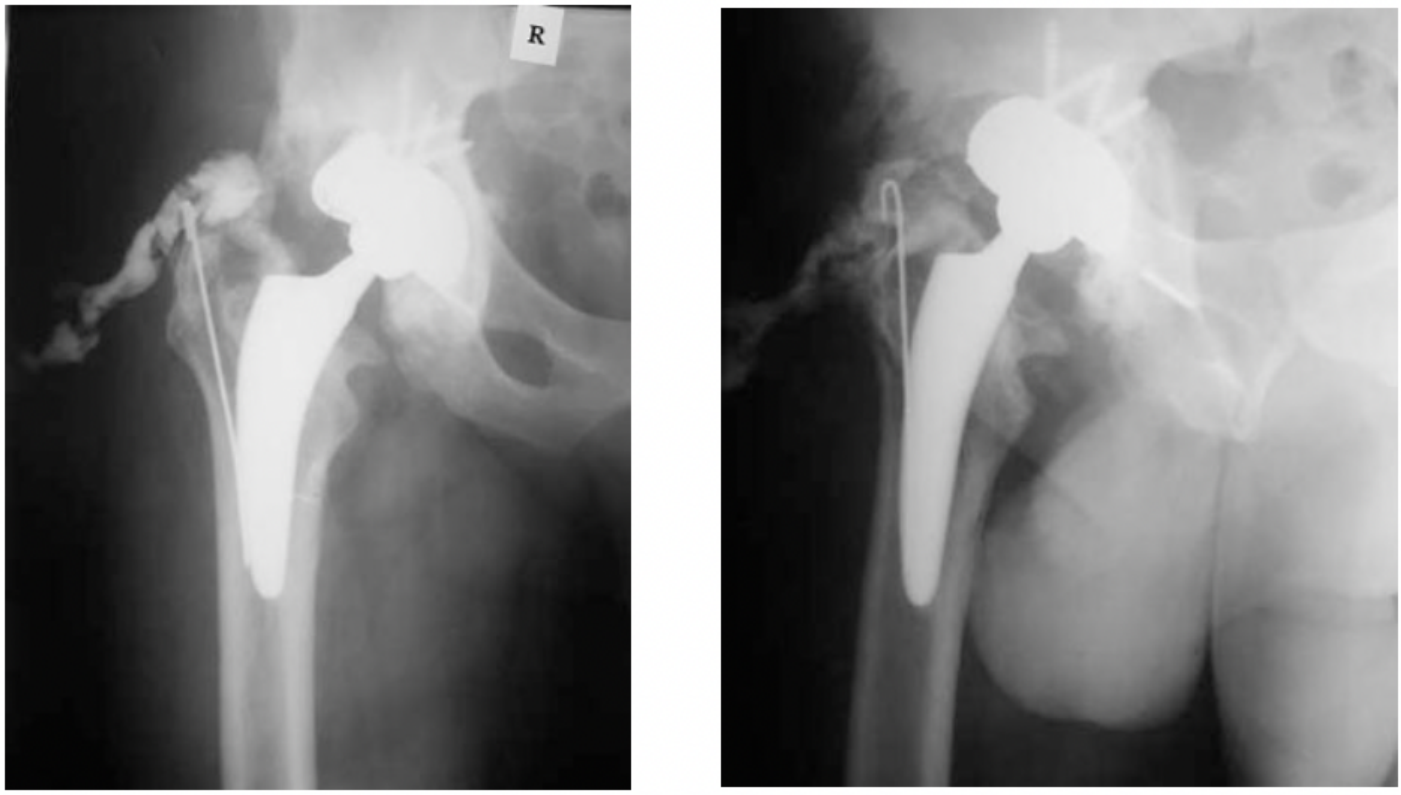

Figure 22

3.21. Suppuration case after reconstruction surgery.