Efficacy of single-position oblique lateral interbody fusion combined with percutaneous pedicle screw fixation in treating degenerative lumbar spondylolisthesis: a cohort study

Hai-hong Zhang (haihongzhang1968@163.com)
Lanzhou University Second Hospital

Peng Cheng
Lanzhou University Second Hospital

Xiao-bo Zhang
Honghui Hospital, Xi'an Jiaotong University

Qi-ming Zhao
Lanzhou University Second Hospital

Research Article

Keywords: degenerative lumbar spondylolisthesis, oblique lumbar interbody fusion, single-position, minimally invasive spinal fusion, surgical technique

Posted Date: April 6th, 2022

DOI: https://doi.org/10.21203/rs.3.rs-1501208/v1

Abstract

Objective: To investigate the surgical outcomes of single-position oblique lateral interbody fusion (OLIF) combined with percutaneous pedicle screw fixation (PPSF) in treating degenerative lumbar spondylolisthesis (DLS).

Methods: We retrospectively analyzed 85 patients with DLS who met the inclusion criteria from April 2018 to December 2020. According to the need to change their position during the operation, the patients were divided into a single-position OLIF group (27 patients) and a conventional OLIF group (58 patients). The operation time, intraoperative blood loss, hospitalization days, instrumentation accuracy and complication rates were compared between the two groups. The visual analog scale (VAS) and Oswestry disability index (ODI) were used to evaluate the clinical efficacy. The surgical segment's intervertebral space height (IDH) and lumbar lordosis (LL) angle were used to evaluate the imaging effect.

Results: The hospital stay, nail placement accuracy, and complication incidence were similar between the two groups ($P>0.05$). The operation time and intraoperative blood loss in the single-position OLIF group were less than those in the conventional OLIF group ($P<0.05$). The postoperative VAS, ODI, IDH and LL values were significantly improved ($P<0.05$), but there was no significant difference between the two groups ($P>0.05$).

Conclusions: Compared with conventional OLIF, single-position OLIF combined with PPSF is also safe and effective, and it has the advantages of a shorter operation time and less intraoperative blood loss.

Introduction

Degenerative lumbar spondylolysis (DLS) refers to the displacement of the lumbar vertebral body relative to the lower vertebral body due to lumbar degenerative changes. The prevalence rate is approximately 4.1% ~ 11.1% [1]. When severe neurological deficits occur or medical treatment is unsuccessful, surgery can be proposed. At present, the commonly used surgical methods for the treatment of DLS include anterior lumbar interbody fusion (ALIF), posterior lumbar interbody fusion (PLIF), translaminar lumbar interbody fusion (TLIF) and oblique lateral interbody fusion (OLIF). The OLIF surgical technique, which has emerged in recent years, uses an approach that targets the region between the abdominal aorta and the psoas major in the retroperitoneal space, reducing the risk of damage to the psoas major and vascular nerves without the need for neuromonitoring during surgery. OLIF has the advantages of reduced trauma, better biomechanical stability and faster functional recovery, and it is gradually being used in clinical practice [2, 3].

However, conventional OLIF requires intervertebral fusion cage placement in the lateral position and pedicle screw placement in the prone position, which significantly increases the operative duration and risks of life-threatening complications, such as tracheal intubation falling off during anesthesia [4]. Therefore, single-position OLIF combined with percutaneous pedicle screw fixation (PPSF) may be an

effective and improved treatment for DLS. This study evaluated and analyzed the clinical, surgical and radiographic outcomes of single-position OLIF combined with PPSF in treating DLS.

Material And Methods

General patient data

This study has been reported in line with the Strengthening the Reporting of Cohort Studies in Surgery (STROCSS) criteria [5]. The inclusion criteria were as follows: persistent low back pain and lower extremity pain that was unresponsive to conservative treatment; determination of the affected level by computed tomography (CT) and magnetic resonance imaging (MRI); Meyerding classification of first- or second-degree DLS (Figure 1); complete clinical and imaging data; and follow-up of more than 12 months. The exclusion criteria were as follows: history of lumbar spine surgery; patients with lumbar trauma, infection, tumor or basic disease who cannot tolerate surgery; coagulation dysfunction; inability to self-evaluate due to mental illness; and missing follow-up data. There were 27 patients in the single-position OLIF group, 10 males and 17 females, with an average age of 57.70 ± 7.20 years (range 46-74), and this group included 6 cases in L3/4 segments and 21 cases in L4/5 segments. The follow-up time was 25.15 ± 4.78 (range 16-33) months. There were 58 patients in the conventional OLIF group, 24 males and 34 females, with an average age of 60.88 ± 9.51 years (range 26-75), and this group included 2 cases in L2/3 segments, 10 cases in L3/4 segments and 46 cases in L4/5 segments. The follow-up time was 25.91 ± 5.26 (range 14-33) months.

All the surgical procedures were performed by orthopedic surgeons with extensive experience in spinal surgery. The patient's sex and age, nail accuracy, operative duration, blood loss, hospitalization duration, complication incidence and other general data were collected and recorded. All patients were placed PPSF with "freehand", since the OLIF procedure is already a standard procedure, not repeated in this paper [6] (Figure 2). The difference between the established and performed procedures was that we placed the cage and pedicle screws when the patient was in the right decubitus position. Since there was no difference in postoperative X-ray examination between the two groups, we reported only one case of DLS treated with OLIF (Figure 3).

Efficacy evaluation indicators

Data were collected from all patients before the operation, 1-week after the operation and at the last follow-up (> 12 months). The VAS score [7] and ODI [8] were used to evaluate pain and spinal function improvements. According to Lee et al. [9], the screw placement’s accuracy was assessed as follows: level 0, the screw was located entirely in the pedicle; level I, less than 25% of the screw diameter broke through the pedicle; level, 25-50% of the screw broke through the pedicle; and level III, more than 50% of the screw diameter broke through the pedicle. The number of screws with a placement level of 0 was recorded. The lumbar lordosis (LL) angle and intervertebral disc height (IDH) were measured by lateral X-ray. The IDH

was the distance from the highest portion of the lower endplate of the cephalad vertebra to the closest portion of the upper endplate of the caudal vertebra [10].

Statistical analysis

The data were analyzed using SPSS (version 26.0). The results are expressed as the mean ± standard deviation. The measurement data were tested by t test, and the count data were tested by chi-square test. $P < 0.05$ was considered to indicate a significant difference.

Results

All 85 patients completed the operation. The average operative durations of the single-position OLIF group and the conventional OLIF group were 118.56 ± 15.74 minutes and 133.19 ± 24.94 minutes, respectively, and the intraoperative blood loss was 66.96 ± 14.77 ml and 88.10 ± 16.25 ml, respectively; these values of the single-position OLIF group were significantly lower than those of the conventional OLIF group ($p < 0.05$). The patients' ages in the two groups were 57.70±7.20 and 60.88±9.51, respectively, and the hospitalization days were 7.44±2.01 days and 7.34±1.48 days, respectively, and values were not significantly different (Table 1).

Clinical efficacy

In the single-position OLIF group, the postoperative lumbar VAS score decreased from 6.89 ± 1.21 points to 2.85 ± 0.99 points and was 1.67 ± 0.92 points at the last follow-up. The postoperative lower extremity VAS score decreased significantly from 6.61 ± 0.98 points to 2.81 ± 0.79 points and was 1.56 ± 0.75 points at the last follow-up. The postoperative ODI decreased from 56.15 ± 8.99 to 24.30 ± 7.03 and was 16.74 ± 5.65 at the last follow-up. Similarly, in the conventional OLIF group, the postoperative VAS score significantly decreased from 7.01 ± 1.18 to 2.93 ± 1.09 and was 1.55 ± 0.78 points at the last follow-up. The postoperative lower extremity VAS score also significantly decreased from 6.57 ± 1.01 to 2.88 ± 0.94 and was 1.71 ± 0.75 at the last follow-up. The postoperative ODI decreased from 55.26 ± 7.55 to 25.72 ± 8.42 and was 16.66 ± 5.06 at the last follow-up. Compared with the preoperative VAS and ODI scores, the postoperative VAS and ODI scores in both groups were significantly improved ($P<0.05$). There was no significant difference in the VAD and ODI between the two groups preoperatively, postoperatively or at the last follow-up ($P>0.05$) (Table 2).

Imaging results

In the single-position OLIF group, the IDH was 8.30 ± 1.00 mm preoperatively, 13.58 ± 1.47 at one week postoperatively, and 13.31 ± 1.57 mm at the last follow-up. The LL angle was 35.31 ± 8.24 preoperatively, 47.37 ± 10.07 at one week postoperatively, and 46.76 ± 10.13 at the last follow-up. Similarly, in the

conventional OLIF group, the IDH was 8.43 ± 1.44 mm preoperatively, 13.15 ± 1.50 mm at one week postoperatively, and 12.78 ± 1.64 mm at the last follow-up. The LL was 36.63 ± 8.73 preoperatively, 48.12 ± 10.39 at one week postoperatively, and 47.07 ± 10.09 at the last follow-up. The postoperative LL and IDH of the two groups were significantly improved compared with the preoperative LL and IDH of the two groups ($P<0.05$), but there was no significant difference between the two groups ($P>0.05$) (Table 3).

Complications

In the single-position OLIF group, the incidence of complications was 21.43% (6/27); 3 patients had transient high pain or numbness, and the symptoms disappeared naturally within half a year. One patient had segmental vascular injury. One patient had pain in the operation area of the iliac bone. One patient had cerebrospinal fluid leakage. After lying on his back and rehydration for three days, the symptoms of dizziness gradually relieved. One patient developed an abdominal bulge at the wound site. In the conservative OLIF group, the incidence of complications was 27.59% (16/58). During the operation, there were 2 cases of peritoneal injury and 2 cases of endplate injury. Five patients had transient thigh pain or numbness, 1 patient had low back pain, and 2 patients had lumbar myasthenia, and the symptoms gradually disappeared within half a year without treatment; 2 patients had transient hip flexion weakness, and the symptoms disappeared after nerve detumescence treatment; 2 patients had cerebrospinal fluid leakage, and the symptoms of dizziness gradually decreased after lying down and rehydration for 7 days. There was no significant difference in the incidence of complications between the two groups ($\chi2=0.276$, $P=0.599$). In the single-position OLIF group, the nail placement accuracy was 96.30% (104/108), and the nail placement accuracy in the conventional OLIF group was 94.83% (220/232). There was no significant difference between the two groups ($\chi2=0.254$, $P=0.614$)

Discussion

Over time, doctors have increasingly favored minimally invasive surgery. While ensuring clinical results, minimally invasive procedures minimize surgical trauma and ease patient suffering. Various minimally invasive techniques have been applied in the clinic and have benefitted many patients. In recent years, the clinic has widely used minimally invasive oblique lateral spinal fusion surgery via OLIF. This procedure uses extraperitoneal blood vessels and the psoas muscle space for entry, allows the implantation of a larger fusion cage, increases the bone contact surface, and thus increases the fusion rate. This approach also allows complete opening of the intervertebral space, expansion of the intervertebral foramen area, and restoration of the spinal canal volume to achieve indirect decompression [2, 11]. OLIF is widely used because of its ability to provide indirect decompression and its minimal invasiveness; it also helps restore the sagittal curve and coronal balance. It can be applied to treat various lumbar degenerative diseases, especially lumbar spondylolisthesis [12]. Because of the lack of an ideal effect and the insufficient rotational stability achieved with a fusion cage alone, bilateral pedicle screw fixation is still the gold standard [13].

However, in conventional OLIF, the patient usually needs to be in the lateral position for cage placement and then transitioned to the prone position for pedicle screw placement. In this study, single-position OLIF significantly reduced the intraoperative blood loss and shortened the operation time compared with conventional OLIF. Single-position OLIF does not require repositioning, which helps save operative time. Additionally, because the operation time is reduced, the intraoperative blood loss and anesthesia time are reduced, which helps decrease the risk of infection and anesthesia decannulation. Although no patients with anesthesia decannulation and infection were observed in this study, patients may benefit from the close attention of anesthesiologists and strict compliance with routine aseptic procedures.

In addition, the VAS score and ODI in this study were significantly lower after the operation than before the operation. The lumbar and lower limb symptoms were significantly improved. Similarly, IDH and LL on imaging were considerably enhanced compared with those before operation. Loss of the LL angle and changes in the IDH are closely related to the development of DLS. Therefore, it has important clinical significance to study the changes in the LL and IDH in DLS patients. The loss of LL is a key cause of low back pain in patients [14], and the restoration of the IDH at the affected segment improves the compression of the nerve root at the corresponding segment. In this study, both OLIF and PLIF can significantly restore lumbar lordosis and intervertebral space height. There was no significant difference in the VAS, ODI, IDH, and LL between the two groups at the last follow-up. In short, single-position OLIF has clinical efficacy, high safety, and feasibility that are similar to those of conventional OLIF. Similar results have been obtained in other studies [6, 15].

The two groups of patients inevitably had different degrees of complications. Vascular injury, which is mainly the injury of vertebral segmental vessels and iliac vessels, is a common complication of OLIF [16]. The risk of vascular injury by the OLIF technique is mainly related to the process of incision exposure, separation of psoas muscle and vascular sheath, and deep clearance of intervertebral space [17]. Endplate injury mostly occurs in patients with osteoporosis [2]. Improper operations during surgery, such as directly using a sharp reamer to remove the nucleus pulposus or the following the wrong direction during intervertebral disc cleaning, can cause endplate damage. For patients with intraoperative endplate injury, screw fixation is necessary [18]. Among our patients who underwent single-position OLIF, three patients (11.11%) had transient leg weakness during follow-up, and four patients (8.62%) in the conventional OLIF group had transient leg weakness during follow-up. The numbers were within the normal range (6.1-60.3%) [11, 19, 20]. Postoperative thigh numbness and hip flexion weakness may be caused by retraction of the psoas muscle and associated sensory nerves [21]. These symptoms are mostly transient, and postoperative rehabilitation exercises can facilitate recovery in a short period.

Pedicle screw misplacement is a common complication in spinal surgery. This study used “freehand” screw placement. According to reports, the displacement rate of “freehand” pedicle screw placement is 1.5-14.3% [22-24]. Although the development of robotic technology (computer navigation technology) has helped to improve accuracy [25, 26], sometimes hospitals do not have computer technology navigation technology and often still perform “freehand” operations.

The single-position OLIF may be a new technology worthy of recommendation. Recently, Kotani et al. [27] found that single-position OLIF can provide a comparable fusion rate, segmental radiologic alignment, and symptomatic adjacent segment degeneration to MIS-TLIF surgery. Pham et al. [28] presented a novel technical report on the recommended workflow of simultaneous robotic single-position OLIF and demonstrated the ’feasibility of placement of sacroiliac fixation in the lateral decubitus position. In addition, Diaz-Aguila et al. [15] found that robot-assisted OLIF can reduce the operative time while ensuring accurate and timely screen placement with minimal complications. As medical technology continues to develop, minimally invasive, robot-assisted surgical treatment will be increasingly used. We expect to see more reports on robot-assisted treatments for lumbar degenerative disease. In short, single-position OLIF serves as a safe, minimally invasive and effective surgical modality that saves valuable operating room time and is worth popularizing.

Although OLIF has advantages over conventional surgery in terms of the operative duration, there is no need for a significant learning curve to adapt to this technology. However, we believe that surgeons should pay attention to the following factors. First, surgeons must have sufficient experience with OLIF combined with "freehand" placement of PPSF. Second, the patient's position is significant. On the one hand, being too close to the bed will affect the fluoroscopy. On the other hand, being too far away from the bed will limit the puncture angle of PPSF. According to our experience, the average time required to insert each percutaneous pedicle screw on the patient's right side was significantly longer than that required to insert each screw on the left side. This difference may occur because it is easier to apply force while inserting the percutaneous pedicle screw from the left side. Therefore, the patient's position should be as close as possible to the side of the operating bed so as not to block the operating bed when the nail is placed on the right side. In our opinion, the ideal position is from the edge of the bed to a quarter of the width of the bed.

There are some limitations to our study. First, because the single-position OLIF method has not yet been popularized, the sample size of our study is small, and larger sample size is needed to confirm its safety and efficacy. Second, the survey subjects were limited to LDS patients treated at Lanzhou University Second Hospital. There may be differences among medical institutions due to differences in medical equipment. Third, surgeons may have varying experiences with OLIF techniques.

Conclusion

Single-position OLIF combined with PPSF significantly shortens the operation time, reduces the amount of intraoperative blood loss, is clinically effective, substantially improves the operation efficiency, and has good feasibility and safety. Thus, the treatment of DLS with single-position OLIF may be worth promoting.

Abbreviations

OLIF: Oblique lateral interbody fusion

PPSF: Percutaneous pedicle screw fixation

DLS: Degenerative lumbar spondylolisthesis

VAS: Visual Analog Scale

ODI: Oswestry Disability Index

IDH: Intervertebral disc height

LL: Lumbar lordosis

ALIF: Axial lumbar interbody fusion

PLIF: Posterior lumbar interbody fusion

TLIF: Translaminar lumbar interbody fusion

STROCSS: Strengthening the Reporting of Cohort Studies in Surgery

CT: Computed tomography

MRI: Magnetic resonance imaging

MIS-TLIF: Minimally invasive transforaminal interbody fusion

Declarations

Ethics approval and consent to participate

The study was approved by the ethics committee of the Lanzhou University Second Hospital and has obtained written informed consent from all patients.

Guideline statement

We confirmed that all methods were carried out following relevant guidelines and regulations and all experimental protocols have been approved by the ethics committee of the Lanzhou University Second Hospital. Additionally, we confirmed that informed consent was obtained from all subjects and/or their legal guardian(s).

Consent to Publish

All authors have agreed to publish the manuscript.

Availability of data and material

The datasets used or analyzed during the current study are available from the corresponding author on reasonable request.

Competing interests

All authors declare that there is no conflict of interest in this study.

Funding

This work was supported by the Natural Science Foundation of China (no. 31960175), the Natural Science Foundation of Gansu Province (no. 21JR1RA127), and the Natural Science Foundation of Gansu Province (no. 17JR5RA235).

Authors Contributions

Peng Cheng and Xiao-bo Zhang conceived the study design and drafted the manuscript. Qi-ming Zhao supervised the data collection. Hai-hong Zhang contributed to the revision.
Statement

All authors read and approved the final version of the manuscript.

Acknowledgments

No application.

Author information

Hai-hong Zhang chief physician, doctoral supervisor, professor, has been engaged in treating spine-related diseases for more than 30 years, has rich clinical experience, and has published many high-quality SCI papers.

References

1. Yi P, Tang X, Yang F, Tan M (2020) A retrospective controlled study protocol of transforaminal lumbar interbody fusion compared with posterior lumbar interbody fusion for spondylolisthesis. Medicine 99:e22878.

2. Sato J, Ohtori S, Orita S, Yamauchi K, Eguchi Y, Ochiai N, Kuniyoshi K, Aoki Y, Nakamura J, Miyagi M, Suzuki M, Kubota G, Inage K, Sainoh T, Fujimoto K, Shiga Y, Abe K, Kanamoto H, Inoue G, Takahashi K (2017) Radiographic evaluation of indirect decompression of mini-open anterior retroperitoneal lumbar interbody fusion: oblique lateral interbody fusion for degenerated lumbar spondylolisthesis[J]. Eur Spine J 26:671-678.
3. Li HM, Zhang RJ, Shen CL (2019) Radiographic and Clinical Outcomes of Oblique Lateral Interbody Fusion Versus Minimally Invasive Transforaminal Lumbar Interbody Fusion for Degenerative Lumbar Disease. World Neurosurg 122:e627-e638.
4. Cappuccino A, Cornwall GB, Turner AW, Fogel GR, Duong HT, Kim KD, Brodke DS (2010) Biomechanical analysis and review of lateral lumbar fusion constructs. Spine 35:S361-367.
5. Agha R, Abdall-Razak A, Crossley E, Dowlut N, Iosifidis C, Mathew G (2019) STROCSS 2019 Guideline: Strengthening the reporting of cohort studies in surgery. Int J Surg 72:156-165.
6. Tan Y, Tanaka M, Sonawane S, Uotani K, Oda Y, Fujiwara Y, Arataki S, Yamauchi T, Takigawa T and Ito Y (2021) Comparison of Simultaneous Single-Position Oblique Lumbar Interbody Fusion and Percutaneous Pedicle Screw Fixation with Posterior Lumbar Interbody Fusion Using O-arm Navigated Technique for Lumbar Degenerative Diseases. J Clin Med 10 (21):4938.
7. Huskisson EC (2010) Measurement of pain. Lancet 2:1127-1131.
8. Fairbank JC, Couper J, Davies JB, O'brien JP (1980) The Oswestry low back pain disability questionnaire. Physiotherapy 66:271-273.
9. Lee SH, Kim KT, Suk KS, Lee JH, Son ES, Kwack YH, Oh HS (2012) Assessment of pedicle perforation by the cervical pedicle screw placement using plain radiographs: a comparison with computed tomography. Spine 37:280-285.
10. Li Z, Yu S, Zhao Y, Hou S, Fu Q, Li F, Hou T, Zhong H (2014) Clinical and radiologic comparison of dynamic cervical implant arthroplasty versus anterior cervical discectomy and fusion for the treatment of cervical degenerative disc disease. J Clin Neurosci 21:942-948.
11. Fujibayashi S, Hynes RA, Otsuki B, Kimura H, Takemoto M, Matsuda S (2015) Effect of indirect neural decompression through oblique lateral interbody fusion for degenerative lumbar disease. Spine 40:E175-182.
12. Ohtori S, Orita S, Yamauchi K, Eguchi Y, Ochiai N, Kishida S, Kuniyoshi K, Aoki Y, Nakamura J, Ishikawa T, Miyagi M, Kamoda H, Suzuki M, Kubota G, Sakuma Y, Oikawa Y, Inage K, Sainoh T, Sato J, Fujimoto K, Shiga Y, Abe K, Toyone T, Inoue G, Takahashi K (2015) Mini-Open Anterior Retroperitoneal Lumbar Interbody Fusion: Oblique Lateral Interbody Fusion for Lumbar Spinal Degeneration Disease. Yonsei Med J 56:1051-1059.
13. Reis MT, Reyes PM, Bse, Altun I, Newcomb AG, Singh V, Chang SW, Kelly BP, Crawford NR (2016) Biomechanical evaluation of lateral lumbar interbody fusion with secondary augmentation. J Neurosurg Spine 25:720-726.
14. Labelle H, Mac-Thiong JM, Roussouly P (2011) Spino-pelvic sagittal balance of spondylolisthesis: a review and classification. Eur Spine J 20 Suppl 5:641-646.

15. Diaz-Aguilar LD, Shah V, Himstead A, Brown NJ, Abraham ME, Pham MH (2021) Simultaneous Robotic Single-Position Surgery (SR-SPS) with Oblique Lumbar Interbody Fusion: A Case Series. World Neurosurg 151:e1036-e1043.
16. Woods KR, Billys JB, Hynes RA (2017) Technical description of oblique lateral interbody fusion at L1-L5 (OLIF25) and at L5-S1 (OLIF51) and evaluation of complication and fusion rates. Spine J 17:545-553.
17. Zeng ZY, Xu ZW, He DW, Zhao X, Ma WH, Ni WF, Song YX, Zhang JQ, Yu W, Fang XQ, Zhou ZJ, Xu NJ, Huang WJ, Hu ZC, Wu AL, Ji JF, Han JF, Fan SW, Zhao FD, Jin H, Pei F, Fan SY, Sui DX (2018) Complications and Prevention Strategies of Oblique Lateral Interbody Fusion Technique. Orthop Surg 10:98-106.
18. He W, He D, Sun Y, Xing Y, Wen J, Wang W, Xi Y, Liu M, Tian W, Ye X (2020) Standalone oblique lateral interbody fusion vs. combined with percutaneous pedicle screw in spondylolisthesis. BMC Musculoskelet Disord 21:184.
19. Gammal ID, Spivak JM, Bendo JA (2015) Systematic Review of Thigh Symptoms after Lateral Transpsoas Interbody Fusion for Adult Patients with Degenerative Lumbar Spine Disease. Int J Spine Surg 9:62.
20. Digiorgio AM, Edwards CS, Virk MS, Mummaneni PV, Chou D (2017) Stereotactic navigation for the prepsoas oblique lateral lumbar interbody fusion: technical note and case series. Neurosurg Focus 43:E14.
21. Xu DS, Walker CT, Godzik J, Turner JD, Smith W, Uribe JS (2018) Minimally invasive anterior, lateral, and oblique lumbar interbody fusion: a literature review. Ann Transl Med 6:104.
22. Smith ZA, Sugimoto K, Lawton CD, Fessler RG (2014) Incidence of lumbar spine pedicle breach after percutaneous screw fixation: a radiographic evaluation of 601 screws in 151 patients. J Spinal Disord Tech 27:358-363.
23. Raley DA, Mobbs RJ (2012) Retrospective computed tomography scan analysis of percutaneously inserted pedicle screws for posterior transpedicular stabilization of the thoracic and lumbar spine: accuracy and complication rates. Spine 37:1092-1100.
24. Blizzard DJ, Thomas JA (2018) MIS Single-position Lateral and Oblique Lateral Lumbar Interbody Fusion and Bilateral Pedicle Screw Fixation: Feasibility and Perioperative Results. Spine 43:440-446.
25. Gelalis ID, Paschos NK, Pakos EE, Politis AN, Arnaoutoglou CM, Karageorgos AC, Ploumis A, Xenakis TA (2012) Accuracy of pedicle screw placement: a systematic review of prospective in vivo studies comparing free hand, fluoroscopy guidance and navigation techniques. Eur Spine J 21:247-255.
26. Helm PA, Teichman R, Hartmann SL, Simon D (2015) Spinal Navigation and Imaging: History, Trends, and Future. IEEE Trans Med Imaging 34:1738-1746.
27. Kotani Y, Koike Y, Ikeura A, Tokunaga H, Saito T (2021) Clinical and radiologic comparison of anterior-posterior single-position lateral surgery versus MIS-TLIF for degenerative lumbar spondylolisthesis. J Orthop Sci 26:992-998.

28. Pham MH, Diaz-Aguilar LD, Shah V, Brandel M, Loya J, Lehman RA (2021) Simultaneous Robotic Single Position Oblique Lumbar Interbody Fusion With Bilateral Sacropelvic Fixation in Lateral Decubitus. Neurospine 18:406-412.

Tables

Table 1

General patient data.

Groups	Single-position OLIF	Conventional OLIF	*t*	*P*
Age	57.70±7.20	60.88±9.51	-1.539	0.128
Operation time	118.56 ± 15.74	133.19 ± 24.94	-2.796	**0.006**
Intraoperative blood loss	66.96 ± 14.77 ml	88.10 ± 16.25	-5.947	**0.001**
Hospitalization days	7.44±2.01	7.34±1.48	0.259	0.798

Table 2

Comparison of the lumbar VAS score and lower limb VAS score between the two groups preoperatively, postoperatively and at the last follow-up.

Time	Single-position OLIF	Conventional OLIF	*t*	*P*
Preoperative lumbar VAS	6.89 ± 1.21	7.01 ± 1.18	-0.475	0.636
Postoperative lumbar VAS	2.85 ± 0.99	2.93 ± 1.09	-0.321	0.749
Last follow-up lumbar VAS	1.67 ± 0.92	1.55 ± 0.78	0.599	0.551
Preoperative lower extremity VAS	6.61 ± 0.98	6.57 ± 1.01	-0.219	0.827
Postoperative lower extremity VAS	2.81 ± 0.79	2.88 ± 0.94	-0.310	0.757
Last follow-up lower extremity VAS	1.56 ± 0.75	1.71 ± 0.75	-0.865	0.391
Preoperative ODI	56.15 ± 8.99	55.26±7.55	0.475	0.636
Postoperative ODI	24.30 ± 7.03	25.72 ± 8.42	-0.765	0.447
Last follow-up ODI	16.74 ± 5.65	16.66 ± 5.06	0.067	0.947

Table 3

Comparison of the ODI and IDH between the two groups preoperatively, postoperatively and at the last follow-up.

Time	Single-position OLIF	Conventional OLIF	*t*	*P*
Preoperative IDH	8.30 ± 1.00	8.43 ± 1.44	-0.424	0.673
Postoperative IDH	13.58 ± 1.47	13.15 ± 1.50	1.241	0.218
Last follow-up IDH	13.31 ± 1.57	12.78 ± 1.64	1.444	0.155
Preoperative LL	35.31 ± 8.24	36.63 ± 8.73	0.659	0.511
Postoperative LL	47.37 ± 10.07	48.12 ± 10.39	-0.312	0.755
Last follow-up LL	46.76 ± 10.13	47.07 ± 10.09	-0.130	0.897

Figures

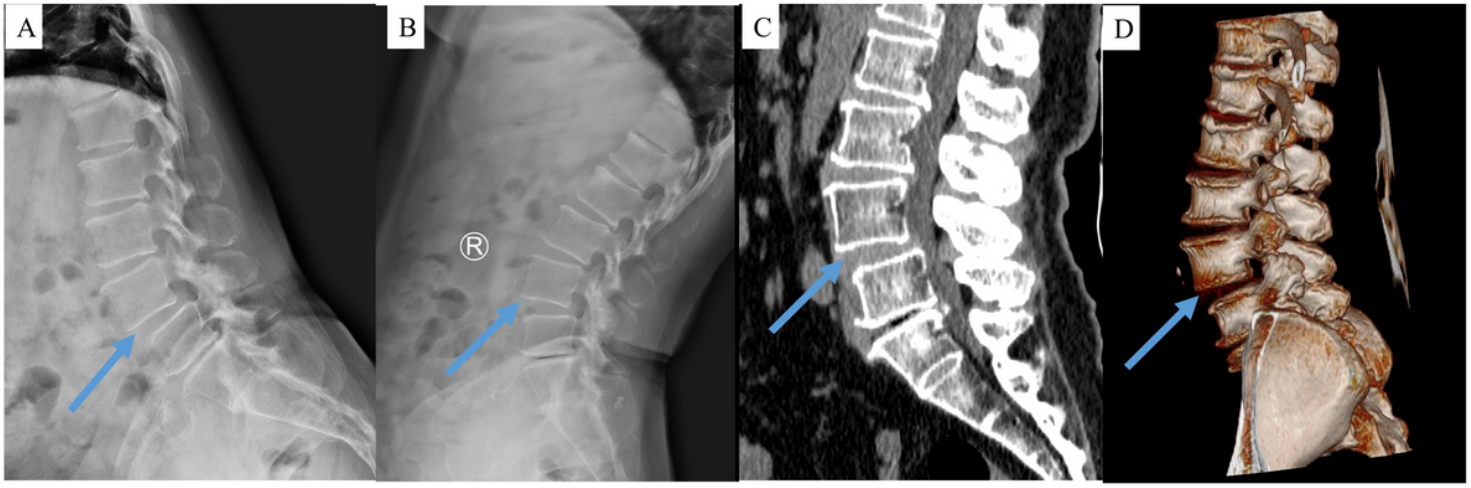

Figure 1

Image of L4/5 spondylolisthesis in a 65-year-old woman. (A-B) X-ray and (C-D) CT images show that the L4/5 vertebral body has slipped forward.

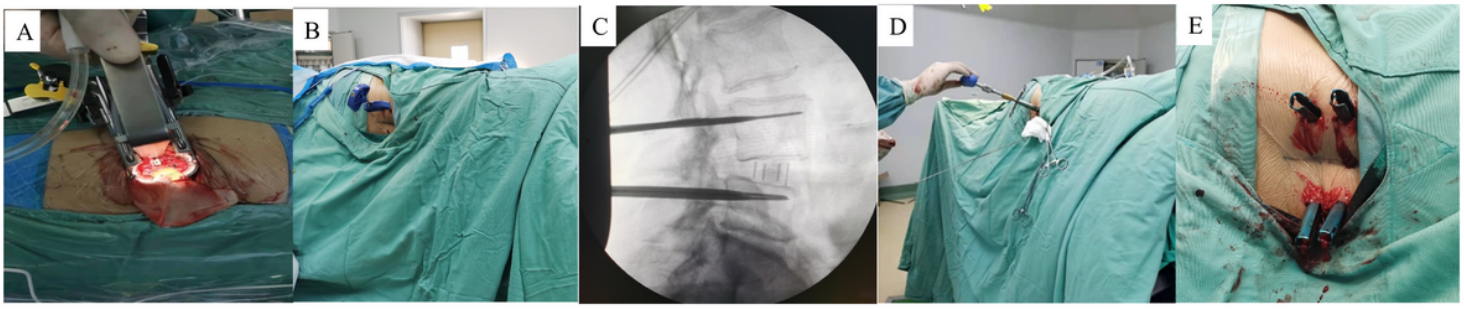

Figure 2

Surgical procedure for single-position OLIF. (A) Establish OLIF channel and place cage. (B) Place puncture needle in the lateral position by "freehand". (C) Verification of whether the guidewire positioning is satisfactory by fluoroscopy. (D) Pedicle screw placement. (E) Installation of the pedicle screw system.

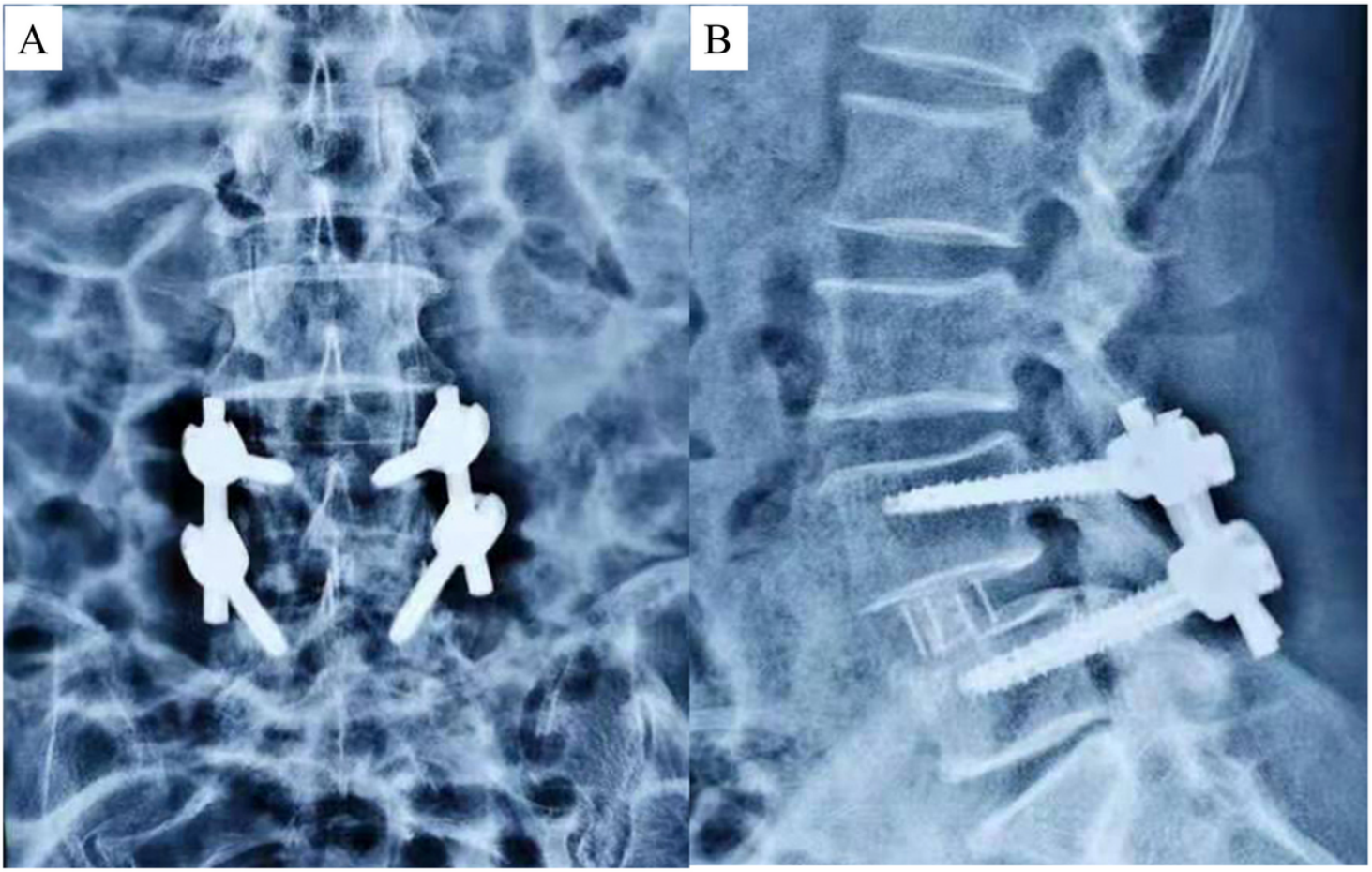

Figure 3

Anterior and lateral radiographs of a patient at 3 months postoperatively.