Transumbilical single-site laparoscopic pyloromyotomy for pediatric hypertrophic pyloric stenosis

Yi Ji
West China Hospital of Sichuan University
Xiaoqin Lai
West China Hospital of Sichuan University
Zhicheng Xu (xzcxewk@163.com)
West China Hospital of Sichuan University

Research Article

Keywords: Hypertrophic pyloric stenosis, Transumbilical laparoscopic pyloromyotomy, Minimally invasive method, Children, Follow-up

Posted Date: April 5th, 2022

DOI: https://doi.org/10.21203/rs.3.rs-1506131/v1

Abstract

Purpose

A new novel technique for the treatment of pediatric hypertrophic pyloric stenosis (HPS), transumbilical single-site laparoscopic pyloromyotomy with a single instrument (TUSSLP), was introduced. TUSSLP was compared with the trans-abdominal three-site laparoscopic pyloromyotomy (TATSLP) procedure.

Methods

Patients with HPS who underwent TUSSLP and TATSLP between January 2016 and September 2020 were assigned to group A and group B, respectively. The data of perioperative clinical characteristics and postoperative follow-up results were retrospectively analysed and compared between the 2 groups.

Results

Sixty-four patients were enrolled in this study. Of these patients, 29 (22 males, 7 females, 54.4±22.6 d) who received TUSSLP were assigned to group A. The remaining 35 (28 males, 7 females, 54.5±27.6 d) who received TATSLP were assigned to group B. The data of preoperative patient variables were comparable between the 2 groups (P>0.05). The mean operative time (ORT) was 28.1±5.6 min in group A, which was not significantly different from 25.8±3.1 min in group B (P=0.25). The other perioperative features were not significantly different between the 2 groups (P>0.05). During follow-up (39.1±14.7 m in group A and 35.4±16.1 m in group B, P=0.51), no significant difference was observed in the overall incidence of vomiting between the 2 groups (P=0.26).

Conclusions

TUSSLP is a feasible and reliable minimally invasive method for HPS. It has the advantages of an improved cosmetic appearance. The postoperative follow-up results of TUSSLP are comparable with those of TATSLP.

Contribution To The Field Statement

Infantile hypertrophic pyloric stenosis (HPS) is a common cause of vomiting during the neonatal period. HPS has an incidence of approximately 2/1000 live births. With the advancement of laparoscopic instrumentation for infants, laparoscopic pyloromyotomy has gained popularity. In this study, we presented our first 29 cases of HPS who underwent transumbilical single-site laparoscopic pyloromyotomy with a single instrument (TUSSLP). We interpreted its technical challenges and solutions. We found that TUSSLP was a feasible and reliable minimally invasive method for HPS. TUSSLP had the advantages of an improved cosmetic appearance. The postoperative follow-up results of TUSSLP were comparable with those of the trans-abdominal three-site laparoscopic pyloromyotomy procedure.

Introduction

Infantile hypertrophic pyloric stenosis (HPS) is a common cause of vomiting during the neonatal period, with an incidence of approximately 2 per 1000 live births[1]. The first laparoscopic pyloromyotomy (LP) procedure was reported in 1990 by Alain et al[2]. With the advancement of laparoscopic instrumentation for infants, this technique has gained popularity[3-7]. However, placing three trocars through a small umbilicus can have the disadvantage of conflicting instruments, so only a few pediatric centers can handle this technique[8, 9]. Since January 2017, we have attempted a novel procedure of transumbilical single-site laparoscopic pyloromyotomy with a single instrument (TUSSLP) through only two incisions around the umbilical ring. In this report, we described the distinct features of TUSSLP.

Materials And Method

Design and study population

This was a retrospective study of patients with HPS who underwent TUSSLP and transabdominal three-site laparoscopic pyloromyotomy (TATSLP) between January 2016 and September 2020. Approval was obtained from the West China Hospital of Sichuan University Institutional Review Board (NO. 2016-118). All procedures followed the research protocols approved by Sichuan University and West China Hospital of Sichuan University and was conducted according to the Declaration of Helsinki. Written informed consent was provided by the patients' parents for their clinical records to be used in this study.

The diagnosis of HPS was based on the history, palpation of a hypertrophied pyloric muscle and ultrasonography. Patients' parents were given the option to choose the treatment (either TUSSLP or TATSLP). The cases with comorbidities and failed follow-up were excluded from this study. The patients receiving TUSSLP who had TATSLP were assigned to group A and group B. The data of perioperative patient characteristics and postoperative follow-up results were retrospectively analysed and compared between the 2 groups (Figure 1).

Surgical Technique

The TUSSLP procedure

In the TUSSLP procedure, the patient was placed in a supine position with a monitor at the patient's head. The operator stood on the left side of the patient's feet, and the camera assistant stood on the other side. A 5 mm incision was made through the right rim of the umbilical ring with the open Hasson technique to establish the pneumoperitoneum at a pressure of 6–8 mmHg with a flow rate of 3-6 L/min. A 5 mm incision was made at the right rim of the umbilical ring for a 5 mm trocar and a 30° laparoscope. The second 3 mm incision was made at the left rim of the umbilical ring for a 3 mm trocar and the related 3 mm instruments. (Figure 2). Laparoscopy was started by inspection of the pyloric olivary mass and further confirmed the diagnosis. The nonvascular area on the anterior wall of the pyloric tube was cut longitudinally with a monopolar electric hook through the 3 mm trocar at the left rim of the umbilical ring. Then, 3 mm Maryland forceps were used to fully divide the wound of pyloric muscle to make the mucous membrane completely bulge (Figure 3). Fifty milliliters of air was slowly injected into the gastric tube, and

a few drops of saline were poured through the port to check for any inadvertent mucosal injury. If not, the air was evacuated. The incisions on the bilateral umbilical rim were closed with 5-0 absorbable thread (Figure 4).

The procedure of TATSLP

In the TATSLP procedure, the patient position was the same as that in the TUSSLP procedure. A 3 mm incision was made through the center of the umbilicus with the open Hasson technique to establish the pneumoperitoneum at a pressure of 6–8 mmHg with a flow rate of 3-6 L/min. A 5 mm trocar and a 30° laparoscope were introduced into the peritoneal cavity. Under laparoscopy, the two 3 mm trocars were placed in the bilateral upper quadrant of the abdominal wall. Laparoscopy was started by inspection of the pyloric olivary mass and confirmed the diagnosis. From the end of the duodenum to the stomach, the nonvascular area on the anterior wall of the pyloric tube was cut longitudinally. Then, the Maryland forceps were used to fully separate the wound of pyloric muscle to make the mucous membrane completely bulge. The remaining surgical steps were the same as those in the TUSSLP procedure.

The postoperative feeding regimen

The protocol of the postoperative feeding regimen was the same for each group. Feeds were started at 8 hours postoperatively. The initial feeding was 20 mL of water; if this was well tolerated, the infant could have 50 mL 2 hours later and formula feeding 2 hours later. When vomiting occurred, the next feeding was omitted and was resumed 6 hours later at the same dose. The baby was adequately discharged after 24 h of ad libitum feeding. All episodes of vomiting were recorded.

Data Collection and Statistical Analysis

First, all patients were analysed for their perioperative clinical features by reviewing the medical charts. Second, the follow-up data were collected using a telephone questionnaire or the last visit to our outpatient clinic according to the medical files.

Student's *t* tests and chi-squared tests were used to compare continuous and categorical descriptive variables, respectively. The results are expressed as the mean and SD. The software applied for statistical calculation was IBM SPSS 22.0 for Windows 10.0 (IBM Corp.) A P value<0.05 was considered statistically significant.

Results

Data on perioperative patient characteristics

There were 74 patients with HPS who received TUSSLP or TATSLP between January 2016 and September 2020. Ten patients were excluded from the study. Of them, 7 patients had comorbidities (in the TUSSLP group, 3 patients had inguinal hernia and 1 patient had malrotation; in the TATSLP group, 2 patients had inguinal hernia and 1 patient had cryptorchidism), and 3 patients were lost to follow-up (1

patient in the TUSSLP group and 2 patients in the TATSLP group). The remaining 64 cases were enrolled in this study. Of them, 29 patients receiving TUSSLP were assigned to group A (22 males, 7 females, 54.4±22.6 d), and 35 patients receiving TATSLP were assigned to group B (28 males, 7 females, 52.5±27.6 d). The preoperative patient variables, including age, sex, weight, pyloric muscle thickness and length measured by ultrasonography, and the duration of symptoms were not significantly different between the 2 groups (P>0.05) (Table 1).

During the operation, most patients did well in both groups. There was 1 case in group A and 2 cases in group B switched to conventional pyloromyotomy. The ORT was 28.1±5.6 min in group A, which was not significantly different from 25.8±3.1 min in group B (P=0.25). The other perioperative patient characteristics, including duration of anesthesia, intraoperative complications (mucosal perforation, duodenal injury), postoperative complications (wound infection, wound dehiscence, revision of pyloromyotomy, time to full feeding, and postoperative length of stay, were not significantly different between the 2 groups (P>0.05) (Table 2).

Postoperative results

The response rate for the telephone questionnaire or clinic interview for the patients enrolled in this study was 95.5%, including 29/30 patients in group A (96.7%) and 35/37 patients in group B (94.6%). The data of 3 patients (1 after TUSSLP, 2 after TATSLP) who had incorrect phone numbers or no family member was contactable for the telephone or clinic interview were not collected.

The follow-up time was 39.1±14.7 months in group A and 35.4±16.1 months in group B (P=0.51). The overall incidence of vomiting was not significantly different between the 2 groups (15 versus 23, P=0.26). All the vomiting symptoms of patients among the 2 groups disappeared after conservative treatment.

Discussion

With the emergence of scarless operations involving the abdominal wall, single-site umbilical LP has also been reported[9-12]. However, single-site umbilical laparoscopy is difficult to perform in newborns and has a high probability of severe complications, such as mucosal perforation and recurrent obstruction[13]. Therefore, a single site umbilical LP has not been greatly reported in recent years. Based on many years of experience with TATSLP, the TUSSLP procedure was developed to overcome many difficulties with transumbilical single-site LP. Here, we present our first 29 cases of HPS who underwent TUSSLP and interpret its technical challenges and solutions.

First, stable fixation and full exposure of the surgical field without instrument collision is a prerequisite for successful TUSSLP. We devised the procedure of transabdominal single-site LP through three incisions made around the umbilical ring. The lack of separation of the camera and instruments limited manoeuvrability in this single-site procedure. In addition, the camera and the two operating forceps parallel to the abdominal cavity could inevitably lead to obstruction of the instruments. Furthermore, the camera in line with the instruments could compromise the intracorporeal visualization of the surgical

field. Kozlov et al.[14] suggested that an endoscope longer than the other instruments could help the assistant's hands out of the operator working space, and the angulation of the optical axis of at least 30° provides an offset, rather than inline, view of the pylorus.

To resolve the problems above, we developed the TUSSLP procedure, in which the LP was performed through two incisions around the umbilical ring, one for a 5 mm trocar and laparoscopy and another for a 3 mm trocar and related single instrument, such as a laparoscopic needle holder, electric hook, pyloric knife, or Maryland forceps. The related laparoscopic instruments may be accessed directly into the perineal cavity through this 3 mm incision. The pyloric canal can be firmly secured and fully exposed by simultaneously tensioning both external thread ends at the left upper quadrant and right lower quadrant of the abdominal wall.

Second, another key to TUSSLP's success is to maintain a clear, bloodless surgical field during the procedure, as well as a large spatial dimension for surgical movements. Due to the traction of external threads on the upper left and lower right quadrants of the abdominal wall, the pyloric tube is lifted forwards. The gap between the abdominal wall and the anterior pyloric tube decreased. By pulling the 5 mm trocar and anchoring umbilical skin upwards to elevate the abdominal wall, the workspace can be expanded. In addition, the incision on pyloric tube with laparoscopic pyloric knife is not recommended because it is too sharp, sometimes will result in the bleeding from the pyloric muscle divided edge. In our experience, the initial cutting on the pyloric tube with a monopolar hook electrocautery, then the pyloric muscle is cleaved with 3 mm Maryland forceps, which could keep the surgical field clean and clear throughout the whole process of TUSSLP.

Third, the length of pyloric muscle separation will determine the effect of LP. The inappropriate length of the incision on the frontier wall of the pyloric canal, whether it is too long or too short, can lead to mucosal damage or incomplete pyloromyotomy[15, 16]. An adequate pyloromyotomy must balance the risk of mucosal perforation and incomplete myotomy, although an inability to palpate the divided pylorus will make the evaluation of these risks particularly challenging. Ostlie et al.[17] suggested that a split length of approximately 2 cm would ensure a complete pyloromyotomy. They also suggested that pyloromyotomy should be longer than the length of the pyloric channel measured by ultrasound[18]. We sought a more objective judgement for a complete myotomy, in which the length of myotomy measured is relatively simple. With the length of the Maryland forceps tip or electric hook tip as a gauge, it is possible to effectively estimate the length of the pyloromyotomy.

Based on the tips above, satisfactory TUSSLP results were achieved in our study. Our findings were consistent with other published series that reported an incidence of incomplete myotomy of 2% to 8%[5, 6, 15] and mucosal perforation of 1.3 to 5.0%[5, 19]. During the follow-up, the overall incidence of vomiting after TUSSLP was not significantly different from that after TATSLP. Nonetheless, the LP procedure does have a learning curve for novices[20-22], especially in the management of TUSSLP, and percutaneous pyloric tube suspension is performed using a needle holder alone without the aid of other

instruments. Thus, surgical teaching using simulators for residents or younger consultants is highly advisable, and it could in fact be deemed to be crucial for the safe performance of LP[23].

Limitations of the current study should be admitted. First, this was a retrospective study. Second, the 10 cases of HPS excluded from the study might reverse the results of the statistical comparison between the 2 groups. Although this study provided standard items for comparison between two procedures, it mostly affected comparison of the cosmetic, which resulted in favor of TUSSLP. Further studies on a larger number of cases may be required for more accurate conclusions.

Conclusion

We conclude that there are no differences between the TUSSLP and TATSLP techniques in terms of the ORT, perioperative complications, conversion to open pyloromyotomy, time to resumption of feeding, duration of hospitalization and postoperative follow-up results. Although TUSSLP surgery is complex and demanding, it is still regarded as a valid alternative to the classic TATSLP procedure with identical clinical results and better esthetic appearances for an experienced surgeon. The TUSSLP procedure is a feasible and reliable minimally invasive method for HPS in well-trained hands.

Declarations

Acknowledgement

None.

Fundings

This work was supported by the Key Project in the Science & Technology Program of Sichuan Province (grant number 2022YFS0233, 2022YFS0225 and 2019YFS0322), the Project of ‘0 to 1’ of Sichuan University (grant number 2022SCUH0033), and the 1·3·5 Project for Disciplines of Excellence Clinical Research Incubation Project, West China Hospital of Sichuan University (grant numbers 2019HXFH056, 2020HXFH048 and ZYJC21060).

Author contributions

ZCX designed the study. YJ, XQL and ZCX collected data and managed its quality. YJ, XQL and ZCX performed the statistical analysis and drafted the manuscript. All authors participated in data interpretation. YJ and ZCX contributed substantially to its revision. All authors read the manuscript carefully and approved the final version.

Ethics statement

The study involved human participants and was approved by the ethics committee of West China Hospital (NO. 2016-118). The study was conducted in accordance with the Declaration of Helsinki and

Good Clinical Practice guidelines. Parents of the enrolled children were informed about the study upon admission and provided written informed consent.

Consent to publish

Written informed consent for publication this study was obtained from the patients' parents. Copies of the signed informed consent forms are available for review by the Series Editor of BMC Pediatrics.

Availability of data and materials

The datasets used and/or analyzed during the current study available from the corresponding author on reasonable request.

Conflicts of interest

The authors have disclosed that they do not have any potential conflicts of interest.

References

1. Peeters B, Benninga MA, Hennekam RC: **Infantile hypertrophic pyloric stenosis–genetics and syndromes**. *Nat Rev Gastroenterol Hepatol* 2012, **9**(11):646-660.
2. Alain JL, Grousseau D, Terrier G: **Extra-mucosa pylorotomy by laparoscopy**. *Chir Pediatr* 1990, **31**(4-5):223-224.
3. Costanzo CM, Vinocur C, Berman L: **Postoperative outcomes of open versus laparoscopic pyloromyotomy for hypertrophic pyloric stenosis**. *J Surg Res* 2018, **224**:240-244.
4. Huang WH, Zhang QL, Chen L, Cui X, Wang YJ, Zhou CM: **The Safety and Effectiveness of Laparoscopic versus Open Surgery for Congenital Hypertrophic Pyloric Stenosis in Infants**. *Med Sci Monit* 2020, **26**:e921555.
5. Ismail I, Elsherbini R, Elsaied A, Aly K, Sheir H: **Laparoscopic vs. Open Pyloromyotomy in Treatment of Infantile Hypertrophic Pyloric Stenosis**. *Front Pediatr* 2020, **8**:426.
6. Kethman WC, Harris AHS, Hawn MT, Wall JK: **Trends and surgical outcomes of laparoscopic versus open pyloromyotomy**. *Surg Endosc* 2018, **32**(7):3380-3385.
7. Siddiqui S, Heidel RE, Angel CA, Kennedy AP, Jr.: **Pyloromyotomy: randomized control trial of laparoscopic vs open technique**. *J Pediatr Surg* 2012, **47**(1):93-98.
8. Muensterer OJ, Adibe OO, Harmon CM, Chong A, Hansen EN, Bartle D, Georgeson KE: **Single-incision laparoscopic pyloromyotomy: initial experience**. *Surg Endosc* 2010, **24**(7):1589-1593.
9. Yu LJ, Wu XJ, Mao SK, Li SM, Luo CF: **The Application of Pyloric chisel in the Treatment of Hypertrophic Pyloric Stenosis by Single-Site Umbilical Laparoscopic Pyloromyotomy**. *J Laparoendosc Adv Surg Tech A* 2019, **29**(2):282-285.
10. Li B, Chen WB, Wang SQ, Wang YB: **Single-site umbilical laparoscopic pyloromyotomy in neonates less than 21-day old**. *Surg Today* 2015, **45**(1):29-33.

11. Yu LJ, Su BL, Shan WY, Luo CF, Shu Q: **Single-Site Umbilical Laparoscopic Pyloromyotomy Using a Pyloric Electrocoagulation Chisel Combined with a Left-Handed Main Operation for Congenital Hypertrophic Pyloric Stenosis**. *J Laparoendosc Adv Surg Tech A* 2020, **30**(11):1248-1252.
12. Vahdad MR, Nissen M, Semaan A, Klein T, Palade E, Boemers T, Troebs RB, Cernaianu G: **Can a simplified algorithm prevent incomplete laparoscopic pyloromyotomy?** *J Pediatr Surg* 2015, **50**(9):1544-1548.
13. Muensterer OJ: **Single-incision pediatric Endosurgical (SIPES) versus conventional laparoscopic pyloromyotomy: a single-surgeon experience**. *J Gastrointest Surg* 2010, **14**(6):965-968.
14. Kozlov Y, Novogilov V, Podkamenev A, Rasputin A, Weber I, Solovjev A, Yurkov P: **Single-incision laparoscopic surgery for pyloric stenosis**. *Pediatr Surg Int* 2012, **28**(4):347-350.
15. Pogorelić Z, Zelić A, Jukić M, Llorente Muñoz CM: **The Safety and Effectiveness of Laparoscopic Pyloromyotomy Using 3-mm Electrocautery Hook versus Open Surgery for Treatment of Hypertrophic Pyloric Stenosis in Infants**. *Children (Basel)* 2021, **8**(8).
16. Sathya C, Wayne C, Gotsch A, Vincent J, Sullivan KJ, Nasr A: **Laparoscopic versus open pyloromyotomy in infants: a systematic review and meta-analysis**. *Pediatr Surg Int* 2017, **33**(3):325-333.
17. Ostlie DJ, Woodall CE, Wade KR, Snyder CL, Gittes GK, Sharp RJ, Andrews WS, Murphy JP, Holcomb GW: **An effective pyloromyotomy length in infants undergoing laparoscopic pyloromyotomy**. *Surgery* 2004, **136**(4):827-832.
18. St Peter SD, Ostlie DJ: **Pyloric stenosis: from a retrospective analysis to a prospective clinical trial - the impact on surgical outcomes**. *Curr Opin Pediatr* 2008, **20**(3):311-314.
19. Hall NJ, Eaton S, Seims A, Leys CM, Densmore JC, Calkins CM, Ostlie DJ, St Peter SD, Azizkhan RG, von Allmen D *et al*: **Risk of incomplete pyloromyotomy and mucosal perforation in open and laparoscopic pyloromyotomy**. *J Pediatr Surg* 2014, **49**(7):1083-1086.
20. Arul GS, Moni-Nwinia W, Soccorso G, Pachl M, Singh M, Jester I: **Getting it right first time: implementation of laparoscopic pyloromyotomy without a learning curve**. *Ann R Coll Surg Engl* 2021, **103**(2):130-133.
21. Binet A, Bastard F, Meignan P, Braïk K, Le Touze A, Villemagne T, Morel B, Robert M, Klipfel C, Lardy H: **Laparoscopic Pyloromyotomy: A Study of the Learning Curve**. *Eur J Pediatr Surg* 2018, **28**(3):238-242.
22. Kaba M, Karadag CA, Demir M, Sever N, Unal A, Akin M, Dokucu AI: **Our Experience with Laparoscopic Pyloromyotomy in Patients with Infantile Hypertrophic Pyloric Stenosis**. *Sisli Etfal Hastan Tip Bul* 2020, **54**(3):333-336.
23. Ballouhey Q, Micle L, Grosos C, Robert Y, Binet A, Arnaud A, Abbo O, Lardy H, Longis B, Bréaud J *et al*: **A Simulation Model to Support Laparoscopic Pyloromyotomy Teaching**. *J Laparoendosc Adv Surg Tech A* 2018, **28**(6):760-765.

Tables

Table 1. Preoperative patient characteristics

Characteristics	Group A (n = 29)	Group B (n=35)	*P*
Age (d)	54.4 ± 22.6	52.5 ± 27.6	.35
Sex (males)	22	28	.69
Weight (kg)	3.9 ± 0.6	4.1 ± 0.5	.84
Pyloric muscle thickness (mm)[a]	4.6 ± 1.0	4.2 ± 0.8	.25
Pylorus length (mm)[a]	20.8 ± 2.1	21.3 ± 2.3	.72
Chloride	103.1 ± 5.4	102.8 ± 7.1	.86
Bicarbonate	27.1 ± 4.3	26.7 ± 5.4	.73
Sodium	137.6 ± 3.2	139.1 ± 4.3	.56
Duration of symptoms (d)	10 (4-40)	9 (7-35)	.23

Quantitative data are expressed as the mean ± SD or median (25th-75th percentile), and categorical data are expressed as a number (percentage).

[a]Measured by ultrasonography.

Table 2. Intra- and postoperative patient characteristics

	Group A (n = 29)	Group B (n = 35)	*P*
Operative time (min)	28.1 ± 5.6	25.8 ± 3.1	.25
Duration of anesthesia (min)	95.3 ± 10.1	84.5 ± 5.9	.34
Intraoperative complications	1 (3.4%)	3 (8.6%)	.40
Mucosal perforation	1 (3.4%)	1 (2.9%)	.89
Duodenal injury	0 (0.0%)	2 (5.8%)	.19
Conversion	1 (3.4%)	1 (2.9)	.89
Postoperative complications	2 (6.8)	3 (8.6%)	.80
Wound infection	1 (3.4%)	2 (5.8%)	.67
Wound dehiscence	0 (0.0%)	1 (2.9%)	.36
Revision of pyloromyotomy	1 (3.4%)	2 (5.8%)	.67
Time to full feeding (h)	38.3 ± 5.6	34.5 ± 8.6	.59
Postoperative length of stay (d)	3.8 ± 1.2	3.6 ± 2.7	.65

Quantitative data are expressed as the mean ± SD, and categorical data are expressed as a number (percentage).

Figures

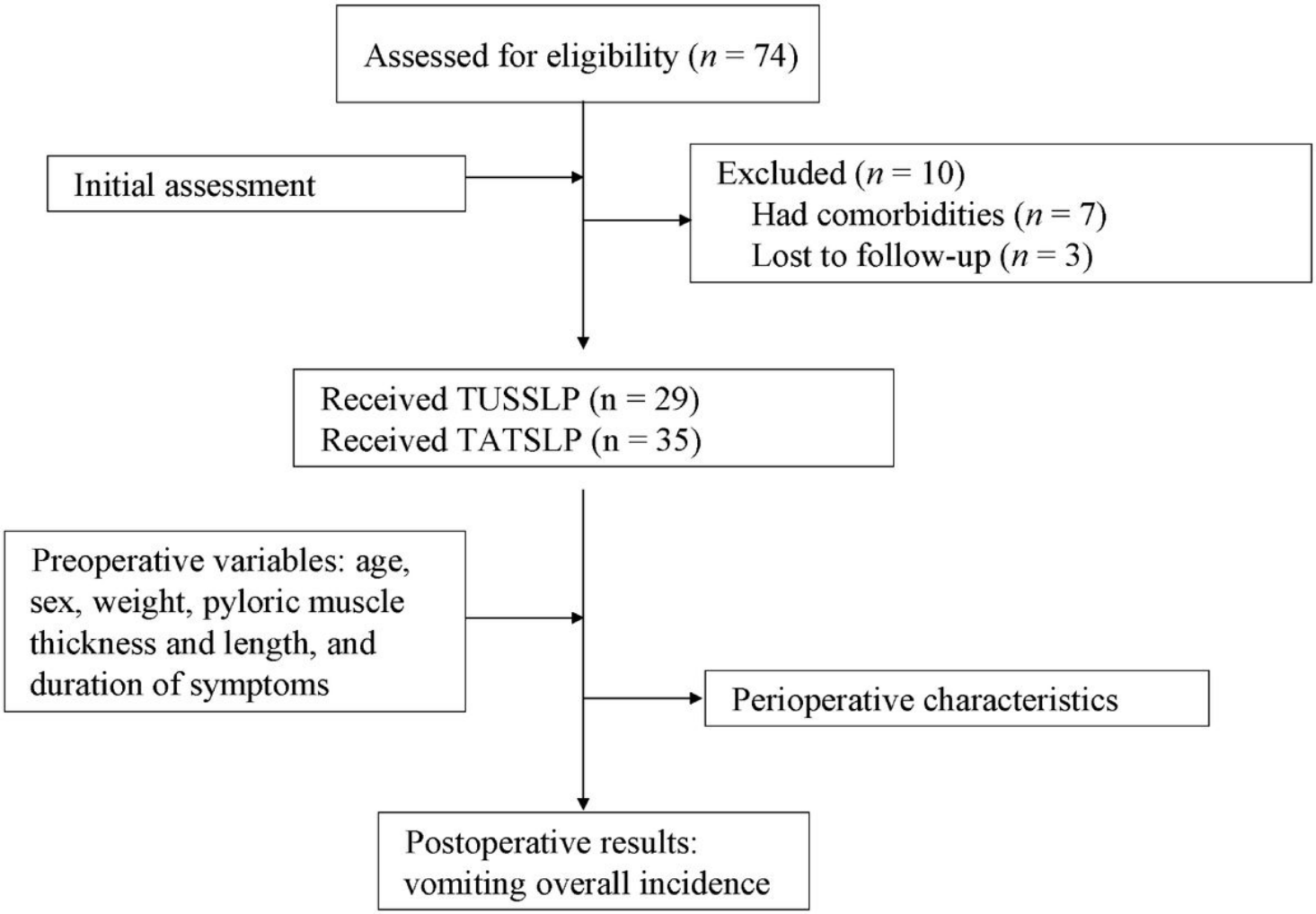

Figure 1

Study flowchart. TUSSLP: transumbilical single-site laparoscopic pyloromyotomy TATSLP: transabdominal three-site laparoscopic pyloromyotomy.

Figure 2

A 5 mm incision was made at the right rim of the umbilical ring for a 5 mm trocar and a 30° laparoscope. The second 3 mm incision was made at the left rim of the umbilical ring for a 3 mm trocar and the related 3 mm instruments.

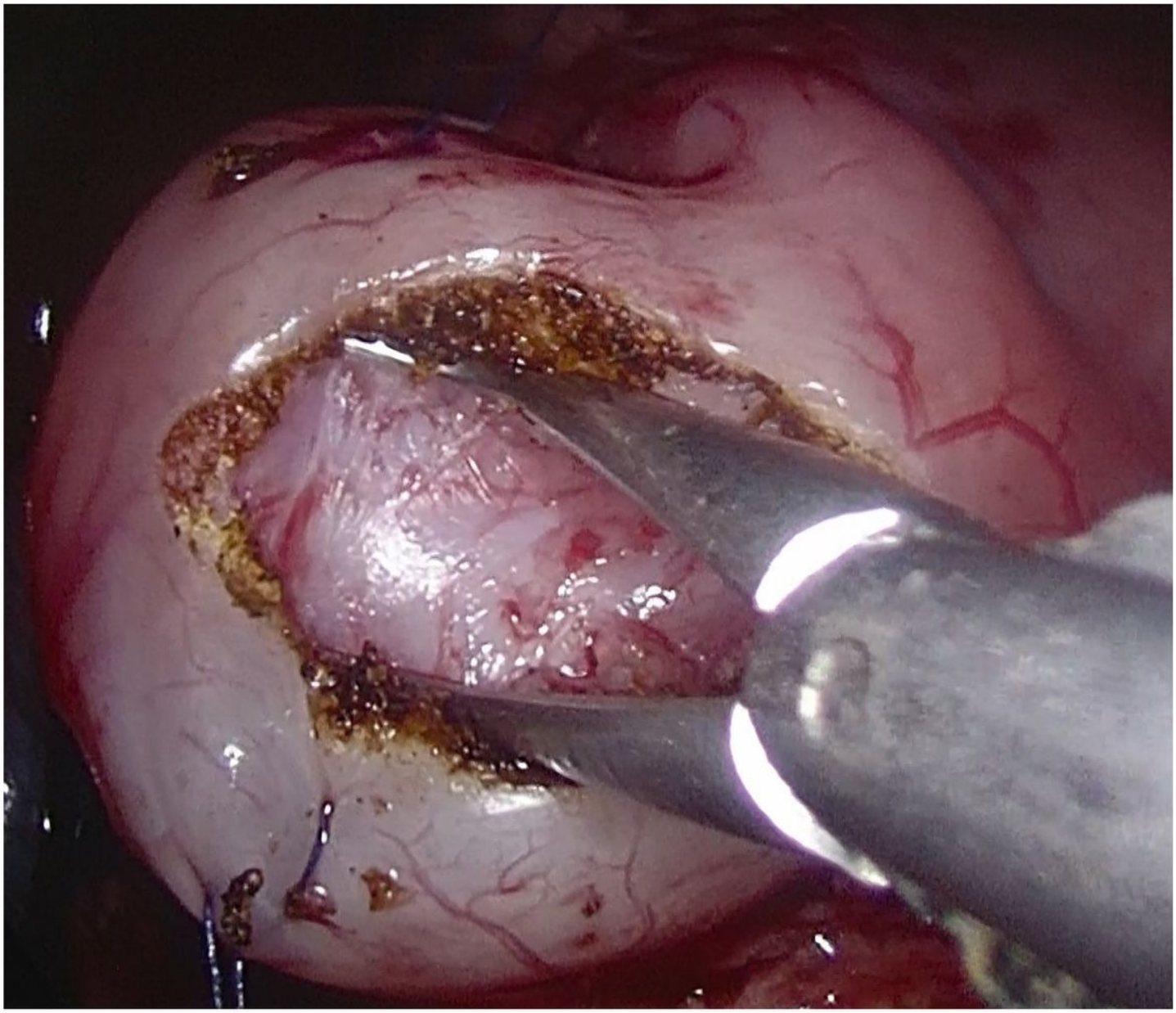

Figure 3

The Maryland forceps were used to divide the wound of pyloric muscle fully to make the mucous membrane completely bulge.

Figure 4

The two incisions (right 5 mm, left 3 mm) on the bilateral rim of the umbilical ring were closed with 5-0 Vicryl thread.