Long-term outcomes of tracheal stents removal under fluoroscopy guidance: comparison of tracheal fistulas with tracheal stenosis

Yonghua Bi
Zhengzhou University First Affiliated Hospital
Jianzhuang Li
Zhengzhou University First Affiliated Hospital
Liangliang Bai
Zhengzhou University First Affiliated Hospital
Gang Wu
Zhengzhou University First Affiliated Hospital
Xinwei Han (dreamweaver08@126.com)
Zhengzhou University First Affiliated Hospital https://orcid.org/0000-0002-8411-6427
Jianzhuang Ren
Zhengzhou University First Affiliated Hospital

Research article

Keywords: Respiratory Tract Fistula, Tracheal Stenosis, Stents, Fluoroscopy, Postoperative Complications, Device Removal

Posted Date: February 25th, 2020

DOI: https://doi.org/10.21203/rs.2.24504/v1

Version of Record: A version of this preprint was published on January 7th, 2021. See the published version at https://doi.org/10.1186/s12890-020-01349-7.

Abstract

Background: No study compared the techniques and complications of stent removal under fluoroscopy guidance for tracheal fistula and tracheal stenosis.

Methods: We conducted a retrospective analysis of 152 patients who underwent fluoroscopy-guided stent removal from January 2011 to June 2017. Eighty-five patients underwent stent removal for tracheal fistula (TF group), and 67 patients for tracheal stenosis (TS group). All patients underwent tracheal CT scans before stent removal and during follow up. The technical success rate, complications, survival rate were compared between the two groups.

Results: The technical success rate of stent removal was 98.9% and 97.4% for tracheal fistula and tracheal stenosis, respectively. Except for the routine removal for half of patients, excessive granulation tissue was the common indications for stent removal, which was found 142.1±25.9 days later for tracheal fistula, and 89.9±15.0 day for tracheal stenosis. The total incidence of complications was 21.1% and 22.4% for tracheal fistula and tracheal stenosis, respectively. One perioperative death of asphyxia was found in TF group, and 2 deaths in TS group. Recurrence of fistula or stenosis requiring stenting was the most comment complication in both groups. The 0.5-, 3-, 6-year survival rates were 90.3%, 59.6%, and 36.1% for TF group, and 80.4%, 75.7%, 75.7% for TS group.

Conclusions: Fluoroscopic removal of tracheal stent is safe and effective for both tracheal fistula and tracheal stenosis, with no significant difference. Recurrence of fistula or stenosis requiring stenting was the most comment complication.

Background

Tracheal fistula and/or tracheal stenosis are severe complications after open thoracic surgery, endotracheal intubation injury, endobronchial tuberculosis, and thoracic trauma [1]. These complications often show high mortality and disability rates; unfortunately, traditional conservative treatment shows a poor curative effect. Besides, some patients may not be willing to undergo open surgery considering that they are too weak or sick under this circumstance [2]. Since first adoption of self-expanding metal stents to treat bronchial obstruction in 1989 [3], the efficacy and safety of tracheal stent has been proven for the treatment of tracheal fistula [4-7] or tracheal stenosis [8-13]. However, tracheal stents placement may bring a series of complications, such as restenosis, migration, fracture, or mucous plugging [14], which make stent removal necessary. Endoscopic removal is the common method for removal of tracheal stents in literatures [15-20]. Few studies reported the technique of tracheal stent removal under fluoroscopy guidance [12, 21, 22]. Is fluoroscopic removal of tracheal stents safe and effective? How long the tracheal stent should be removed? Topics of ongoing investigation include the safety and efficacy of fluoroscopic stent removal as well as the optimal time interval of stent usage. We compared the outcomes of techniques and complications associated with fluoroscopy-guided removal of tracheal stents for tracheal fistula and tracheal stenosis.

Materials And Methods

Patients

This retrospective study was approved by the Ethics Committee and Medical Records Management Section of our University. All patients gave written informed consents. A total of 152 patients underwent fluoroscopy-guided stent removal from January 2011 to June 2017 in our department. Of which, 85 patients underwent stent removal for tracheal fistula (TF group), and 67 patients for tracheal stenosis (TS group). Following to the doctors' advices, more than 50% of patients underwent routine removal in both groups to avoid long-term complications even if they show no obvious symptoms or signs.

Tracheal stent

Tracheal stents were designed and manufactured according to individual tracheal shape and size measured by CT examination (Nanjing Micro-Tech Medical Company, Nanjing, China), and woven with a temperature-memory nickel–titanium alloy wire. All tracheal stents for fistula were fully covered in TF group, and 70 covered stents and 6 bare stents were used in TS group (Figure 1). Ninety tracheal stents were implanted in TF group, and large Y-shaped single-plugged tracheal stent was the most common type (32.2%). In TS group, 76 stents were implanted and the most common type was straight tracheal stent (73.7%).

Technical preparation before and after tracheal stent removal

Chest CT and bronchoscopy was performed on the day before stent removal. Patients' electrocardiogram, heart rate and blood pressure were routinely monitored during perioperative period. Oxygen was given by nasal catheter and a sputum aspirator was prepared. Ten mg of diazepam and anisodamine (654-2) was intramuscularly injected to calm the patient and to reduce tracheal secretions before stent removal. Ten mg of dexamethasone was injected to relieve dyspnea or to improve the tolerability if necessary. The sputum aspiration tube was then advanced into the tracheal for sputum drainage and to maintain tracheal patency. All patients were monitored by electrocardiogram, heart rate and blood pressure for at least 8 hours after stent removal.

Technical details of tracheal stent removal

A 5F catheter and 0.035inch hydrophilic guide wire (Cook Corporation, Bloomington, IN, USA) were inserted into the main bronchus under topical anesthesia by lidocaine. A 10-12F long sheath was inserted below the tracheal stent via a 0.035inch stiff hydrophilic guide wire. A removal hook was introduced slowly along the sheath with its tip placed next to the end of stent. The tracheal stent was hooked firmly and then withdrawn carefully (Figure 2). The radiography was performed again to show whether there was a overflow of contrast after stent removal.

Complications of stent removal and follow up

All complications of stent removal were recored and analyzed. Patients were followed up after stent removal, and chest CT scans were performed. Telephone follow-up was used for patients who did not come to the hospital for reexamination.

Statistical analysis

Data were expressed as mean ± standard deviation, and analyzed by student t test and ANOVA. Qualitative data were expressed in percentage, and analyzed by Fisher's exact test. Patency rate was compared by Log-rank (Mantel-Cox) Test (GraphPad Software, Inc., USA). Statistical significance was considered when $p<0.05$.

Results

Patient characteristics

Ninety covered tracheal stents were inserted in TF group and 76 tracheal stents were implanted in TS group. 81.2% of patients with tracheal fistulas were caused by malignancy disease in TF group, 82.1% of patients with tracheal stenosis were caused by benign primary disease in TS group. The success rate of stent removal was 98.9% (89/90) in TF group. Only one patient underwent bronchoscopic removal for the retained stent pieces after failure in fluoroscopic removal. In TS group, 74 of 76 tracheal stents were successfully removed, only 2 stents retained, with a technical success rate of 97.4% (74/76). The mean procedure time of stent implantation or removal was similar between two groups. Tumor invasion or tumor operation was the main causes for tracheal fistula, and tracheotomy or trachea cannula was the main causes for tracheal stenosis ($p < 0.0001$, Table 1).

Indications for stent removal and interval

Following to doctors' advices, 47 stents (52.2%) and 40 stents (52.6%) were routinely removed for tracheal fistula and tracheal stenosis, respectively. Stent migration and stent intolerance were the main indications for early stent removal in both groups. Excessive granulation tissue increased as time interval increased, with a mean interval of 142.1±25.9 days for tracheal fistula and 89.9±15.0 day for tracheal stenosis, which was the most common indications for later stent removal. Interestingly, tracheal stents were routinely removed after 107.8±9.8 days and 85.4±6.7 days in TF group and TS group, respectively (Table 2). These two time points are consistent, suggesting that the stent should be removed about 3 months after implantation to reduce the incidence of restenosis. Six bare stents were emergency implanted in TS group for sever tracheal stenosis, of which, 3 stents were removed and replaced by covered stents, with a mean duration of 8.7±3.2 days, and 1 stent was replaced by tracheal T tube.

Complications

The technical success rate of stent removal was 98.9% and 97.4% for tracheal fistula and tracheal stenosis, respectively. In TF group, 75 stents were removed in one piece; stent fracture and retained stent pieces was found in 14 and 1 stent. In TS group, 74 tracheal stents were successfully removed from, 5

stents showed strut fracture. Of which, 2 stents retained, and the 3 retained stent pieces were successfully removed by endoscopy; the remained 71 stents were removed in one piece (Table 3).

Recurrence of fistula or stenosis requiring stenting was the most comment complications in both groups. Two patients showed severe dyspne in each group and were endotracheal intubation and mechanical ventilation. Symptoms were relieved and the endotracheal tube was removed within 4 hours. Massive hemoptysis occurred in 2 cases during stent removal in TF group. One patient died of asphyxia caused by blood clogging, and bleeding ceased in the other patient after administration of pituitrin. Two patients died perioperatively in TS group, resulting in a clinical success rate of 94.7% (72/76). One patient with tracheal stenosis after resection of esophageal carcinoma died of massive hemoptysis 3 days after stent removal. The other patient died of respiratory failure 2 days after the second stent insertion.

Second stenting after removal

Eight stents were replaced immediately and 5 stents were replaced 5 to 9 days after removal in TF group. Replacements included Y-type tracheal stents (n=5), L-type tracheal stents (n=3), Y-shaped single-plugged stents (n=2), straight tracheal stents (n=2) and 1 combination of a large and a small Y-type tracheal stent. One patient required stenting due to proximal re-obstruction of the stent after removal of a straight tracheal stent, and the same size of straight tracheal stent was implanted immediately. In TS group, 20 tracheal stents (15 straight tracheal stents and 5 Y type tracheal stents) were implanted again after removal for replacement of bare stents (n=3), or due to restenosis (n=9), migration (n=3), inadequate expansion (n=3), and intolerance (n=2).

Follow up

All patients were followed up except for perioperative deaths. Five patients (6.0%) lost in TF group and 4 lost (6.2%) in TS group during follow up. Thirty-three patients were cured and 20 patients were improved in TF group. In TS group, 29 patients were cured and 20 patients were improved; six patients underwent tracheotomy and tracheal T tube implantation after stent removal. Twenty-four patients died in TF group, tumor progression was the most common cause of death. Besides, one died of respiratory failure due to asphyxia, and 2 patients died of massive hemoptysis and hematemesis (Table 4). The 0.5-, 3-, 6-year survival rates were 90.3%, 59.6%, and 36.1% for TF group, and 80.4%, 75.7%, 75.7% for TS group (Figure 3).

Discussion

Tracheal stent has been widely used clinically for the treatment of tracheal fistula [4-7] or tracheal stenosis [8-13]. However, tracheal stents placement may bring a series of complications, and stent removal sometimes is necessary [23]. Currently, tracheal stent is commonly removed under bronchoscopic guidance and general anesthesia [17, 24-27] or local anesthesia [28, 29]. Few studies reported fluoroscopic removal of tracheal stent [12, 21, 22], and no study compared the long-term

outcomes of techniques and complications associated with fluoroscopic removal of tracheal stents between tracheal fistula and tracheal stenosis.

In the present study, 97.4% of stents for tracheal stenosis were successfully removed under fluoroscopy guidance, which is higher than that of silicon stent removal in patients with tracheobronchial stenosis [30]. Additionally, 83.3% of stents were removed in one piece and only one stent showed retained stent pieces in this study. However, 73% of stents were removed piecemeal with rigid alligator forceps [24]. Our data indicate that fluoroscopic removal of tracheal stents is a feasible procedure for tracheal fistula and tracheal stenosis.

Although the process of fluoroscopic removal of tracheal stent is rapid, serious complications may occur during stent removal, such as massive bleeding, acute tracheal obstruction, and even death [24, 31, 32]. In our study, one patient died of asphyxia caused by blood clogging in TF group; one patient died of massive hemoptysis 3 days after stent removal, and the other patient died of respiratory failure in TS group. In addition, the total incidence of complications was 21.1% and 22.4% for tracheal fistula and tracheal stenosis, respectively. Compared with previous reports in rigid bronchoscopy [24, 25, 29, 31], we showed a lower rate of complication.

How long of indwelling interval suitable for stent removal in the treatment of tracheal disease is a problem worthy of investigation [25]. The incidence of stent restenosis induced by granulation tissue hyperplasia and stent fracture may increase as indwelling time increases [33-35], and may bring difficulty or failure of stent removal [28]. According to our findings, excessive granulation tissue was found 142.1±25.9 days later for tracheal fistula, and 89.9±15.0 day for tracheal stenosis. Interestingly, tracheal stents were routinely removed about 3 months after implantation in this study. A indwelling interval of 1 to 3 months should be recommended for stent removal to avoid long-term complications.

There are weaknesses in our study. This is a retrospective study conducted in a single center. We solely performed stent removal under fluoroscopy guidance, stents should be removed by variety of technologies including bronchoscopy.

Conclusions

Fluoroscopic removal of tracheal stent is safe and effective for both tracheal fistula and tracheal stenosis, with no significant difference. Recurrence of fistula or stenosis requiring stenting was the most comment complication.

Abbreviations

CT: computed tomography; TF: tracheal fistula; TS: tracheal stenosis

Declarations

Ethics approval and consent to participate

This study obtained approval from the institutional review board of Zhengzhou University First Affiliated Hospital to review and publish information obtained from patient records. Written informed consent was obtained from all patients.

Consent to publish

We informed each patient of the publication, which includes the individuals personal data in any form (including individual details, images, or videos), and obtained written informed consent.

Availability of data and materials

The datasets used and/or analyzed during the current study are available from the corresponding author on reasonable request.

Competing interests

The authors declare that they have no competing interests.

Funding

This work was supported by National Natural Science Foundation of China (Grant No. 81501569). No funding body participated in the design of the study and collection, analysis, and interpretation of data and in writing the manuscript.

Authors' contributions

BYH, LJD, HXW and RJZ designed study

BYH, LJD, BLL and WG performed study

BYH, LJD, BLL collected and analyzed data

All authors wrote the paper and finally approved of the version to be published.

Acknowledgements

Not applicable

References

1. Turk AE, Karanas YL, Cannon W, Chang J. Staged closure of complicated bronchopleural fistulas. Ann Plast Surg 2000; 45:560-564.

2. Fernando HC, Sherwood JT, Krimsky W. Endoscopic therapies and stents for benign airway disorders: where are we, and where are we heading? Ann Thorac Surg 2010; 89:S2183-2187.
3. Simonds AK, Irving JD, Clarke SW, Dick R. Use of expandable metal stents in the treatment of bronchial obstruction. Thorax 1989; 44:680-681.
4. Han X, Li L, Zhao Y, Liu C, Jiao D, Ren K, Wu G. Individualized airway-covered stent implantation therapy for thoracogastric airway fistula after esophagectomy. Surg Endosc 2017; 31:1713-1718.
5. Han X, Wu G, Li Y, Li M. A novel approach: treatment of bronchial stump fistula with a plugged, bullet-shaped, angled stent. Ann Thorac Surg 2006; 81:1867-1871.
6. Wu G, Li ZM, Han XW, Wang ZG, Lu HB, Zhu M, Ren KW. Right bronchopleural fistula treated with a novel, Y-shaped, single-plugged, covered, metallic airway stent. Acta Radiol 2013; 54:656-660.
7. Cui YF, Fu YF, Li DC, Xu H. Percutaneous recanalization for hepatic vein-type Budd-Chiari syndrome: long-term patency and survival. Hepatol Int 2016; 10:363-369.
8. Stockton PA, Ledson MJ, Hind CR, Walshaw MJ. Bronchoscopic insertion of Gianturco stents for the palliation of malignant lung disease: 10 year experience. Lung Cancer 2003; 42:113-117.
9. Prasad M, Bent JP, Ward RF, April MM. Endoscopically placed nitinol stents for pediatric tracheal obstruction. Int J Pediatr Otorhinolaryngol 2002; 66:155-160.
10. Han X, Al-Tariq Q, Zhao Y, Li L, Cheng Z, Wang H, Liu C, Jiao D, Wu G. Customized Hinged Covered Metallic Stents for the Treatment of Benign Main Bronchial Stenosis. Ann Thorac Surg 2017; 104:420-425.
11. Thornton RH, Gordon RL, Kerlan RK, LaBerge JM, Wilson MW, Wolanske KA, Gotway MB, Hastings GS, Golden JA. Outcomes of tracheobronchial stent placement for benign disease. Radiology 2006; 240:273-282.
12. Park JH, Kim PH, Shin JH, Tsauo J, Kim MT, Cho YC, Kim JH, Song HY. Removal of Retrievable Self-Expandable Metallic Tracheobronchial Stents: An 18-Year Experience in a Single Center. Cardiovasc Intervent Radiol 2016; 39:1611-1619.
13. Ma J, Han X, Wu G, Jiao D, Ren K, Bi Y. Outcomes of Temporary Partially Covered Stent Placement for Benign Tracheobronchial Stenosis. Cardiovasc Intervent Radiol 2016; 39:1144-1151.
14. Freitag L, Ernst A, Unger M, Kovitz K, Marquette CH. A proposed classification system of central airway stenosis. Eur Respir J 2007; 30:7-12.
15. Gaissert HA, Grillo HC, Wright CD, Donahue DM, Wain JC, Mathisen DJ. Complication of benign tracheobronchial strictures by self-expanding metal stents. J Thorac Cardiovasc Surg 2003; 126:744-747.
16. Miyazawa T, Yamakido M, Ikeda S, Furukawa K, Takiguchi Y, Tada H, Shirakusa T. Implantation of ultraflex nitinol stents in malignant tracheobronchial stenoses. Chest 2000; 118:959-965.
17. Filler RM, Forte V, Chait P. Tracheobronchial stenting for the treatment of airway obstruction. J Pediatr Surg 1998; 33:304-311.

18. Rousseau H, Dahan M, Lauque D, Carre P, Didier A, Bilbao I, Herrero J, Blancjouvant F, Joffre F. Self-expandable prostheses in the tracheobronchial tree. Radiology 1993; 188:199-203.
19. Nashef SA, Dromer C, Velly JF, Labrousse L, Couraud L. Expanding wire stents in benign tracheobronchial disease: indications and complications. Ann Thorac Surg 1992; 54:937-940.
20. Zakaluzny SA, Lane JD, Mair EA. Complications of tracheobronchial airway stents. Otolaryngol Head Neck Surg 2003; 128:478-488.
21. Kapoor BS, Rathmann G, Shrawny S, Dunitz J, Hunter D. Retrieving a malpositioned tracheobronchial stent utilizing Amplatz gooseneck snare: a case report. Cardiovasc Intervent Radiol 2004; 27:291-293.
22. Song HY, Shim TS, Kang SG, Jung GS, Lee DY, Kim TH, Park S, Ahn YM, Kim WS. Tracheobronchial strictures: treatment with a polyurethane-covered retrievable expandable nitinol stent–initial experience. Radiology 1999; 213:905-912.
23. Han XW, Wu G, Li YD, Zhang QX, Guan S, Ma N, Ma J. Overcoming the delivery limitation: results of an approach to implanting an integrated self-expanding Y-shaped metallic stent in the carina. J Vasc Interv Radiol 2008; 19:742-747.
24. Lunn W, Feller-Kopman D, Wahidi M, Ashiku S, Thurer R, Ernst A. Endoscopic removal of metallic airway stents. Chest 2005; 127:2106-2112.
25. Noppen M, Stratakos G, D'Haese J, Meysman M, Vinken W. Removal of covered self-expandable metallic airway stents in benign disorders: indications, technique, and outcomes. Chest 2005; 127:482-487.
26. Dooms C, De Keukeleire T, Janssens A, Carron K. Performance of fully covered self-expanding metallic stents in benign airway strictures. Respiration 2009; 77:420-426.
27. Chan AL, Juarez MM, Allen RP, Albertson TE. Do airway metallic stents for benign lesions confer too costly a benefit? BMC Pulm Med 2008; 8:7.
28. Chung FT, Chen GY, Chou CL, Chen HC, Yu CT, Kuo CH, Lin SM, Kuo HP. Remove airway ultraflex stents by flexible bronchoscope. Am J Med Sci 2012; 343:267-272.
29. Fruchter O, Raviv Y, Fox BD, Kramer MR. Removal of metallic tracheobronchial stents in lung transplantation with flexible bronchoscopy. J Cardiothorac Surg 2010; 5:72.
30. Verma A, Park HY, Lim SY, Um SW, Koh WJ, Suh GY, Chung MP, Kwon OJ, Kim H. Posttuberculosis tracheobronchial stenosis: use of CT to optimize the time of silicone stent removal. Radiology 2012; 263:562-568.
31. Gottlieb J, Fuehner T, Dierich M, Wiesner O, Simon AR, Welte T. Are metallic stents really safe? A long-term analysis in lung transplant recipients. Eur Respir J 2009; 34:1417-1422.
32. Murthy SC, Gildea TR, Mehta AC. Removal of self-expandable metallic stents: is it possible? Semin Respir Crit Care Med 2004; 25:381-385.
33. Chung FT, Lin SM, Chen HC, Chou CL, Yu CT, Liu CY, Wang CH, Lin HC, Huang CD, Kuo HP. Factors leading to tracheobronchial self-expandable metallic stent fracture. J Thorac Cardiovasc Surg 2008;

136:1328-1335.
34. Chung FT, Lin SM, Chou CL, Chen HC, Liu CY, Yu CT, Kuo HP. Factors Leading to Obstructive Granulation Tissue Formation after Ultraflex Stenting in Benign Tracheal Narrowing. Thorac Cardiovasc Surg 2010; 58:102-107.
35. Chung FT, Chen HC, Chou CL, Yu CT, Kuo CH, Kuo HP, Lin SM. An outcome analysis of self-expandable metallic stents in central airway obstruction: a cohort study. J Cardiothorac Surg 2011; 6:46.

Tables

Table 1. Patient characteristics

Characteristics	TF group	TS group	*p*
Patients, N	85	67	
Mean age (range), years.	54.9±1.3 (15-81)	51.1±2.2 (12-85)	0.1306
Male/female gender, N	72/13	39/28	0.0004
Malignancy/benign primary disease, N	69/16	12/55	< 0.0001
Procedure time of implantation	29.1±1.6 (10-53)	26.8±1.9 (9-60)	0.3598
Procedure time of stent removal	19.0±1.3	23.3±2.0	0.0715
Causes of disease, N (%)			
Tracheotomy/Trachea cannula	0 (0%)	32 (47.8%)	< 0.0001
Tumor invasion/Tumor operation	69 (81.2%)	12 (17.9%)	< 0.0001
External pressure	0 (0%)	7 (10.4%)	0.0027
Surgery for Inflammatory disease	9 (10.6%)	6 (9.0%)	0.7908
Tracheal stent implantation	0 (0%)	5 (7.5%)	0.0153
Tracheal mechanical injury or trauma	3 (3.5%)	3 (4.5%)	1.0000
Others	4 (4.7%)	2 (3.0%)	0.6947

N=number

Table 2. Indications of stent removal and interval

	TF group	TS group	*p*
Indications of removal, N (%)			
Routine removal	47 (52.2%)	40 (52.6%)	1.0000
Excessive granulation tissue	11 (12.2%)	15 (19.7%)	0.2041
Stent migration	12 (13.3%)	5 (6.6%)	0.2011
Intolerance of stenting	8 (8.9%)	6 (7.9%)	1.0000
Inadequate expansion and deformation	0 (0.0%)	5 (6.6%)	0.0187
Strut fracture	4 (4.4%)	1 (1.3%)	0.3764
Recurrence of fistula	8 (8.9%)	-	-
Replacement of bare stent	-	4 (5.3%)	-
Interval between placement and removal, days			
Routine removal	107.8±9.8	85.4±6.7	0.0703
Excessive granulation tissue	142.1±25.9	89.9±15.0	0.0744
Stent migration	20.2±8.1	27.0±19.2	0.7003
Intolerance of stenting	18.9±10.5	8.3±4.3	0.4256
Inadequate expansion and deformation	-	2.0±2.0	-
Strut fracture	97.0±14.8	105	-
Recurrence of fistula	60.6±36.7	-	-
Replacement of bare stent	-	8.7±3.2	-
Total (range)	89.5 ±8.3 (0-435)	68.1 ±6.1(0-221)	0.0439

Table 3. Complications of stent removal.

Complication	TF group	TS group	*p*
Recurrence requires stenting	13 (14.4%)	9 (11.8%)	0.6538
Y-type tracheal stent	6 (6.7%)	2 (2.6%)	0.2914
Straight tracheal stent	3 (3.3%)	7 (9.2%)	0.1886
L-type tracheal stent	3 (3.3%)	0 (0.0%)	0.2508
plugged bullet-shaped stent	1 (1.1%)	0 (0.0%)	1.0000
Strut fracture and residue	1 (1.1%)	5 (6.6%)	0.0944
Mucosal tear with massive bleeding	2 (2.2%)	1 (1.3%)	1.0000
Reobstruction requiring stenting	1 (1.1%)	0 (0.0%)	1.0000
Dyspne need for mechanical ventilation	2 (2.2%)	2 (2.6%)	1.0000
Total complications	19 (21.1%)	17 (22.4%)	0.8525

N=number

Table 4. Clinical efficacy and death evaluation during follow-up

	TF group	TS group	*p*
Loss of follow up	5/84 (6.0%)	4/65 (6.2%)	1.0000
Clinical efficacy evaluation, N (%)			
Cured	33 (39.3%)	29 (44.6%)	0.6154
Improved	20 (23.8%)	20 (30.8%)	0.3576
Invalid	2 (2.4%)	3 (4.6%)	0.6534
Death	24 (28.6%)	9 (13.8%)	0.0458
Causes of death, N (%)			
Tumor progression	21 (25.0%)	5 (7.7%)	0.0081
Asphyxia	1 (1.2%)	4 (6.2%)	0.1679
Massive bleeding	2 (2.4%)	0 (0.0%)	0.5048

N=number

Figures

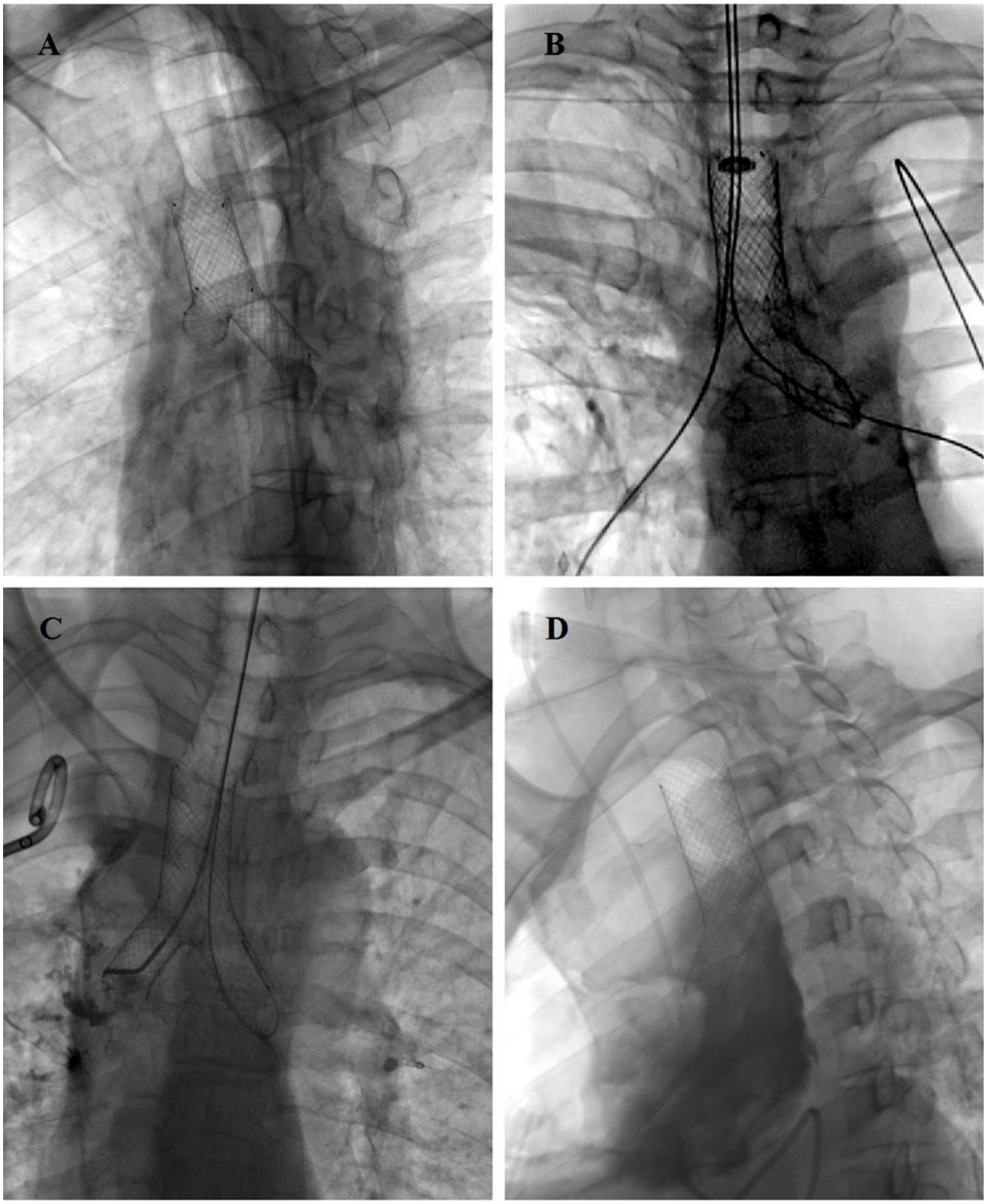

Figure 1

Types of individualized tracheal stents under fluoroscope. (A) Y-shaped single-plugged tracheal stent, (B) plugged bullet-shaped tracheal stent, (C) Y-type tracheal stent, (D) L-type tracheal stent.

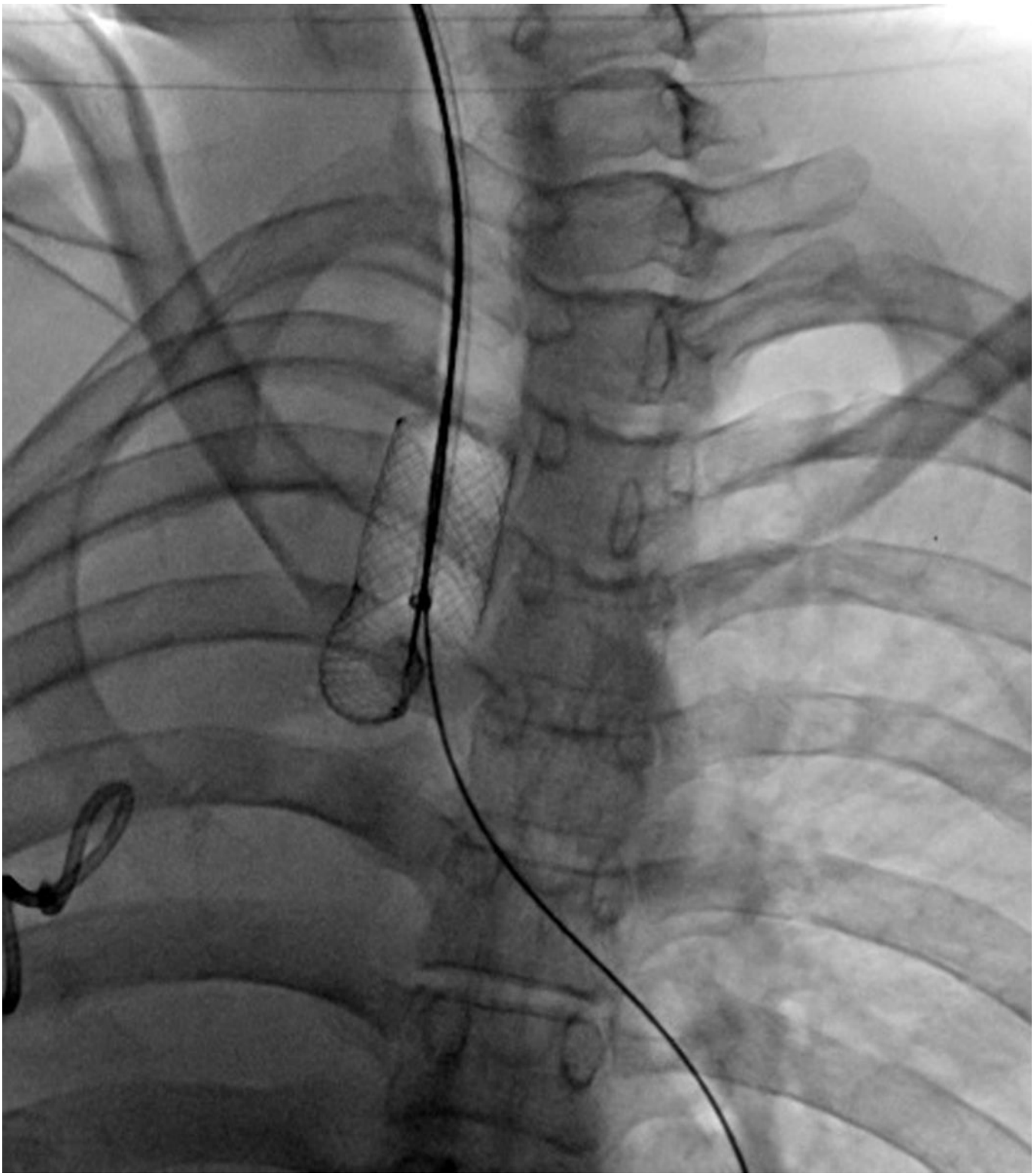

Figure 2

Technique of tracheal stent removal. A retrieval hook was inserted through a sheath and the tip of hook was placed next to the proximal end of the stent. The stent then was carefully dissected from the tracheal wall.

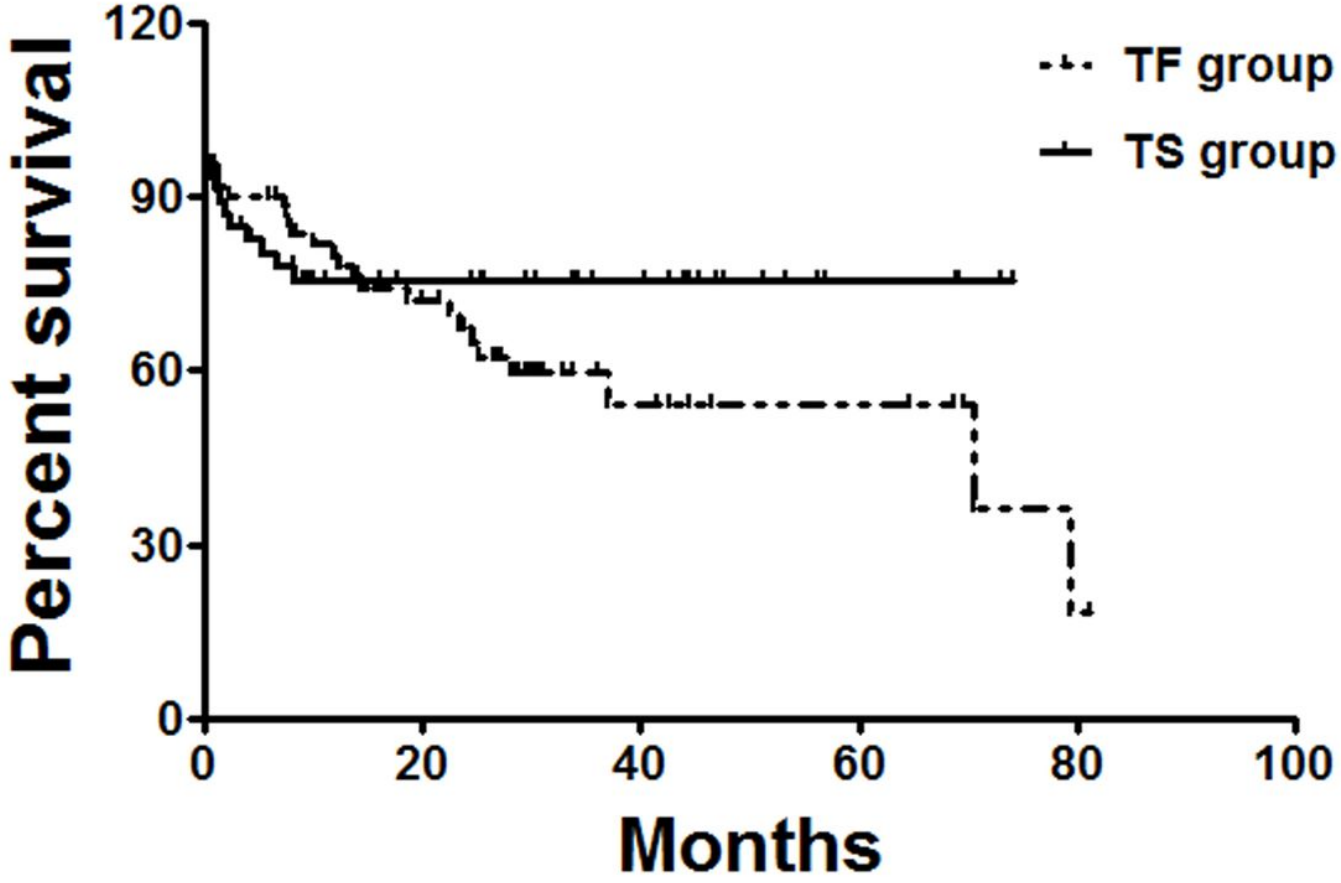

Figure 3

Survival rate follow up. The 0.5-, 3-, 6-year survival rates were 90.3%, 59.6%, and 36.1% for TF group, and 80.4%, 75.7%, 75.7% for TS group.