Application of Self-Pulling and Latter Transection in Totally Laparoscopic Total Gastrectomy

Yang Zhao
Ningxia Medical College: Ningxia Medical University
Zhi-Xia Bai
Ningxia Medical College: Ningxia Medical University
Tao Wang
Ningxia Medical College: Ningxia Medical University
Dong Song
Ningxia Medical College: Ningxia Medical University
Tao Li (litao2151@yeah.net)
Ningxia Medical College: Ningxia Medical University https://orcid.org/0000-0003-4854-4579

Research

Keywords: Totally laparoscopic total gastrectomy, Self-pulling latter transection, Gastric cancer, Laparoscopic-assisted gastrectomy

Posted Date: January 25th, 2021

DOI: https://doi.org/10.21203/rs.3.rs-150879/v1

Abstract

Background: To investigate the safety and efficacy of self-pulling and latter transection in totally laparoscopic total gastrectomy (SPLT-TLTG).

Methods: Eighty patients with gastric cancer who received either SPLT-TLTG or laparoscopic-assisted total gastrectomy (LATG) were enrolled for this study from January 2016 to June 2018. Clinical data including clinicopathologic parameters, postoperative conditions and long-term prognosis were collected and compared between patients received different types of surgeries.

Results: Compared to LATG, patients who received SPLT-TLTG surgery were associated with shorter operation time, less intraoperative blood loss and smaller incision lesion. In addition, patients who received SPLT-TLTG surgeries spent significantly less time in bed-rest post-surgically, to first bowel movement, hospital stay and before first oral food-intake ($P < 0.05$), as long as lower postoperative pain scores. However, no significant difference was observed between SPLT-TLTG and LATG surgeries in terms of how many lymph nodes (LNs) were retrieved during operation, as well as the overall incidence of postoperative complications ($P > 0.05$). **Conclusions**: This pilot study provided primary evidence for the application of self-pulling and latter transection in totally laparoscopic total gastrectomy in the treatment of gastric cancer.

Introduction

The gastric cancer (GC) is the second most popular and the third lethal cancer among all malignant tumors in China [1]. Despite improvements in early diagnosis and systemic therapy [2], gastrectomy is still recommended for patients with early and moderate stages of gastric cancer. Since the Laparoscopic gastrectomy (LG) was first performed on early gastric cancer in 1991[3], it has been welcomed worldwide due to the minimal lesion and limited blood loss. Generally, LG includes totally laparoscopic total gastrectomy (TLTG) and laparoscopic-assisted total gastrectomy (LATG). Compared with LATG, TLTG surgery is less invasive and requires shorter operation time, in addition to faster postoperative recovery and shorter hospital stay. However, the technique difficulties, especially during anastomose, impedes the wide use of this advanced surgery. A Chinese surgical team introduced a new anastomosis method, self-pulling and latter transection (SPLT) esophagojejunostomy after traction based on the overlap and functional end-to-end anastomosis (FETE) in TLTG [4] [5]. Their study indicated that SPLT is a simple and secure process that helped to apply TLTG surgery on patients with more advanced stages. Moreover, less than five endoscopic linear staplers is required for lesion closure in this procedure, demanding much less in both clinical costs and surgical skills [5]. However, no comparison between SPLT-TLTG and LATG surgeries have been conducted to the best of our knowledge.

In this study, we examined and compared the safety and efficacy between SPLT-TLTG and LATG surgeries in patients with GC.

Methods

1 Patients and methods

1.1 A total of eighty patients diagnosed with GC were retrospectively enrolled in this study from January 2016 to June 2018 at the Department of Oncology II, General Hospital of Ningxia Medical University, China. Among all patients, forty cases received SPLT-TLTG surgery and the other forty received LATG surgery, respectively.

1.2 Inclusion and exclusion criteria:

Inclusion criteria as 1) The diagnosis was made based on electronic gastroscopy examination and confirmed by pathological examinations.

Exclusion criteria as 1) Established distant metastasis 2) Patients who received neoadjuvant radiotherapy and chemotherapy before the operation; 3) History of surgical treatments for gastric cancer.

1.3 Surgical procedures

Firstly,patients were intubated under general anesthesia and maintained a modified lithotomy position. Five-hole Trocars were placed routinely at the preparatory stage. (Fig. A). Secondly, the liver, abdominal cavity, pelvic cavity and mesentery were examined carefully. Patients with distant metastasis and invasion of perigastric organs were exclude from further operation. Then laparoscopic gastrectomy (total gastrectomy + D2 lymph node dissection) was conducted. Thirdly, the esophagogastric junction was ligated with a sterilized rope in SPLT group to facilitate the traction of the esophagus. A small pinhole was made by ultrasonic scalpel on the right side of the esophagus, about 3cm above the ligation rope (Fig. B). Then the jejunum was lifted away for 30cm to ligament of the Treitz. Another 1cm pinhole was made at the mesenteric margin. A side-to-side esophagojejunostomy(E-J) was performed through these two holes (Fig. C) and the entry hole was closed with a linear stapler (Fig. D). Next, a side-to-side jejunojejunostomy was performed between the afferent loop stump and the roux limb 40cm below E-J, meanwhile another entry hole was formed and closed. A drainage tube near the upper abdominal duodenal stump was placed after anastomosis was conducted. The sample bag of the stomach was removed through a small incision in the navel (Fig. E).

LAG: laparoscopic gastrectomy was performed conventionally as introduced before. Briefly, 5cm incisions were made below the xiphoid process before the digestive tract reconstruction which was performed similarly as in open surgery (Fig. F).

1.4 Clinical parameters

Intraoperative and postoperative clinical parameters include total operation time, digestive tract reconstruction time, intraoperative blood loss, numbers of retrieved lymph nodes (LNs), postoperative off-bed activities time, time to first flatus, time to first oral food intake and total postoperative hospital stay were collected. Prognosis and complications include postoperative anastomotic leakage, anastomotic bleeding, anastomotic stricture, abdominal bleeding, intra-abdominal infection, disturbance of gastric emptying, pancreatic and biliary fistula were also collected.

Numerical rating scale (0–10) was employed to assess the postoperative pain: 0: no pain; 1–3: mild pain; 4–6: moderate pain; 7–10: severe pain. For moderate pain, oral clofenaceine tablets or paracetamol and oxycodone tablets were prescribed, and pethidine hydrochloride was prescribed for severe pain [6].

1.5 Follow up

All patients were followed up by outpatient clinic or telephone. Clinical parameters including imaging, blood routine test, serum biochemical test, tumor marker detection, abdominal CT and gastroscope were evaluated as appropriate.

1.6 Statistical analysis

All statistical calculations were conducted using Statistical Product and Service Solutions (SPSS) version 18.0 statistical software. Continuum data was described as means ± standard deviation and analyzed by Student t-test. Kaplan-Meier method was applied when depicting the survival curve. P values < 0.05 were considered as statistically significant.

Results

2.1 Patient demographics and pathologic findings

The baseline characteristics between two groups were comparable and no significant difference was identified. (Table 1)

Table 1
Patient demographics and Pathologic findings

Characteristics	SPLT(N = 40)	LAG(N = 40)	P value
Patient demographics			
gender(Male/Female)	19/21	20/20	0.823
Age	61.75 ± 8.61	61.35 ± 8.60	0.836
BMI	22.38 ± 3.27	22.69 ± 3.25	0.672
Pathologic findings			
T1/T2/T3/T4	11/7/16/6	9/14/10/7	0.262
N0/N1/N2/N3	19/12/6/3	13/12/11/4	0.586
TMN stage I/II/III/IV	15/17/8/0	12/15/13/0	0.438

2.2 Surgical outcomes

No significant difference in the numbers of retrieved LNs was identified between two groups. However, the operation time and digestive tract reconstruction time were significantly shorter in patients who received SPLT-TLTG group. In addition, patients in the SPLT-TLTG group suffered a smaller incision lesion than patients in the LATG group ($P < 0.05$). Moreover, the intraoperative blood loss was less severe in SPLT-TLTG group than in the LATG group. (Table 2).

Table 2
surgical outcomes

Surgical outcomes	SPLT(n=40)	LAG(n=40)	t	P
Operation duration (min)	234.2 ± 33.8	267.3 ± 28.7	-4.714	P<0.05
Anastomosis duration (min)	39.5 ± 6.8	44.5 ± 6.5	-3.377	P<0.05
Retrieved LNs (n)	26.8 ± 6.5	26.6 ± 6.5	0.086	P = 0.932
Blood loss (mL)	180.0 ± 58.3	223.8 ± 80.9	-2.776	P<0.05
Incision length(cm)	9.3 ± 2.3	13.85 ± 2.1	-9.098	P<0.05

2.3 Postoperative outcomes

Our results showed that patients who received SPLT-TLTG surgery covered faster than those who received LATG surgery. The time to off-bed rehabilitation, first flatus, first oral food intake and total postoperative hospital stay were significantly shorter in the SPLT-TLTG group than in LATG group ($P < 0.05$). Meanwhile, the average pains score was also decreased in the SPLT-TLTG group. (Table 3)

Table 3
postoperative outcomes

Postoperative outcomes	SPLT(n=40)	LAG(n=40)	t	P
Postoperative off-bed activities time (Days)	1.6 ± 0.6	2.9 ± 0.8	-8.459	P<0.05
Time to first flatus (Days)	4.2 ± 1.0	4.8 ± 0.7	-3.475	P<0.05
Postoperative hospital stay (Days)	8.3 ± 1.1	10.6 ± 1.5	-7.920	P<0.05
Postoperative time to first oral intake (Days)	5.7 ± 0.9	7.9 ± 1.0	-10.427	P<0.05
Postoperative Pain score	3.8 ± 0.7	5.8 ± 1.0	-10.181	P<0.05

2.4 Postoperative complications

There was no significant difference of postoperative complications between the 2 groups (P > 0.05). Among all patients, 2 cases of postoperative infection were reported in the laparoscopic assistant group and were successfully treated with third-generation cephalosporin antibiotics. Each group has 1 case of intra-peritoneal or digestive tract hemorrhage and was treated with hemostatic and somatostatin. Each group has 1 case of anastomotic fistula and was treated conservatively with food restriction, acid inhibition and parenteral nutrition. Two patients in the laparoscopic group had disturbance of gastric emptying and were treated with traditional Chinese medicine and acupuncture. No pancreatic fistula, biliary fistula and esophageal reflux was reported in the two groups. (Table 4)

Table 4
postoperative complications

Groups	Postoperative infection	Intra-peritoneal or digestive tract hemorrhage	Anastomotic fistula	Anastomotic stenosis	Disturbance of gastric emptying
SPLT(n=40)	0	1	1	0	0
LAG(n=40)	1	1	0	2	
P Value□c^2	c^2=1.127;p = 0.288				

2.5 Prognosis of the two Groups

No patient died during the 18 months follow-up period. The median recurrence time was 16 months in SPLT-TLTG group and 15 months in LATG group, which was not significantly different. (Fig. G)

Discussion

Due to the limit of current technique, it is important to develop a safer and more reliable digestive tract reconstruction method after total laparoscopic radical resection [7]. It has been known that Roux-en-Y anastomosis can effectively reduce the occurrence of reflux esophagitis and maintain good nutritional status and is currently the main reconstruction method [8]. This study examined the efficacy and safety of SPLT-TLTG surgery compared to conventional LATG surgery. Consistent with other studies [4–5, 9], our study suggested that SPLT-TLTG surgery has the advantages of minimally invasive, reduced bleeding and rapid postoperative recovery. Meanwhile, avoid squeezing tumor tissue during the operation, which diminishes the risk of rupture and dissemination of the tumor during the operation [9]. Furthermore, the SPLT-TLTG is more suitable for patients who are obese and have narrow rib arch [11]. This case-control study compared and analyzed the clinical data intraoperative and postoperative of SPLT-TLTG and LATG gastric cancer surgery, and our results are consistent with the findings that TLTG was safer and more beneficial to patients [10] [12]–[16]. Specifically, compared to LATG, the advantage of SPLT-TLTG surgery includes: (1) Better visualization during operation. The direct use of linear cutting suture device in anastomosis is more accurate and can prevent secondary injury, anastomotic stenosis and fistula induced by improper traction [17]. (2) The incision lesion is smaller compared to LATG surgery and does not require manual suture for lesion closure. (3) The operation process is less technique demanding. The procedure was completed under laparoscopic therefore has better visualization [18]. (4) The time to off-bed rehabilitation, first flatus, first oral food intake and total postoperative hospital stay were significantly shorter in patients who received SPLT-TLTG surgery (5) The SPLIT-TLTG surgery has a reliable safety profile partially due to the side-to-side esophagojejunostomy during operation is much safer than conventional round anastomosis [19][20]. Gong et al [21] suggested that linear stapler, but not circular stapler, should be used in TLTG surgery.

This study had several limitations. Firstly, the nature of the study was a retrospective analysis of prospectively collected data and might presented with some inherent biases. Secondly, the follow-up period was relatively short and long-term safety of this novel technique was not evaluated. Thirdly, other confounding factors that might exist in the baseline and affected the results. More studies include larger population are needed to better confirm the efficacy and safety profile of this novel technique.

Conclusions

In conclusion, SPLT Roux-en-Y anastomosis with totally laparoscopic total gastrectomy has the advantages of shorter operation duration, minimally invasive, quick recovery and shorter hospitalization time compared with laparoscopic assistance gastrectomy, which is worthy of clinical popularization and application.

Abbreviations

SPLT-TLTG (Self-pulling and latter transection in totally laparoscopic total gastrectomy); LATG (Laparoscopic-assisted total gastrectomy); LNs (Lymph nodes); GC (Gastric cancer) ; LG (Laparoscopic

gastrectomy); TLTG (Totally laparoscopic total gastrectomy); LATG (Laparoscopic-assisted total gastrectomy); FETE (functional end-to-end anastomosis); E-J(esophagojejunostomy); SPSS (Statistical Product and Service Solutions); BMI (Body Mass Index).

Declarations

Acknowledgements

Not applicable.

Availability of data and materials

All data generated and/or analyzed during this study are included in this article.

Authors' contributions

Yang Zhao and Tao Li performed the surgery. Dong Song and Tao Wang assisted in the surgery. Zhi-Xia Bai performed statistical analysis and assisted with drafting of the manuscript. Yang Zhao wrote the manuscript. All authors read and approved the final manuscript.

Ethics approval and consent to participate

Written informed consent was obtained from all patients for the use of their tissues for research purposes, and the study protocol was approved by General Hospital of Ningxia Medical University Ethics Committee (Yinchuan, China).

Funding

Supported by the Ethics Committee of General Hospital of Ningxia Medical University, and the First-Class Discipline Construction Founded Project of NingXia Medical University and the School of Clinical Medicine [Grant No. NXYLXK2017A05].

Patient consent for publication

Not applicable.

Competing interests

No potential conflict of interest relevant to this article was reported.

Consent for publication

I give my consent for information about my relative circle to be published in the World Journal of Surgical Oncology. I understand that the information will be published without my relative's (circle as appropriate) name attached, but that full anonymity cannot be guaranteed. I understand that the text and any pictures

or videos published in the article will be freely available on the internet and may be seen by the general public. The pictures, and text may also appear on other websites or in print, may be translated into other languages, or used for commercial purposes. I have been offered the opportunity to read the manuscript.

References

1. Bray F, Ferlay J, Soerjomataram I, Siegel RL, Torre LA, Jemal A. Global cancer statistics 2018: GLOBOCAN estimates of incidence and mortality worldwide for 36 cancers in 185 countries. CA Cancer J Clin. 2018 Nov;68(6):394–424. doi: 10.3322/caac.21492. Epub 2018 Sep 12. Erratum in: CA Cancer J Clin. 2020 Jul;70(4):313. PMID: 30207593.
2. Woo Y, Hyung WJ, Pak KH, Inaba K, Obama K, Choi SH, Noh SH. Robotic gastrectomy as an oncologically sound alternative to laparoscopic resections for the treatment of early-stage gastric cancers. Arch Surg. 2011 Sep;146(9):1086–92. doi:10.1001/archsurg.2011.114. Epub 2011 May 16. PMID: 21576595.
3. Kitano S, Iso Y, Moriyama M, Sugimachi K. Laparoscopy-assisted Billroth I gastrectomy. Surg Laparosc Endosc. 1994 Apr;4(2):146-8. Erratum in: Surg Laparosc Endosc. 2013 Oct;23(5):480. PMID: 8180768.
4. Hao H, Hong J, Wang Y, Wang J, Bei Y, Hua L. [Safety evaluation on initial 100 consecutive procedures of self-pulling and latter transected esophagojejunostomy]. Zhonghua Wei Chang Wai Ke Za Zhi. 2018 Feb 25;21(2):206–211. Chinese. PMID: 29492922.
5. Hong J, Wang YP, Wang J, Bei YB, Hua LC, Hao HK. A novel method of self-pulling and latter transected delta-shaped Billroth-I anastomosis in totally laparoscopic distal gastrectomy. Surg Endosc. 2017 Nov;31(11):4831. doi: 10.1007/s00464-017-5532-y. Epub 2017 Apr 13. PMID: 28409373.
6. Jin SJ, Park JY, Kim DH, Yoon SH, Kim E, Hwang JH, Song C, Kim YK. Comparison of postoperative pain between laparoscopic and robot-assisted partial nephrectomies for renal tumors: A propensity score matching analysis. Medicine. 2017 Jul;96(29):e7581. doi:10.1097/MD.0000000000007581. PMID: 28723795; PMCID: PMC5521935.
7. Zang L, Hu W, Zheng M. [Difficulty and skill of digestive tract reconstruction after totally laparoscopic total gastrectomy]. Zhonghua Wei Chang Wai Ke Za Zhi. 2014 Aug;17(8):747–9. Chinese. PMID: 25164885.
8. Matsuda T, Iwasaki T, Mitsutsuji M, Hirata K, Maekawa Y, Tsugawa D, Sugita Y, Shimada E, Kakeji Y. Surgical outcomes of intracorporeal circular-stapled esophagojejunostomy using modified over-and-over suture technique in laparoscopic total gastrectomy. Surg Endosc. 2015 Nov;29(11):3386–91. doi: 10.1007/s00464-015-4073-5. Epub 2015 Jan 29. PMID: 25631108.
9. Song KY, Park CH, Kang HC, Kim JJ, Park SM, Jun KH, Chin HM, Hur H. Is totally laparoscopic gastrectomy less invasive than laparoscopy-assisted gastrectomy? prospective, multicenter study. J Gastrointest Surg. 2008 Jun;12(6):1015–21. doi: 10.1007/s11605-008-0484-0. Epub 2008 Feb 7. PMID: 18256884.

10. Chen K, Mou YP, Xu XW, Pan Y, Zhou YC, Cai JQ, Huang CJ. Comparison of short-term surgical outcomes between totally laparoscopic and laparoscopic-assisted distal gastrectomy for gastric cancer: a 10-y single-center experience with meta-analysis. J Surg Res. 2015 Apr;194(2):367–374. doi: 10.1016/j.jss.2014.10.020. Epub 2014 Oct 22. PMID: 25488721.
11. Kim MG, Kim KC, Kim BS, Kim TH, Kim HS, Yook JH, Kim BS. A totally laparoscopic distal gastrectomy can be an effective way of performing laparoscopic gastrectomy in obese patients (body mass index ≥ 30). World J Surg. 2011 Jun;35(6):1327-32. doi: 10.1007/s00268-011-1034-6. PMID: 21424875.
12. Shinohara T, Kawano S, Tanaka Y, Fujisaki M, Watanabe A, Yamamoto K, Hanyu N. Comparison of the cost and outcomes following totally laparoscopic and laparoscopy-assisted distal gastrectomies for gastric cancer: a single-institution comparison. Surg Endosc. 2016 Aug;30(8):3573–81. doi:10.1007/s00464-015-4656-1. Epub 2015 Nov 5. PMID: 26541736.
13. Bracale U, Marzano E, Nastro P, Barone M, Cuccurullo D, Cutini G, Corcione F, Pignata G. Side-to-side esophagojejunostomy during totally laparoscopic total gastrectomy for malignant disease: a multicenter study. Surg Endosc. 2010 Oct;24(10):2475–9. doi:10.1007/s00464-010-0988-z. Epub 2010 Apr 16. PMID: 20396906.
14. Ikeda O, Sakaguchi Y, Aoki Y, Harimoto N, Taomoto J, Masuda T, Ohga T, Adachi E, Toh Y, Okamura T, Baba H. Advantages of totally laparoscopic distal gastrectomy over laparoscopically assisted distal gastrectomy for gastric cancer. Surg Endosc. 2009 Oct;23(10):2374-9. doi: 10.1007/s00464-009-0360-3. Epub 2009 Mar 5. PMID: 19263143.
15. Chen K, Pan Y, Cai JQ, Wu D, Yan JF, Chen DW, Yu HM, Wang XF. Totally laparoscopic versus laparoscopic-assisted total gastrectomy for upper and middle gastric cancer: a single-unit experience of 253 cases with meta-analysis. World J Surg Oncol. 2016 Mar 31; 14:96. doi: 10.1186/s12957-016-0860-2. PMID: 27036540; PMCID: PMC4815120.
16. Kim HB, Kim SM, Ha MH, Seo JE, Choi MG, Sohn TS, Bae JM, Kim S, Lee JH. Comparison of Reduced Port Totally Laparoscopic-assisted Total Gastrectomy (Duet TLTG) and Conventional Laparoscopic-assisted Total Gastrectomy. Surg Laparosc Endosc Percutan Tech. 2016 Dec;26(6): e132-e136. doi: 10.1097/SLE.0000000000000329. PMID: 27846181.
17. Kim HS, Kim MG, Kim BS, Lee IS, Lee S, Yook JH, Kim BS. Comparison of totally laparoscopic total gastrectomy and laparoscopic-assisted total gastrectomy methods for the surgical treatment of early gastric cancer near the gastroesophageal junction. J Laparoendosc Adv Surg Tech A. 2013 Mar;23(3):204–10. doi:10.1089/lap.2012.0393. Epub 2012 Dec 20. PMID: 23256584.
18. Wang S, Su ML, Liu Y, Huang ZP, Guo N, Chen TJ, Zou ZH. Efficacy of totally laparoscopic compared with laparoscopic-assisted total gastrectomy for gastric cancer: A meta-analysis. World J Clin Cases. 2020 Mar 6;8(5):900–911. doi: 10.12998/wjcc. v8.i5.900. PMID: 32190626; PMCID: PMC7062624.
19. Okabe H, Obama K, Tsunoda S, Tanaka E, Sakai Y. Advantage of completely laparoscopic gastrectomy with linear stapled reconstruction: a long-term follow-up study. Ann Surg. 2014 Jan;259(1):109 – 16. doi: 10.1097/SLA.0b013e31828dfa5d. PMID: 23549426.

20. Gong CS, Kim BS, Kim HS. Comparison of totally laparoscopic total gastrectomy using an endoscopic linear stapler with laparoscopic-assisted total gastrectomy using a circular stapler in patients with gastric cancer: A single-center experience. World J Gastroenterol. 2017 Dec 28;23(48):8553–8561. doi: 10.3748/wjg. v23.i48.8553. PMID: 29358863; PMCID: PMC5752715.
21. Gong CS, Kim BS, Kim HS. Comparison of totally laparoscopic total gastrectomy using an endoscopic linear stapler with laparoscopic-assisted total gastrectomy using a circular stapler in patients with gastric cancer: A single-center experience. World J Gastroenterol. 2017 Dec 28;23(48):8553–8561. doi: 10.3748/wjg. v23.i48.8553. PMID: 29358863; PMCID: PMC5752715.

Figures

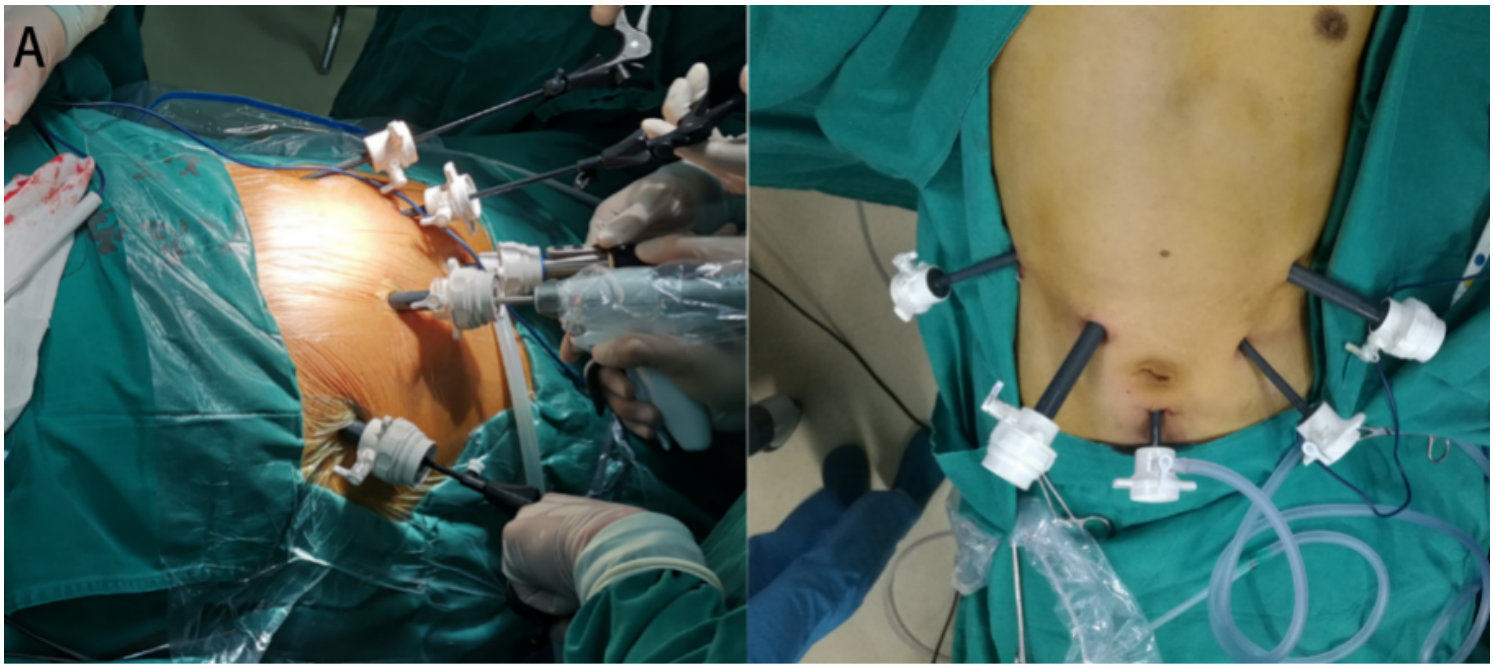

Figure 1

Placement of the trocars and Operation

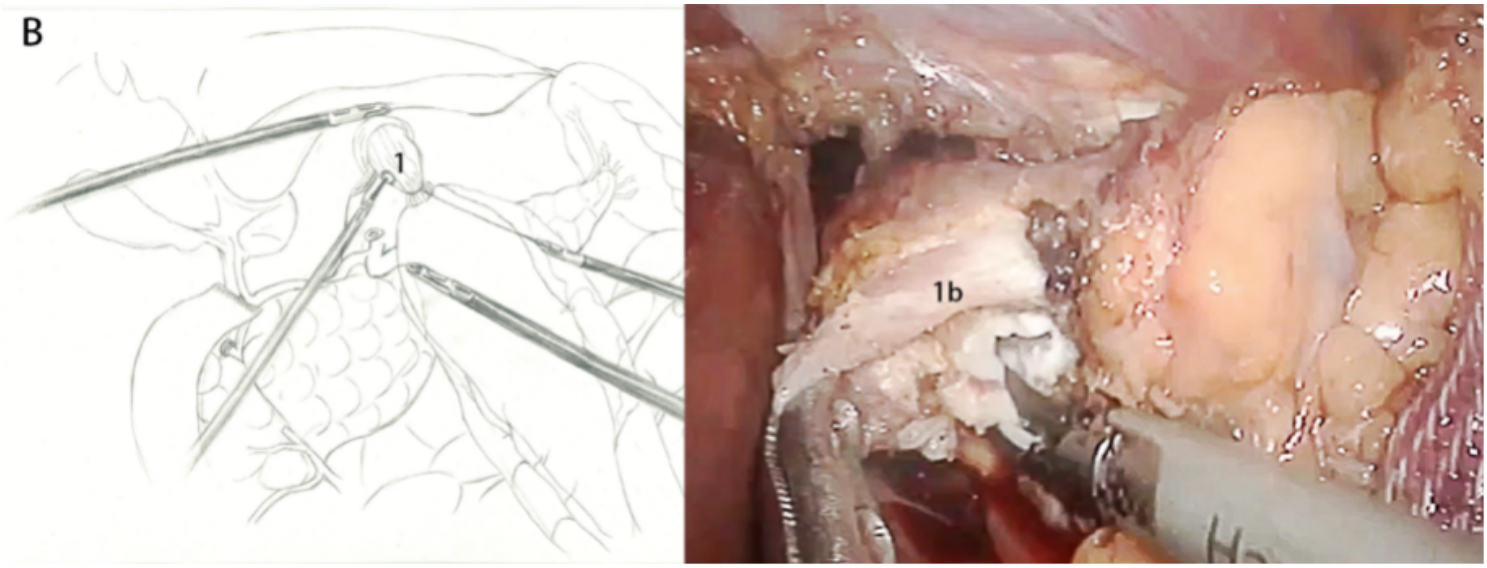

Figure 2

Make a hole in the posterior wall of the esophagus.

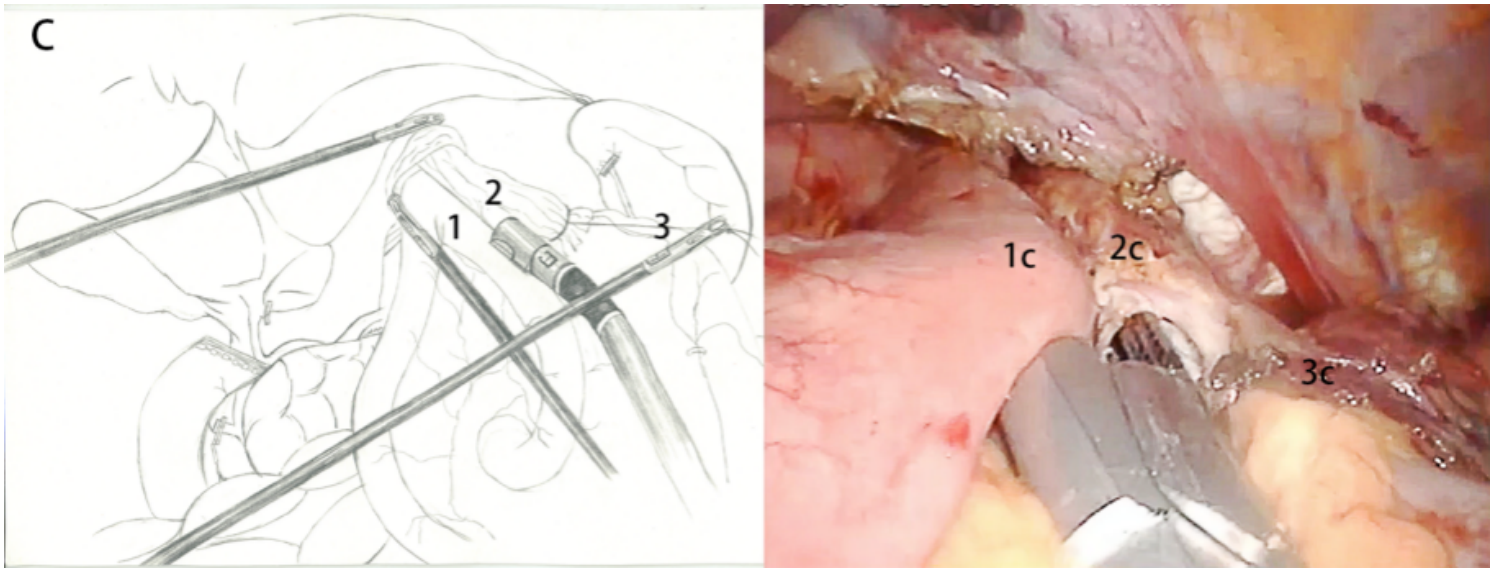

Figure 3

Esophagojejunostomy (E-J) is completed between the posterior wall of the esophagus and the anti-mesenteric border of the jejunum.

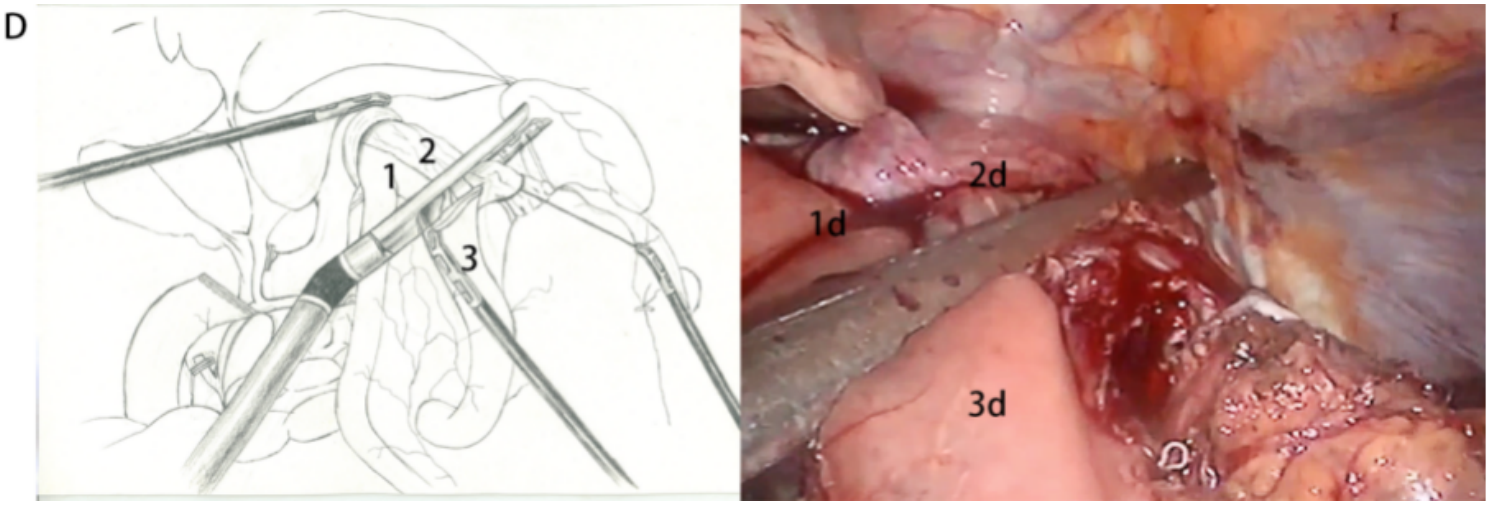

Figure 4

Closing the Esophagojejunostomy (E-J) entry hole.

Figure 5

An arc incision extended from the 5mm umbilical trocar site is made to remove the specimen.

Figure 6

laparoscopic-assisted gastrectomy (LAG).

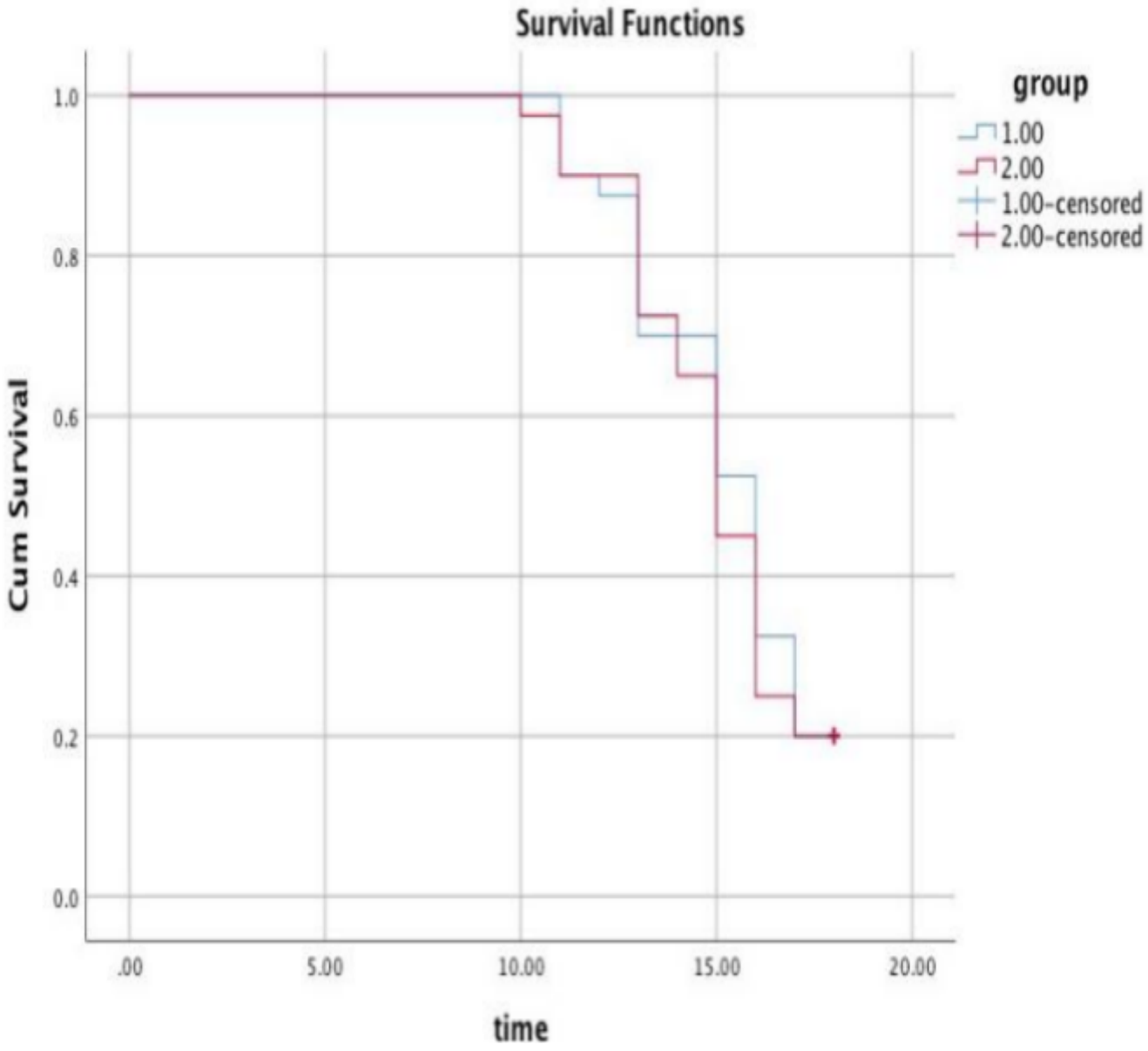

Figure 7

No patient died during the 18 months follow-up period.