Advantages and disadvantages of vitrectomy combined with cataract surgery in the treatment of patients with proliferative diabetic retinopathy: a meta-analysis

Bo Meng (mengbo-2007@163.com)
Beijing Friendship Hospital, Capital Medical University

Shuang Li
Beijing Friendship Hospital, Capital Medical University

Yingxiang Huang
Beijing Friendship Hospital, Capital Medical University

Kang Wang
Beijing Friendship Hospital, Capital Medical University

Lihua Luo
Beijing Friendship Hospital, Capital Medical University

Taoran Zhang
Beijing Friendship Hospital, Capital Medical University

Bojing Yan
Beijing Friendship Hospital, Capital Medical University

Lu Zhao
Beijing Friendship Hospital, Capital Medical University

Yanling Wang
Beijing Friendship Hospital, Capital Medical University

Research Article

Keywords:

Posted Date: April 4th, 2022

DOI: https://doi.org/10.21203/rs.3.rs-1512292/v1

Abstract

Purpose To evaluate the advantages and disadvantages of vitrectomy combined with cataract surgery compared with simple vitrectomy without cataract surgery in patients with proliferative diabetic retinopathy.

Methods PubMed, EMBASE, CBM, COCHRANE, CNKI, WANFANG and VIP databases were systematically reviewed. Complications include transient ocular hypertension, corneal edema, anterior chamber inflammation, posterior synechia of iris, iris neovascularization, posterior capsular opacification, recurrent vitreous hemorrhage, macular edema and hard exudate of retina.

Results Seventeen studies that included 1630 eyes were selected. The proportion of anterior chamber inflammation (OR = 2.15; P= 0.03) was higher in combined group than simple group. The proportions of iris neovascularization (OR = 0.40; P = 0.0002), vitreous hemorrhage (OR = 0.46; P = 0.02), macular edema (OR = 0.28; P = 0.007), hard exudation of retina (OR = 0.26; P = 0.004) and posterior capsular opacification (OR = 0.42; P = 0.006) were lower in combined group than simple group. The proportions of corneal edema, high intraocular pressure and iris synechia between two groups were similar.

Conclusion Vitrectomy combined with cataract surgery could reduce retinal ischemia related complications than simple vitrectomy at the cost of increasing anterior chamber inflammation. Combined surgery should be considered first after weighing the advantages and disadvantages.

Introduction

Diabetic retinopathy(DR) is a common complication of diabetic microangiopathy, and proliferative diabetic retinopathy(PDR) is the leading cause of blindness in diabetics. Hyperglycemia is an important pathological factor in the progression of diabetic retinopathy, which can damage the normal retinal vascular barrier, resulting in retinal vascular leakage and macular edema. And as the disease progresses, new blood vessels can be formed, which can lead to vitreous hemorrhage and/or tractional retinal detachment[1–4].

At present, PDR is mostly treated by pars plana vitrectomy(PPV). The purpose is to improve the vision and/or the quality of life of theses patients. It involves removing vitreous hemorrhage, tearing off the organic proliferative membrane, closing the retinal hole caused by traction, reattaching detached retina and filling silicone oil. The operation is complicated and there may be many complications after operation. In addition, most of PDR patients have cataract. Studies have confirmed that long-term hyperglycemia can cause lens metabolism disorder, leading to the production of cataract or promoting the progress of cataract. PPV and cataract surgery are performed by some surgeons in stages. But some surgeons advocate PPV combined with cataract surgery because they think the opacity of the lens often reduces the effect of PPV[5]. However, the prolonged operation time also increases the incidence of postoperative complications[6].

In summary, it is controversy whether the PPV is combined with cataract surgery in patients with PDR. So we carried out the systematic review to evaluate the advantages and disadvantages of combined operation in patients with PDR from the perspective of safety[7].

Methods

We conducted the meta-analysis following the recommendations of the Cochrane Handbook. This paper is reported following PRISMA's statement (see Supplemental Data File 1).

Literature search

We conducted a literature search on the safety of PPV combined with cataract surgery in the patients with PDR. Pubmed, Embase, Cochrane, CBM, Wanfang, CNKI and VIP databases were searched from the beginning to March 22, 2021. There is no language restrictions. Key words were used as free, truncated and thematic words. The detailed search strategy is shown

in Supplemental Data File 2. We searched the reference list of all retrieved articles manually to find articles that may meet the criteria.

The inclusion and exclusion criteria

All articles were screened by two people according to the pre-determined selection criteria. Any differences were discussed and settled by the two persons. The inclusion criteria are as follows: (1)randomized or non-randomized study to evaluate the proportion of postoperative complications between the combined and simple group of patients with PDR; (2)no less than one of the indicators of complications; (3)this analysis will include the most comprehensive version, if the research is repetitive. The e

xclusion criteria are as follows: case report, letter, editorial, non comparative study, animal study, single arm research, abstract and meeting minutes.

Data extraction

Data extraction from each paper was performed by two independent persons. Any differences would be discussed and resolved by this two one. Information extracted includes: the first author, the year of publication, the place of study, the time of follow-up, the number of eyes studied, the age of patients and the duration of diabetes.

Assessment of study quality

MINORS items were used to evaluate the quality of the literature. Two people used this to assess the quality in our study. Any differences were discussed and solved by the two. MINORS items includes: (1)clear research purpose; (2)inclusion of the consecutive patients; (3)prospective data collection; (4)endpoint appropriate to research purpose; (5)unbiased evaluation of the endpoint; (6)follow up period appropriate to primary endpoint; (7)loss of other bias during the follow-up was no more than 5%; (8)having gold standard intervention in the control group; (9) contemporary population; (10)baseline equivalence among groups; (11)prospective calculations of sample size; (12)adapted statistical analysis for research design.

Complication indicators of interest

The following complication indexes were used to compare the combined group (PPV combined with cataract surgery) and simple group (simple PPV without cataract surgery), which includes transient ocular hypertension, corneal edema, anterior chamber inflammation, posterior synechia of iris, iris neovascularization (NV), posterior capsular opacification, recurrent vitreous hemorrhage (VH), macular edema (ME) and hard exudate.

Statistical analysis

Revman 5.3 was used for data analysis. We used OR and 95% CI to analyze binary variables. Heterogeneity was evaluated by calculating I^2 and chi square test. $I^2 > 50\%$ and $P < 0.05$ showed significant heterogeneity. If there wasn't obvious heterogeneity, we used the fixed effect model. Otherwise, we used the random effect model. In addition, funnel plot was used to evaluate the publication bias.

Results

Identification of Eligible Studies

Initially, 300 articles were retrieved. However, most of these studies weren't suitable for the meta for all sorts of reasons, such as one arm study, repetitive studies and so on. In all, 283 articles were excluded according to the screening criteria. Finally, 17 studies were included in our analysis[6–22](Fig. 1).

Characteristics of included studies

A total of 1630 eyes were included, 873 eyes in combined group and 757 eyes in the simple group. The characteristics of studies are shown in the Table 1.

Table 1
Characteristics of included studies in the comparison of combined group and simple group

		Study	Follow-up	PPV Combined with Cataract Surgery			Simple PPV without Cataract Surgery			MINORS
Author	Year	Location	Time(m)	Eyes	Age(y)	Course of Diabetes(y)	Eyes	Age(y)	Course of Diabetes(y)	Score
Liu et al.	2007	China	6–18	33	45–68	NR	24	40–71	NR	19
Tseng et al.	2007	China	16	31	62.5 ± 8.2	NR	53	54.1 ± 11.35	NR	19
Park et al.	2009	Korea	2	30	58 ± 10	12.6 ± 4.3	30	57 ± 14	14.1 ± 5.2	19
Lee et al.	2012	Korea	3	207	53.3 ± 11	13.2 ± 7.9	95	55.4 ± 14.3	14.1 ± 7.6	17
Zhou et al.	2016	China	12–24	39	53.8 ± 3.6	NR	41	50.8 ± 3.1	NR	19
Jia et al.	2017	China	6–24	44	52.13 ± 2.09	12.69 ± 2.02	42	52.56 ± 2.45	12.57 ± 2.23	19
You et al.	2017	China	1	42	44.18 ± 14.91	NR	42	43.83 ± 14.69	NR	18
Zhao et al.	2018	China	6–24	41	53.3 ± 6.0	11.4 ± 3.7	42	54.5 ± 7.1	12.2 ± 4.1	19
Suo et al.	2019	China	NR	18	44.56 ± 3.45	NR	17	44.85 ± 3.25	NR	19
Huang et al.	2019	China	6–8	44	71.1 ± 2.99	11.28 ± 4.59	43	69.12 ± 2.05	10.97 ± 3.08	19
Zhang et al.	2019	China	12	30	53.6 ± 5.5	10.5 ± 3.7	30	52.4 ± 5.4	10.2 ± 3.5	19
Jiao et al.	2019	China	6	39	56.31 ± 5.1	8.83 ± 2.11	39	55.86 ± 4.97	8.83 ± 2.11	19
Hou et al.	2020	China	3	100	56.93 ± 10.84	7.23 ± 2.95	100	56.87 ± 10.93	7.31 ± 3.01	20
Zhang et al.	2020	China	3	40	57.8 ± 4.6	7.8 ± 1.5	40	57.3 ± 4.9	7.5 ± 1.8	19
Miao et al.	2020	China	3	50	62.4 ± 5.5	9.5 ± 2.6	50	62.6 ± 5.7	9.4 ± 2.8	19
Hu et al.	2020	China	NR	28	53.81 ± 4.88	9.86 ± 3.24	28	53.81 ± 4.88	9.86 ± 3.24	19
Hu et al.	2020	China	3–35	57	52-61.5	10-16.5	41	52-59.5	8–15	19
PPV: pars plana vitrectomy; NR: not reported.										

Quality assessment

Table 1 comprehensively lists the quality assessment of included studies.

Postoperative high intraocular pressure

The consolidated data from 7 studies[7, 14, 17–21] containing 765 eyes indicated that combined group had a similar proportion of postoperative high intraocular pressure than simple group (OR = 1.38, 95% CI: 0.82–2.31; $P = 0.23$). There was no significant difference between the two groups ($P = 0.56$, $I^2 = 0\%$) (Fig. 2A).

Postoperative corneal edema

The proportion of postoperative corneal edema was reported in 4 studies[7, 15, 17, 18] including 421 eyes in combined group compared with simple group. The statistical heterogeneity was observed between studies ($P = 0.13$, $I^2 = 47\%$). And fixed effect model showed that the incidence of corneal edema in combined group was close to that in the simple group (OR = 1.67, 95% CI: 0.85–3.27; $P = 0.13$) (Fig. 2B).

Anterior chamber inflammation

The proportion of anterior chamber inflammation was reported in 6 studies[7, 10, 11, 15, 18, 20] including 575 eyes in combined group compared with simple group. There was no statistical heterogeneity between studies ($P = 0.70$, $I^2 = 0\%$). Besides, fixed effect model showed that the incidence of anterior chamber inflammation in combined group was higher than that in simple group (OR = 2.15, 95% CI: 1.07–4.32; $P = 0.03$) (Fig. 2C).

Iris synechia

Patients in the combined group had a similar incidence of iris synechia than those in simple group (7 studies including 655 eyes)[7, 8, 10, 11, 15, 18, 20]. No significant heterogeneity was observed ($P = 0.23$, $I^2 = 27\%$). And fixed effect model showed that, the incidence of iris synechia in the combined group was close to the simple group (OR = 1.36, 95% CI: 0.72–2.60; $P = 0.35$) (Fig. 2D).

Iris neovascularization

The consolidated data from 11 studies[6–10, 12, 13, 15, 16, 18, 19] containing 959 eyes indicated that combined group had lower proportion of iris NV than the simple group (OR = 0.40, 95% CI: 0.25–0.66; $P = 0.0002$). And there wasn't significant difference in heterogeneity between two groups ($P = 0.85$, $I^2 = 0\%$) (Fig. 3D).

Posterior capsular opacification

The consolidated data from 8 studies[6, 8–10, 12, 13, 16, 22] containing 587 eyes indicated that combined group had a lower proportion of posterior capsular opacification than simple group (OR = 0.42, 95% CI: 0.23–0.78; $P = 0.006$). In heterogeneity, there was no significant difference ($P = 0.93$, $I^2 = 0\%$) (Fig. 3E).

Vitreous hemorrhage

The incidence of VH was reported in 6 studies[7, 11, 14, 17, 19, 21] including 726 eyes in combined group compared with simple group. There wasn't significant difference in the heterogeneity ($P = 0.23$, $I^2 = 27\%$). Also, fixed effect model suggested that the incidence of VH in combined group was higher than that in the simple group (OR = 0.46, 95% CI: 0.24–0.90; $P = 0.02$) (Fig. 3A).

Macular edema

The incidence of ME was reported in 9 studies[6, 8–10, 12, 13, 16, 19, 22] including 671 eyes in combined group compared with simple group. Fixed effects model suggested that the combined group had lower incidence of ME than simple group

(OR = 0.28, 95% CI: 0.11–0.70; $P = 0.007$). Besides, there was not significant difference in the heterogeneity between the trials ($P = 1.00$, $I^2 = 0\%$)(Fig. 3B).

Hard exudation of retina

The proportion of hard exudation of retina was reported in 6 studies[6, 9, 12, 13, 16, 22] including 407 eyes in combined group compared with simple group. Fixed effects model showed that the combined group had lower incidence of hard exudation than the simple group (OR = 0.26, 95% CI: 0.10–0.65; $P = 0.004$) (Fig. 3C). And there wasn't significant difference in terms of heterogeneity ($P = 0.95$, $I^2 = 0\%$).

Publication bias

The incidences of the combined group and the simple group in patients with PDR shows that, symmetry exists on the funnel plots. This indicated that there was no publication bias (see Supplemental Data File 3).

Discussion

With the improvement of equipment and materials of phacoemulsification and vitrectomy, combined phacoemulsification, IOL implantation, and PPV has become a new method for the treatment of diabetic retinopathy. The number of combined surgery has increased these years[23, 24]. The purpose of surgery is to treat the vitreoretinal complications as well as cataract in patients with PDR.

Some doctors tend to the combined surgery. They suppose that the combined surgery offers many benefits. Firstly, they believe that the application of phacoemulsification in patients with PDR can improve the clarity of visualization of the posterior segment during the operation, which ensures that the removal of the surrounding vitreous body and anterior fibrovascular structures more completely. So this facilitates the treatment of vitreoretinal complications associated with PDR and allows to carry out the operation accurately[5, 16, 19]. Secondly, the combined operation allows complete laser photocoagulation of the peripheral retina. And there was no risk of lens damage in surgery. It can also improve the convenience of fundus examination after surgery, according to which we can decide whether or not to add photocoagulation therapy. Intraoperative and postoperative supplementary phototherapy are important to reduce the incidence of iris NV[18, 25, 26]. Thirdly, due to the presence of diabetes or old age, the microenvironment of the vitreous cavity can be changed in patients with PDR after surgery, especially those eyes with silicone oil tamponade. These factors can cause postoperative cataract or accelerate the development of cataract[7, 25]. Also, because of weak zonular's support, it's a challenge to perform the sequential cataract surgery after prophase PPV[25]. Fourthly, combined surgery can facilitate immediate visual rehabilitation by solving cataract and vitreoretinal problems effectively through a single surgery. It can also relieve the psychological pressure of patients with secondary surgery and reduce the economic burden [1, 6, 7, 17, 18, 20, 27].

However, some doctors prefer PPV in the first stage and then cataract surgery in the second stage. First of all, they believe that vitreous hemorrhage can make the red light reflection worse during cataract surgery, which results in the difficulty of capsulorhexis. This requires a higher level of medical equipment and doctors. Secondly, corneal endothelial cells in diabetic patients have a low tolerance to the process of surgery. The folds of Descemet's membrane after phacoemulsification will affect the subsequent operation, which makes the following vitreous surgery challenging. Finally, they worry that the increase of operation time and steps will aggravate the inflammation of the anterior chamber and increase the incidence of postoperative intraocular infection[7, 20, 28, 29].

This meta-analysis summarizes evidence to evaluate the safety of the combined group versus that of the simple group in patients with PDR. The results indicate that combined surgery has a low proportion of recurrent VH, iris NV, macular edema, hard exudate and posterior capsular opacification at the cost of high proportion of anterior chamber inflammation. There is no statistical difference in terms of other postoperative complication indicators such as transient ocular hypertension, corneal edema and iris synechia, though there is a rising tendency between two groups.

With the extension of operation time and the increase of operational steps, the structure of the ciliary body and the trabecular meshwork may change. The function of them may change too. These changes include relative pupil block secondary to the thickening of ciliary body and inflammatory obstruction of the trabecular meshwork and so on, which can make the intraocular pressure rise instantaneously. Therefore, elevated intraocular pressure after PPV is more common in patients with prolonged operation, such as the combined surgery[30]. Although there is no statistical difference in terms of ocular hypertension between two groups in our study, there is a rising trend. Caution should be paid in these patients because the optic nerve is susceptible to the fluctuation of intraocular pressure[21, 30].

PPV may destruct the blood aqueous barrier (BAB). In addition, for patients with poor PPV tolerance, cataract extraction may promte the angiogenesis and pro-inflammatory cytokines in the anterior chamber. Therefore, combined surgery can induce stronger inflammatory response than simple vitrectomy in anterior chamber[27–29]. Previous clinical studies have shown that phaco-vitrectomy can promote fibrin exudation and/or posterior adhesion[20, 27–29]. In our study, the combined group could increase the incidence of anterior chamber inflammation significantly after surgery as compared to the simple group. Although this is not enough to cause posterior synechia, there is a rising trend. The above points give us a hint that some details such as the control of preoperative blood glucose and the improvement of surgical skills should be paid attention.

Kadonosono et al. believes that the incidence of iris NV after the combined surgery is lower than that after simple PPV. The combined surgery is advantageous because lens removal can ensure better visibility. In addition, it allows more reliable operations, such as complete vitrectomy and adequate peripheral photocoagulation. These lead to the lower incidence of iris NV[19]. Besides, combined surgery was reported to have a benefit in reducing the incidence of postoperative VH in several studies [19, 20, 27]. Moreover, lens-sparing diabetic vitrectomy was reported to have an association with nonclear VH. In current meta-analysis, the combined group could reduce the incidence of VH, iris NV, macular edema and hard exudate as compared to the simple group. It may be related to the improvement of retinal ischemic state which benefits from thorough vitrectomy and adequate intraocular photocoagulation.

However, there are several limitations of this meta-analysis, which should be given enough attention. First, ethnic background of this analysis is based on Asians. This may have some effect on extrapolation of the results. Therefore, further research is needed from other parts of the world. Second, some studies available for this meta-analysis have short follow-up periods. This may introduce the observer bias. Finally, the heterogeneity and publication bias usually occur due to the small number of studies, although the funnel plot shows no publication bias.

Conclusions

All in all, this meta-analysis shows that vitrectomy combined with cataract surgery could reduce the incidence of vitreous hemorrhage, iris neovascularization, macular edema, hard exudate and posterior capsular opacification and increase the incidence of anterior chamber inflammation significantly after surgery as compared to simple vitrectomy without cataract surgery. There is no statistical difference in terms of the proportions of corneal edema, high intraocular pressure and iris synechia. The combined operation should be considered first after weighing the advantages and disadvantages.

Authors' Contributions YW and LZ gave work in the process of designing the study, revising and deciding the final edition of the manuscript. BM was in charge of data collection, analysis and drafting the manuscript. SL, LL and TZ provided assistance in the data collection. YH, KW and BY provided aids for literature screening. The content of the final version was read and approved by all the authors.

Declarations

Authors' Contributions YW and LZ gave work in the process of designing the study, revising and deciding the final edition of the manuscript. BM was in charge of data collection, analysis and drafting the manuscript. SL, LL and TZ provided

assistance in the data collection. YH, KW and BY provided aids for literature screening. The content of the final version was read and approved by all the authors.

Data availability The datasets used and/or analyzed during the current study are available from the corresponding author on reasonable request.

Funding No funding was received for this research.

Conflict of Interest The authors declare that they have no conflicts of interest.

References

1. Smith JM, Steel DH (2015) Anti-vascular endothelial growth factor for prevention of postoperative vitreous cavity haemorrhage after vitrectomy for proliferative diabetic retinopathy. Cochrane Database Syst Rev 2015: Cd008214. https://doi.org/10.1002/14651858.CD008214.pub3
2. Antonetti DA, Silva PS, Stitt AW (2021) Current understanding of the molecular and cellular pathology of diabetic retinopathy. Nat Rev Endocrinol 17: 195–206. https://doi.org/10.1038/s41574-020-00451-4
3. The Lancet Diabetes E (2020) Under the lens: diabetic retinopathy. Lancet Diabetes Endocrinol 8: 869. https://doi.org/10.1016/S2213-8587(20)30347-8
4. Wykoff CC, Khurana RN, Nguyen QD, Kelly SP, Lum F, Hall R, Abbass IM, Abolian AM, Stoilov I, To TM, Garmo V (2021) Risk of Blindness Among Patients With Diabetes and Newly Diagnosed Diabetic Retinopathy. Diabetes Care 44: 748–56. https://doi.org/10.2337/dc20-0413
5. Ikeda T, Minami M, Nakamura K, Kida T, Fukumoto M, Sato T, Ishizaki E (2014) Progression of nuclear sclerosis based on changes in refractive values after lens-sparing vitrectomy in proliferative diabetic retinopathy. Clin Ophthalmol 8: 959–63. https://doi.org/10.2147/opth.s61372
6. Zhao XD, Gu YX, Wang W, Cai Y (2018) The Clinical Effect of Vitrectomy Combined With Cataract Surgery for Proliferative Diabetic Retinopathy. China Continuing Medical Education 10: 104–05. https://doi.org/10.3969/j.issn.1004-6763.2018.09.050
7. Zhou AY, Li T, Zhao L, Wang JM, Quan YL (2016) The clinical analysis of micro-invasion vitrectomy combined with phacoemusification for proliferative diabetic retinopathy. Chinese Journal of Practical Ophthalmology 34: 58–61. https://doi.org/10.3760/cma.j.issn.1006-4443.2016.01.015
8. Zhang Y, Lv XC (2020) Effect of 23G minimally invasive vitrectomy combined with phacoemulsification and intraocular lens implantation in the treatment of proliferative diabetic retinopathy Practical Clinical Journal of Integrated Traditional Chinese and Western Medicine 20: 55–56.
9. Zhang HY (2019) Effect of vitrectomy combined with cataract surgery on proliferative diabetic retinopathy Health Guide 341. https://doi.org/10.3969/j.issn.1006-6845.2019.14.323
10. Miao JB, Wang L (2020) Clinical study of vitrectomy combined with cataract surgery in the treatment of severe proliferative diabetic retinopathy Journal of Medical Forum 41: 118–21.
11. Jiao LL (2019) Effect of 23G minimally invasive vitrectomy combined with phacoemulsification and intraocular lens implantation on best corrected visual acuity after surgery for proliferative diabetic retinopathy clinical research 27: 73–74.
12. Huang ZH (2019) Vitrectomy combined with cataract surgery for the treatment of proliferative diabetic retinopathy Diabetes New World 22: 192–94.
13. Hu YJ (2020) Clinical observation of vitrectomy combined with cataract surgery in the treatment of proliferative diabetic retinopathy Healthmust-Readmagazine 62.

14. Hu ZX, Lin HS, Ye LY, Xu MN, Lin K, Chen TY, Wu RH (2020) The efficacy of combined vitrectomy-lensectomy and non-combined surgery in the treatment of proliferative diabetic retinopathy. Journal of Wenzhou Medical University 50: 825–29.
15. Hou L (2020) Effect analysis and research on 25G vitrectomy combined with phacoemulsification in the treatment of PDR Journal of Imaging Research and Medical Applications 4: 208–09.
16. Jia XF, Feng XF, Xin ZK, Xiao B (2017) Vitrectomy combined with cataract surgery in treatment of proliferative diabetic retinopathy. Journal of Regional Anatomy and Operative Surgery 26: 215–17. https://doi.org/10.11659/jjssx.09E016018
17. You AL (2017) Clinical effect of vitrectomy combined with cataract surgery in patients with proliferative diabetic retinopathy For All Health 11: 111. https://doi.org/10.3969/j.issn.1009-6019(x).2017.09.142
18. Liu DC, Wu H, Guo L (2007) Vitrectomy combined with phacoemulsification and intraocular lens implantation for treatment of proliferative diabetic retinopathy. Chinese Journal of Ophthalmology 43: 346 – 49. https://doi.org/10.3760/j.issn:0412-4081.2007.04.012
19. Tseng HY, Wu WC, Hsu SY (2007) Comparison of vitrectomy alone and combined vitrectomy, phacoemulsification and intraocular lens implantation for proliferative diabetic retinopathy. Kaohsiung J Med Sci 23: 339–43. https://doi.org/10.1016/s1607-551x(09)70419-x
20. Park SP, Ahn JK, Lee GH (2009) Morphologic changes in the anterior segment after phacovitrectomy for proliferative diabetic retinopathy. J Cataract Refract Surg 35: 868–73. https://doi.org/10.1016/j.jcrs.2008.12.032
21. Lee JY, Jeong HS, Lee DY, Sohn HJ, Nam DH (2012) Early postoperative intraocular pressure stability after combined 23-gauge sutureless vitrectomy and cataract surgery in patients with proliferative diabetic retinopathy. Retina 32: 1767–74. https://doi.org/10.1097/IAE.0b013e3182475ad6
22. Suo NC (2019) Observation of the therapeutic effect of vitrectomy combined with cataract surgery in the treatment of proliferative diabetic retinopathy Electronic Journal of Clinical Medical Literature 6: 91–94.
23. Xiao QB (2016) Effect of vitrectomy combined with phacoemulsification on proliferative diabetic retinopathy China Medical Device Information 22: 96–97.
24. Zhang B (2015) Clinical analysis of vitrectomy combined with phacoemulsification in the treatment of proliferative diabetic retinopathy Journal of Qiqihar University of Medicine 24:
25. Braunstein RE, Airiani S (2003) Cataract surgery results after pars plana vitrectomy. Curr Opin Ophthalmol 14: 150–4. https://doi.org/10.1097/00055735-200306000-00007
26. Antoszyk AN, Glassman AR, Beaulieu WT, Jampol LM, Jhaveri CD, Punjabi OS, Salehi-Had H, Wells JA, 3rd, Maguire MG, Stockdale CR, Martin DF, Sun JK, Network DR (2020) Effect of Intravitreous Aflibercept vs Vitrectomy With Panretinal Photocoagulation on Visual Acuity in Patients With Vitreous Hemorrhage From Proliferative Diabetic Retinopathy: A Randomized Clinical Trial. JAMA 324: 2383–95. https://doi.org/10.1001/jama.2020.23027
27. Lahey JM, Francis RR, Kearney JJ (2003) Combining phacoemulsification with pars plana vitrectomy in patients with proliferative diabetic retinopathy: a series of 223 cases. Ophthalmology 110: 1335–9. https://doi.org/10.1016/s0161-6420(03)00454-8
28. Diolaiuti S, Senn P, Schmid MK, Job O, Maloca P, Schipper I (2006) Combined pars plana vitrectomy and phacoemulsification with intraocular lens implantation in severe proliferative diabetic retinopathy. Ophthalmic Surg Lasers Imaging 37: 468–74. https://doi.org/10.3928/15428877-20061101-04
29. Treumer F, Bunse A, Rudolf M, Roider J (2006) Pars plana vitrectomy, phacoemulsification and intraocular lens implantation. Comparison of clinical complications in a combined versus two-step surgical approach. Graefes Arch Clin Exp Ophthalmol 244: 808–15. https://doi.org/10.1007/s00417-005-0146-9
30. Sharma YR, Pruthi A, Azad RV, Kumar A, Mannan R (2011) Impact of early rise of intraocular pressure on visual outcome following diabetic vitrectomy. Indian J Ophthalmol 59: 37–40. https://doi.org/10.4103/0301-4738.73724

Figures

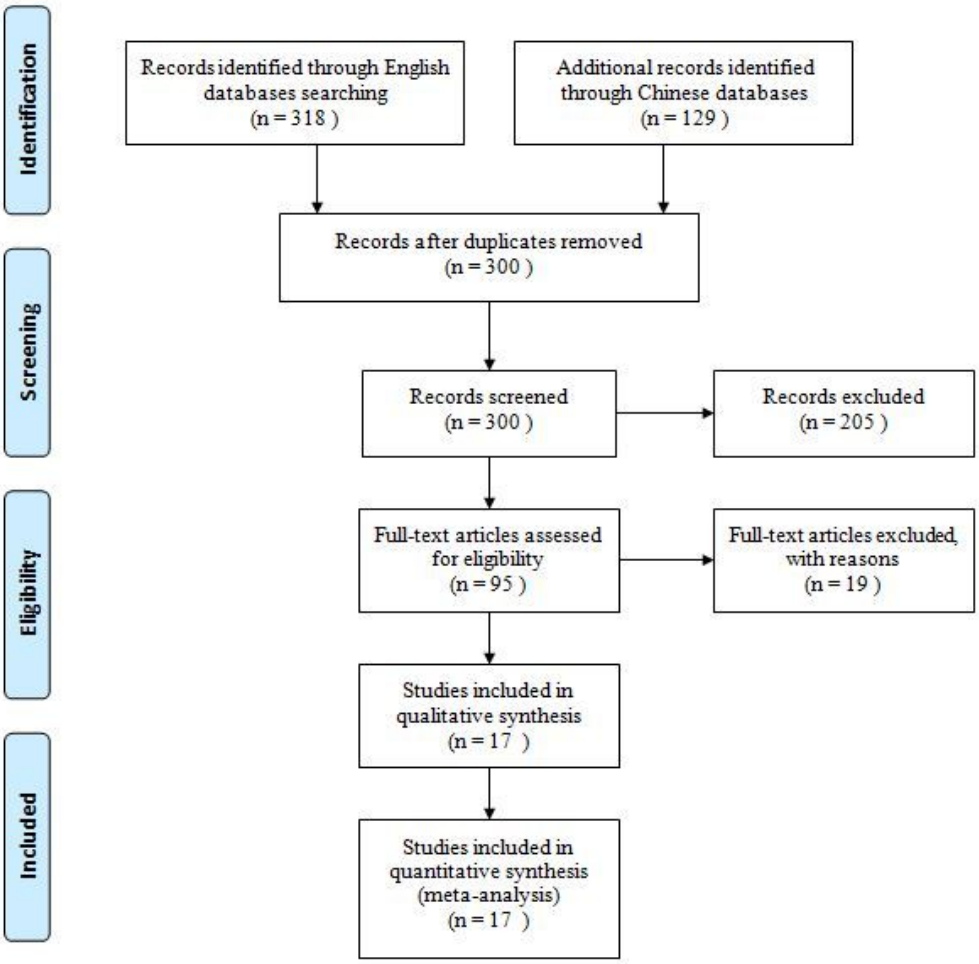

Figure 1

The flowchart of selection process in comparison of the combined group and simple group

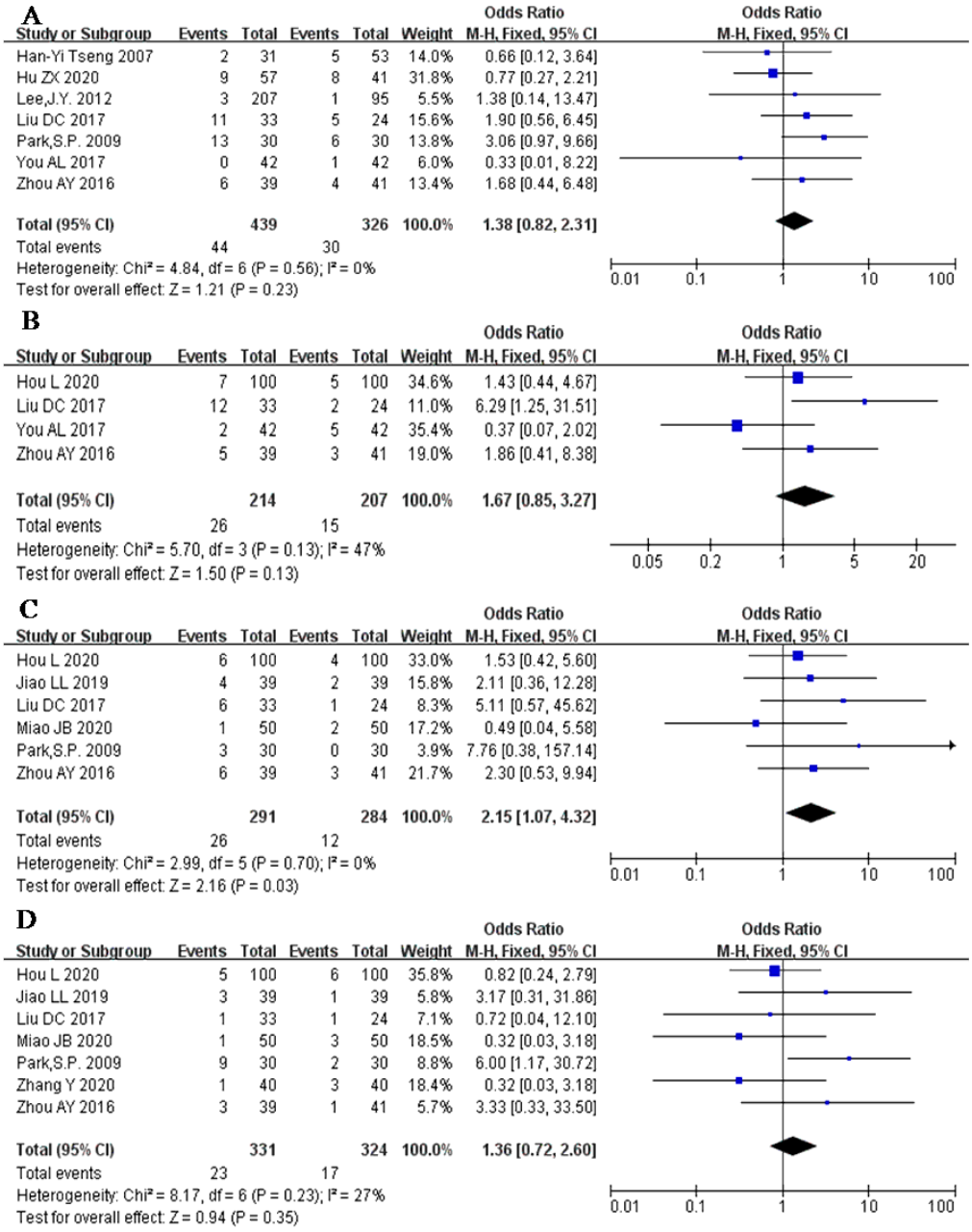

Figure 2

Forest plot showing the rates of postoperative high intraocular pressure (A), postoperative corneal edema (B), anterior chamber inflammation (C) and iris synechia (D) for combined group versus simple group

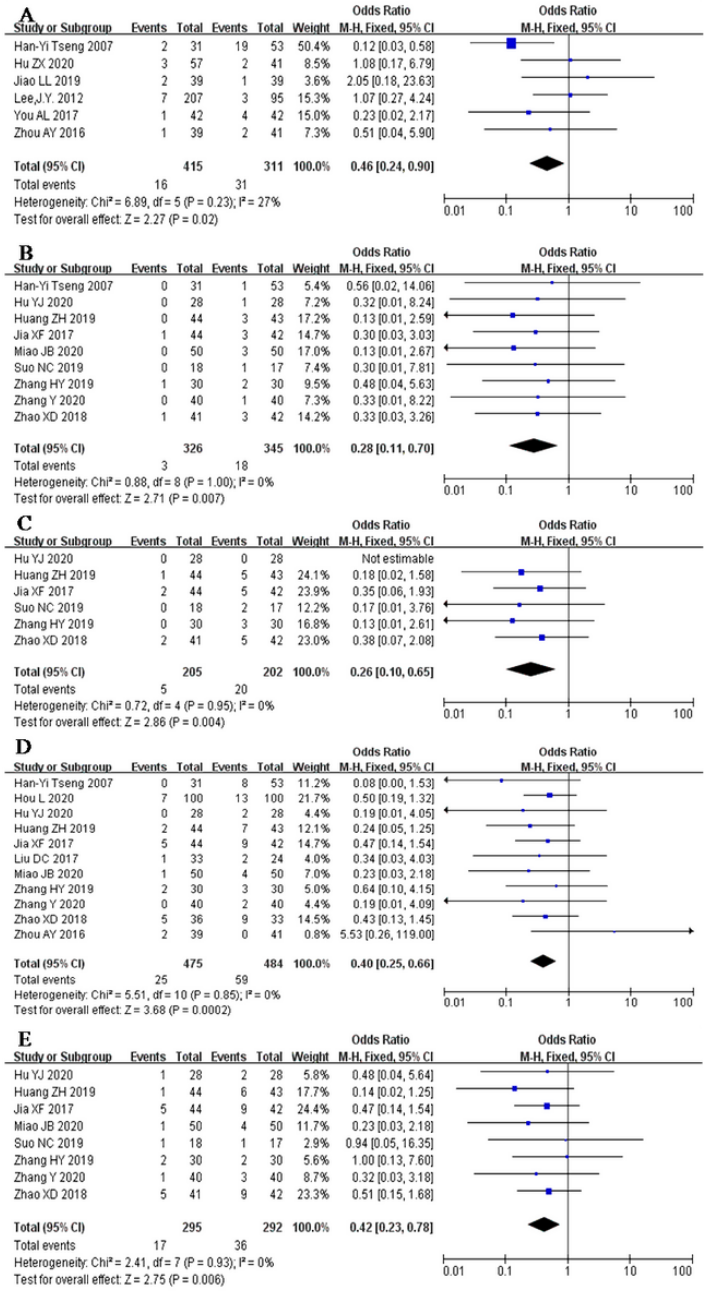

Figure 3

Forest plot demonstrating the rates of postoperative high vitreous hemorrhage (A), macular edema (B), hard exudation (C), iris neovascularization (D) and posterior capsular opacification (E) for combined group versus simple group

Supplementary Files

This is a list of supplementary files associated with this preprint. Click to download.

- SupplementalDataFile1.doc
- SupplementalDataFile2.doc
- SupplementalDataFile3.doc