Unusual Behavior of Subfoveal Perfluorcarbon Liquid

Hamouda Hamdy Ghoraba
Tanta University

Hashem HamoudaGhoraba
Tanta University

Adel Galal Zaky (Adelzaky12@gmail.com)
Menoufia University

Case Report

Keywords: perfluorocarbon, subretinal, retained, resolution

Posted Date: April 4th, 2022

DOI: https://doi.org/10.21203/rs.3.rs-1514998/v1

Abstract

Purpose: To report unprompted closure of spontaneous macular hole secondary to inadvertent subfoveal perfluorocarbon after vitrectomy surgery.

Patients& Methods: We present a case of a retained large single subfoveal PFCL droplet following vitrectomy and silicone oil injection for subtotal rhegmatogenous retinal detachment (RRD) that showed spontaneous release 4 weeks postoperatively, with subsequent development of full thickness macular hole (FTMH) which completely closed later on after silicone oil removal without internal limiting membrane peeling.

Results: Marvelous anatomic and visual improvement after spontaneous closure of MH.

Discussion: Few complications have been associated with use of PFCLs. The most common is postoperative residual PFCL in vitreous cavity or in the anterior chamber. Subretinal retention of PFCL has been reported and it has the most significant ocular toxicity but spontaneous release of subfoveal PFCL without surgical interference has rarely been reported.

Conclusion: Different behaviors of subfoveal PFC droplets may occur.

Introduction

Perfluorocarbon liquids (PFCLs) have become a regular surgical tool in the repair of retinal detachments complicated by proliferative vitreoretinopathy, giant retinal tears, and other conditions. However, Subfoveal perfluorocarbon liquid (SPCL) is a rare but important complication of vitreoretinal surgery. Since the introduction of perfluorocarbonated liquids to date, very few publications have focused on this topic.[1] Subfoveal PFCL may be visually threatening, and prompt surgical removal or displacement is indicated according to the visual prognosis.[1] While peripheral subretinal PFCL can often be observed. Also, migration of peripherally located droplets towards the fovea is noticed, although the mechanisms of migration remain unclear.2 Spontaneous resolution of subfoveal PFCL without surgical intervention has rarely been reported.[3] We present a case of a retained large single subfoveal PFCL droplet that spontaneously released in unusual behavior.

Case Report

Male patient 52years old presented with subtotal rhegmatogenous retinal detachment with single large upper equatorial break (10–12 o' clock) with macula off in the left eye with visual acuity of hand movement. He underwent pars plana vitrectomy and silicone oil injection. Transconjunctival 23 gauge 3-port PPV technique using the Eva surgical system (DORC), and a noncontact wide-angle viewing system BIOM (Binocular Indirect Ophthalmoscope; Oculus, Wetzlar, Germany) were used. Posterior vitreous detachment was created using aspiration by a vitreous cutter with Triamcinolone. PFCL was used to stabilize the posterior pole and the vitreous base was shaved 360 degrees as safe as possible without

lensectomy using high-speed vitreous cut rates (8000–9000 cuts/min) and low vacuum settings (100–150 mmHg). Internal limiting membrane peeling or retinectomy were not performed. Subretinal fluid was drained anteriorly through the original break with the assistance of PFCL by injection with 23 G dual bore cannula (MedOne Surgical, Sarasota, USA) keeping the injection within the single PFCL bubble to avoid “satellite” bubbles followed by Air-PFC exchange. Endolaser photocoagulation was performed around all identifiable retinal tears. Silicon-air exchange using silicon oil 5000 centistokes was performed. On postoperative day 1 and then at postoperative week 1, the patient had counting fingers vision with retinal attachment under silicone oil, but a subfoveal PFCL droplet was noted on ophthalmoscopy (Fig. 1A) and confirmed with optical coherence tomography (OCT) imaging, which revealed a focal area of severely thinned retinal tissue overlying the droplet with omega sign (Fig. 1B). After 2 weeks VA improved to 0.1 & patient complained of metamorphopsia. The decision was made to aspirate PFCL by 41 G cannula after 1 week. The patient came at the time, but he complained of marked drop of vision with central scotomas, VA was counting fingers 2 m. Fundus examination showed development of full thickness macular hole with disappearance of PFCL droplet which was confirmed by OCT (Fig. 2). We preferred to follow the patient and after 4 months from original surgery, he underwent phacoemulsification with intraocular lens implantation and silicone oil removal (SOR) without any ILM peeling & subretinal or intravitreal PFCL was never identified. In the 1st day & 1st week post SOR fundus examination showed attached retina with FTMH & VA was 0.05. On postoperative 3rd week, he noticed improvement in his vision 3 days before the visit. By examination VA was 0.4 and ophthalmoscopy was performed, demonstrating closure of MH. OCT performed that day revealed a restored foveal depression. Without any surgical intervention, these architectural changes improved over the subsequent months, with restoration of the ellipsoid zone at the fovea (Fig. 3). His visual acuity improved to 0.7 after 3 months of silicone oil removal.

Discussion

Subretinal perfluorocarbon retention is a potential adverse consequence after PFC use in retinal detachment repair. Though, posterior migration of peripheral subretinal PFC toward the fovea is a recognized phenomenon, spontaneous peripheral migration away from the fovea and the anatomical findings during migration have not been described. Multiple studies have shown that even with highly purified PFCLs, retinal toxicity occurs after just a few days of intravitreal PFCL exposure and an even shorter period for subretinal PFCL.[4–6]

In this report, we demonstrate a case of spontaneous resolution of subfoveal PFCL. Examination of the posterior and peripheral retina just revealed FTMH without any subretinal PFCL droplets following release. We hypothesize that the surface tension of the PFCL droplet resulted in tangential forces that created a defect at the fovea. We suggest that the PFCL droplet extruded through this retinal defect into the vitreous cavity, where it remained undetected, but was subsequently removed during silicone oil removal. The possibility of retinal hole formation due to chronic subretinal PFCL retention with a very thin overlying retina has been reported in the literature.

Ghoraba et al,[7] revealed spontaneous formation of macular holes in 2 patients. In those 2 patients, subfoveal PFCL droplets disappeared. Also, Tanabu et al,[8] reported a case of macular hole secondary to subfoveal perfluorocarbon that subsequently closed after its spontaneous resolution. This occurred after doing a vitrectomy for traumatic retinal detachment. They speculated that the retinal structure in the macula was fragile. Thus, subretinal PFCL droplets were likely to release more easily. Also, they explained that in eyes in which the internal limiting membrane has already become detached or removed PFCL droplets are more likely to be spontaneously discharged.

Toth et al, reported a large PFCL bubbles spontaneously migrated from the fovea in a downward direction or a subretinal PFCL droplet subsequently disappeared from the central fovea, resulting in improvement of the retinal structure [9]. Also, Oellers et al.[10] postulated that the PFCL droplet discharged through a transient hole created in the thinned retina overlying the droplet spontaneously, which later closed leaving the macula flat & atrophic.

OCT was important tool especially for follow up those patients & for the differential diagnosis of retained subretinal fluid, subretinal SO, sticky silicone oil and subretinal PFCL due to their differences in viscosity, density and surface tension. Entrapped PFCL bubble has distinct border & retina take the shape of omega sign (Ω) thus the angle between RPE & neurosensory retina at base of PFCL bubble is acute and retinal layers can't be identified above PFCL droplet as whole retina were being squeezed with hyper-reflective shadow at the choroid.[7]

As regard VA, it was dramatically improved in our patient after release PFCL droplet & closure of MH and reached 0.7. This agree with Oellers et al.,[10] who reported in their case VA improvement to 20/70 at 6 weeks following oil removal, with sustained retinal attachment, absence of any retained PFCL, and continued improvement of the retinal contour and microarchitecture.

The mechanism of this unusual event is rarely reported in literature and poorly recognized as different behaviors and scenarios of submacular PFCL droplets may occur. In the future, improved understanding of the mechanisms of spontaneous resolution may enable the development of nonsurgical or minimal invasive techniques to remove subfoveal PFCL.

Declarations

Patient Consent

Written consent to publish this case has not been obtained. This report does not contain any personal identifying information.

Ethics approval and consent to participate:

This study was approved by Ethical Committee of the Magrabi Hospitals , the patient received a thorough explanation of the study design and aims followed by a signed informed consent; the study

was conducted in compliance with the tenets of the Declaration of Helsinki.

Consent for publication:

Not applicable

Availability of data and material:

The datasets used and/or analyzed during the current study are available from the corresponding author on reasonable request.

Authorship:

All authors attest that they meet the current ICMJE criteria for Authorship

Conflicts of Interest:

The authors declare that they have no competing interests or financial disclosures

Funding:

No funding was received

Authors' contributions:

H.G & A.Z conceptualized the idea. A.Z & H.H.G designed the study. H.G & A.Z recruited the case for the study & performed surgeries and clinical follow up examinations. H.G performed fundus photography and OCT examination & its analysis. A.Z & H.H.G drafted the manuscript. H.G revised manuscript. All authors approved the final manuscript.

Acknowledgements:

Not applicable

References

1. Blinder KJ (2001) Use of perfluorocarbon liquids. In: Peyman GA,Meffert SA, Conway MD, Chou F: Vitreoretinal Surgical Techniques, Martin Dunitz, London, UK, PP 173–191.
2. Meffert S, Peyman GA. (1999) Intraoperative complications of perfluoroperhydrophenanthrene: Subretinal perfluorocarbon, retinal slippage and residual perfluorocarbon. Vitreon Study Group. Can J Ophthalmol; 34(5):272–280.
3. Shulman M, Sepah YJ, Chang S, et al. (2013) Management of retained subretinal perfluorocarbon liquid. Ophthalmic Surg Lasers Imaging Retina; 44(6):577–583.

4. Wilbanks GA, Apel AJ, Jolly SS, et al. (1996) Perfluorodecalin corneal toxicity: Five case reports. Cornea; 15(3):329–334.
5. Weinberger D, Goldenberg-Cohen N, Axer-Siegel R, et al.(1998) Long-term follow-up of perfluorocarbon liquid in the anterior chamber. Retina; 18(3):233–237.
6. Ramaesh K, Bhagat S, Wharton SB, Singh J. (1999) Corneal epithelial toxic effects and inflammatory response to perfluorocarbon liquid. Arch Ophthalmol; 117(10):1411–1413.
7. Ghoraba HH, Ghoraba HH, HeikalMA,et al .Submacular Perfluorocarbon Liquid: Long-Term Follow-Up. IntOphthalmol2020 May; 40(5):1209–1219.
8. Tanabu R, Suzuki Y, Suzuki K, et al. (2017) Macular Hole Caused by Retained Subfoveal Perfluorocarbon that Subsequently Closed After Its Spontaneous Resolution: A Case Report. OphthalmolTher.; 6(2):381–384.
9. Toth CA, Schneider EW, Folgar FA. (2014) Spontaneous peripheral migration of subfoveal perfluorocarbon. Retina, 34:2315–6.
10. Oellers P, Charkoudian LD, Hahn P. (2015) Spontaneous resolution of subfoveal perfluorocarbon. ClinOphthalmol.; 9:517–9.

Figures

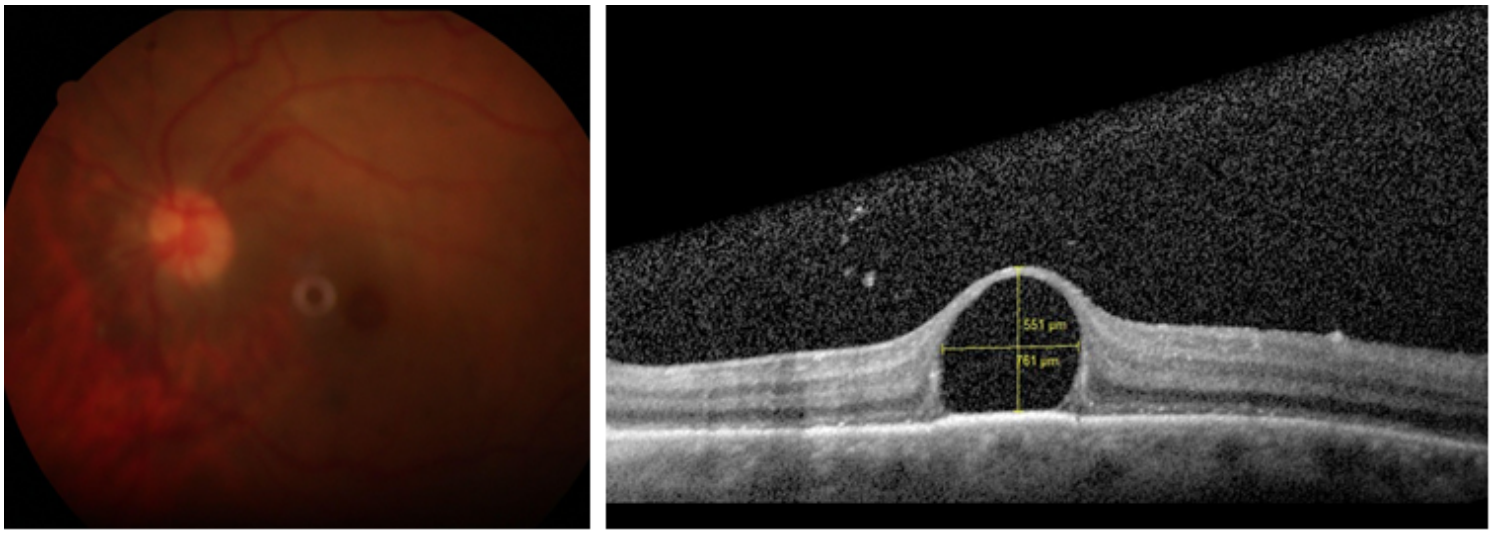

Figure 1

a) colored fundus photography showing subfoveal PFCL droplet b) OCT showing Ω sign

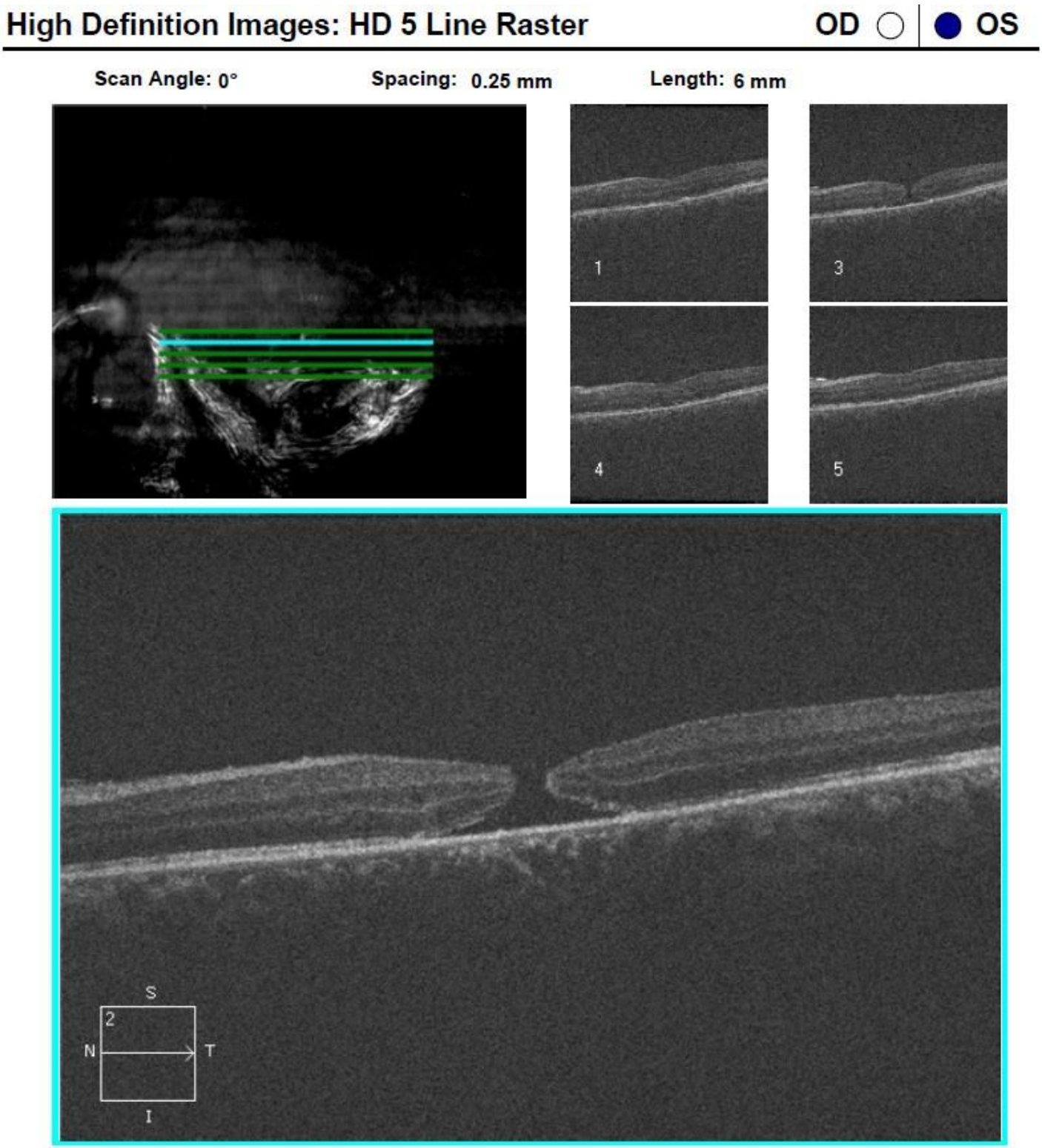

Figure 2

OCT showing development of FTMH

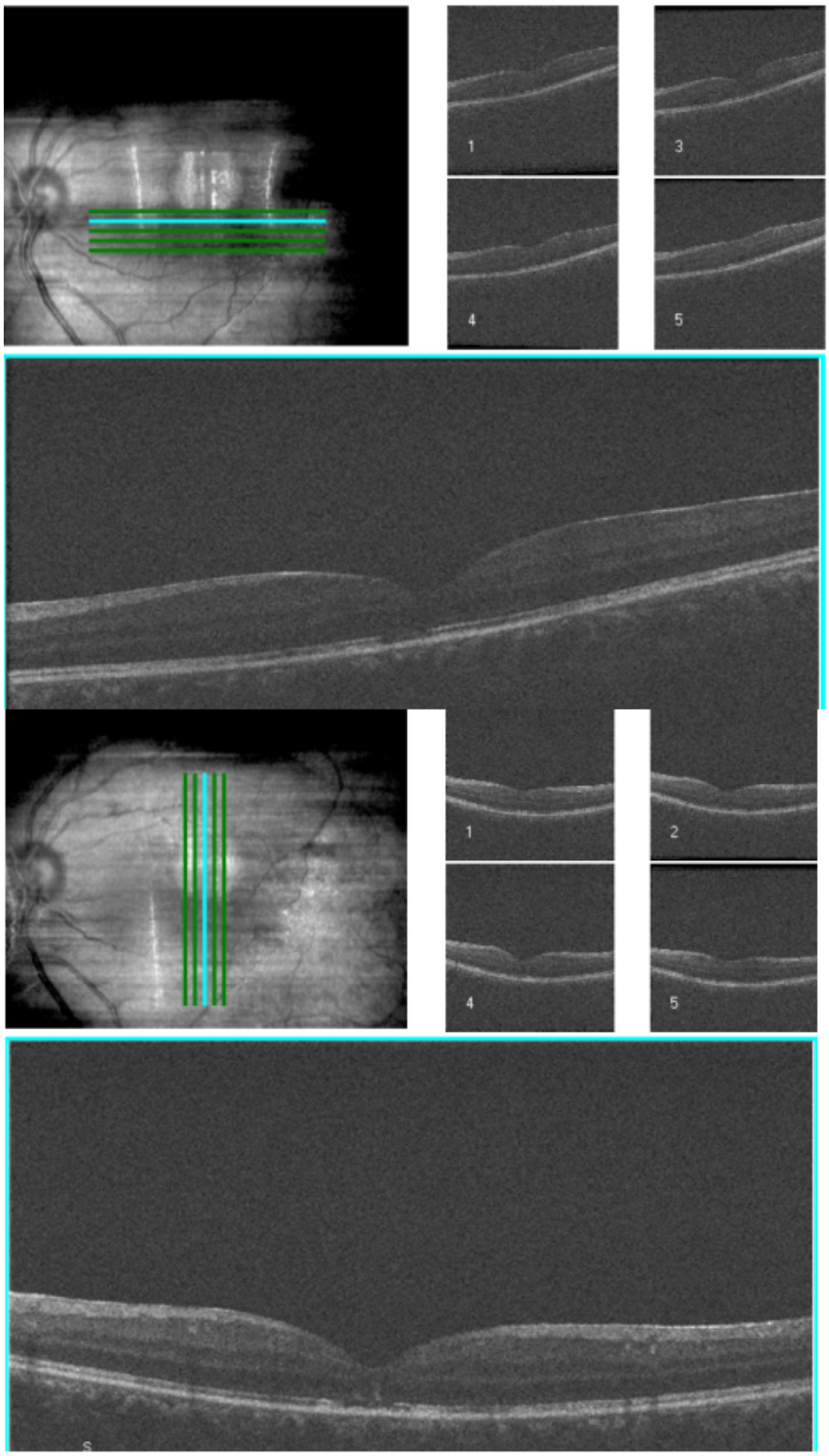

Figure 3

OCT horizontal & vertical HD raster scan showing closure of MH with improvement of microarchitecture of retina