Effect of chlorhexidine acetate on the early postoperative orthotopic ileal neobladder in situ mucus secretion

Peng kang
Xuzhou Renci hospital
Ashok Raj
Department of Urology, the Affiliated Hospital of Xuzhou Medical University, Xuzhou 221000, China.
Chen Renfu
Department of Urology, the Affiliated Hospital of Xuzhou Medical University, Xuzhou 221000, China.
Peng Yunpeng
Department of Urology, the Affiliated Hospital of Xuzhou Medical University, Xuzhou 221000, China.
Xie Wenjing
Department of Urology, the Affiliated Hospital of Xuzhou Medical University, Xuzhou 221000, China.
Fu jian wang
Xuzhou Renci hospital
Sun Xiaolei (326916159@qq.com)
Department of Urology, the Affiliated Hospital of Xuzhou Medical University, Xuzhou 221000, China.

Research Article

Keywords: orthotopic ileal neobladder, intestinal mucus secretion, chlorhexidine acetate, bladder cancer

Posted Date: April 20th, 2022

DOI: https://doi.org/10.21203/rs.3.rs-1515207/v1

Abstract

Objective: To investigate the impact of chlorhexidine acetate's on the mucus secretion function in the early postoperative period of the neo-ileal bladder and compare other treatment agents.

Method: 24 patients who underwent total Cystectomy with orthotopic ileal neobladder in our department and divided into three groups (8 each). During the procedure, mucosal treatment agents were infused for five minutes, and specimens were taken for histological examination of the neobladder mucosa under light and electron microscopy.

Results: The daily intestinal mucus secretion in the early stage of the neobladder(POD 3-14). Group A (Iodophor) compared to B (anhydrous ethanol), and C (chlorhexidine acetate) were reduced and statistically significant ($P < 0.05$), with no statistical difference between B and C ($P > 0.05$). Light and Electron microscopy; In group A, the neobladder intestinal mucosa layer is complete; villi were uniformly arranged. A few goblet cells between the apex of the villi disappear an acceptable arrangement of micro-villi and a relatively low degree of organelle damage. In group B, the neobladder intestinal mucosa layer is unclear, the villi arrangement lost and shedding, muscle layer structure disrupted, accompanied by RBC and inflammatory cells infiltration. In group C, neo-bladder intestinal mucosa structure was complete, and villi are low, rupture, shedding, and inflammatory cells infiltrated without significant damage muscle layer.

Conclusion: As a new mucous membrane treatment agent, chlorhexidine acetate has a protective effect on the mucous membrane of the new bladder. Meanwhile, it also inhibits the secretion of mucous in the new bladder in the early postoperative period.

Introduction

Bladder cancer is the most common malignant tumor(1). Recent reports show that 430000 patients worldwide are diagnosed with bladder cancer every year, a public health issue affecting health and quality of life(2, 3). on depth invasion, non-muscle-invasive bladder cancer (NMIBC), and muscle-invasive bladder cancer (MIBC). About 70% of patients present with NMIBC, and the five-year survival is about 90% with surgery (4). Radical Cystectomy (RC) and pelvic lymphadenectomy are recommended treatments for patients without distant metastasis(5). Since hautmann .et reported his orthotopic diversion operation, orthotopic intestinal neobladder has become the standard. Compared with other urinary diversion methods, the orthotopic ileal neobladder is closer to the normal anatomy, maintains sexual function to the greatest extent, and improves the quality of life.

Orthotopic ileal neobladder has a series of related postoperative complications, as early and late complications(6). A segment of the ileum is reconstructed and incorporated into the urinary bladder. The intestinal mucosa has the characteristics of absorption and secretion compared to the Bladder mucosa. Hence, absorption and secretion function cause complications such as electrolyte disorder, acid-base imbalance, mucus plug obstruction of the urinary tract, new bladder stones, abnormal bone metabolism

(7–9). Postoperative thick intestinal mucous plug blocked the urinary tract, poor anastomotic healing, and anastomotic leakage.

However, early mucosa-related complication needs to be addressed. At present, we lack a uniform treatment protocol for the treatment of intestinal mucous. Bladder irrigation or wash post-operation is a primary method to prevent plug-blocking catheters. After removing the catheter, the risk of urinary tract blocking, poor anastomotic healing, and leakage is significantly increased. There are two reasons: first, in the early postoperative period, the anastomotic stoma is not mature; second, pain on the catheter is placed. Hence. There is still no satisfactory method for clinicians to solve the complications caused by early mucus secretion.

Our observation and study relevant studies suggest intestinal mucosa gradually undergoes adaptive changes (the villi and glands were atrophied) (10), it takes even a year and so. Therefore these patients are at high risk of block and need a catheter intermittently. At present, the best way to solve this kind of issue is to treat intestinal mucosa during operation to achieve de-mucositization, which can reduce the absorption and secretion function of the mucosa. The chemical treatment agents are anhydrous Ethanol, Iodophor, silver nitrate, formalin(11).: 2. Mechanical treatment: using physical methods, mechanical blunt or sharp dissection of the intestinal mucosa(12) 3. Photochemical process: the deadly effect of substances produced by photosensitizer on mucosal tissue after light irradiation(13) .4. The mucosal tissue was destroyed by enzyme digestion(14) 5. Other methods: treat intestinal mucosa with mitomycin and sodium morrhuate(15). The ultimate goal is to reduce the intestinal mucosal cells through various treatment methods to minimize postoperative mucosal complications.

At present, no unified standard protocol treatment methods for de-mucositization in the clinic. **Chlorhexidine (**$C_{22}H_{30}Cl_2N_{10}.2C_2H_4O_2$**)** is a bisbiguanide compound with a structure consisting of two (p-chlorophenyl) guanide units linked by a hexamethylene bridge. It has an anti-infective agent, an antibacterial agent, and a disinfectant for skin and mucous membrane. Skin disinfectant in preterm infants and chewing gum containing chlorhexidine acetate can reduce dental plaque and significantly improve oral hygiene(16, 17). Based on animal pre-experiment, we found that the ileal mucosa treated with chlorhexidine acetate was reduced secretion significantly, reduced blockage complications, and safe.

Hence, our hospital conducted a prospective study with orthotopic ileal neobladder to treat ileum mucus with three different mucosal treatment agents. Observe the changes in morphology and structure under a light and electron microscope. We also measure the mucus quantity and explore the effect of chlorhexidine acetate on the early mucus secretion of the neobladder.

Materials And Methods

General information

Methods: 24 patients with orthotopic ileal neobladder surgery were selected from a medical team of Affiliated Hospital of Xuzhou Medical University from October 2017 to December 2018. They were

randomly divided into group A (iodophor group), group B (anhydrous Ethanol), and group C (chlorhexidine acetate group) accordingly to the different treatment methods of intestinal mucosa during operation.

Inclusion criteria

(1) Pathology confirmed urothelial carcinoma and MIBC, no distant metastasis;(2) recurrent non-MIBC;(3) refractory TURBT;(4) normal mental state and signed the informed consent.

Exclusion criteria

(1) Incomplete urethra and injury of external sphincter;(2) systemic chronic diseases unable to tolerate surgery;(3) Intestinal malignant tumors;(4) Acute inflammatory or infectious diseases;(5) Acute and chronic renal and liver failure, connective tissue or severe autoimmune diseases.

Main reagents and instruments

Iodophor Xinghua Medical and Sanitary Products Co., Ltd.

Chlorhexidine Acetate (2.8-3.2g/L) Xinghua Medical and Sanitary Products Co., Ltd.

Projection Electron Microscope Japan JEOL Company . Xuzhou Medical University Pathology Laboratory

Research methods and observation indexes

preoperative preparation

1. History, physical examination, and Bowel preparation.

2. Routine cystoscopy, ultrasound, chest CT, CTU, Pelvic MRI, cardiopulmonary function examination .

Operation procedure

After general anesthesia, standard laparoscopy radical cystoprostatectomy with pelvic lymphadenectomy was performed. The specimens were put into the bag and sent to routine pathology. The serosal layer of the ileum was sutured with 4-0 suture at a distance of 10 cm from the ileocecal junction. An intestinal mucosa treatment agent was infused into the intestinal cavity for five minutes. The intestinal wall was cut longitudinally along the opposite side of the mesentery, folded into a "W" shape, and sutured continuously with 3-0 v-loc thread to form a spherical allantoic sac. The intestinal canal's useless parts at both ends during the operation were reserved and put into formalin and electron microscope examination.

Postoperative management

Postoperative diet and bladder wash

After bowel, the patient was allowed to diet according to GI tolerance. Bladder wash was started on the POD 1 with 5% sodium bicarbonate. The patient lies in a supine position, the catheter connects the

syringe, low pressure, and gently wash until liquid is clear. The flush fluid and urine were collected for weight daily.

Flushing weighing

After washing, the urine is stored in a glass container for 24 hrs; the upper washing liquid without mucus was filtered out. The lower washing liquid with mucus was centrifuged at a speed of 5000 rpm for 5 minutes. The supernatant was discarded, weighed mucus secretion at 10 a.m. every day, and Calculated as neobladder secretion per unit area.

Specimen collection and determination

the specimen of ileum treated with a mucosal treatment agent was sent to the pathology Department for H/E staining and an electron microscope.

Statistical methods

SPSS 25.0 software and normal distribution with the mean ± standard deviation ('± s). One-way ANOVA for homogeneity, the nonparametric test for unevenness, median. Quartile for non-normal distribution, the nonparametric test for comparison among groups. The chi-square test for categorical variable data. Test level $\alpha = 0.05$, $P < 0.05$ for the difference was statistically significant.

Result

General information

After the strict screening, 24 patients were eligible for orthotopic ileal neobladder. They were randomized into group A (iodophor group), group B (anhydrous Ethanol), and group C (chlorhexidine acetate group) and treated with mucosa treatment agents 8 in each group.

In group A, 6 males and 2 females, were aged (62.0 ± 11.3) years, BMI (25.2 ± 4.1) kg / m2, and preoperative tumor size (4.76 ± 3.06) cm. Among them, 3 patients had hypertension, 2 patients had diabetes mellitus, 4 patients had no smoking history, 2 patients had undergone TURBT and relapsed again. In group A, preoperative hemoglobin was (128.5 ± 18.3) g / L, and preoperative albumin was (37.6 ± 3.3) g / L.In group B, 7 males and 1 female, age of (58.8 ± 10.6) years, a BMI of (24.8 ± 4.7) kg / m2, and preoperative tumor size of (4.34 ± 3.20) cm. Among them, 2 patients had hypertension, 1 patient had diabetes mellitus, 3 patients had no smoking history, 1 patient had undergone TURBT and recurred after the operation. In group B, preoperative hemoglobin was (132.3 ± 15.8) g / L, and preoperative albumin was (38.4 ± 343) g / L.

In group C, 7 males and 1 female, age of (61.3 ± 12.7) years, a BMI of (25.4 ± 4.3) kg / m2, and preoperative tumor size of (4.87 ± 3.46) cm. Among them, 4 patients had hypertension, 2 patients had diabetes mellitus, 2 patients had no smoking history, 3 patients had undergone TURBT and relapsed

again. In group C, preoperative hemoglobin was (130.5 ± 17.5) g / L, and preoperative albumin were (39.6 ± 2.3) g / L.

Postoperative data

All 24 cases were operation completed successfully. The operation time of groups A, B, and C were (275 ± 20.62) min, (280.1 ± 19.76) min, and (290 ± 21.27) min, respectively (P = 0.3498), no statistical difference. There is no significant difference among the three groups: intraoperative blood loss, postoperative NPO, drainage time, neobladder surface area, postoperative TNM stage, postoperative lymph node status, and pathological grading, no significant difference among the three groups (P > 0.05).

Statistics of postoperative complications

Three patients in group A had catheter blockage on follow-up for a year, but not in group B and C, P = 0.048 < 0.05, with a statistical difference. There was no significant difference in other related complications (P > 0.05), indicating that catheter blockage incidence in patients treated with Iodophor was significantly higher than in the other two groups, with statistical significance [Table 1].

Mucus secretion of neobladder after different treatments

Most patients did not eat on POD 1st and 2nd, and no new mucus secretion. Neobladder mucus mainly came from epithelial tissue shedding and a new bladder's blood clot. These data errors were too large, so we removed mucus volume data of POD 1st and 2nd. Hence, we decided to analyze data from 3-14 days [Table 1]. The graph shows the secretion of intestinal mucus has a certain regularity, which gradually begins to secrete on the POD 3RD, reaches the peak on the 7th, and then gradually decreases but does not disappear. The mucus secretion in the iodophor group was significantly higher than that in the chlorhexidine acetate and absolute ethanol groups. The mucus secretion in the chlorhexidine acetate and absolute ethanol groups was similar, with no significant difference.The weight of mucus secretion per unit area of the neobladder was calculated according to the mucus weight of three groups of neobladder after irrigation.

Analysis of variance among groups A, B, and C

The mucus secretion of the Iodophor, anhydrous Ethanol, and chlorhexidine acetate groups are different within 3-14 days. We Compared the mucus secretion of the neobladder in the anhydrous ethanol group and chlorhexidine acetate group within 3-14 days. We found no statistical difference in the anhydrous Ethanol and chlorhexidine acetate groups. The mucus secretion was more after the operation (P < 0.01) [Figure 1].

Discussion

This study focused on early complications that arise due to mucosa secreted by the ileal neobladder and compared three treatment agents to reduce mucus. Previous studies advocate that After the ileal

neobladder, the intestinal epithelium gradually adapting to the urine environment reduces mucus secretion over time (18). However, this process generally takes a year or even longer. Bejany et al.(19) also confirmed this point. Several intestinal mucosa treatment methods are reported in the literature along with their mechanism of action, still no satisfactory result.

Mechanical, photochemical, and enzyme treatment are still at the animal experiments level, challenging to operate, and expensive, so currently not feasible for clinical application. Whereas, Chemical agents are less harmful, convenient, and economical, with a tremendous clinical prospect. Commonly used Chemical agents are Iodophor, anhydrous alcohol, formalin. Iodophor in Experimental and clinical results showed that mucus secretion was reduced, but the effect was not noticeable, and intestinal mucus was still prominent. Anhydrous alcohol can coagulate, denaturation, destroy intestinal mucosa protein, destroy intestinal mucosa absorption and secretion cells, and reduce secretion and absorption function. Based on pre-experiment, chlorhexidine acetate is infused in the ileal neobladder during operation, hoping to reduce mucus secretion and not affect bladder function after the procedure.

Chlorhexidine acetates can adsorb on the permeability barrier of the bacterial membrane, destroying the cell wall, and cell contents leak out. Chi Wei et al. found that chlorhexidine acetate Hemorrhoids Suppository can effectively prevent recurrence of postoperative anal canal condyloma acuminatum. It can also prevent infection of insufficient preoperative intestinal preparation.

HE staining showed that compared with the Iodophor group, the chlorhexidine acetate and anhydrous ethanol groups showed a stronger mucosal damaging ability. Under the microscope, the two groups' villi were sparsely arranged, with many distal villi breaking and falling off. In contrast, the villi of the iodophor group were closely arranged, with only a tiny number of distal goblet cells disappearing. However, after being treated with anhydrous Ethanol, the mucosal layer appeared with different degrees of damage, and the tissue structure was unclear. The results of the HE staining demonstrate that the muscle layer structure of the anhydrous ethanol group was destroyed, accompanied by bleeding and a large number of inflammatory cells infiltration comparing group A and group C. however, group A and group C B has stronger tissue penetration ability. This phenomenon is not consistent with the research purpose. Once the muscle layer is damaged, it will lead to fibrosis of the muscle layer and contracture of the new bladder, reduce the capacity of the new bladder, affect the contraction and peristalsis function of the new bladder [*Figure 2*]. The results of electron microscopy showed that: in group A, the intestinal barrier was intact, the microvilli were arranged in order, and the degree of organelle damage was low; in group B, the intestinal barrier was seriously damaged, no complete microvilli and intercellular connections were found, and the organelles were significantly reduced, and the structure was unclear; in group C, the microvilli were short and slightly uneven, and the organelles were slightly swollen, most of the damage was low, and the intestinal barrier was relatively complete. The chlorhexidine acetate group can ensure the intestinal barrier's integrity and effectively damage the microvilli, reducing the number and height of microvilli Compared to other groups. Further, We collected and measured the mucus weight of 24 patients in neobladder irrigation. We found that mucus was significantly reduced in groups B and C, with statistical significance. The results showed that Iodophor had a weak effect on the mucosa, resulting in a

chance of high mucus secretion, causing catheter blocking complications. Due to the short follow-up and fewer cases, other postoperative complications were not statistically significant. However, the above studies show that neobladder mucosa treatment is more beneficial to patients. We observe the mucosa's performance after cauterization and corrosion [*Figure 3]*. the intestinal stem cells can not control goblet cells' regeneration(20), and its specific mechanism is not fully understood. However, it needs further study whether the regenerated function of goblet cells can be inactivated by periodic perfusion of mucosal treatment agent after an operation, with the following caution 1. Whether the anti-reflux effect of the ureter is not as good as that of the normal bladder? 2. When the neobladder mucosa is inactivated with chemical agents, can it result in urethral stricture, scar formation, and ureteral orifice stenosis?

Mucus secretion reduction is more significant than removing the mucous membrane itself. In addition to the intestinal mucosa's absorption and secretion function, intestinal flora's translocation can cause various conditions such as infectious shock, contracture, and even canceration once the barrier is damaged, which is unpredictable. Therefore, mucosa removal should be cautious. Mucous membrane treatment is ideal for reducing intestinal mucus secretion and clinical application. Chlorhexidine acetate can be a better choice than Iodophor and anhydrous alcohol inactivating ileal mucosa in situ.

In Conclusion, As a new mucous membrane treatment agent, chlorhexidine acetate has a protective effect on the mucous membrane of the new bladder. Meanwhile, it also inhibits mucous secretion in the new bladder in the early postoperative period

Declarations

Acknowledgments

None.

Author contributions: *PK, AR, and SXL take responsibility for the integrity and accuracy of the data analysis.*

Study concept and design: PK, AR, SXL.

Acquisition of data: SXL, CRF, PK, AR, PYP, XWJ, FJW.

Analysis and interpretation of data: PK, AR, PYP.

Drafting of the manuscript: SXL, CRF, PK, AR

Critical revision of the manuscript for content: All authors.

Statistical analysis: PK, AR.

Supervision: SXL, CRF

Funding

No funding for this clinical trial

Availability of data and materials

The datasets used during the current study are available on reasonable request from the corresponding author.

Ethics approval and consent to participate The study were approved by the Clinical Trial Ethics Committee, Affiliated Hospital of Xuzhou Medical University. All patients have signed informed consent forms. The final protocol, any amendments, and informed consent documentation were reviewed and approved by the Institutional Review Boards. All methods were carried out in accordance with relevant guidelines and regulations

Consent for publication

Informed consent to publish was obtained. Competing interests The authors declare no conflict of interest. Author details 1 Department of Urology, The Affiliated Hospital of Xuzhou Medical University, Xuzhou 221000, China. 2 Xuzhou renci hospital, Xuzhou 221000, China.

References

1. Li X, Wang W, Zhu G, He W, Gou X. Risk factors, follow-up, and treatment of urethral recurrence following radical cystectomy and urinary diversion for bladder cancer: a meta-analysis of 9498 patients. Oncotarget. 2018;9(2):2782.
2. Torre LA, Bray F, Siegel RL, Ferlay J, Lortet-Tieulent J, Jemal A. Global cancer statistics, 2012. CA: a cancer journal for clinicians. 2015;65(2):87–108.
3. XU Hangjie, FU Yiming. Comparison of urinary diversion patterns after radical cystectomy. Journal of Clinical and Pathology. 2018;38(10):2261264–2264.
4. Edge SB, Compton CC. The American Joint Committee on Cancer: the 7th edition of the AJCC cancer staging manual and the future of TNM. Annals of surgical oncology. 2010;17(6):1471–4.
5. Gerharz EW. Re: Hautmann RE, Abol-Enein H, Hafez K, et al: Urinary diversion. Urology 69 (suppl): 17–49, 2007. Urology. 2008;72(1):231-2; author reply 2.
6. Mills R, Studer U. Metabolic consequences of continent urinary diversion. The Journal of urology. 1999;161(4):1057–66.
7. Roosen A, Gerharz EW, Roth S, Woodhouse CR. Bladder, bowel and bones—skeletal changes after intestinal urinary diversion. World journal of urology. 2004;22(3):200–9.
8. Tanrikut C, McDougal WS. Acid-base and electrolyte disorders after urinary diversion. World journal of urology. 2004;22(3):168–71.

9. N’dow J, Robson C, Matthews J, Neal D, Pearson J. Reducing mucus production after urinary reconstruction: a prospective randomized trial. The Journal of urology. 2001;165(5):1433–40.
10. Şenkul T, Yildirim Ş, Işeri C, Karademir K, Erden D, Baykal K. Histopathologic changes in the mucosa of ileal orthotopic neobladder: findings in 24 patients followed up for 5 years. Scandinavian journal of urology and nephrology. 2003;37(3):202–4.
11. Demirbilek S, Uğuralp S, Gürbüz N, Sezgin N, Kırımlıoğlu H. The use of silver nitrate for chemical de-epithelialization and urothelialization of intestine in a rabbit model of augmentation cystoplasty. Urological research. 2003;31(4):236–41.
12. KÏBAR Y, TAHMAZ L, ÖNGÜRÜ Ö, DAYANÇ M. Prevention of colonic mucosal regrowth after seromuscular enterocystoplasty. The Journal of urology. 2001;165(6 Part 1):2059–62.
13. Luksiene Z. Photodynamic therapy: mechanism of action and ways to improve the efficiency of treatment. Medicina (Kaunas, Lithuania). 2003;39(12):1137–50.
14. Türkeri L, Simsek F, Sav A, Ilker Y, Akdaş A. Enzymatic treatment of ileal segments used for urinary tract reconstruction. International urology and nephrology. 1996;28(5):655–63.
15. Fan W, Yu Y, Shu J, Ming H, Li W, Fan Z. Mitomycin-C suppresses mucus secretion in an ileal neobladder rat model. Experimental and therapeutic medicine. 2015;10(2):598–602.
16. Simons D, Brailsford S, Kidd E, Beighton D. The effect of chlorhexidine acetate/xylitol chewing gum on the plaque and gingival indices of elderly occupants in residential homes: a 1-year clinical trial. Journal of clinical periodontology. 2001;28(11):1010–5.
17. Janssen LM, Tostmann A, Hopman J, Liem KD. 0.2% chlorhexidine acetate as skin disinfectant prevents skin lesions in extremely preterm infants: a preliminary report. Archives of Disease in Childhood-Fetal and Neonatal Edition. 2018;103(2):F97-F100.
18. Heagy W, Hansen C, Nieman K, Rodriguez JL, West MA. Impaired mitogen-activated protein kinase activation and altered cytokine secretion in endotoxin-tolerant human monocytes. Journal of Trauma and Acute Care Surgery. 2000;49(5):806–14.
19. Bejany DE, Politano VA. Modified Ileocolonic Bladder: 5Years of Experience. The Journal of urology. 1993;149(6):1441–4.
20. Pinto D, Clevers H. Wnt control of stem cells and differentiation in the intestinal epithelium. Experimental cell research. 2005;306(2):357–63.

Tables

[Table 1].*Statistics of postoperative complications (n = 8)*

Group	A (iodophor)	B (Anhydrous ethanol)	C (Chlorhexidine acetate)	P-value
Catheter blockage	3(37.5)	0(0.0)	0(0.0)	0.048
Anastomotic leakage	1(12.5)	0(0.0)	0(0.0)	0.352
Incision infection	0(0.0)	0(0.0)	0(0.0)	-
Urinary incontinence occurred at 12 months	0(0.0)	0(0.0)	0(0.0)	-
Hydronephrosis	1(12.5)	0(0.0)	1(12.5)	1.00
dysuria	0(0.0)	0(0.0)	0(0.0)	-
Recurrent urinary tract infection	1(12.5)	0(0.0)	0(0.0)	1.00
Electrolyte disorder	1(12.5)	1(12.5)	0(0.0)	1.00
New bladder stones	1(12.5)	0(0.0)	0(0.0)	1.00

As shown in .Table1, 24 patients were followed up for one year. Three patients in group A had catheter blockage. However, group B and group C did not find this phenomenon, $P = 0.048 < 0.05$, with a statistical difference and no significant difference in other related complications ($P > 0.05$), indicating that the incidence of catheter blockage in patients treated with Iodophor was significantly higher than that in the other two groups.

Figures

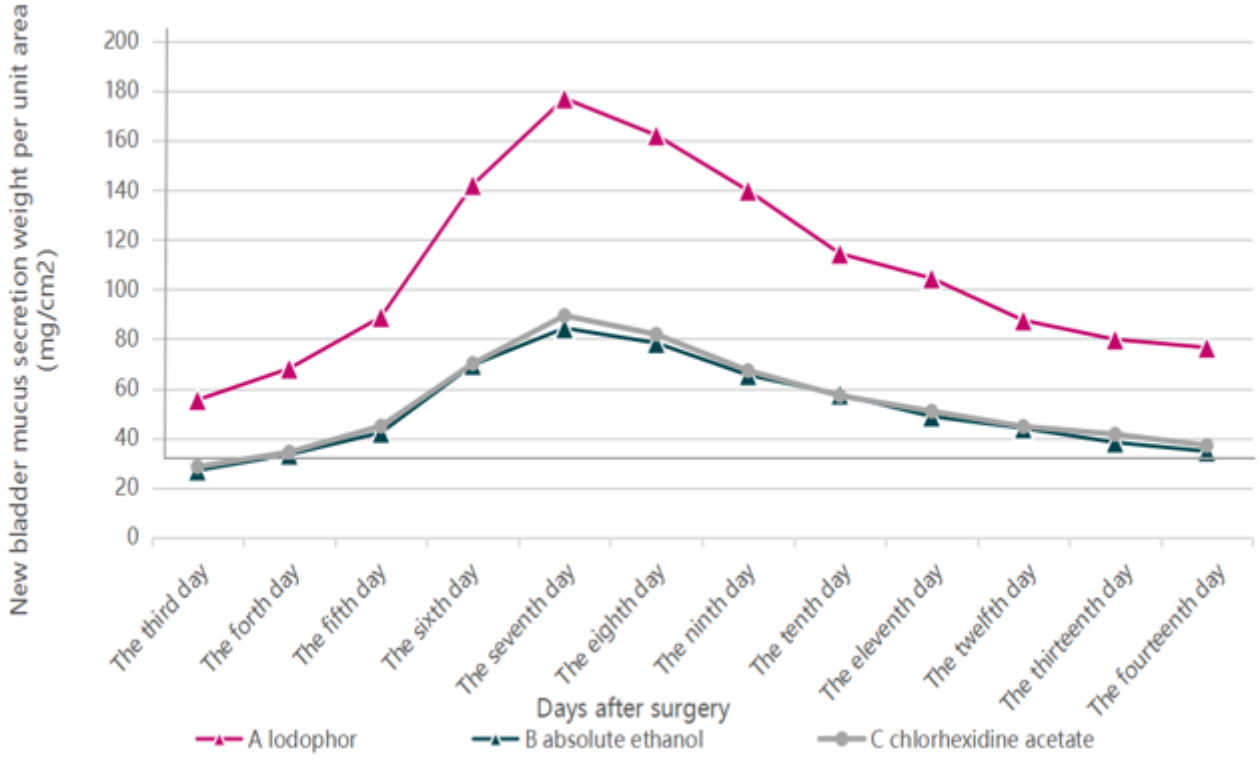

Figure 1

The relationship between the three groups of new bladder mucus secretion per unit area 3-14 days after the operation.

TREATMENT	A ×40	B ×100	A ×40	B ×100
iodophor	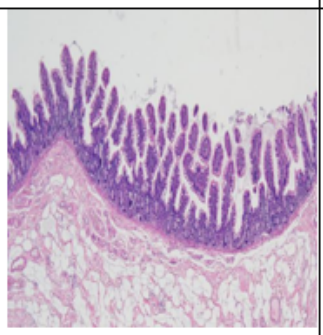	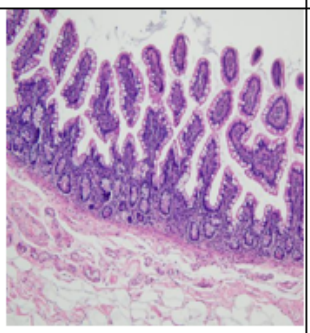	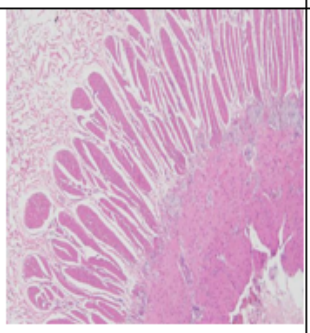	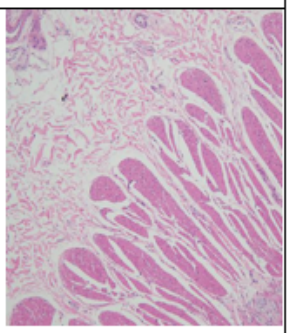
chlorhexidine	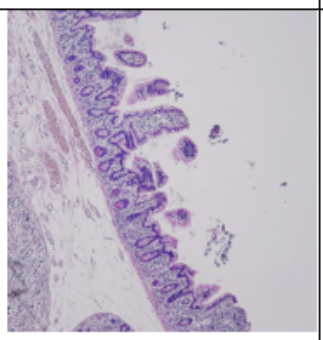	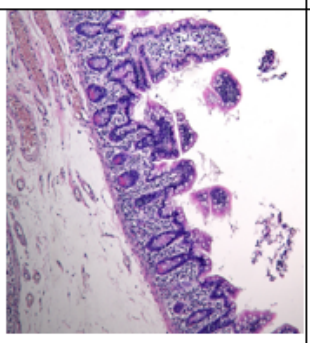	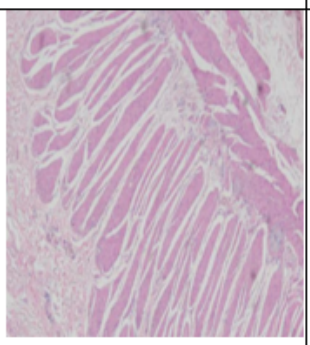	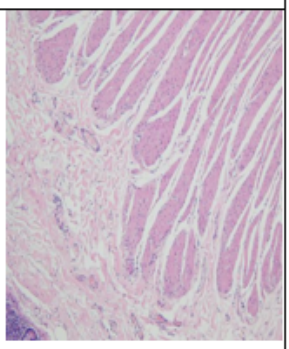
absolute ethanol	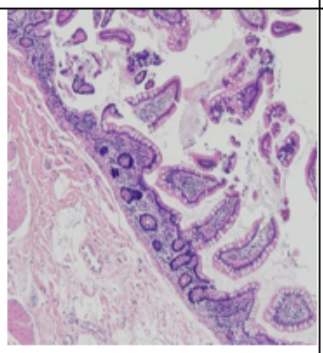	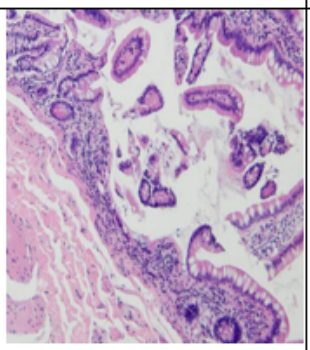	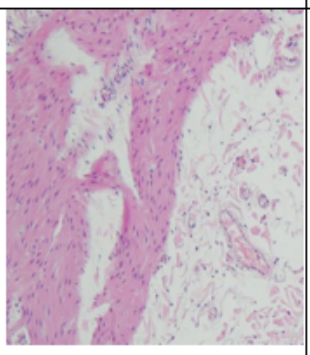	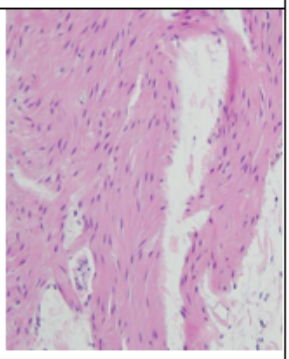

Figure 2

H/E staining showed that compared with the Iodophor group, the chlorhexidine acetate and anhydrous ethanol groups shown below

iodophor group: A, B showed that the intestinal mucosa layer was complete, the villi arranged orderly and tightly, protruded into the intestinal cavity in a finger shape, and a few goblet cells disappeared at the top of the villi. (Figure 2A× 40, Figure 2B× 100). C, D showed a clear and complete myometrial structure with a small inflammatory cell infiltration. (Figure 2C× 40, Figure 2D × 100)

chlorhexidine group: A. B showed that the intestinal mucosa structure was complete, the villi arranged low and flat, and the distal end was broken and fell off. (Figure2 A× 40, Figure 2 B× 100). A. B showed that the muscular layer structure was clear and complete, accompanied by many inflammatory cell infiltration, without muscle layer damage. (Figure 2 C× 40, Figure 2 D × 100)

absolute ethanol group: A. B's visible intestinal mucosa structure is unclear. Villi arranged disorder, low flat, distal fracture, fall off. (Figure 4 A× 40, Figure 4 B× 100). C, D: muscle layer structure disorder, accompanied by a small number of red blood cells and many inflammatory cell infiltration. (Figure 2 C× 40, Figure 2 D× 100).

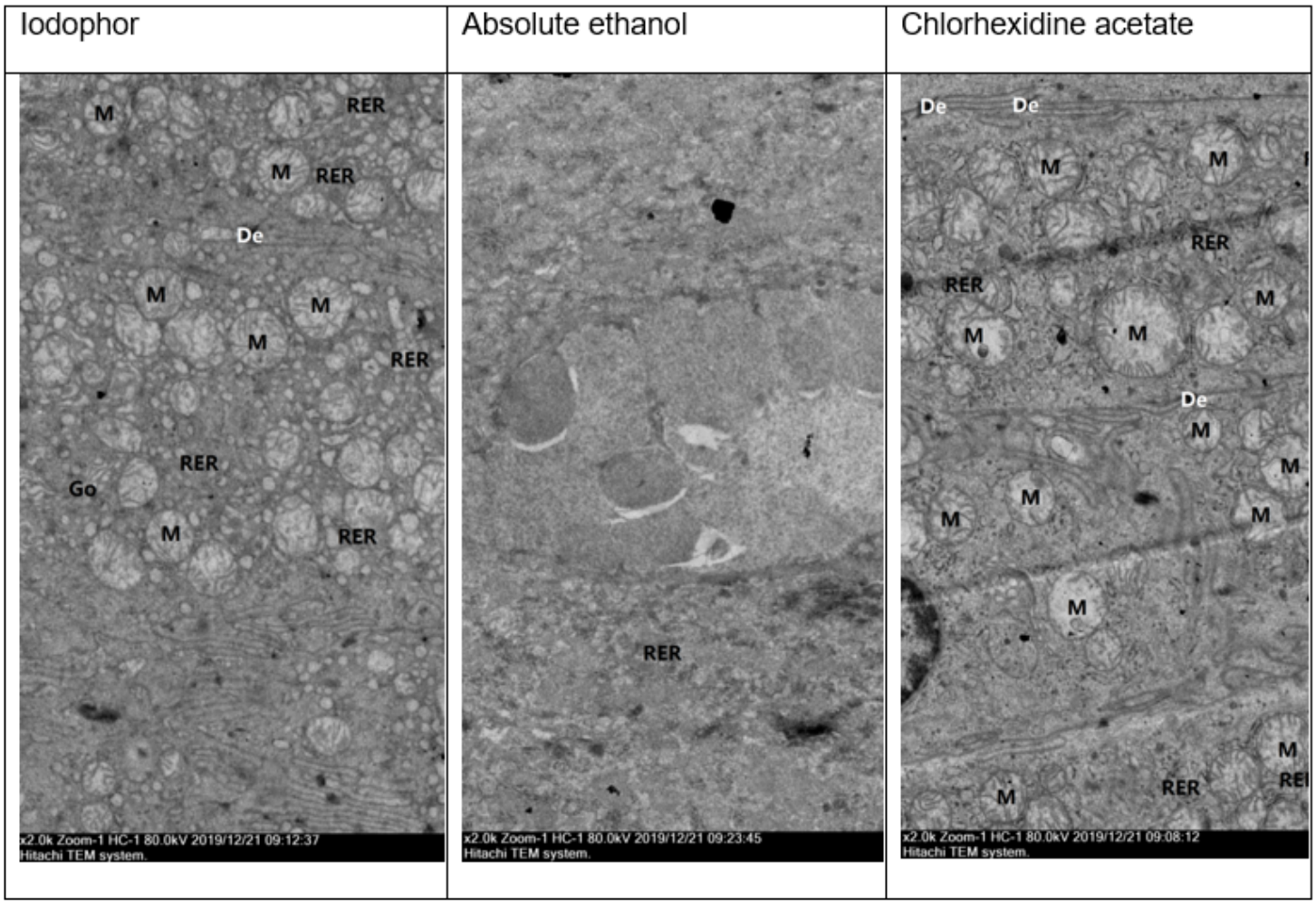

Figure 3

Results of electron microscopy compared with the Iodophor group, the chlorhexidine acetate, and anhydrous ethanol groups showed below.

Iodophor group: the intestinal barrier is intact, the microvilli (Mv) are neatly arranged, and the thickness is relatively uniform; the epithelial cells have no obvious edema in the cytoplasm, abundant organelles, abundant mitochondria (M), clear inner and outer membrane structures, and most of them Mild swelling, a few cristae fractures, mild expansion of rough endoplasmic reticulum (RER), mild hypertrophy of Golgi apparatus (Go); clear tight junctions (TJ), intermediate junctions (ZA), desmosomes (De), the composite connection structure is complete, the connection is tight, and there is no obvious breakage and disappearance.

Absolute ethanol group: the intestinal barrier was severely damaged or disappeared, and the microvilli (Mv) were largely shed, lost, and broken; the epithelial cells tended to be necrotic, the integrity of the cell membrane was lost and blurred, and the intracellular organelles were reduced. The mitochondrial structure is obvious, and some residual rough endoplasmic reticulum (RER) can be seen in the cells.

Chlorhexidine acetate group: the intestinal barrier is relatively complete, the microvilli (Mv) are shortened and slightly uneven; the cytoplasm of epithelial cells has no obvious edema, the organelles are rich, and the inner and outer membranes of the mitochondria (M) have clear and large structures. Some mild swelling, some moderate swelling, some ridges are broken, shortened, reduced, mild expansion of rough endoplasmic reticulum (RER); clear tight junctions (TJ), intermediate junctions (ZA), desmosomes can be seen between cells (De), the composite connection structure is complete, and the connection is tight.