Trans-catheter closure of ASD and abnormal connection of left pulmonary vein to vertical vein: Follow-Up report

Mahmoud Mohamadzadeh Shabestari
Mashhad University of Medical Sciences
Abdollah Kerachian
Mashhad University of Medical Sciences
Hoorak Poorzand (hpoorzand@yahoo.com)
M.D. & FASE, Imam Reza Hospital, Mashhad University of Medical Sciences
Ali Eshraghi
Mashhad University of Medical Sciences
Faeze Keihanian
Mashhad University of Medical Sciences

Case Report

Keywords: Partial anomalous pulmonary venous connection, Vertical vein, Device closure

Posted Date: April 6th, 2022

DOI: https://doi.org/10.21203/rs.3.rs-1516750/v1

Abstract

Background: Partial anomalous pulmonary venous connection (PAPVC) is a rare congenital anomaly in which one or more pulmonary veins are connected to the venous circulation leading to left to right heart shunt. Although correction of anomalous pulmonary venous connection is achieved through surgery, there are rare instances where the abnormal pulmonary vein has dual connection to both left atrium and the major systemic veins. Under these circumstances catheter-based treatment might become a feasible option.

Case presentation: We report a case of atrial septal defect (ASD) and dual drainage of left upper pulmonary vein, which were successfully addressed by occluder devices and followed carefully while detecting early clot formation behind the implanted device in the vertical vein.

Conclusion: For comprehensive evaluation of patients with ASD, assessment of pulmonic veins is crucial and in the presence of a vertical vein, the dual drainage of pulmonic veins should be considered.

Background

Partial anomalous pulmonary venous connection (PAPVC) is a rare congenital anomaly in which pulmonary veins carry blood from the lungs to the right side of the heart. The condition has a prevalence of 0.4–0.7%, it is frequently diagnosed as an incidental finding [1,2]. Herein we described an adult patient with ASD, in which the left upper pulmonary veins (LUPV) drained into the innominate vein which were successfully obstructed by occlude devices.

Case Presentation

A 22-year-old female was referred to our clinic for exertional dyspnea since one month ago. Physical examination defined holo-systolic systolic murmur in left lower sternal border with fixed splitting of S2. Twelve-lead electrocardiogram showed normal sinus rhythm with incomplete right bundle branch block. Transthoracic echocardiography (TTE) was done. Right ventricle was dilated with preserved systolic function. Paradoxical septal motion was noted. There was mild to moderate tricuspid regurgitation. Secundum atrial septal defect (ASD) was seenwith left to right shunt. The estimated systolic pulmonary artery pressure was 45mmHg. A vertical vein was detected traversing at the left side of the thoracic descending aorta and draining into innominate vein (IV). The calculated Qp/Qs was 1.85. In trans esophageal echocardiography (TEE), ASD size was 16mm, with suitable rims (except to the antero-superior rim). Left and right pulmonic veins were seen draining into left atrium. Left upper pulmonary vein (LUPV) seem to be narrow with turbulent flow passing the vein (Peak velocity: 1.2m/sec, mean pressure gradient: 5mmHg). The vertical vein and the abnormal drainage of LUPV could be clearly seen in TEE (Fig. 1). Diameter of LUPV and the site of connection to the vertical vein was about 5-mm in 2D TEE. No other associated abnormality was reported. The patient underwent cardiac catheterization that confirmed

secundum type ASD and the connection of the vertical vein to both innominate vein and the left atrium via the left upper pulmonary vein (Fig. 2).

The patient was referred for device closure. On admission her blood pressure was 110/60 mm Hg, heart rate was 85 beats/min, and respiratory rate was 18 breaths/min and O2 saturation at room temperature was 94%. After local anesthesia and placing two 6F sheaths in femoral artery and femoral vein, full oximetry run was done. Left to right shunts in level of pulmonary vein to abnormal connection and in ASD level was proved. The patient deeply sedated. Then 6f sheath of vein access was replaced with 10F sheath. Then under TEE guidance, Muscular VSD occluder (12mm) was deployed in abnormal connection (Fig. 3.a). Contrast injection proved optimal occlusion. Then, under TEE guidance and using the same 10F sheath, ASD occlude (Figulla® Flex II ASD, 18mm) was deployed in place of ASD (Fig. 3.b). TEE proved eliminated flow of the vertical vein and proper position of devices with no compressive effect on adjacent structures and no clot (Fig. 4).

Follow-up echocardiogram the next day showed complete occlusion of flow through the vertical vein and ASD. Dual antiplatelet with ASA and Clopidogrel were prescribed on discharge.

Trans-thoracic echocardiography was done three months later. There was obvious improvement in right ventricle size. Haziness was suspected behind the device in the vertical vein, which was confirmed in TEE, and ascribed to the clot formation back to the device with approximate length of 15mm (Fig. 5). Turbulent flow in the narrow LUPV was seen with peak velocity of flow reaching to 1.7m/sec. Pulmonary artery pressure was normal (#20mmHg). The patient is following for five years. She is symptom free. Repeated TEE after two years did not show any change in the burden of clot. Single antiplatelet therapy with ASA continued. On annual TTE, the turbulent flow in LUPV was still evident. Pulmonary artery pressure remained in normal limits.

Discussion

PAPVC is a relatively uncommon congenital anomaly characterized by one or more pulmonary veins draining into a systemic vein or the right atrium rather than the left atrium. Overall, PAPVC is symptomatic and often co-exists with ASD, in 80–90% of the cases [3]. Dual drainage of the pulmonary veins to both a systemic vein and the LA is rare and difficult to estimating the incidence, because most of these patients are asymptomatic[4]. Trans-catheter closure of the abnormal venous connection is certainly the treatment of choice for PAPVC with dual drainage, although successful surgical ligation of the vertical vein has been reported [5]. The closure could be attained by coil or Amplatzer duct occlude or vascular plugs[6].The type of closure device used is determined by the anatomical size and shape of the abnormal venous connection[4].We used a muscular VSD occluder in our patient that achieve complete occlusion of vertical vein; concurrently utilized Amplatzer® PFO occluder for secundum ASD. Performing a balloon occlusion test in the vertical vein, before the implanting of the device has been suggested to confirm the adequacy of the alternative drainage. Device closure could not be done with ≥ 10 mmHg increase in pulmonary venous pressure.

In this case, the flow velocity of pulmonic vein was increased from 1.2 to 1.7 m/sec after the device closure; but PAP did not increase during 5-year follow up. Therapy does not finish with the end of the procedure. Device thrombosis would be a possible serious complication. Optimal antiplatelet or antithrombotic medication have been proposed to enhance safe and complete endothelial coverage of the implanted device. We encountered clot formation behind the implanted device while the patient was on dual antiplatelet therapy, which was ascribed to stagnation of flow. Conservative management with periodic follow up was selected and there was not further extension or increase in the burden of clot on periodic TTE studies. The patient is still receiving ASA a single antiplatelet therapy [7].

Although TTE is usually unable to detect thrombus formation on the device, routine TEE examination is not suggested in adult patients in many centers, and TTE as an imaging tool might be sufficient. TEE could be performed in cases when transthoracic echocardiography suggests thrombosis or when transthoracic images are suboptimal [7].

Conclusion

For comprehensive evaluation of patients with ASD, assessment of pulmonic veins is crucial and in the presence of a vertical vein, the dual drainage of pulmonic veins should be considered. Trans-catheter interventions could be a safe and efficient treatment of such cases and the thrombus formation after device closure of the vertical vein could be managed conservatively.

Abbreviations

ASD= atrial septal defect

IV= innominate vein

LUPV= Left upper pulmonary veins

PAP= Pulmonary Artery Pressure

PAPVC= Partial anomalous pulmonary venous connection

PFO= Patent foramen ovale

TEE= Trans esophageal echocardiography

TTE= Transthoracic echocardiography

VSD= Ventricular septal defect

Declarations

Ethics approval and consent to participate

Publishing this case presentation is performed according to ethical guidelines of Mashhad University of Medical Sciences. Patient was evaluated for his problem and fulfilled informed consent for participation.

Consent to publish

Written consent to publish this information was obtained from study participant.

Availability of data and material

The data that support the findings of this study are available from Imam Reza Hospital, Mashhad University of Medical Sciences, but restrictions apply to the availability of these data, which were used under license for the current study, and so are not publicly available. Data are however available from the authors upon reasonable request and with permission of the corresponding author.

Competing interests

The authors declare that they have no competing interests.

Funding

There is no funding support.

Authors' contributions

M.M.Sh. and H.P. analyzed and interpreted the patient data regarding the cardiovascular disease and managed patient. A.K. helped in data gathering and diagnosis patient in echocardiographic evaluation. A.E. helped in patient catheterization and management. F.K. helped in management of patient, diagnosis and was a major contributor in writing the manuscript. All authors read and approved the final manuscript.

Acknowledgements

We all thank nurses of Imam Reza Hospital helped us in different stages of patient evaluations.

References

1. Javangula K, Cole J, Cross M, Kay PH (2010 Dec) An unusual manifestation of left partial anomalous pulmonary venous connection. Interactive cardiovascular and thoracic surgery. 11:846–847 PubMed PMID: 20805252. Epub 2010/09/02. eng. 6
2. Senocak F, Ozme S, Bilgiç A, Ozkutlu S, Ozer S, Saraçlar M (1994 Jan) Partial anomalous pulmonary venous return. Evaluation of 51 cases. Japanese heart journal 35(1):43–50 PubMed PMID: 8201780. Epub 1994/01/01. eng
3. Tourmousoglou C, Kalogeropoulou C, Koletsis E, Charoulis N, Prokakis C, Alexopoulos P et al (2014) Right upper lobe partial anomalous pulmonary venous connection.Case reports in vascular medicine.

; 2014:249896. PubMed PMID: 24716092. Pubmed Central PMCID: PMC3971852. Epub 2014/04/10. eng.

4. Arı S, Arı H, Vatansever F, Melek M, Bozat T (2020 Nov) Transcatheter treatment of partial anomalous pulmonary venous connection to left subclavian vein. Turk Kardiyoloji Dernegi arsivi: Turk Kardiyoloji Derneginin yayin organidir. 48:771–774 PubMed PMID: 33257612. Epub 2020/12/02. Sol subklavyen vene olan anormal pulmoner venöz bağlantının perkütan tedavisi. eng. 8
5. Saedi S, Saedi T (2018 Jun) Catheter intervention for abnormal pulmonary venous drainage. The Egyptian heart journal: (EHJ) : official bulletin of the Egyptian Society of Cardiology. 70:125–127 PubMed PMID: 30166894. Pubmed Central PMCID: PMC6112374. Epub 2018/09/01. eng. 2
6. Wilson W, Horlick E, Benson L (2015 Jun) Successful transcatheter occlusion of an anomalous pulmonary vein with dual drainage to the left atrium. Catheterization and cardiovascular interventions: official journal of the Society for Cardiac Angiography & Interventions. 85:1212–1216 PubMed PMID: 25384927. Epub 2014/11/12. eng. 7
7. Olasinska-Wisniewska A, Grygier M (2019) Antithrombotic/Antiplatelet Treatment in Transcatheter Structural Cardiac Interventions-PFO/ASD/LAA Occluder and Interatrial Shunt Devices.Frontiers in cardiovascular medicine. ; 6:75. PubMed PMID: 31231662. Pubmed Central PMCID: PMC6568033. Epub 2019/06/25. eng.

Figures

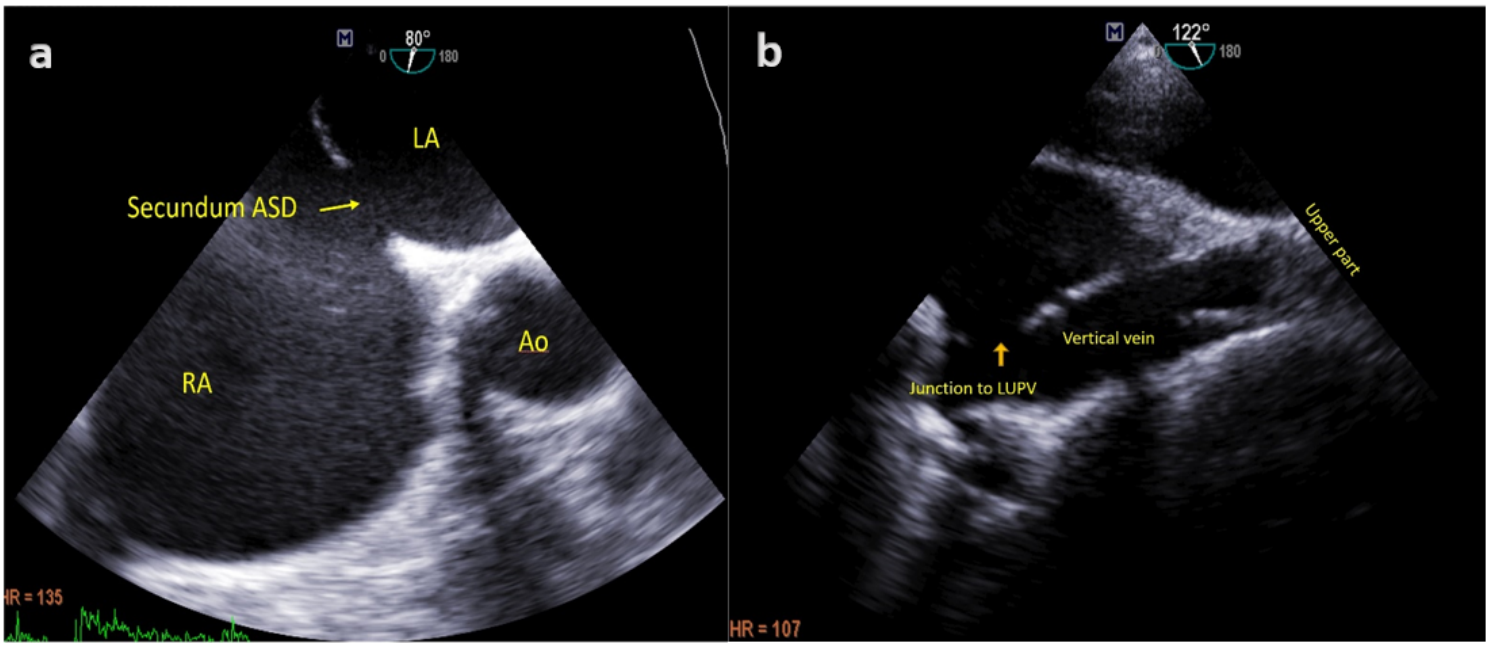

Figure 1

Transesophageal echocardiography images. (a) Two-dimensional TEE image shows atrial septal defect and (b) vertical vein before device closure. LUPV: Left upper pulmonary vein, LA: Left atrium, RA: Right atrium, Ao: Aorta.

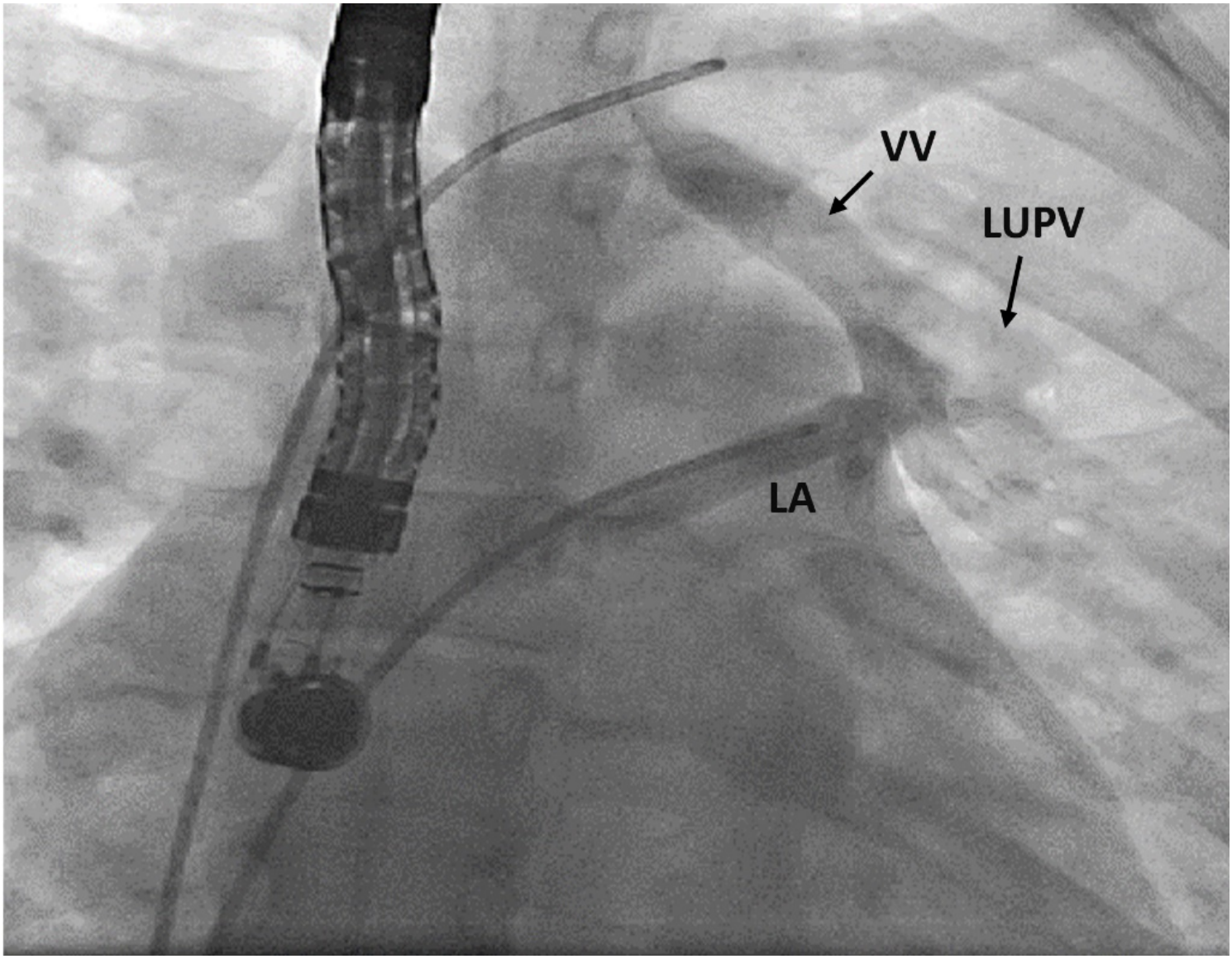

Figure 2

The catheter was positioned in the left pulmonary vein, where the angiography was performed. VV: Vertical vein, LA: Left atrium; LUPV: Left upper pulmonary vein.

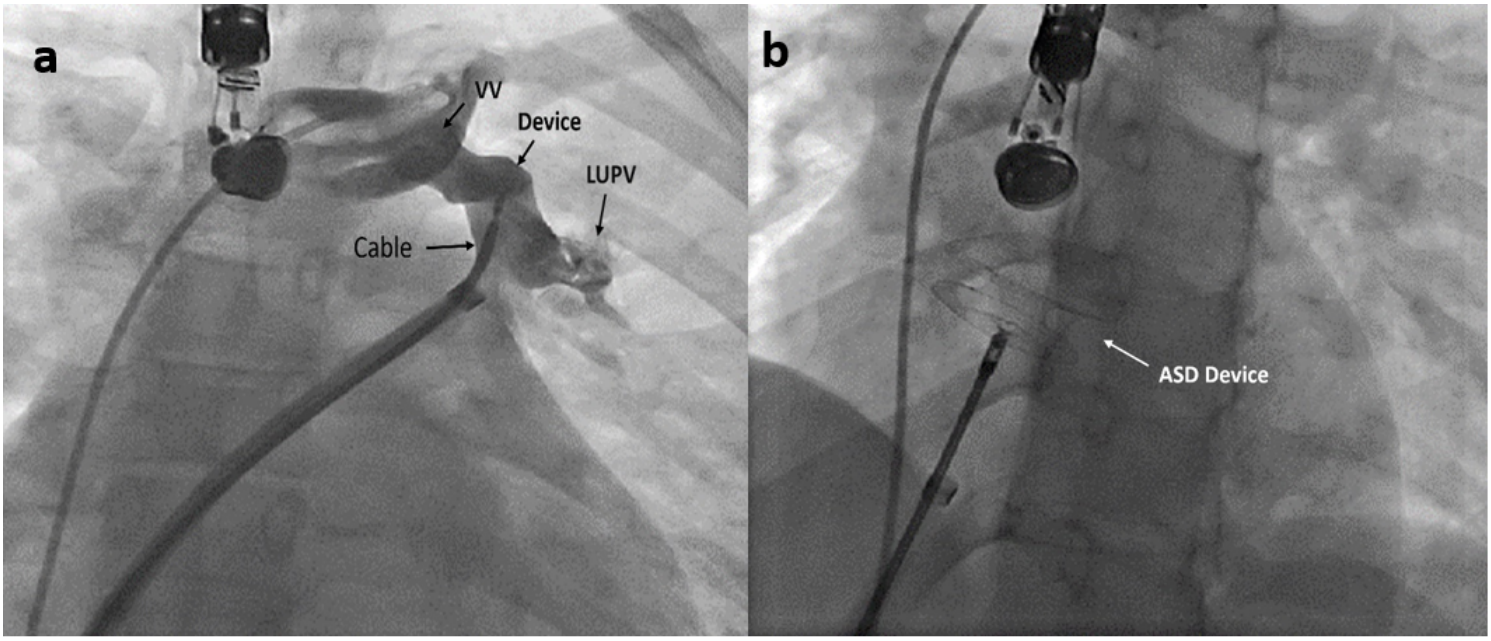

Figure 3

Angiogram demonstrate (a) VSD occluder device in proper position in the abnormal connection without significant residual flow into the left atrium and (b) ASD device. VV: Vertical vein, LUPV: Left upper pulmonary vein.

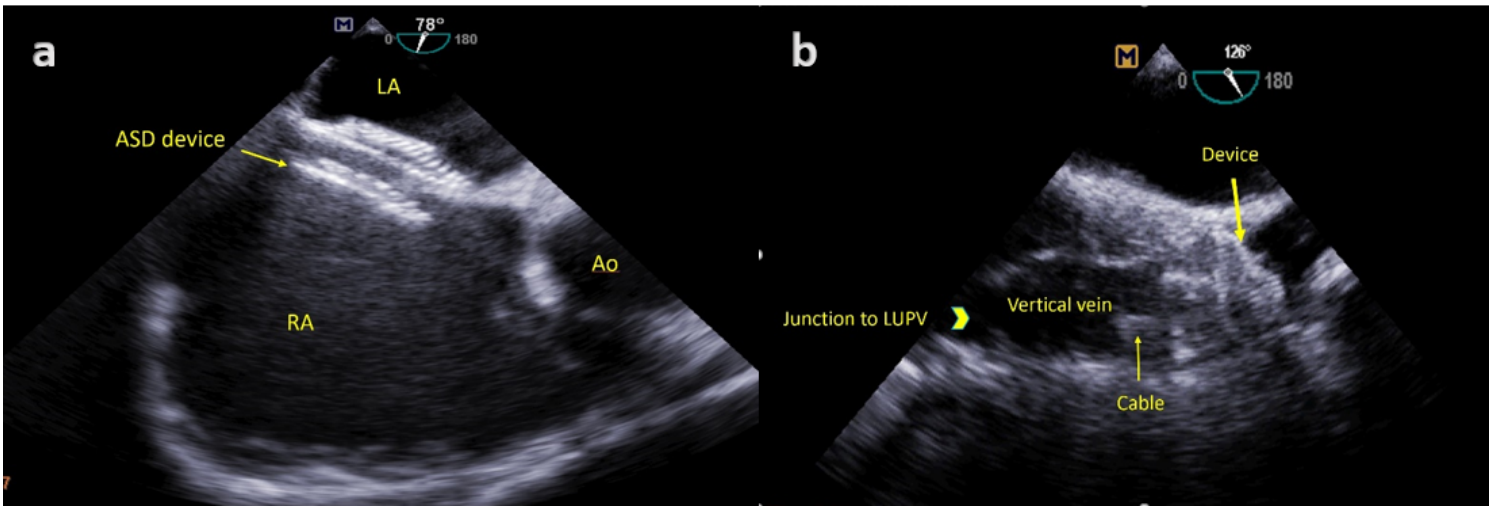

Figure 4

Transesophageal echocardiography images. The images show (a) the ASD device deployed in an appropriate position and (b) the VSD occluder device with complete occlusion of the vertical vein. LUPV: Left upper pulmonary vein, LA: Left atrium, RA: Right atrium, Ao: Aorta.

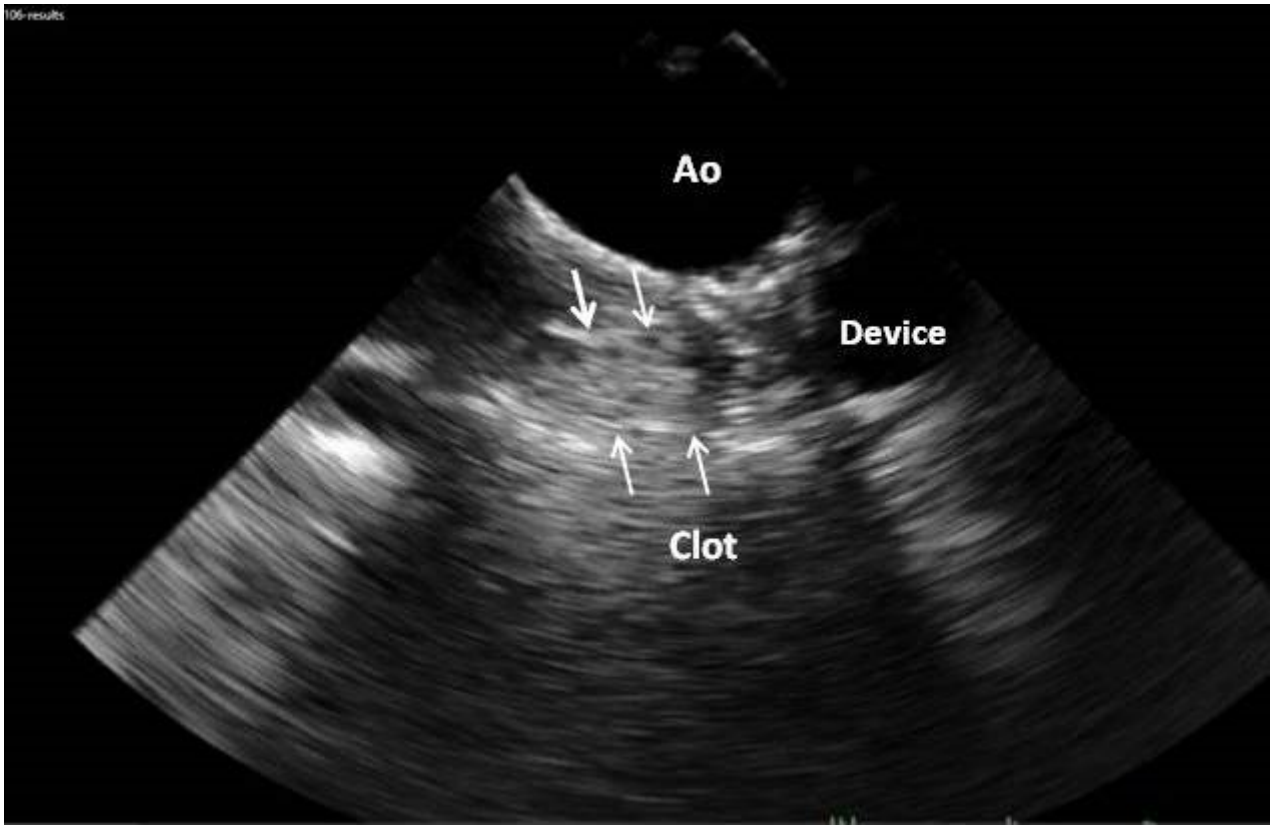

Figure 5

Transesophageal echocardiography images. It shows the clot formation back to the device in the vertical vein.