The accuracy of first metatarsophalangeal joint palpation guided injections. An arthrography cadaveric study

Ian Neil Reilly (ianreilly@nhs.net)
Northamptonshire Healthcare NHS Foundation Trust https://orcid.org/0000-0002-2786-5739

Roozbeh Naemi
Staffordshire University

Nachiappan Chockalingam
Staffordshire University

Research Article

Keywords: First metatarsophalangeal joint, steroid, injection, injectable medicine safety, hallux limitus, hallux rigidus, osteoarthritis, accuracy

Posted Date: April 25th, 2022

DOI: https://doi.org/10.21203/rs.3.rs-1519780/v1

Abstract

Background

Injectable glucocorticoids are widely used in the management of foot pathology, in particular for the treatment of osteoarthritis of the great toe - hallux limitus/rigidus. Injections can be performed using anatomical (blind) guided methods or performed with needle placement aided by the use diagnostic imaging with ultrasound or fluoroscopy, with or without the use of contrast media.

Aim

Palpation and image guided injection techniques have been studied in other joints of the body but less so for the first metatarsophalangeal joint of the foot, where palpation guidance is commonly performed. The aim of this study was to investigate the injection accuracy of palpation guided injections of the first metatarsophalangeal joint in six cadaveric feet using radio-opaque contrast media.

Methods

The injection equipment consisted of a 2.5ml Luer lock syringe and a 23-gauge needle used to inject iohexol (Omnipaque 300) into the first metatarsophalangeal joint in six cadaveric specimens. The needle was placed into the joint space by a single practitioner using palpation guidance. The contrast media was injected under live (cine) view without further movement or ingress of the needle. The injectate was considered accurate if the media coated the inside of the synovial membrane and/or outlined the joint shape.

Findings

Failure of technique was seen in one of six feet, and extravasation of contrast media beyond the joint margins noted in three out of six feet.

Conclusions

Further study on a large sample of live subjects using a variance of technique is required to expand the confidence of these findings but the high failure rate calls into question the confidence of palpation guided techniques for injection of the first metatarsophalangeal joint.

Introduction

Background

Injection therapy for joint pathology is one of the most common therapeutic interventions in musculoskeletal healthcare (1–3). A needle is inserted into a joint for two main indications: aspiration of fluid (arthrocentesis) for diagnostic purposes or injection of medication(s) for therapeutic purposes (4,5). Most therapeutic injections into joints consist of a glucocorticoid, a local anaesthetic, or a combination

of the two, and are widely used in the treatment of foot pathology, in particular for the treatment of osteoarthritis of the first metatarsophalangeal joint (1st MTP jt) - hallux limitus/rigidus (6–25).

The 1st MTP jt is a condyloid synovial juncture (26); the metatarso-sesamoid complex consists of the head of the first metatarsal, the base of the proximal phalanx, two sesamoid bones and associated soft tissue attachments including the tendons, collateral ligaments, and a plantar plate complex (27,28). Injections into the joint can be performed using anatomical (palpation-guided) guided methods (29) or performed with needle placement aided by diagnostic imaging from ultrasound (US) or fluoroscopy, with or without the use of contrast media (12,25,30–45).

Arthrography

Injection of contrast media comes in two basic forms: injection via percutaneous needle access, such as direct arthrography, or injection via an indwelling catheter or tube, such as in cystography or sinography (46). Arthrography is the intra-articular (IA) injection of contrast media to improve the evaluation or visualisation of joint structures under imaging (i.e., outline the articular structures, and gives information on basic joint architecture) or for confirmation of needle placement prior to the intra articular delivery of medication(s) (47–49).

Aim

Palpation and image-guided techniques have been studied in other joints of the body but less so for the 1st MTP jt, where palpation guidance is commonly performed (50). Production of a best practice injection technique for the 1st MTP Jt by novice injectors has already been presented as part of this schema of work (29). The aim of this experiment was to investigate the accuracy of that technique using contrast media to confirm needle and injectate placement.

Methods

Ethical approval

The study was authorised by Innovation and Research Department, Northamptonshire Healthcare NHS Foundation Trust (NHFT) and approved by the Ethics Committee of Staffordshire University (ref: SPOR80004-2019-SPG2-2020-SPG1) as part of a professional doctorate programme.

Location of the study

The procedure room at Danetre Hospital, Daventry was used with access to handwashing and sharps disposal (see Fig. 1). The X-ray machine used was the InSight mini-C-arm fluoroscan (Hologic International, see Fig. 2)). Personal protective equipment (PPE) consisted of a standard lead x-ray gown and thyroid protector, sterile gown gloves, and eye protection. The Principal Investigator (PI) was Ian Reilly, with assistance from a Podiatric Surgery team member for additional photography. The PI is a Radiation Protection Supervisor and IR(ME)R-operator with authority and responsibility to direct and expose radiographic images. Standard safety precautions were followed, as per the (Northamptonshire Healthcare Foundation NHS Trust (NHFT) C-Arm protocol.

Figure 1: room set-up	Figure 2: cadaver set up

Cadaveric specimens

A total of six cadaveric feet from six individual donors were used for this investigation, which was the maximum number that were available at the time of the study (see Fig 2). All cadaveric feet were anonymous, fresh-frozen specimens, thawed overnight, and obtained from the Procedural Skills Laboratory at Nottingham City Hospital (NCH), and delivered via anatomy technologists to the NHFT Department of Podiatric Surgery, Danetre Hospital. The anatomy technologists were responsible for the transporting, safety, and safe return of all cadavers and at all times the feet were the responsibility of the NCH anatomical team. The cadavers were noted to be free from major deformity, trauma, or surgical changes. Three feet were right-sided, three were left-sided.

Procedure

A green (21-gauge needle) was used to draw up the injectate into a 2.5ml Luer lock syringe, and a blue (23-gauge needle) needle to inject the contrast media (see Fig.3). The injectate was iohexol [N,N´-Bis(2,3-dihydroxypropyl)-5-[N-(2,3-dihydroxypropyl)-acetamido]-2,4,6-triiodoisophthalamide], a non-ionic, water-soluble radiographic contrast medium, with a molecular weight of 821.14 and iodine content 46.36%.nn

(Omnipaque, GE Healthcare AS, Buckinghamshire, UK). Immediately prior to the study six identical syringes were prepared with 2.5ml of Omnipaque 300 (see Fig. 4).

Figure 3: injection equipment Figure 4: prepared injectate

All injections were performed by the PI using the following sequence:

1. The PI placed a blue, 23-gauge hypodermic needle in the 1st MTP jt in six cadaveric specimens using a standard palpation guided technique (see Figs. 5 and 6),
2. A pre-injection anterior-posterior (AP) x-ray was taken of the foot but with no change in position or further ingress of the needle (see Fig. 7),
3. 2ml of iohexol was injected into the joint space under live (cine) view ensuring safe distancing of the PI from the x-ray beam,
4. Following each injection, the foot was x-rayed in the AP and lateral (LAT) planes to confirm the location of contrast media placement (see Fig. 8 – AP view),
5. The injectate was considered accurate if the contrast media coated the inside of the synovial membrane and/or outlined the joint shape,
6. The contrast media was considered inaccurate if the dye did not coat the inside of the synovial membrane or outline the joint shape,
7. Each injection/x-ray sequence took between 3-5 minutes,
8. All X-rays were stored on secure NHS server for further assessment,
9. The results were tabulated and subject to further analysis (see table 1).

See supplementary video material.

Figure 5: needle placement in the 1st MTP jt

Figure 6: image taken pre contrast placement (at safe distance)

Figure 7: pre-injection x-ray Figure 8: post-injection x-ray

Results

The results are at table 1 (see Figs. 9-14). An extra, pre-infiltration, lateral x-ray was taken of case 1 only, prior to injection of the contrast media. No lateral view was taken for case 1 owing to the surprising failure in technique. Five out of the six injections were accurate with the contrast media coating the inside of the synovial capsule. However, three of five accurate injections (cases 3, 4 and 5) showed some extravasation of the contrast media beyond the joint space: two plantar-proximally and one dorso-medially and proximally.

Table 1: results of contrast media placement

Case	Accurate?	Leakage	Remarks
1	Yes	No	One extra pre-injection lateral X-ray view demonstrating good needle placement prior to injection
2	No	NA	Significant extra-capsular leakage medially, and proximally via a digital vessel; no lateral view taken
3	Yes	Yes	Accurate injection but slight leakage of dye plantar-proximally
4	Yes	Yes	Accurate injection but moderate leakage dorso-medial and proximally
5	Yes	Yes	Accurate injection but slight leakage of dye plantar-proximally
6	Yes	No	Dorsal joint mouse seen on encircled with dye on lateral view but within synovial membrane

Figure 9: a-d, case 1

Figure 10: a-b, case 2

Figure 11: a-c, case 3

Figure 12: a-c, case 4

Figure 13: a-c, case 5

Figure 14: a-c, case 6

The cadavers were subsequently used as part of a cadaveric surgery dissection course for podiatric surgery students. On specimen 1, following dissection of the soft tissues and subcutaneous layer away from the joint capsule, a 1.0mm Kirschner (K) wire was inserted into the joint using the standard palpation guided technique. With minimal extra advancement of the K-wire, the tip exited the capsule dorso-laterally (see Figs. 15 and 16). A wider discussion around technical failure will be the subject of a subsequent article.

Figure 15: K-wire pass through Figure 16: close-up view

Discussion

Koski *et al* (45) state that palpation guided injection of joints and soft tissues is an important clinical skill used in everyday work by clinicians in several specialty fields. Naylor *et al* (50) had 18 emergency medicine residents perform four US and four landmark (LM) guided aspirations each of 1st MTP jt simulated effusions in fresh-frozen cadavers. A total of 144 joint aspirations were attempted: 72 by US and 72 by LM guidance. In their study, US did not prove superior to LM for first-pass aspiration of 1st MTP jt effusions. The PI was expecting to see 100% accurate injections in this study and therefore the complete failure of technique in case two was surprising. Further work is now planned to identify the reasons for - and management of - injection technique failure. Three of the five accurate injections had significant extra-capsular leakage which may predispose to complications such as atrophy and tendon rupture (51–56). Further, the live (cine) view demonstrates the contrast media infiltrating the medial tissues then intravenously entering one of the digital vessels and coursing proximally. This has implications for the under-reported risk of accidental intravenous injection. Regrading contrast media, Wang *et al*. (57) note that most patients in whom extravasations of nonionic iodinated contrast medium occur rarely result in moderate or severe adverse effects but McAlister and Palmer (58) note that an acute local inflammatory response from contrast media may not peak until 24 to 48 hours post procedure.

Derian *et al.* (38) state that smaller joints, such as the first carpometacarpal joint (CMC) are often affected by degenerative joint conditions that may benefit from therapeutic injections. They hypothesised that image guidance may be useful for accurate needle placement in these smaller joints but in an ultrasound vs palpation guided latex dye injection cadaveric study of the 1st CMC jt, they found no difference between the two methods. However, injectate placement accuracy - judged on a four-point scale after dissection of the joint - found that most of the injections (59.7%) were 50%, or less, accurate.

Pollard *et al.* (59) investigated the accuracy of IA injection of the basal thumb joint and to determine the rate of soft-tissue extravasation of injected material in successful IA injection. The authors injected 30

cadaveric hands with radiopaque dye - with fluoroscopy-guided needle placement in 8 cases - and then used fluoroscopy to check injection accuracy. The results were recorded depending on the location of the injected dye under fluoroscopic examination. The rates of IA accuracy and soft-tissue extravasation for successful IA injections were 100% and 25% for the fluoroscopy guided group and 81.8% and 33% for the "blind" group. The authors discuss that this is a relatively high soft tissue extravasation rate for successful IA injection with the implications for drug extravasation into the surrounding extra-articular space presumed to be similar to those cited for failed needle placement. The authors also recommend injecting a drug at an appropriate volume. In their study, 0.2-0.5mL were injected; they note that a palpable endpoint was difficult to detect but they suggest that forcing excess fluid into the joint space may induce a painfully distended capsule and that care must be exercised during injections to prevent excessive internal pressurization of the capsule. The authors accept the shortcomings of their study viz using preserved cadaveric specimens for injection where surface anatomy (and joint mobility) is more difficult to identify in stiff, embalmed specimens.

The local pathological changes and the experience of the clinician are also relevant. Heidari *et al*. (60) found that the presence of pathologic changes reduces the rate of successful IA puncture, but that the overall frequency of successful IA injections can be improved through experience and the use of imaging. In their study a total of 106 cadaveric 1st MTP jts were injected with a methylene blue solution and then dissected to distinguish IA from periarticular injections. To evaluate the importance of experience, 38 injections were performed by a student, 38 by a trained resident, and 30 by an experienced surgeon. In the second part of the study, the authors examined the relation of pathologic findings of the MTP jt and the accuracy of IA injection. The overall rate of unintentional periarticular injections was low (9.4%; 10 of 106 joints). The student achieved a successful IA injection in 86.8% of joints (33 of 38), the resident in 92.1% (35 of 38), and the specialist in 93.3% (28 of 30). The number of extra-articular injections increased significantly with the presence of deformity (hallux valgus) or osteoarthritis of the 1st MTP jt.

Curtiss *et al.* (61) found that the accuracy of supero-lateral, palpation-guided knee injections were significantly influenced by experience, with a less-experienced investigator demonstrating an accuracy rate of only 55% compared to a more experienced investigator demonstrating an accuracy rate of 100%. At the time of the investigation, the senior author had 19 years of experience in injection therapy of the foot and ankle, including 14 years' experience in teaching injection techniques to podiatrists and trainee podiatric surgeons, nationally and internationally. The overall implication of our study is therefore that palpation guided injections of the 1st MTP jt has a significant failure rate, in this series despite the experience of the PI. This calls into question the accuracy of palpation guidance for the 1st MTP Jt.

Systematic reviews by Gilliland *et al.* (62) and Huang *et al.* (63) confirm that injection accuracy is improved with the use of US guidance over palpation-guidance. Over advancement of the needle into and out of the joint could be one reason for technique failure. Compounding the failure could be the length of the needle. Typically, the author recommends a 1¼ inch 23-gauge (blue) needle as the standard for 1st MTP jt injections. A shorter needle, for instance the ¾ inch 25-gauge (orange) needle might be less prone to 'overshooting the target'. These factors will be discussed in greater detail in a subsequent paper.

This study had several limitations that warrant discussion. The first consideration is the sample size. Only six specimens were available at the time of the study, which was insufficient to carry out statistical analysis. Consideration was given to performing a post-hoc power calculation but as the main effort of this study was to look at needle accuracy, and this was therefore discounted. Future studies would benefit not only from having a larger sample size and performed using live subjects with confirmed metatarsal phalangeal joint pathology (rather than cadaver specimens). Use of fresh frozen over embalmed specimens was considered to be as close to a realistic clinical scenario as possible, and injection equipment used was exactly that as used by the author in clinical practice but as Smith *et al* (64,65) and Pollard *et al.* (59) state in their studies, clinicians may wish to exercise caution when extrapolating cadaveric data into clinical populations.

Conclusion

The accuracy of palpation-guided injections of the 1st MTP jt was assessed in an arthrography cadaveric study. In this study there was a complete failure of technique in one of six cases and significant extra-capsular leakage in three out of six cases. Further work is required to identify the reasons for - and management of - injection technique failure.

References

1. Rozental TD, Sculco TP. Intra-articular corticosteroids: an updated overview. Am J Orthop (Belle Mead NJ). 2000;29(1):18–23.

2. von Stechow D, Rittmeister M. Die intraartikuläre injektion. Substanzen und techniken. Orthopade. 2003 Dec;32(12):1127–35. doi: 10.1007/s00132-003-0564-5

3. Wittich CM, Ficalora RD, Mason TG, Beckman TJ. Musculoskeletal Injection: Concise review for clinicians. Vol. 84, Mayo Clin Proc. 2009. doi: 10.4065/84.9.831

4. Roberts WN. Joint aspiration or injection in adults: Technique and indications. UpToDate. 2020; [accessed 12 Jan 2021] Available from: https://somepomed.org/articulos/contents/mobipreview.htm?24/19/24893#H1

5. de Zordo T, Mur E, Bellmann-Weiler R, Sailer-Höck M, Chhem R, Feuchtner GM, et al. US guided injections in arthritis. Vol. 71, European Journal of Radiology. 2009. p. 197–203. doi: 10.1016/j.ejrad.2009.04.047

6. Al-Jabri T, Charalambides C. First metatarsophalangeal joint injections: the “Sulcus Sign” technique. Clinics in Surgery. 2019;4(Article 2429):1–2. Available from: http://clinicsinsurgery.com/

7. Boxer MC. Osteoarthritis involving the metatarsophalangeal joints and management of metatarsophalangeal joint pain via injection therapy. Clin Podiatr Med Surg. 1994;11(1):125–32.

8. Anderson MR, Ho BS, Baumhauer JF. Current concepts: Hallux rigidus. Foot & Ankle Orthopaedics. 2018 Jun;3(2):247301141876446. doi: 10.1177/2473011418764461

9. Bilstrom E, O’Rourke KS, Deodhar A. Aspiration and injection of the metatarsophalangeal joints. The Journal of Musculoskeletal Medicine. 2007;24(12):517–8.

10. Courtney P, Doherty M. Joint aspiration and injection. Vol. 19, Best Practice and Research: Clinical Rheumatology. Bailliere Tindall Ltd; 2005. p. 345–69. doi: 10.1016/j.berh.2005.01.009

11. Kilmartin TE. Corticosteroid injection therapy in Podiatry. Podiatry Now. 2017;February:CPD Suppl 1-11.

12. Sahler CS, Spinner DA, Kirschner JS. Ultrasound-guided first metatarsophalangeal joint injections: Description of an in-plane, gel standoff technique in a cadaveric study. Foot and Ankle Specialist. 2013 Aug;6(4):303–6. doi: 10.1177/1938640013493465

13. Uthman I, Raynauld J-P, Haraoui B. Intra-articular therapy in osteoarthritis. Postgrad Med J. 2003;79:449–453. Available from: http://pmj.bmj.com/

14. Tallia AF, Cardone DA. Diagnostic and therapeutic injection of the ankle and foot. 2003. [accessed 1 Apr 2022] Available from: https://www.aafp.org/afp/2003/1001/p1356.html

15. Reilly IN, Bromley G, Flanagan G. A systematic review of injectable corticosteroid for osteoarthritis of the first metatarsophalangeal joint. The Foot and Ankle Online Journal. 2020;13(3). [accessed 3 Jan 2021] Available from: http://faoj.org/2020/09/30/a-systematic-review-of-injectable-corticosteroid-for-osteoarthritis-of-the-first-metatarsophalangeal-joint/

16. Vanore J v., Christensen JC, Kravitz SR, Schuberth JM, Thomas JL, Weil LS, et al. Diagnosis and treatment of first metatarsophalangeal joint disorders. Section 2: hallux rigidus. The Journal of Foot and Ankle Surgery. 2003;42(3):124–36. doi: 10.1053/jfas.2003.50037

17. Solan MC, Calder JDF, Bendall SP. Manipulation and injection for hallux rigidus. Is it worthwhile? The Journal of Bone and Joint Surgery. 83-B(5):706–8. doi: 10.1302/0301-620X.83B5.0830706

18. Lam A, Chan JJ, Surace MF, Vulcano E. Hallux rigidus: How do I approach it? World Journal of Orthopaedics. 2017 May 18;8(5):364–71. doi: 10.5312/wjo.v8.i5.364

19. Sarkin TL. Indications for intra-articular steroid in osteo-arthritis of the ankle and big toe joints. SA Medical Journal. 1974;2067.

20. Ward ST, Williams PL, Purkayastha S. Intra-articular corticosteroid injections in the foot and ankle: a prospective 1-year follow-up investigation. Journal of Foot and Ankle Surgery. 2008 Mar;47(2):138–44. doi: 10.1053/j.jfas.2007.12.007

21. Manadan AM, Mushtaq S, Block JA. Radiocarpal and first metatarsophalangeal intraarticular injection site confirmation with fluoroscopy and review of accuracy of intraarticular injections. American Journal of Therapeutics. 2015;11–3. Available from: www.americantherapeutics.com

22. Grice J, Marsland D, Smith G, Calder J. Efficacy of foot and ankle corticosteroid injections. Foot and Ankle International. 2017 Jan 1;38(1):8–13. doi: 10.1177/1071100716670160

23. Ajwani S, Kocialkowski C, Hill R, Kurdy N. Manipulation under anaesthesia and steroid injection for pain and stiffness after surgery to the first metatarsophalangeal joint. Foot. 2018 Mar 1;34:36–9. doi: 10.1016/j.foot.2017.11.009

24. King CKK, Loh Sy J, Zheng Q, Mehta K v. Comprehensive review of non-operative management of hallux rigidus. Cureus. 2017 Jan 21; doi: 10.7759/cureus.987

25. Lungu E, Moser TP. A practical guide for performing arthrography under fluoroscopic or ultrasound guidance. Vol. 6, Insights into Imaging. Springer Verlag; 2015. p. 601–10. doi: 10.1007/s13244-015-0442-9

26. McSweeney S. First metatarsophalangeal joint osteoarthritis. A clinical review. Journal of Novel Physiotherapies. 2016;06(03):1–4. doi: 10.4172/2165-7025.1000293

27. Alvarez R, Haddad RJ, Gould N, Trevino S, Alvarez RG. The simple bunion: anatomy at the metatarsophalangeal joint of the great toe. Foot & Ankle. 1984;4(5):229–40. doi: 10.1177/107110078400400502

28. Hallinan JTPD, Statum SM, Huang BK, Bezerra HG, Garcia DAL, Bydder GM, et al. High-resolution MRI of the first metatarsophalangeal joint: gross anatomy and injury characterization. RadioGraphics. 2020 May 15;190145. Available from: http://pubs.rsna.org/doi/10.1148/rg.2020190145

29. Reilly I. Palpation-guided intra-articular injection of the first metatarsophalangeal joint: Injection technique and safe practice for novice practitioners. SN Comprehensive Clinical Medicine. 2021 Jan 8; doi: 10.1007/s42399-020-00719-w

30. Muir JJ, Curtiss HM, Hollman J, Smith J, Finnoff JT. The accuracy of ultrasound-guided and palpation-guided peroneal tendon sheath injections. American Journal of Physical Medicine and Rehabilitation. 2011 Jul;90(7):564–71. doi: 10.1097/PHM.0b013e31821f6e63

31. Yablon C. Ultrasound-guided interventions of the foot and ankle. Seminars in Musculoskeletal Radiology. 2013;17(1):60–8. doi: 10.1055/s-0033-1333916

32. Hansford BG, Mills MK, Hanrahan CJ, Yablon CM. Pearls and pitfalls of fluoroscopic-guided foot and ankle injections: what the radiologist needs to know. Vol. 48, Skeletal Radiology. Springer Verlag; 2019. p. 1661–74. doi: 10.1007/s00256-019-03226-9

33. Sofka CM, Adler RS. Ultrasound-guided interventions in the foot and ankle. Seminars in Musculoskeletal Radiology. 2002;6(2). doi: 10.1055/s-2002-32362

34. Yun JS, Chung MJ, Kim HR, So JI, Park JE, Oh HM, et al. Accuracy of needle placement in cadavers: Non-guided versus ultrasound-guided. Annals of Rehabilitation Medicine. 2015;39(2):163–9. doi: 10.5535/arm.2015.39.2.163

35. Wisniewski SJ, Smith J, Patterson DG, Carmichael SW, Pawlina W. Ultrasound-guided versus nonguided tibiotalar joint and sinus tarsi injections: A cadaveric study. PM and R. 2010 Apr;2(4):277–81. doi: 10.1016/j.pmrj.2010.03.013

36. To P, McClary KN, Sinclair MK, Stout BA, Foad M, Hiratzka S, et al. The accuracy of common hand injections with and without ultrasound: an anatomical study. Hand. 2017 Nov 1;12(6):591–6. doi: 10.1177/1558944717692086

37. Drakonaki EE, Kho JSB, Sharp RJ, Ostlere SJ. Efficacy of ultrasound-guided steroid injections for pain management of midfoot joint degenerative disease. Skeletal Radiology. 2011 Aug;40(8):1001–6. doi: 10.1007/s00256-010-1094-y

38. Derian A, Amundson J, Abi-Aad K, Vasquez-Duarte R, Johnson-Greene D. Accuracy of ultrasound-guided versus palpation-based carpometacarpal joint injections: A randomized pilot study in cadavers. Ultrasound. 2018 Nov 1;26(4):245–50. doi: 10.1177/1742271X18789711

39. Soneji N, Peng PWH. Ultrasound-guided interventional procedures in pain medicine: a review of anatomy, sonoanatomy, and procedures: part vi: ankle joint. Vol. 41, Regional Anesthesia and Pain Medicine. Lippincott Williams and Wilkins; 2016. p. 99–116. doi: 10.1097/AAP.0000000000000344

40. Peck E, Finnoff JT, Smith J, Curtiss H, Muir J, Hollman JH. Accuracy of palpation-guided and ultrasound-guided needle tip placement into the deep and superficial posterior leg compartments. American Journal of Sports Medicine. 2011 Sep;39(9):1968–74. doi: 10.1177/0363546511406235

41. Cunnington J, Marshall N, Hide G, Bracewell C, Isaacs J, Platt P, et al. A randomized, double-blind, controlled study of ultrasound-guided corticosteroid injection into the joint of patients with inflammatory

arthritis. Arthritis and Rheumatism. 2010 Jul;62(7):1862–9. doi: 10.1002/art.27448

42. Babaei-Ghazani A, Roomizadeh P, Forogh B, Moeini-Taba SM, Abedini A, Kadkhodaie M, et al. Ultrasound-Guided versus landmark-guided local corticosteroid injection for carpal tunnel syndrome: a systematic review and meta-analysis of randomized controlled trials. Vol. 99, Archives of Physical Medicine and Rehabilitation. 2018. doi: 10.1016/j.apmr.2017.08.484

43. Huang Z, Du S, Qi Y, Chen G, Yan W. Effectiveness of ultrasound guidance on intraarticular and periarticular joint injections. American Journal of Physical Medicine & Rehabilitation. 2015; doi: 10.1097/phm.0000000000000260

44. Reach JS, Easley ME, Chuckpaiwong B, Nunley JA. Accuracy of ultrasound guided injections in the foot and ankle. Foot and Ankle International. 2009 Mar;30(3):239–42. doi: 10.3113/FAI.2009.0239

45. Koski JM, Hermunen HS, Kilponen V-M, Saarakkala SJ, Hakulinen UK, Heikkinen JO. Verification of palpation-guided intra-articular injections using glucocorticoid-air-saline mixture and ultrasound imaging (GAS-graphy). Clin Exp Rheumatol. 2006;24(3):247–52. Available from: https://www.researchgate.net/publication/6916476

46. Pasternak JJ, Williamson EE. Clinical pharmacology, uses, and adverse reactions of iodinated contrast agents: A primer for the non-radiologist. Vol. 87, Mayo Clinic Proceedings. Elsevier Ltd; 2012. p. 390–402. doi: 10.1016/j.mayocp.2012.01.012

47. Carter K, Mudigonda S. Arthrography and injection procedures. In: Weissman BN, editor. Imaging of Arthritis and Metabolic Bone Disease. Elsevier Inc.; 2009. p. 60–80. doi: 10.1016/B978-0-323-04177-5.00005-7

48. Masala S, Fiori R, Bartolucci DA, Mammucari M, Angelopoulos G, Massari F, et al. Diagnostic and therapeutic joint injections. Seminars in Interventional Radiology. 2010;27(2):160–71. doi: 10.1055/s-0030-1253514

49. Perlman MD. Use of radiopaque contrast media in the foot and ankle. The Journal of Foot Surgery. 1988;27(1):3–29.

50. Naylor JF, Dekay KB, Donham BP, Hall BT. Ultrasound versus landmarks for great toe arthrocentesis. Military Medicine. 2017 Mar 1;182:216–21. doi: 10.7205/MILMED-D-16-00055

51. Brinks A, Koes BW, Volkers AC, Verhaar JAN, Bierma-Zeinstra SMA. Adverse effects of extra-articular corticosteroid injections: A systematic review. BMC Musculoskeletal Disorders. 2010;11. doi: 10.1186/1471-2474-11-206

52. Cole BJ, Schumacher HR. Injectable corticosteroids in modern practice. J Am Acad Orthop Surg. 2005;13(1):37–46.

53. Honcharuk E, Monica J. Complications associated with intra-articular and extra-articular corticosteroid injections. Vol. 4, JBJS Reviews. Journal of Bone and Joint Surgery Inc.; 2016. doi: 10.2106/JBJS.RVW.16.00004

54. Kompel AJ, Roemer FW, Murakami AM, Diaz LE, Crema MD, Guermazi A. Intra-articular corticosteroid injections in the hip and knee: Perhaps not as safe as we thought? Radiology. 2019;293(3):656–63. doi: 10.1148/radiol.2019190341

55. Lavelle W, Lavelle ED, Lavelle L. Intra-articular injections. Vol. 25, Anesthesiology Clinics. 2007. p. 853–62. doi: 10.1016/j.anclin.2007.07.002

56. Anderson SE, Lubberts B, Strong AD, Guss D, Johnson AH, DiGiovanni CW. Adverse events and their risk factors following intra-articular corticosteroid injections of the ankle or subtalar joint. Foot and Ankle International. 2019 Jun 1;40(6):622–8. doi: 10.1177/1071100719835759

57. Wang CL, Cohan RH, Ellis JH, Adusumilli S, Dunnick NR. Frequency, management, and outcome of extravasation of nonionic iodinated contrast medium in 69 657 intravenous injections. Radiology. 2007 Apr;243(1):80–7. doi: 10.1148/radiol.2431060554

58. McAlister WH, Palmer K. The histologic effects of four commonly used media for excretory urography and an attempt to modify the responses. Radiology. 1971;99(3):511–9. doi: 10.1148/99.3.511

59. Pollard MA, Cermack MB, Buck WR, Williams DP. Accuracy of injection into the basal joint of the thumb. The American Journal of Orthopedics. 2007;36(4):204–6.

60. Heidari N, Kraus T, Fischerauer S, Tesch N, Weinberg A. Do the presence of pathologic changes and the level of operator experience alter the rate of intra-articular injection of the first metatarsophalangeal joint? A cadaver study. J Am Podiatr Med Assoc. 2013;103(3):204–7. doi: 10.7547/1030204

61. Curtiss HM, Finnoff JT, Peck E, Hollman J, Muir J, Smith J. Accuracy of ultrasound-guided and palpation-guided knee injections by an experienced and less-experienced injector using a superolateral approach: a cadaveric study. PM and R. 2011 Jun;3(6):507–15. doi: 10.1016/j.pmrj.2011.02.020

62. Gilliland CA, Salazar LD, Borchers JR. Ultrasound versus anatomic guidance for intra-articular and periarticular injection: a systematic review. Vol. 39, The Physician and sportsmedicine. 2011. p. 121–31. doi: 10.3810/psm.2011.09.1928

63. Huang Z, Du S, Qi Y, Chen G, Yan W. Effectiveness of ultrasound guidance on intraarticular and periarticular joint injections: Systematic review and meta-analysis of randomized trials. American Journal of Physical Medicine and Rehabilitation. 2015 Oct 20;94(10):775–83. doi: 10.1097/PHM.0000000000000260

64. Smith J, Brault JS, Rizzo M, Sayeed YA, Finnoff YT. Accuracy of sonographically guided and palpation guided scaphotrapezio-trapezoid joint injections. J Ultrasound Med. 2011;30(11):1509–15. doi:

10.7863/jum.2011.30.11.1509

65. Smith J, Finnoff JT, Levy BA, Lai JK. Sonographically guided proximal tibiofibular joint injection. Technique and accuracy. Ultrasound Med 2010; 29:783–789. 2010;29(5):783–9. doi: 10.7863/jum.2010.29.5.783

Declarations

Ethics approval and consent to participate: this project was completed as part the Professional Doctorate in Healthcare Science and is covered by Staffordshire University Ethics committee policy.

Consent for publication: NA.

Availability of data and material: available on request.

Competing interests: the authors have no competing interests to declare.

Acknowledgments: our thanks are extended to the technicians and staff of the Anatomy Laboratory of Nottingham City Hospital who provided the cadaveric materials. Thanks also to Sharon Taylor, Clinical Assistant in Podiatric Surgery, NHFT, for help with the cadaveric examinations.

Funding: this research did not receive any grant from funding agencies in the public, commercial, or not-for-profit sectors.

Authors' contributions: IR conceived the aim and format of the paper. IR performed the literature search and produced the first draft of the paper. All authors made substantial contributions to the final version.

Authors' information:

INR: https://orcid.org/0000-0002-2786-5739

RN: https://orcid.org/0000-0002-2998-2883

NC: https://orcid.org/0000-0002-7072-1271

Corresponding author:

Ian Reilly: ianreilly@nhs.net.

Department of Podiatric Surgery

Northamptonshire Healthcare Foundation NHS Trust

Danetre Hospital

Daventry

Northamptonshire

NN11 4DY. UK

(+44) 01327 708102

Figures

Figure 1

room set-up

Figure 2

cadaver set up

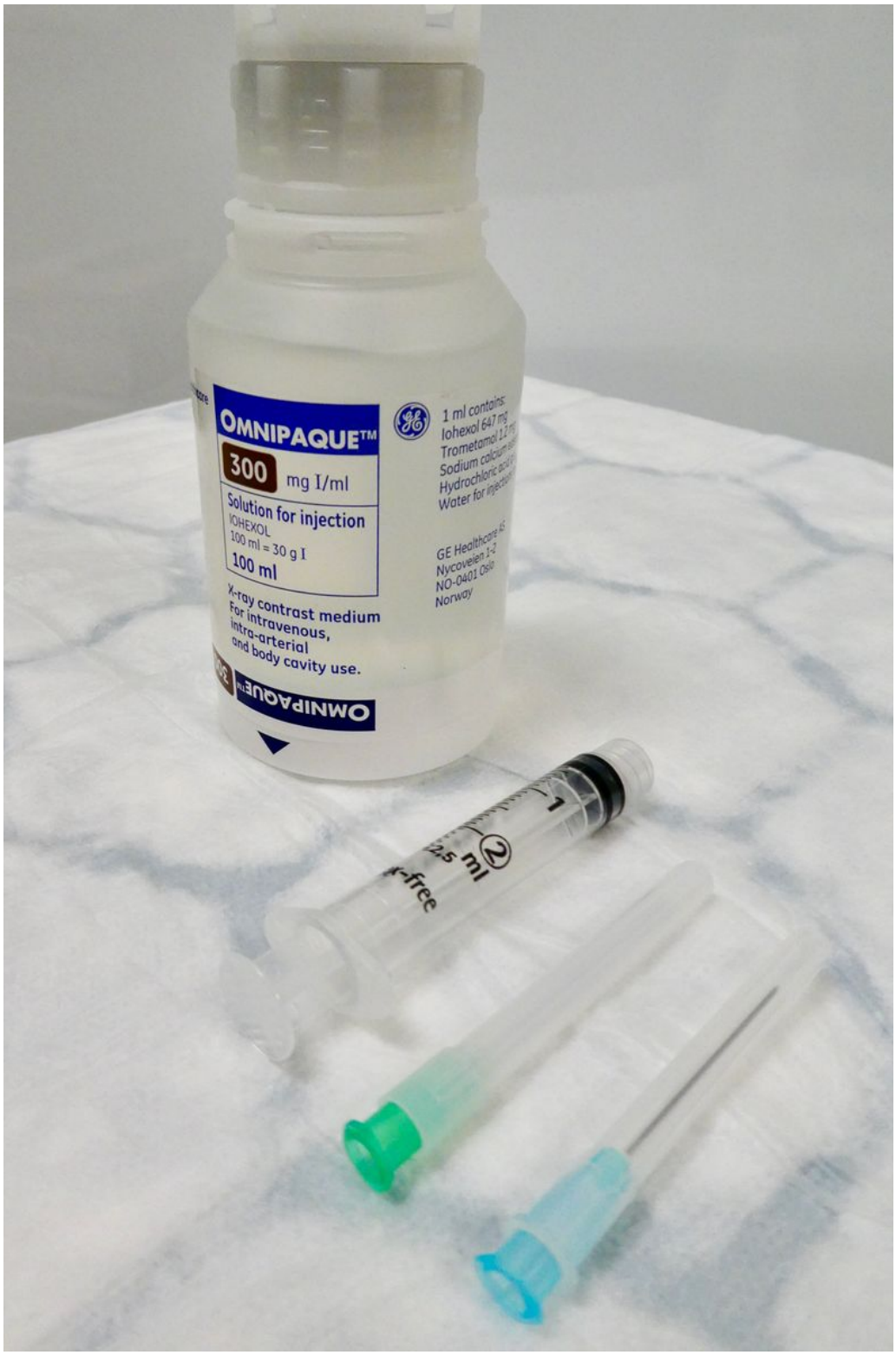

Figure 3

injection equipment

Figure 4

prepared injectate

Figure 5

needle placement in the 1st MTP jt

Figure 6

image taken pre contrast placement (at safe distance)

Figure 7

pre-injection x-ray

Figure 8

post-injection x-ray

Figure 9

a-d, x-rays case 1

Figure 10

a-b, x-rays case 2

Figure 11

a-c, x-rays case 3

Figure 12

a-c, x-rays case 4

Figure 13

a-c, x-rays case 5

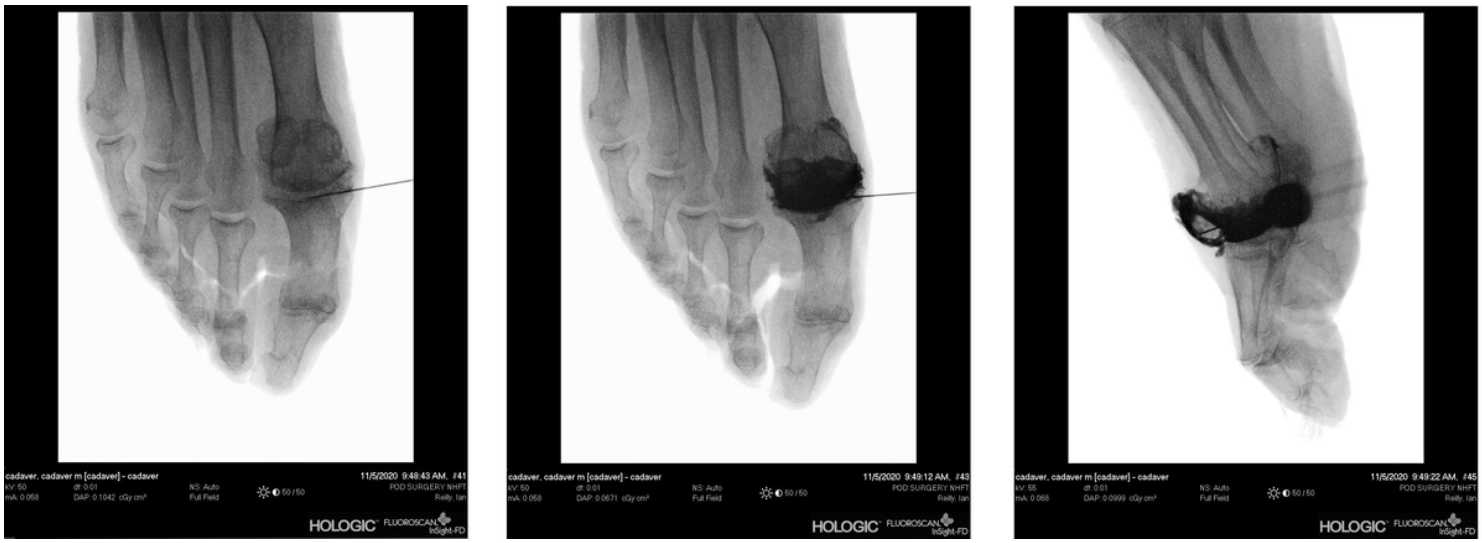

Figure 14

a-c, x-rays case 6

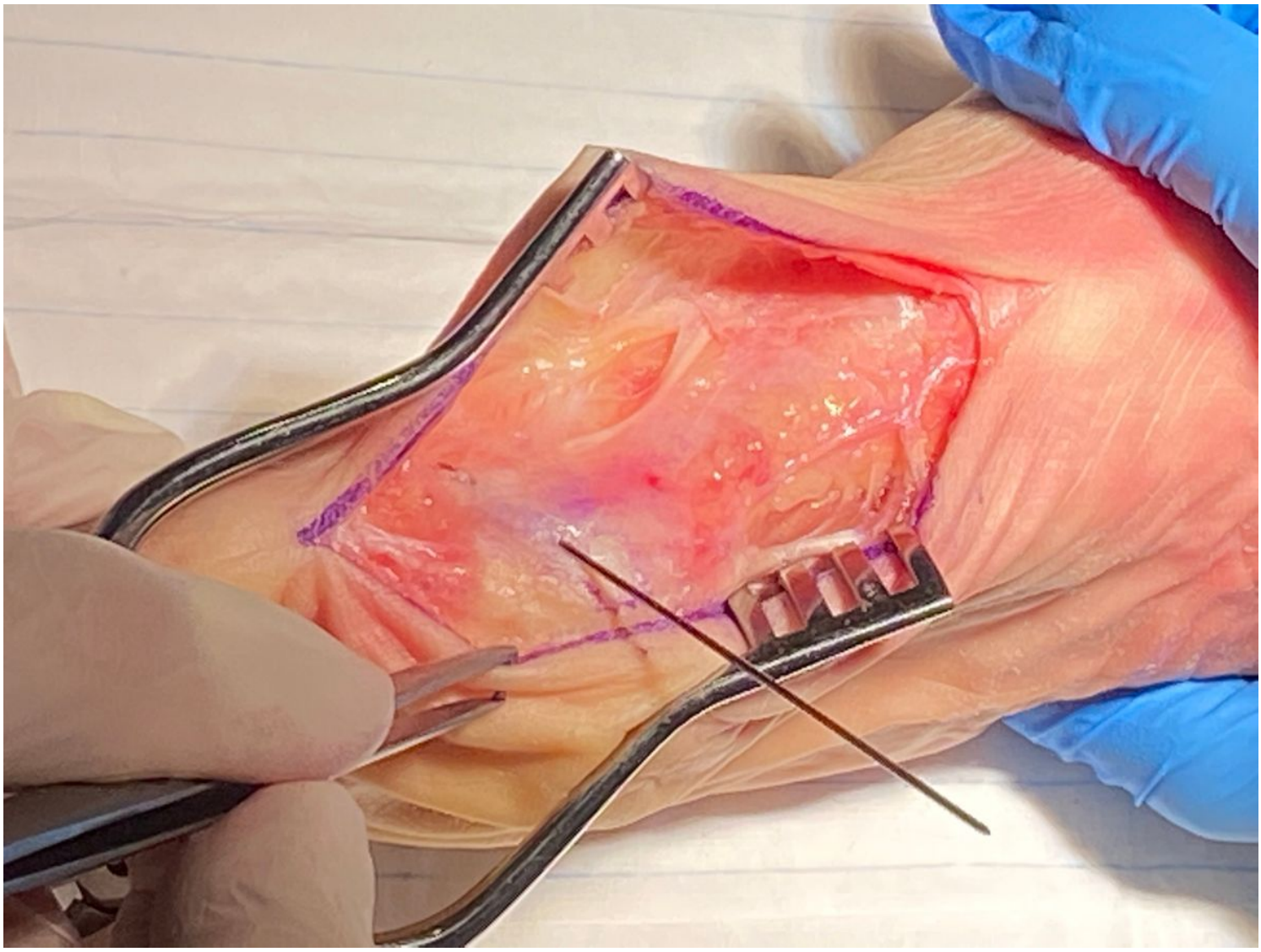

Figure 15

K-wire pass through

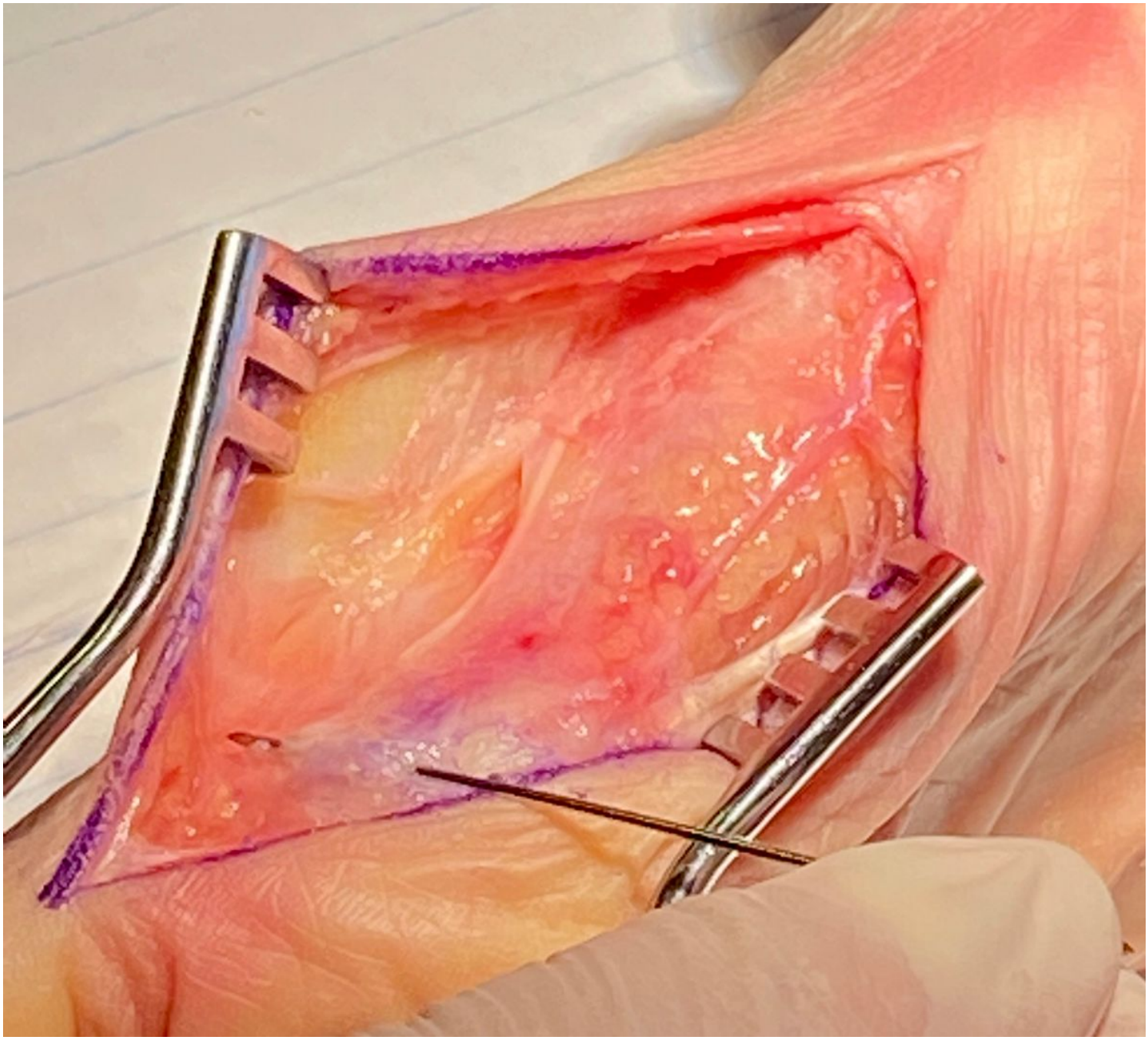

Figure 16

close-up view

Supplementary Files

This is a list of supplementary files associated with this preprint. Click to download.

- suppinfocase1cine.mp4
- suppinfocase2cine.mp4
- suppinfocase3cine.mp4

- suppinfocase4cine.mp4
- suppinfocase5cine.mp4
- suppinfocase6cine.mp4