Size of contralateral aneurysm: an indicator of Posterior Communicating artery mirror aneurysm management

Jiayao Li
Qingdao University
Chao Wang
Qingdao University
Jia-Yi Chang
Qingdao University
Dong-Mei Xu
Qingdao University
Han Zhou
Qingdao University
Huanting Li
The Affiliated Hospital of Qingdao University
Shifang Li
The Affiliated Hospital of Qingdao University
Yugong Feng (fengyugongqdu@163.com)
The Affiliated Hospital of Qingdao University

Research Article

Keywords: Aneurysm size, Clipping, Mirror aneurysms, Radiological characteristics, Unilateral craniotomy

Posted Date: April 19th, 2022

DOI: https://doi.org/10.21203/rs.3.rs-1520164/v1

Abstract

Introduction: Intracranial mirror aneurysm is one of the subspecies of multiple intracranial aneurysms. The clear consensus on the treatment of mirror aneurysms has not come into existence. We investigated the preoperative value for radiographic data of Posterior Communicating artery (PComA) mirror aneurysms in operation choosing.

Materials and Methods: We retrospectively reviewed patients with PComA mirror aneurysms treated with clipping from December 1997 to April 2019. The PComA mirror aneurysms were confirmed by computed tomographic angiography or digital substraction angiography and PComA mirror aneurysms patients with other aneurysms complicated were excluded. Patients' radiographic data, general clinical data and Modified Rankin Score were analysed by R 4.1.2.

Results: 33 PComA mirror aneurysm patients were analysed. Mirror aneurysms were clipped by one-stage unilateral craniotomy approach in 10 of 33. There was one factor that was statistically significant. In patients accepted unilateral approach, the size of silence aneurysm tended to be in the range of 5.1mm to 10mm

Discussion: The size of silent aneurysm performs as an indicator for neuro- surgeon in choosing management strategy of mirror aneurysms. Thus it is helpful to measure the size of silence aneurysm before operation.

1 Introduction

Intracranial mirror aneurysm is one of the subspecies of multiple intracranial aneurysms. However, clear consensus on the treatment of mirror aneurysms has not come into existence [5]. Clipping aneurysm enables neurosurgeons to deal with ruptured intracranial aneurysms and intracranial hematoma at one time, and significantly reduce the possibility of poor prognosis [7]. In comparison, interventional treatment of ruptured aneurysms, in order to achieve the same effect, it is necessary to perform bone flap surgery as supplement. Besides professor Sai's work pointed out that microsurgical clipping is a safe and effective treatment for mirror aneurysms [5]. However, neurosurgeons could be entangled with craniotomy strategies. In order to reduce the injury caused by repeated craniotomy and the fatal risk of silent aneurysm rupture, one-stage clipping of bilateral aneurysms, especially with unilateral approach, should be performed as patient's conditions permit. In this study, given the posterior communicative artery (PComA) is a common distribution of mirror aneurysms [6], we chose mirror aneurysms located on PComA as research subjects and retrospectively analyzed the relationship among preoperative radiologic features and surgical methods of aneurysms.

2 Materials And Methods

All the patients in this study came from our medical center from December 1997 to April 2019, and all received surgical treatment under the principle of one- stage clipping first. All the data obtained were

recorded in the Excel table after being digitized, and the statistical calculation was carried out by using R 4.1.2. In the statistical calculation, multivariate analysis was carried out to avoid the use of logistic regression. $P \leqslant 0.05$ is considered to be statistically significant. The mirror aneurysms in this study are defined as intracranial aneurysms located in pairs or ”twins” symmetrically located on both sides cerebral arteries. The imaging physicians of our center analyzed the imaging data, extracting location, size and basal pointing characteristics of aneurysms as the factors of this study. The inclusion criteria of patients in this study are as follows: 1. Mirror aneurysms were diagnosed by Computed Tomography Angiography (CTA) or Digital sub- traction angiography (DSA). 2. Imaging data are complete; 3. The clinical data were detailed and complete, and the postoperative complications as well as Glascow prognosis score were recorded. 4. Patients accepted microsurgical clipping. Exclusion criteria include: 1. Mirror aneurysm combined with other aneurysms; 2. Lack of clinical or imaging data; 3. A hybrid operation of microsurgery and interventional treatment was performed. The ethics committee of the affiliated hospital of Qingdao university had approved this study.

3 Results

3.1 Data analysis

Of the 33 patients in the study, 10 patients received unilateral clipping of bilateral aneurysms, (30.3%) was defined as group I, and 23 patients received other treatments including clipping only ruptured aneurysms, or clipping bilateral aneurysms through a coronary incision (69.7%), defined as group II. As for imaging data, the imaging parameters of unruptured aneurysms were classified as follows: size 1 means size of aneurysm varies from 5.1mm to 10mm; size 2 means size of aneurysm $\leqslant$ 5 mm or > 10mm. The unruptured aneurysm originated behind the angle between PComA and ICA were defined as location 1 and originated from proximal segment at the beginning of PComA or originated from lateral wall of PComA segment was defined as location 2. Unruptured aneurysm pointed to superior was defined as direction 1 and direction 2 referred to inferior direction. In group I, the imaging features of unruptured aneurysms were as follows: 3 cases were located on the left side (30%), 7 cases on the right side (70%). 2 of patients belonged to size 2 and the rest belonged to size 1. 3 cases were classified as location 2 (30%), and 7 cases were located behind the angle between PComA and ICA (70%). 2 cases pointed to superior (20%) and 8 cases pointed to inferior. There were no postoperative complications including cerebral infarction, hydrocephalus, brain edema and oculomotor nerve paralysis. According to the Glascow prognosis score, 9 patients had a score of 5 (90%) and 1 patient had a score of 4 (10%). In group II, the imaging features of unruptured aneurysms were as follows: 6 cases were located in the range of 5.1-10mm (26.1%), the rest were ascribed size 2(73.9%). 19 cases were located behind the angle between PComA and ICA (82.6%), and the rest were located in the lateral wall of PComA segment or proximal to the beginning of PComA(17.4%). As for the direction of aneurysm neck, 4 cases belonged to direction 1(17.4%), 19 belonged to direction 2(82.6%).

3.2 Statistical calculation results

Statistical calculation results: Patients who received unilateral clipping of bi- lateral aneurysms were defined as group I (n = 10) and the rest were defined as group II (n = 23). The results of logistic regression model showed that there was statistical significance between factor ”size 2” and unilateral craniotomy(P = 0.00887). The OR was 0.08212 and 95% CI varied were (0.00925, 0.45403). There were not other factors showing statistic significance as shown in Table 1.

Table 1
Statistic analysis showed the P value of size2 = 0.00887, the OR value = 0.08212 and 95%CI was 0.00925 to 0.45403, other P values did not show statistic significance

	B value	OR value	P value	95%CI	
				2.5%	97.5%
Intercept	1.31961	1.31961	0.78797	0.15161	11.16327
Direction2	0.78190	0.78190	0.83230	0.07768	8.78378
Size2	0.08212	0.08212	0.00887	0.00925	0.45403
Location2	2.81024	2.81024	0.35165	0.32019	29.64703

3.3 Illustrative cases

3.3.1 Case 1

A 67-year-old female patient was transferred to our emergency room for 19 hours of sudden severe headache. Computed tomography revealed a subarachnoid hemorrhage (Fig. 1a). DSA was arranged and two internal carotid aneurysms were detected, locating separately on both sides (Fig. 1b & Fig. 1c). Sizes of both aneurysms were in a range from 5.1mm to 10mm. The ruptured aneurysm on the right side was clipped via ipsilateral pterion approach (Fig. 2a & Fig. 2b). Then through the sellar regional surgical spaces, the unruptured aneurysm was clipped (Fig. 2c & Fig. 2d). The postsurgical course was uneventful and patent was discharged without neurological deficits.

3.3.2 Case 2

A 66-year-old female patient who suffered from sudden severe headache for a day was transferred to our emergency room. Computed tomography found the existence of subarachnoid hemorrhage (Fig. 3a), while CTA detecting mirror aneurysms of PComA. Size of the ruptured aneurysm was less than 5mm as size of the unruptured aneurysm was in a range from 5.1mm to 10mm (Fig. 3b & Fig. 3c & Fig. 3d). Via the ipsilateral pterion approach, the ruptured aneurysm was clipped preferentially (Fig. 4a & Fig. 4b). And then with same craniotomy, the unruptured aneurysm was clipped via sellar operation spaces (Fig. 4c & Fig. 4d). The rest of clinical course was uneventful.

4 Discussion

4.1 General clinical characteristics of mirror aneurysms of posterior communicating artery

Intracranial mirror aneurysms, a subgroup of multiple intracranial aneurysms, refer to aneurysms that symmetrically located on bilateral intracranial artery, accounting for 2 to 12% of total intracranial aneurysms [3]. Compared with non-mirror multiple intracranial aneurysms, though female patients and patients with family history of intracranial aneurysm are more likely to develop mirror aneurysms as well, mirror aneurysms can be larger especially MIA on PComA. Data from Canada and China show that MCA, cavernous ICA and PComA are the most common locations of mirror aneurysms [4, 10].

4.2 Rupture and recurrence of mirror aneurysm

In MIA, the risk of bleeding caused by silent aneurysm are reported to be 10–17%, and incidence of fatal bleeding could reach 6.6% [5], the risk could be even higher for mirror aneurysms located on PComA. Follow-up of patients up to 24.8–84.4 months, the recurrence rates of patients accepting endovascular treatment reached 15–33%, and said recurrence rate of patients receiving clipping operations was 2.9%. Thus early clipping of both aneurysms can assure better clinical outcome.

4.3 The clipping of mirror aneurysms

The management of mirror aneurysms with endovascular coiling or microsurgical clipping can be controversial. Yet, considering the complicated vascular anatomy [2], recanalization rate and recovery of ONP, clipping does have its benefits for patients. Despite the difference of recurrence rate, some studies indicated endovascular coiling's efficiency for poor grade aneurysmal SAH (Hunt-Hess grades IV or V or [WFNS grade III or IV]) remains uncertainty [7, 9], and for aneurysmal SAH patient, microsurgery clipping of aneurysm is associated with favorable outcome [7]; this view is supported by Sai.Kiran [5] that draw the conclusion carrying out aggressive strategy of early clipping of both aneurysm can bring good outcome. In developing countries, device cost of coiling making it quite an expensive treatment, clipping however is more cost effective consequently become the primary treatment modality for patients with strict economical limit [11]. Professor Khan also points that surgical clipping is more commonly linked with complete recovery of oculomotor nerve palsy(ONP) [1]. In this study, 2 patients suffered from ONP, and after Unilateral craniotomy clipping, both of them got fully recovery of ONP. Our result shows that when size of contralateral aneurysm ranges from 5.1 to 10mm, unilateral craniotomy clipping of both aneurysm can be a suitable modality. Inferred from our clinical experience, clipping a contralateral aneurysm which is bigger than 10mm can be challenging for limited manipulation room causes neurosurgeons unable to clip it after exposure and a big diameter of aneurysm means higher risk of rupture. Once rupture happens, it can be a disaster for neurosurgeons to deal with ruptured aneurysm by contralateral craniotomy because it is inconvenient for neurosurgeons to clip aneurysm or perform occlusion of internal carotid artery. As for aneurysms smaller than 5mm, exposure of contralateral aneurysms can be hard. Though we did not get statistic evidence, we tend to assume direction and shape of mirror aneurysms also play a key role in choosing craniotomy strategies based on our clinical experience. To guarantee patients' safety, when silent aneurysm owns an irregular shape, a one-stage

bilateral craniotomy or a two-stage operation might replace one-stage unilateral craniotomy as an ideal management strategy [8]. In conclusion, unilateral craniotomy clipping has following advantages: 1. Neurosurgeons are able to clip two aneurysms in one-stage operation, reduce the risk of silent aneurysm rupture. 2.Compared with two-stage operation, a proper one-stage unilateral craniotomy clipping assures less hospital stay, lower surgical risk and smaller economic burden. 3.Through sellar operational spaces, it sometimes offers neurosurgeon a better exposure of contralateral aneurysm whose size varies from 5.1mm to 10mm.

Yet, the basic principle in admission is securing patient's life, making management of ruptured aneurysm the priority and the choice of modality should be based on the patient situation [8]. Neurosurgeons could choose management based on CT characteristics of aneurysms. However, if neurosurgeons are not good at clipping contralateral aneurysm, one-stage-operation with unilateral craniotomy is not necessary. Cause the limited number of patients enrolled in this study, though location and direction of aneurysm did not show statistical significance, we do not tend to deny their effects in clinical decisions.

4.4 Limit of our study

Limitation of our study mainly comes from the small group of patients. In the logistic regression calculation, we could only calculate three parameters at a time and we failed to subdivide aneurysms' size, location and direction. This might explain why we were unable to get statistical evidence to proof direction and shape of mirror aneurysms affect operation strategy, which contradicted main- stream opinion that management of mirror aneurysm should be tailored to individual patients [3, 5, 7, 8]. The further study should contain medical centers from more regions collecting adequate clinical data of patients. After ISUIA integrated data from medical centers in America, Canada and Europe [4], similar research should be carried out in Asia.

5 Conclusion

Mirror aneurysm is a subtype of multiple intracranial aneurysm. The basic principle in admission is securing patient's life, making management of ruptured aneurysm the priority and the choice of modality should be based on the patient situation. Neurosurgeons could choose management based on CT characteristics of aneurysms. However, if neurosurgeons are not good at clipping contralateral aneurysm, one-stage-operation with unilateral craniotomy is not necessary. Cause the limited number of patients enrolled in this study, though location and direction of aneurysm did not show statistical significance, we do not tend to deny their effects in clinical decisions and further study is needed.

Declarations

6.1 Ethical Approval and Consent to participate

Though, this is a retrospective study, we have received approval from ethics committee of the affiliated hospital of Qingdao university, and the reference number is QYFY WZLL 26908. Informed consent was

obtained from all individual participants included in the study.

6.2 Human and Animal Ethics

Not applicable.

6.3 Consent for publication

Not applicable. There are no images or data about identifying information, making it not necessary to obtain consent.

6.4 Availability of supporting data

The datasets used and analysed during the current study are available from the corresponding author on reasonable request.

6.5 Competing interests

All authors have no relevant financial or non-financial interests to disclose.

6.6 Funding

The authors declare that no funds, grants, or other support were received during the preparation of this manuscript.

6.7 Authors' contributions

All named authors meet the International Committee of Medical Journal Editors (ICMJE) criteria for authorship for this article, take responsibility for the integrity of the work as a whole, and have given their approval for this version to be published. And all authors contributed to the study conception and design. Material preparation, data collection and analysis were performed by Yugong Feng, Jiayao Li, Chao Wang, Jiayi Chang and Dongmei Xu. The first draft of the manuscript was written by Jiayao Li and all authors commented on previous versions of the manuscript. All authors read and approved the final manuscript.

6.8 Acknowledgements

Professor Feng performed all surgeries and completed detailed case data. Huanchen Shi and Junjie Ji gave great help to statistic analysis in this study.

6.9 Authors' information

Jia-Yao Li, Qingdao University, Qingdao City 266000, China. sdssljy@163.com

Chao Wang, Qingdao University, Qingdao City 266000, China. wangchao987@163.com

Jia-Yi Chang, Qingdao University, Qingdao City 266000, China. changrabbit@2008.sina.com

Dong-Mei Xu, Qingdao University, Qingdao City 266000, China. 15947994162@163.com

Han Zhou, Qingdao University, Qingdao City 266000, China. zh29471@163.com

Huanting Li, Department of Neurosurgery , affiliated hospital of Qingdao University, lihuantingqdu@163.com

Shifang Li, Department of Neurosurgery , affiliated hospital of Qingdao University, lishifangqdu@163.com

Yu-Gong Feng, Department of Neurosurgery , affiliated hospital of Qingdao University, fengyugongqdu@163.com.

References

1. S A Khan, A Agrawal, C E Hailey, T P Smith, S Gokhale, M J Alexander, G W Britz, A R Zomorodi, D L McDonagh, and M L James. Effect of surgical clipping versus endovascular coiling on recovery from oculomotor nerve palsy in patients with posterior communicating artery aneurysms: A retrospective comparative study and meta-analysis. Asian journal of neurosurgery, 8(3), Jul 2013. http://dx.doi.org/10.4103/1793-5482.121671
2. Min Jeoung Kim, Joonho Chung, Keun Young Park, Dong Joon Kim, Byung Moon Kim, Sang Hyun Suh, Jae Whan Lee, Seung Kon Huh, Yong Bae Kim, Jin Yang Joo, Nak Hoon Son, and Chang Ki Jang. Recurrence and risk factors of posterior communicating artery aneurysms after endovascular treatment. *Acta neurochirurgica*, 163(8), Aug 2021. http://dx.doi.org/10.1007/s00701-021-04881-5
3. Young-Jun Lee, Tiago Parreira, Charles C. Matouk, Ravi Menezes, Daniel M. Mandell, Karel G. ter Brugge, Robert A. Willinsky, and Timo Krings. Clinical characteristics and preferential location of intracranial mirror aneurysms: a comparison with non-mirror multiple and single aneurysms. 57(1):35–40. http://dx.doi.org/10.1007/s00234-014-1437-9
4. Irene Meissner, James Torner, John Huston, Michele L. Rajput, David O. Wiebers, Lyell K. Jones, Robert D. Brown, and International Study of Unruptured Intracranial Aneurysms Investigators. Mirror aneurysms: a reflection on natural history. 116(6):1238–1241. http://dx.doi.org/10.3171/2012.1.JNS11779

5. Narayanam Anantha Sai Kiran, Vivek Raj, Laxminadh Sivaraju, Kanneganti Vidyasagar, Dilip Mohan, and Alangar S. Hegde. Outcome of microsurgical clipping for multiple versus single intracranial aneurysms: A single-institution retrospective comparative cohort study. 143:e590–e603. http://dx.doi.org/10.1016/j.wneu.2020.08.019
6. Ankush Sharma, Nitin Gupta, Munish Gupta, and Shivam Sharma. Dreadful twins: Twin unruptured aneurysms of bilateral intracranial arteries. 4(3):215–217. http://dx.doi.org/10.4103/1658-631X.188253
7. Hong-Yu Wang, Jian Song, Fei Gao, Xu-Dong Duan, Xuan Gao, Yuan Wang, Hong-Bo Cheng, Cheng-Rui Nan, and Di Zhao. Outcomes of microsurgical clipping vs coil embolization for ruptured aneurysmal subarachnoid hemorrhage: A multicenter real-world analysis of 583 patients in China. 98(33):e16821. http://dx.doi.org/10.1097/MD.0000000000016821
8. Wen-Xin Wang, Zhe Xue, Lin Li, Chen Wu, Yan-Yang Zhang, Xin Lou, Lin Ma, and Zheng-Hui Sun. Treatment strategies for intracranial mirror aneurysms. 100:450–458. http://dx.doi.org/10.1016/j.wneu.2017.01.049
9. Zhi-Wei Xia, Xiao-Ming Liu, Jun-Yu Wang, Hui Cao, Feng-Hua Chen, Jun Huang, Qi-Zhuang Li, Shuang-Shi Fan, Bing Jiang, Zi-Gui Chen, and Quan Cheng. Coiling is not superior to clipping in patients with high-grade aneurysmal subarachnoid hemorrhage: Systematic review and meta-analysis. World neurosurgery, 98, Feb 2017. http://dx.doi.org/10.1016/j.wneu.2016.11.032
10. Han Zhou, Jing Cheng, Hengjian Liu, Donglin Lu, and Yugong Feng. Surgical treatment strategy and perioperative analysis of patients with intracranial mirror aneurysms. 30(6):e518–e521. http://dx.doi.org/10.1097/SCS.0000000000005420
11. Muhammad Zubair Tahir, S. Ather Enam, Rushna Pervez Ali, Atta Bhatti, and Tanveer ul Haq. Cost-effectiveness of clipping vs coiling of intracranial aneurysms after subarachnoid hemorrhage in a developing country—a prospective study. 72(4):355–360. http://dx.doi.org/10.1016/j.surneu.2008.11.003

Figures

a CT scan showed bilateral SAH in lateral fissure cistern \& suprasellar cistern in case 1

b CTA showed PComA aneurysm on the left side in case 1

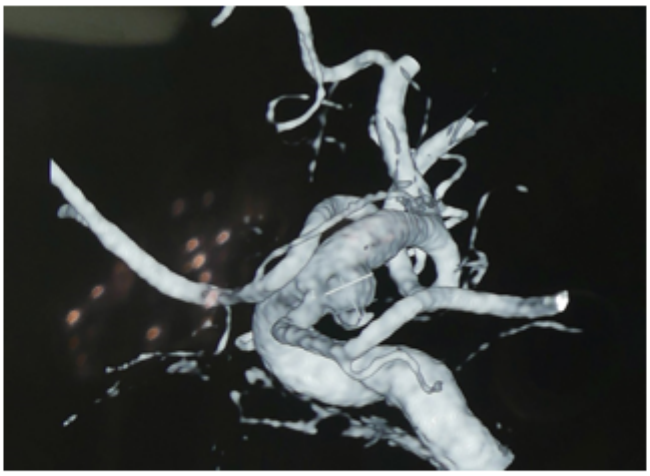

c CTA showed PComA aneurysm on the right side in case 1

Figure 1

CT & CTA before surgery in case 1

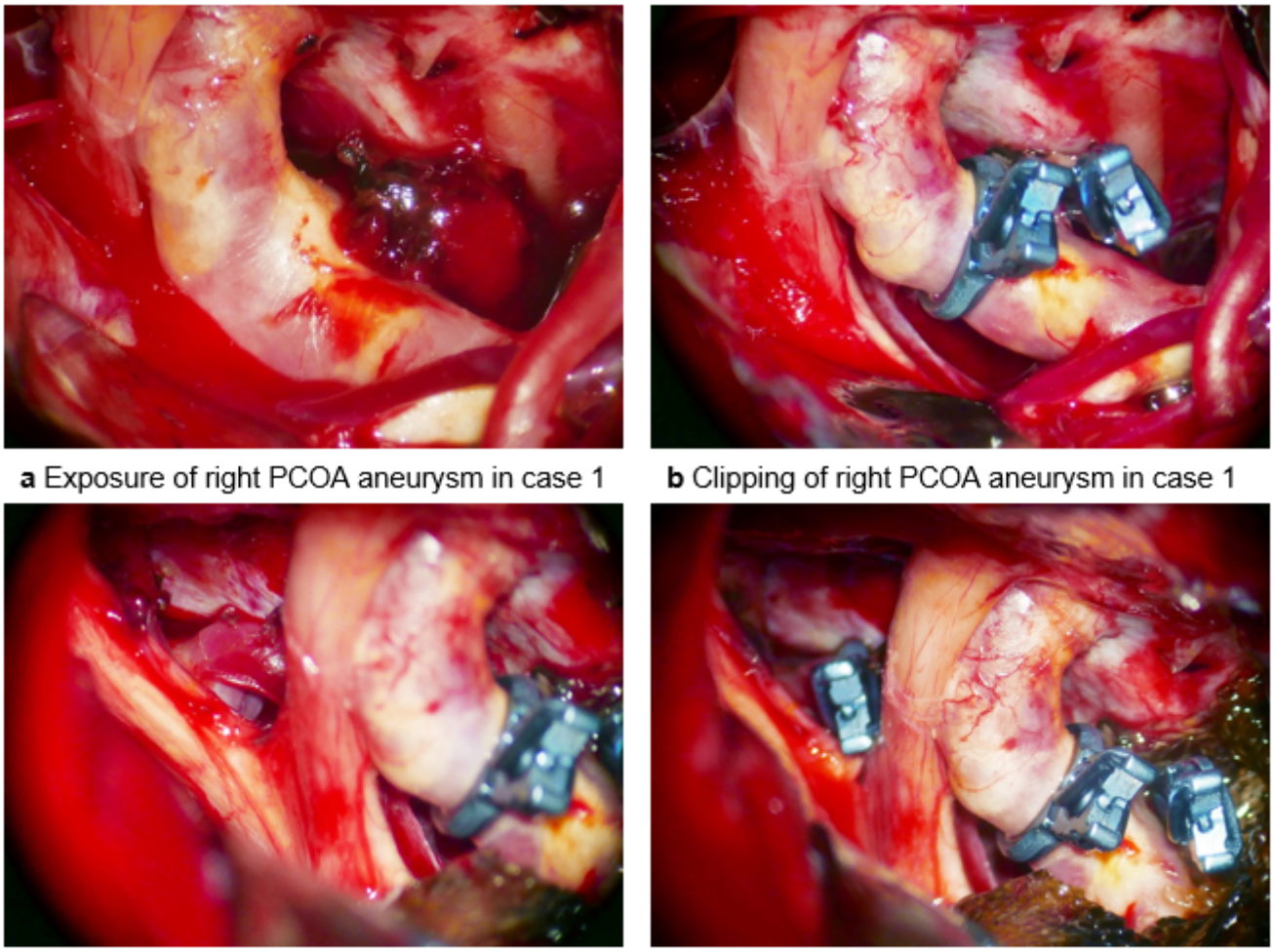

a Exposure of right PCOA aneurysm in case 1

b Clipping of right PCOA aneurysm in case 1

c Exposure of left PCOA aneurysm in case 1

d Clipping of left PCOA aneurysm in case 1

Figure 2

Exposure and Clipping of aneurysms in case

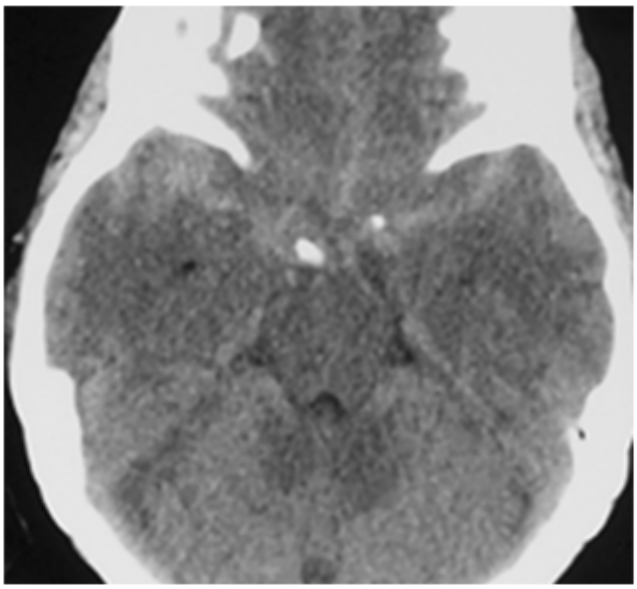

a CT scan showed bilateral SAH in lateral fissure cistern & suprasellar cistern in case 2

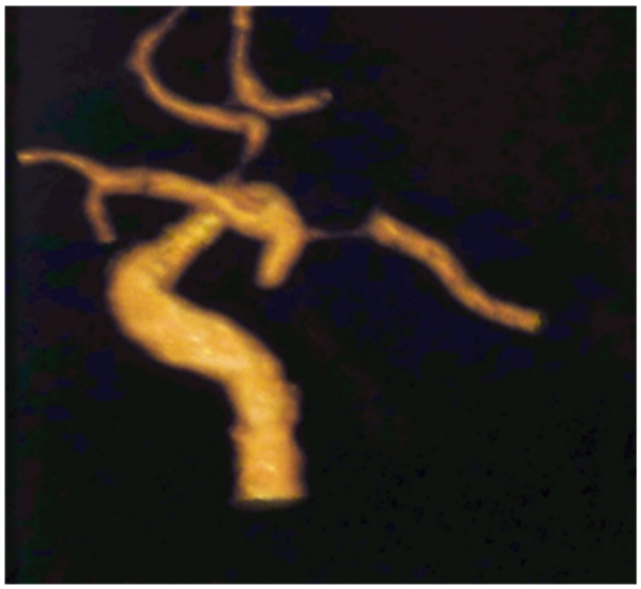

b CTA showed PComA aneurysm on the left side in case 2

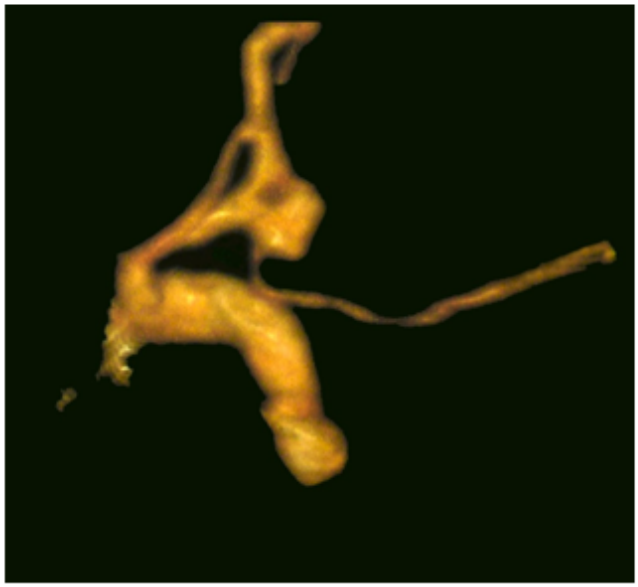

c CTA showed PComA aneurysm on the right side in case 2

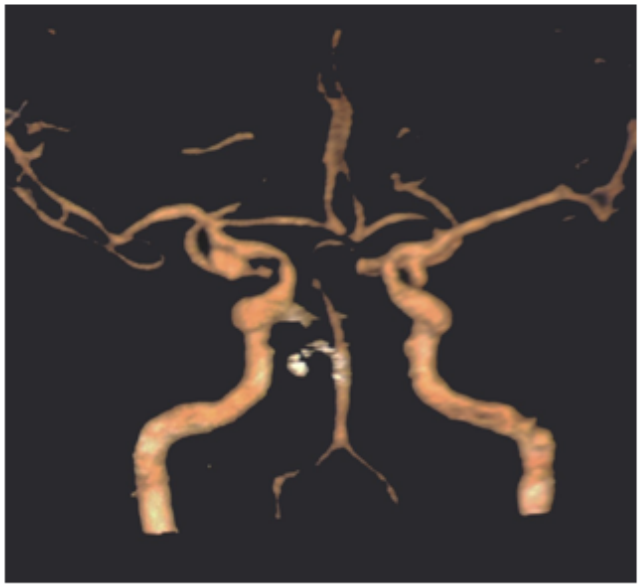

d CTA showed PCOA aneurysms of both sides in case 2

Figure 3

CT & CTA before surgery in case 2

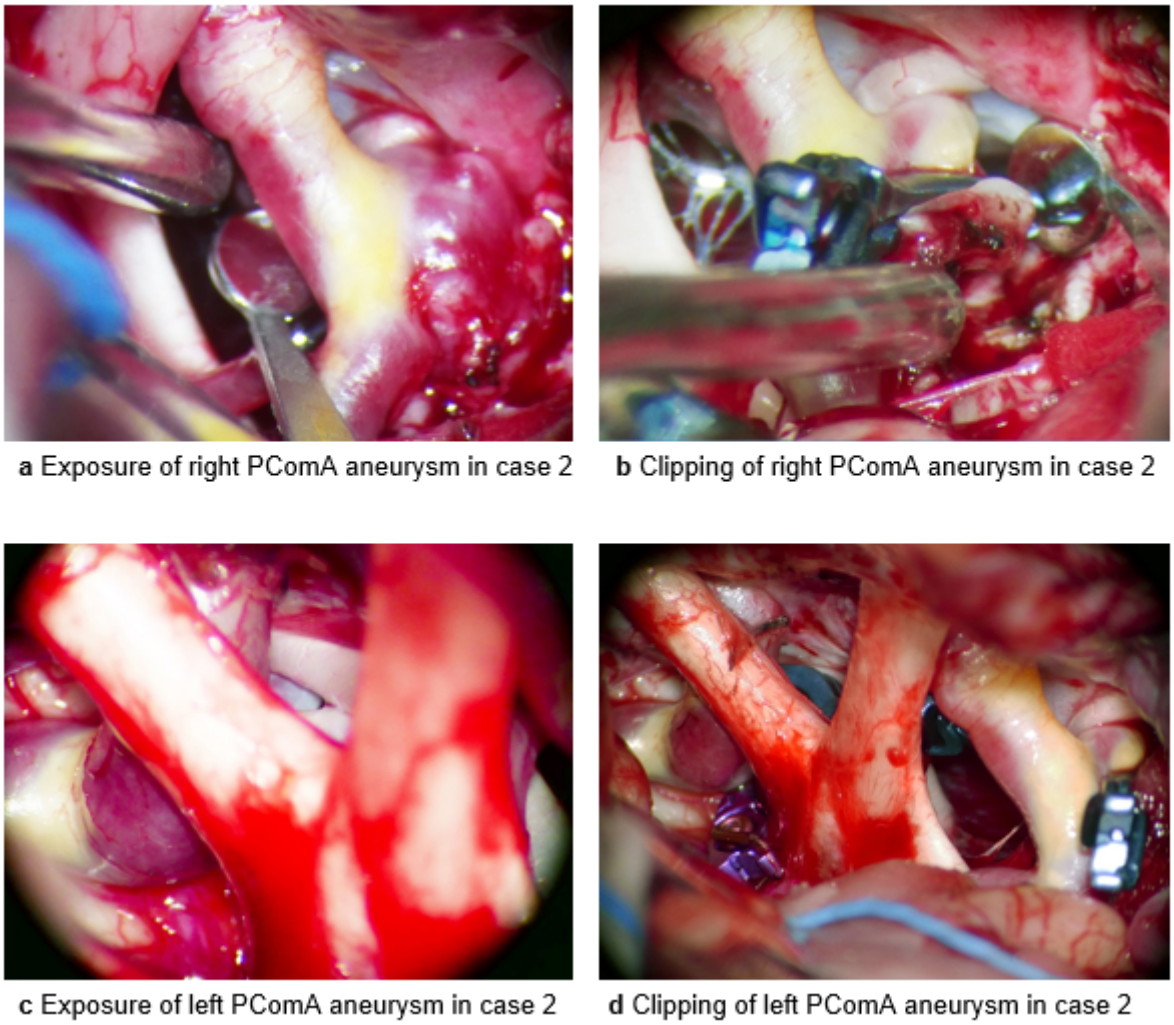

a Exposure of right PComA aneurysm in case 2 **b** Clipping of right PComA aneurysm in case 2

c Exposure of left PComA aneurysm in case 2 **d** Clipping of left PComA aneurysm in case 2

Figure 4

Exposure and Clipping of PComA aneurysms in case 2