Characteristic MRI findings of the shoulder, elbow, and wrist joints in elite wheelchair basketball players

Masafumi Sakai
Tsukuba Daigaku Igaku Iryokei
Hirotaka Mutsuzaki
Ibaraki Kenritsu Iryo Daigaku
Yukiyo Shimizu
Tsukuba Daigaku Igaku Iryokei
Yoshikazu Okamoto (yokamoto@md.tsukuba.ac.jp)
University of Tsukuba
Takahito Nakajima
Tsukuba Daigaku Igaku Iryokei

Research article

Keywords: MRI, wheelchair basketball player, joint of upper extremity, TFCC injury

Posted Date: April 20th, 2022

DOI: https://doi.org/10.21203/rs.3.rs-1521186/v1

Abstract

Background

The health of wheelchair users' upper limbs is directly related to their quality of life. In addition, para-sport athletes are subjected to a dual load on their upper extremities from competition and daily life, making it even more critical to maintain upper extremity health. This study aimed to investigate the characteristics of joint disorders in elite wheelchair basketball players using magnetic resonance imaging (MRI).

Methods

We scanned MRI images of the bilateral shoulders, elbows, and wrist joints of ten elite wheelchair basketball players and ten general wheelchair users. Two radiologists interpreted the MRI images and diagnosed the diseases of each joint. We compared the number of lesions between the two groups. We used Fisher's exact test to determine whether the lesions diagnosed by MRI were specific to wheelchair basketball players. The significance threshold was set at $P < 0.05$.

Results

Elite wheelchair basketball players had significantly more left-sided and bilateral latero-posterior lesions, which are cysts found on the lateral-posterior corner of the capitulum of the humerus than general wheelchair users ($P < 0.05$). Severe damage to the right triangular fibrocartilage complex was also observed more frequently ($P < 0.05$) in wheelchair basketball players.

Conclusions

We believe that the patient's tendency to fall forward in the wheelchair hitting both hands on the ground, thereby injuring the triangular fibrocartilage complex and locking the lateral elbow, may be the cause of the characteristic findings on MRI. High-speed wheelchair operation was also thought to be a cause of severe triangular fibrocartilage complex injuries. Therefore, more attention should be paid to hand placement and wrist protection during falls. This study's insights can be useful for future solutions to extend players' careers.

Trial registration:

This paper is not a paper reporting the results of a medical intervention on human participants. That is, it is not a report of a clinical trial.

Background

Wheelchair basketball is considered the most popular para-sport in the world. However, players perform complex wheelchair maneuvers quickly and repeatedly, as well as playing with the ball using their upper limbs (1, 2). In addition, they use a wheelchair in their daily lives (3, 4), so their upper limbs are likely to be doubly stressed.

For wheelchair users, it is no exaggeration to say that the condition of their upper limbs is directly related to their quality of life (QOL) (5, 6). Therefore, top wheelchair basketball players need to take care of their upper extremity health, especially to maintain their performance and QOL.

Recent studies have shown that wheelchair users have unique abnormal findings in the shoulder, elbow, and wrist joints on MRI (7–9). Therefore, it is highly likely that an MRI of the upper extremity joints of wheelchair basketball players will show more complex abnormal findings. However, if the characteristics of the injury can be determined, it will be possible to identify actions to avoid damage. This information will be beneficial for elite wheelchair basketball players in extending their lifespan.

The purpose of this study was to perform bilateral MRI examinations of the shoulder, elbow, and wrist joints of elite-level wheelchair basketball players to investigate the characteristics of MRI images of the upper extremity joints of wheelchair basketball players, and to examine whether there are any differences between the findings of wheelchair basketball players and those of normal wheelchair users based on the previous literature (7–9). The results of this study can be applied to the prevention of disabilities in other wheelchair sports and the maintenance and improvement of the QOL of people in wheelchairs. In this case, we believe that para-sports will become even more popular.

Methods

Subjects

Ten elite wheelchair basketball players and ten general wheelchair users participated in this study. The medical checkup of the candidates for the national team for the international women's tournament was conducted at our institution, and 10 female elite players who agreed to this research purpose were included in the study.

Ten control subjects were recruited from wheelchair users in their 20s and 30s who had no daily exercise habits and who agreed to the study objectives.

In both groups, the exclusion criteria were using a power wheelchair and having used a wheelchair for less than 6 months. All participants were scanned from November 2018 to November 2021. The study was approved by the ethics committee of our institution on August 13, 2018. Written informed consent was obtained from study participants prior to the study. If written informed consent was not obtained, it was obtained in the form of opt-out on the website.

MRI scan

All participants were scanned in the order of right shoulder, right elbow, right wrist, left shoulder, left elbow, and left wrist by 1.5 T MRI (Vantage XG 1.5T, Cannon, Japan). For details of the imaging parameters, a previous paper is referred to (7).

Imaging interpretation

Imaging interpretation was performed by two blinded radiologists independently in both groups. One was a musculoskeletal radiologist with 18 years of experience, and the other was a general radiologist with 8 years of experience. A reproducibility test for the two radiologists was performed with an agreement rate and kappa value for the bilateral shoulder, elbow, and wrist (Table 13).

Table 1
MRI diagnoses in the shoulder and frequency of occurrence in the right, left, and bilateral joints

	Wheelchair basketball players				**Normal wheelchair users**				**Inter-observer agreement rate (%)**	**Kappa coefficient**
Shoulder injury	R	L	Bi	With symptom (R/L)	R	L	Bi	With symptom (R/L)		
Partial tear of supraspinatus tendon	4	3	2	2/1	1	0	0	0/0	81	0.63
OA of gleno-humeral joint	1	0	0	0/0	0	0	0	0/0	82	0.88
Superior labral tear	0	1	0	0/0	0	0	0	0/0	91	0.91

* indicates $P < 0.05$
Abbreviations: MRI, magnetic resonance imaging; OA, osteoarthritis; R, right; L, left; Bi, bilateral.

Table 2
MRI diagnoses in the elbow and frequency of occurrence in the right, left, and bilateral joints

	Wheelchair basketball players				Normal wheelchair users				Inter-observer agreement rate (%)	Kappa coefficient
Elbow injury	**R**	**L**	**Bi**	**With symptom (R/L)**	**R**	**L**	**Bi**	**With symptom (R/L)**		
LP lesion	7*	6*	5*	1/2	2	1	0	0/0	93	0.72
OA	0	0	0	0/0	2	0	0	0/0	83	0.66
MCL injury	0	0	0	0/0	0	1	0	0/0	93	0.86

* indicates P < 0.05
Abbreviations: MRI, magnetic resonance imaging; LP, latero-posterior; OA, osteoarthritis; MCL, medial collateral ligament; R, right; L, left; Bi, bilateral.

Table 3
MRI diagnoses in the wrist and frequency of occurrence in the right, left, and bilateral joints

	Wheelchair basketball players				Normal wheelchair users				Inter-observer agreement rate (%)	Kappa coefficient
Wrist injury	**R**	**L**	**Bi**	**With symptom (R/L)**	**R**	**L**	**Bi**	**With symptom (R/L)**		
Severe TFCC injury	5*	2	2	2/1	0	0	0	0/0	92	0.81
Minor TFCC injury	2	0	0	0/0	3	2	2	0/0	77	0.55
Extensor carpi ulnaris tendon tear	0	0	0	0/0	0	1	0	0/0	95	0.66

*indicates P < 0.05
Abbreviations: MRI, magnetic resonance imaging; TFCC, triangular fibrocartilage complex; R, right; L, left; Bi, bilateral

Neuropathy-related diseases, such as carpal tunnel syndrome, were not discussed in this study because patients with these findings on MRI often did not present with symptoms.

Definition of abnormal findings

We defined abnormal findings on MRI as shown in Table 4.

Table 4
Definition of abnormal findings on MRI

Disease	Definition of abnormal findings on MRI
Tear of tendon	High signal intensity in the tendon on T2-weighted image or proton density weighted image
Osteophytes	Bony humps around joints
Subchondral cyst	Cyst formation just below the articular cartilage
Injury of fibrocartilage (e.g., triangular fibrocartilage complex injury)	High signal area in fibrocartilage on some sequences with or without swelling
Injury of ligament	High signal area in a ligament on some sequences with or without swelling
Abbreviations: MRI: magnetic resonance imaging	

Grading of diseases

We graded the rotator cuff tears into two groups. A partial tear was defined as an abnormal signal intensity within the rotator cuff, while a full-thickness tear was defined as an abnormal signal intensity extending from one end of the rotator cuff to the other.

We graded the injury of the triangular fibrocartilage complex (TFCC) into two groups. Minor injury was defined as damage to one or two components of the TFCC, and severe injury was defined as damage to the entire TFCC.

Definition of the latero-posterior lesion

We defined the latero-posterior (LP) lesion as cysts of various sizes found on the lateral posterior corner of the capitulum of the humerus. The differentiating features from the subchondral cysts were the site of predilection and the presence of subchondral bone between the cartilage and the cyst.

Analysis

We compared the number of lesions between the two groups. We used Fisher's exact test to determine whether the lesions diagnosed by MRI were specific to wheelchair basketball players. The significance threshold was set at $P < 0.05$.

Results

This study included ten elite wheelchair basketball players, all of whom were women with a mean age was 29.6 years (SD: 6.9). There were also ten general wheelchair users in the control group: nine males and one female; the mean age was 30.1 years (SD = 7.8).

The underlying diseases of the elite para-athletes were skeletal diseases and neurological diseases, such as spinal cord injuries, in seven and three patients, respectively, whereas in general wheelchair users, there were five and five users, respectively.

The scanning time was 2 h 25 min for elite wheelchair basketball players and 2 h and 22 min for general wheelchair users. The top three disease names and the number of patients with findings in the shoulder, elbow, and wrist joints on MRI images of elite wheelchair basketball players and general wheelchair users are summarized in Tables 1–3. The patients in whom the abnormal findings on the MRI images matched the patient's chief complaint are also listed in Tables 1–3.

In the case of the shoulder joint, the most frequent trauma disease was supraspinatus tendon injury. Superior labral injury and osteoarthritis of the glenohumeral joint were also observed in one patient each. There was no significant difference in the number of these findings between elite wheelchair basketball players and general wheelchair users.

In the case of the elbow joint, the top three most frequent trauma diseases were LP lesions, osteoarthritis, and medial collateral ligament injury. Of these, right LP lesions were found in seven, left LP lesions in six, and bilateral LP lesions in five elite wheelchair basketball players, with a statistically significant difference compared to general wheelchair users ($P < 0.05$).

In the case of the wrist joint, the top three most frequent trauma diseases were severe TFCC injury, minor TFCC injury, and ulnar extensor carpal tendon injury. Of these, right severe TFCC injuries were more common in elite wheelchair basketball players, with a statistically significant difference of five in elite wheelchair basketball players and zero in general wheelchair users ($P < 0.05$). Interestingly, the number of patients with abnormal MRI findings that matched the chief complaint was not very large.

Discussion

This study revealed a tendency for elite wheelchair basketball players to have multiple characteristically abnormal findings in their bilateral upper extremity joints. First, it was found that bone cysts of various sizes were more likely to occur in the lateral posterior region of the elbow joint. This is consistent with what was reported as an LP lesion in a previous study (7, 10), and is therefore included in the results as LP lesions in the text (Fig. 1). In addition, the TFCC was easily injured. No significant findings were observed in the shoulder joints.

Previous reports have already shown that the frequency of LP lesions and TFCC injuries is high in general wheelchair users, consistent with the results reported here (7). The average age of the subjects in the study was approximately 50 years (7). The mean age of the subject group of general wheelchair users in this study was 30.1 years, and there were no significant abnormal findings. Therefore, it is suggested that the frequency of abnormal findings in the upper extremities of general wheelchair users increases with age.

On the other hand, the elite wheelchair basketball players, as young as 29.6 years old, showed remarkable abnormal findings. These findings suggest that LP lesions and severe TFCC injuries are characteristic upper limb joint findings in elite wheelchair basketball players.

Although these LP lesions and severe TFCC injuries have been observed in normal wheelchair users, previous literature suggests that the cause is not excessive wheelchair operation, but frequent push-up movements performed over several years to prevent pressure ulcers (7, 11, 12). The push-up motion must be performed many times a day by wheelchair users, and it is assumed that this causes TFCC injuries and LP lesions because the load is applied to the wrist joint by the forearm axis with locking of the elbow joint (7, 13, 14).

On the other hand, because elite wheelchair basketball players are still young, severe TFCC injuries and LP lesions are likely not only caused by push-ups but are also caused by the competitive characteristics of wheelchair basketball.

Although they handle the ball all the time, passing, shooting, and dribbling are not unnatural and overloaded movements for wheelchair basketball players in this study. Therefore, it is unlikely that basketball play itself produces characteristic findings for elite wheelchair basketball players.

On the other hand, compared to other wheelchair sports, wheelchair basketball is characterized by a high incidence of “tipping the wheelchair forward” (15). For example, as shown in Fig. 2, when a player makes a layup shot, the upper body is often thrown out of the wheelchair, and the wheelchair tends to fall forward (15). There are also many other cases in which the wheelchair falls forward during the game (15). This is because the player's body is fixed to the wheelchair to some extent. As shown in Fig. 2, when a wheelchair falls forward, it is most common to fall on the hands and elbows to avoid hitting the face or twisting the neck. If a person falls with his or her hands, the TFCC is overloaded (16). If the elbows are locked, the load on the TFCC is even greater (16). In addition, when the elbow is locked, it is hyperextended at the time of the fall, which increases the likelihood of the load being applied to the lateral side of the elbow. Severe TFCC injuries and LP lesions are assumed to occur under these circumstances. In addition, it is thought that keeping hands on the wheelchair from 6 o'clock direction to 9 o'clock direction when driving the wheelchair at full force is also a risk for severe TFCC injury. There is a possibility that motion analysis using motion capture will further clarify the cause of the problem, which will be the subject of future research.

The forward fall of a wheelchair is an attractive element for watching wheelchair basketball games and is difficult to avoid from a competitive standpoint. For this reason, it is essential to try to fall in a way that places as little load on the hand and elbow joints as possible. Specifically, it is desirable to brace the fall from the elbow or forearm, rather than the hand. In addition, protectors with the hand, elbow, or forearm may reduce the incidence of severe TFCC injuries and LP lesions by using a wrist joint supporter to cushion the load from the forearm to the wrist joint.

In summary, the characteristic MRI findings of the upper extremities in elite wheelchair basketball players are severe TFCC injuries and LP lesions. These lesions are observed more frequently in normal wheelchair users as they age and are thought to be caused by longstanding push-up movements. On the other hand, elite wheelchair basketball players may be at risk because they may fall with their hands in front of the wheelchair, lock their elbow joints during the fall, and keep their hands on the wheel from 6 to 9 o'clock while driving the wheelchair at full speed.

An interesting finding of this study is that there was not a large agreement between the abnormal findings on imaging and the chief complaint in both elite wheelchair basketball players and general wheelchair users. The reason for this is not clear, but we speculate that it may be due to the stabilization of joints by stronger muscle strength of the upper body in wheelchair users rather than that in a healthy person. In addition, the adaptation to disability caused by chronic injuries, such as overuse, may also be the reason.

This study had two limitations. First, only ten elite wheelchair basketball players were scanned; however, the number of elite wheelchair basketball players is small, and opportunities to gather as a group outside of training camps are limited. In the future, we will consider the use of a mobile MRI system to clarify this problem (17). In addition, while all elite wheelchair basketball players were female, most of the wheelchair users in the study were male.

The incidence of spinal cord injury has been reported to be higher in males worldwide (18). The latest epidemiology in our country also shows that spinal cord injuries are more common in males (19). In addition, head and neck trauma has been reported to be more common in males at younger ages (20). Since there are more males with spinal cord injuries and head trauma than females, it can be inferred that there are more male wheelchair users than female wheelchair users in the younger age group. This may be the biggest reason why it was difficult to gather female wheelchair users in this study. Furthermore, as already mentioned, MRI of the upper extremity joints of general wheelchair users has the influence of push-up as a basic life factor in the background (7). There is no difference between men and women in this regard (7). Therefore, we assume that the influence of gender differences on the results of this study is small.

Conclusion

In a previous research paper, characteristic MRI findings were observed in the upper limb joints of wheelchair users, and it was speculated that “push up” to prevent pressure ulcers, a movement unique to wheelchair users, may be the cause of these findings (7).

Our study revealed characteristic MRI findings of upper extremity joints in elite wheelchair basketball players, where LP lesions and severe TFCC injuries were observed. These findings were thought to be mainly due to the characteristic movements of wheelchair basketball, such as falling forward with the wheelchair during competition and high-speed wheelchair handling. These injuries can be avoided by using the elbow and forearm instead of the hands when falling forward, and by wearing wrist and elbow protectors.

List Of Abbreviations

QOL
quality of life
MRI
magnetic resonance imaging
TFCC
triangular fibrocartilage complex
LP lesion
latero-posterior lesion
SD
standard deviation
OA
osteoarthritis;
MCL
medial collateral ligament

Declarations

Ethics approval and consent to participate

This study was approved and conducted by the Ethics Committee of Ibaraki Prefectural University of Health Sciences. The approval number is 'e251'.

We explained verbally to all subjects the main purpose of the study and obtained their written informed consent after they agreed that the data obtained would be revealed to them.

Consent for publication

Subjects who participated in the study were verbally informed that their clinical and imaging data would be disclosed anonymously. Written informed consent was then obtained from all participants.

Availability of data and materials

The datasets used and/or analysed during the current study are available from the corresponding author on reasonable request.

Competing interests

The authors declare that they have no competing interests

Funding

No funding was received in the design of the study or in the collection, analysis, or interpretation of the data. English-language support for the writing of the manuscript was paid by the University of Tsukuba Research School Fund. This is a research fund distributed annually by the University of Tsukuba to all university faculty members and has no specific name.

Authors' contributions

MS came up with the structure of this entire paper. He further performed image readings, discussed the results with several people, and described parts of the paper.

HM gathered the subjects and explained the purpose of this study to them. He also discussed the results with the other co-authors.

YS also gathered subjects and explained the purpose of this study to them. She also discussed the results with the other co-authors.

YO made a research plan and assigned it to the co-authors. Furthermore, the images were read together with MS. The results were discussed with the co-authors. The paper was written together with MS.

TN polished the completed paper and advised MS and YO to improve the quality of the paper.

Acknowledgments

In order to carry out this study, it was necessary to perform MRI scans on a large number of subjects who were wheelchair users. In order to conduct this study, we had to perform many MRI scans on a large number of wheelchair users, which takes much longer than a normal MRI exam. We would like to express our sincere gratitude to Katsuhiko Yatabe and Ichio Muraki for their cooperation.

References

1. Nunome H, Doyo W, Sakurai S, Ikegmai Y, Yabe K. A kinematic study of the upper-limb motion of wheelchair basketball shooting in tetraplegic adults. J Rehabil Res Dev. 2002;39(1):63–71.
2. Matthew H, Gretchen O. Muscle Activation Patterns in Wheelchair Basketball Athletes with and without Physical Disability. International Journal of Physiatry. 2018;4(1).
3. van der Woude LH, Veeger HE, Dallmeijer AJ, Janssen TW, Rozendaal LA. Biomechanics and physiology in active manual wheelchair propulsion. Med Eng Phys. 2001;23(10):713–33.
4. Gorce P, Louis N. Wheelchair propulsion kinematics in beginners and expert users: influence of wheelchair settings. Clin Biomech (Bristol Avon). 2012;27(1):7–15.
5. Rice LA, Smith I, Kelleher AR, Greenwald K, Boninger ML. Impact of a wheelchair education protocol based on practice guidelines for preservation of upper-limb function: a randomized trial. Arch Phys Med Rehabil. 2014;95(1):10–9. e1.

6. Ellapen TJ, Hammill HV, Swanepoel M, Strydom GL. The health benefits and constraints of exercise therapy for wheelchair users: A clinical commentary. Afr J Disabil. 2017;6:337.
7. Sakai M, Mutsuzaki T, Shimizu Y, Okamoto Y, Yatabe K, Muraki I, et al. Characteristic MRI findings of shoulder, elbow, and wrist joints in wheelchair user. Skeletal Radiol. 2021;50(1):171–8.
8. Morrow MM, Van Straaten MG, Murthy NS, Braman JP, Zanella E, Zhao KD. Detailed shoulder MRI findings in manual wheelchair users with shoulder pain. Biomed Res Int. 2014;2014:769649.
9. Pepke W, Brunner M, Abel R, Almansour H, Gerner HJ, Hug A, et al. Risk factors for the development of rotator cuff tears in individuals with paraplegia: A cross-sectional study. Orthopade. 2018;47(7):561–6.
10. Ohishi T, Takahashi M, Suzuki D, Matsuyama Y. Giant Intraosseous Cyst in an Osteoarthritic Knee. Orthopedics. 2016;39(6):e1193-e6.
11. Fordyce WE, Simons BC. Automated training system for wheelchair pushups. Public Health Rep. 1968;83(6):527–8.
12. White GW, Mathews RM, Fawcett SB. Reducing risk of pressure sores: effects of watch prompts and alarm avoidance on wheelchair push-ups. J Appl Behav Anal. 1989;22(3):287–95.
13. Reyes ML, Gronley JK, Newsam CJ, Mulroy SJ, Perry J. Electromyographic analysis of shoulder muscles of men with low-level paraplegia during a weight relief raise. Arch Phys Med Rehabil. 1995;76(5):433–9.
14. Nawoczenski DA, Clobes SM, Gore SL, Neu JL, Olsen JE, Borstad JD, et al. Three-dimensional shoulder kinematics during a pressure relief technique and wheelchair transfer11No commercial party having a direct financial interest in the results of the research supporting this article has or will confer a benefit upon the author(s) or upon any organization with which the author(s) is/are associated. Arch Phys Med Rehabil. 2003;84(9):1293–300.
15. Sasadai J, Maeda N, Shimizu R, Kobayashi T, Sakai S, Komiya M, et al. Analysis of team-sport wheelchair falls during the Rio 2016 Summer Paralympic Games: a video-based cross-sectional observational study. BMJ Open. 2020;10(3):e033088.
16. Casadei K, Kiel J. Triangular Fibrocartilage Complex. StatPearls. Treasure Island (FL): StatPearls Publishing. Copyright © 2021, StatPearls Publishing LLC.; 2021.
17. Nakagomi M, Kajiwara M, Matsuzaki J, Tanabe K, Hoshiai S, Okamoto Y, et al. Development of a small car-mounted magnetic resonance imaging system for human elbows using a 0.2 T permanent magnet. J Magn Reson. 2019;304:1–6.
18. Kang Y, Ding H, Zhou H, Wei Z, Liu L, Pan D, et al. Epidemiology of worldwide spinal cord injury: a literature review. J Neurorestoratology. 2017;6:1–9.
19. Miyakoshi N, Suda K, Kudo D, Sakai H, Nakagawa Y, Mikami Y, et al. A nationwide survey on the incidence and characteristics of traumatic spinal cord injury in Japan in 2018. Spinal Cord. 2021;59(6):626–34.
20. James SL, Theadom A, Ellenbogen RG, Bannick MS, Montjoy-Venning W, Lucchesi LR, et al. Global, regional, and national burden of traumatic brain injury and spinal cord injury, 1990–2016: a

systematic analysis for the Global Burden of Disease Study 2016. Lancet Neurol. 2019;18(1):56–87.

Figures

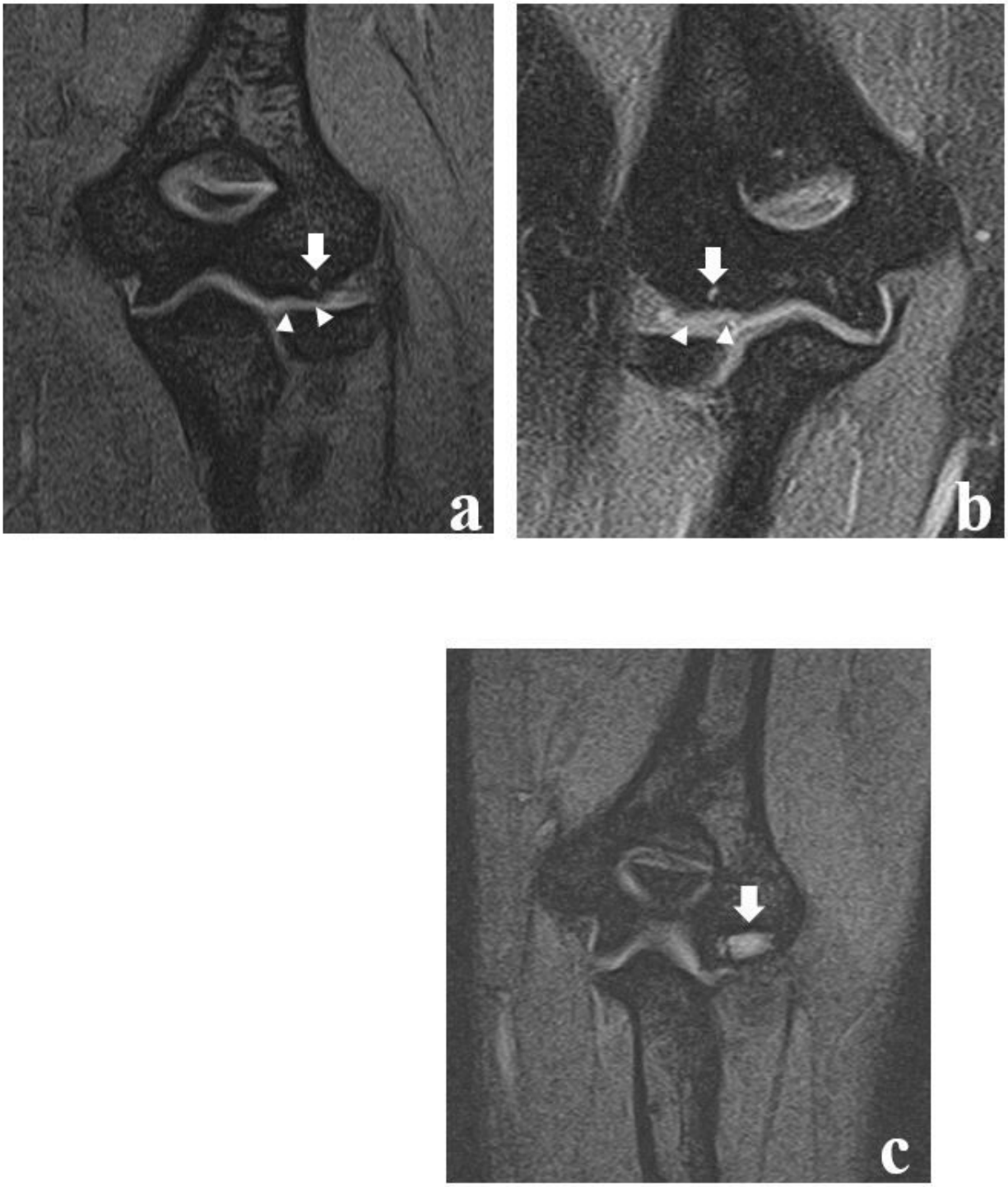

Figure 1

MRI finding of various LP lesions

a, b: A 32-year-old woman with bilateral LP lesions, which appeared as a small cyst at the LP part of the capitulum (arrows) in the left (a) and right (b).

Arrowheads suggest that cartilage is observed, and cysts exist in the subchondral bone. These findings suggest that the entity of this cyst is apparently different from the subchondral cysts observed in osteoarthritis.

c: A 27-year-old woman with a LP lesion, which appears as a large, flat-shaped cyst with a septum (arrow) at the LP part of the capitulum.

Image was acquired by T2* weighted imaging.



Figure 2

Illustration of a wheelchair basketball player falling forward while playing.

The illustration shows a player falling forward with a wheelchair during the game. At the time, players tend to fall on to the hands bilaterally. In this situation, the hands are on the ground with the elbows extended. Therefore, the load is applied to the wrist joint by the forearm axis with locking of the elbow joint, causing triangular fibrocartilage complex injury and locking of the elbow at the lateral side.

This illustration is an original drawing by MS, the co-author, based on a photo of a player falling forward in an actual wheelchair basketball game.