Lobular carcinoma *in situ* within fibroadenoma: a case report and literature review

Bin Zhou
Dean Huaxing Medical Laboratory Co., Ltd
Luoyan Wu
Nanchang First Hospital
Liyuan Liu
Nanchang First Hospital
Zhi Zhang
Nanchang First Hospital
Minshi Ye
Nanchang First Hospital
Ying Yang
Nanchang First Hospital
Fangli Wei
Nanchang First Hospital
Guijie Zhang
Nanchang First Hospital
Dongmei Ye (790111025@qq.com)
Nanchang First Hospital
Li Qingwu
Nanchang First Hospital

Case Report

Keywords: Lobular carcinoma in situ, fibroadenoma, differential diagnosis

Posted Date: April 6th, 2022

DOI: https://doi.org/10.21203/rs.3.rs-1522212/v1

Abstract

Background: Breast fibroadenoma is the most common tumor with benign biological behavior in women. It is rarely malignant. However, the imaging and clinical features of carcinoma in situ within a fibroadenoma are often similar to those of a fibroadenoma.

Case presentation: This study aimed to report the case of a 38-year-old young woman with a regular painless mass in her right breast for 6 years. This tumor had a clear boundary and was composed of epithelial and mesenchymal cells. Most of the area comprised the so-called fibroadenoma structure, besides swelling and proliferation in a small part of the terminal duct and no expression of E-cadherin protein. The histological morphology and immunohistochemistry confirmed the diagnosis of a fibroadenoma with lobular carcinoma in situ.

Conclusions: We need to be careful of malignant transformation within fibroadenomas and improve the understanding of lobular carcinoma in situ within fibroadenoma.

Introduction

Breast fibroadenoma is a benign tumor confined to the terminal ductal lobular unit; it consists of bidirectional hyperplasia of epithelial and mesenchymal components [1,2] .Fibroadenoma is a common tumor in young women, especially women of childbearing age, which is often diagnosed initially by color Doppler ultrasound [3] . Besides, it also occurs in adolescents and older women. Fibroadenoma is usually a painless, well-defined, and solitary solid mass [4].The diagnosis of breast fibroadenoma mainly depends on histopathological characteristics. Different groups of people adopt different methods to manage fibroadenomas, that is, asymptomatic small fibroadenomas can be followed up for observation. The surgical resection of larger ones is the most common treatment for fibroadenomas [5]. Most fibroadenomas after resection have a good prognosis.

However, in a small part of the fibroadenoma in the present case, carcinoma *in situ* coexisted, including lobular carcinoma *in situ*, ductal carcinoma, and mixed carcinoma of the two. Studies have shown that fibroadenoma combined with lobular carcinoma *in situ* is the most common [6]. Compared with fibroadenoma, fibroadenoma with lobular carcinoma *in situ* has no special clinical and imaging features. In addition, no agreement exists on its management. This study was performed to report a case and review the literature to strengthen the understanding of the clinical characteristics of lobular carcinoma *in situ* in breast fibroadenoma and discuss its management plan.

Case Presentation

A 38-year-old woman presented with a painless mass in her right breast for 6 years. Since the discovery of the mass, the patient had been rechecked using breast color ultrasound every year, and no significant enlargement of the mass was found. However, color Doppler ultrasound showed that the mass was enlarged, that is, a hypoechoic area of $2 \times 1.5 \times 1$ cm^3 was observed in the upper right breast quadrant,

with regular morphology and clear boundaries in December 2020. The Breast Imaging Reporting and Data System (BI-RADS) was classified as Category IV.

The doctor performed a fine-needle aspiration biopsy on the patient to clarify the nature of the mass. Then, hematoxylin–eosin-stained pathological sections were made, and the tissue morphology was observed under a microscope. The components of fibroadenoma, namely, epithelial and mesenchymal hyperplasia comprising mesenchymal cells, grew around the ducts of the breast, and the ducts were squeezed into cracks or an open lumen (Fig. 1A and 1B). In addition, some swollen terminal ductal lobular units were found in the fibroadenoma, and the acini were filled with uniform and deep-stained round cells, that is, lobular carcinoma *in situ* (Fig. 1C). The hyperchromatic and uniform round cells involved the ducts of the breast (Fig. 1D). These deeply stained cells were negative for E-cadherin (Fig. 1E), while myoepithelial cells surrounding acini were positive for P63 (Fig. 1F). Subsequently, the tumor was resected. The lobular carcinoma *in situ* was present only in the fibroadenoma, with no involvement of the surrounding margins.

Discussion

Breast fibroadenoma is the most common fibroepithelial tumor comprising both epithelial and mesenchymal components. Although ductal epithelial hyperplasia or metaplasia is common in fibroadenomas, malignant transformation in fibroadenoma is very rare. Cheatle in 1931 first reported carcinoma within fibroadenoma was first reported; subsequently, people gradually increased their understanding, and different types of intrafibroadenoma carcinoma were reported successively [1,2,7] . The types of intrafibroadenoma carcinoma include lobular carcinoma *in situ*, ductal carcinoma *in situ*, and invasive breast cancer. This study focused on the clinical features, pathological characteristics, differential diagnosis, therapy, and prognosis of lobular carcinoma *in situ* within fibroadenoma.

Fibroadenomas are often painless, isolated, and slow-growing nodules. However, breast carcinoma within a fibroadenoma may be accompanied by a rapid increase in mass in a short period. The radiology showed clear nodules with occasional calcification. Studies have shown that one should be vigilant against the occurrence of tumors with fuzzy edges or microcalcifications. Many studies have reported that fibroadenoma is the most common type of benign tumor in women aged less than 35 years. In addition, older age is considered a riks transformation of factor for malignant fibroadenoma [8]. In fact, no clear difference exists between intrafibroadenoma carcinoma and fibroadenoma in terms of clinical and radiological manifestations. Malignancy is rarely suspected even during gross examination, and the final diagnosis depends on pathology. As reported in this case, the patient was a 38-year-old relatively young woman who had no special clinical and imaging findings but was diagnosed with lobular carcinoma *in situ* within fibroadenoma. Therefore, we must be careful of not only the malignant transformation of old or suddenly enlarged fibroadenoma, especially lobular carcinoma *in situ*, but also young and symptomatic fibroadenoma.

Breast fibroadenoma is a common benign fibrous and epithelial tumor. The latest edition of the World Health Organization of the breast divides fibroadenoma into four types, namely classic type, juvenile type, complex type, and cell-rich type [4]. The risk of breast cancer in complex fibroadenoma is increased compared with that in other types of fibroadenoma [9] . The fibroadenoma mainly presents a growth pattern in and around the tube, with no dysplasia of interstitial cells. Epithelial components are often accompanied by common ductal hyperplasia, myoepithelial hyperplasia, sclerosing adenopathy, fibrocystic degeneration, or apocrine metaplasia. Moreover, atypical ductal or lobular hyperplasia, ductal or lobular carcinoma *in situ*, and invasive carcinoma are occasionally seen in fibroadenoma.

Carcinomas within fibroadenoma refer to the cancerous transformation of epithelial components into fibroadenoma; the cancerous tissue is limited to fibroadenoma or accompanied by small infiltration. Carcinomas within fibroadenoma include lobular carcinoma *in situ*, ductal carcinoma, and invasive carcinoma. The literature reports showed that the occurrence of lobular carcinoma *in situ* was the most common. Other types of cancer, such as mucus carcinoma, metaplastic carcinoma, and adenoid cystic carcinoma, are rarely reported. Lobular carcinoma within fibroadenoma needs to be differentiated from the following diseases. (1) Ductal carcinoma *in situ* within fibroadenoma: It has uniformly packed cells in the lumen, but lobular carcinoma in situ loses adhesion and is negative for E-caherin. (2) Common ductal epithelial hyperplasia in fibroadenoma: It also involves the terminal ductal lobular unit, but the cells are disorderly or with the flow-like arrangement, and cell size is inconsistent. In addition, immunohistochemical markers show a mixed phenotype of the myoepithelial and glandular epithelium; Estrogen receptor (ER) and progesterone receptor (PR) are expressed unevenly. (3) Carcinoma within phyllode tumors: Sometimes, it is difficult to distinguish between fibroadenomas and phyllode tumors. The latter often forms distinct phyllode-like structures; mesenchymal spindle cells are also significantly proliferated and even atypical. (4) Lobular carcinoma: It should be differentiated from invasive carcinoma in fibroadenoma. The main body of invasive cancer is often absent in fibroadenoma and infiltrates into fibroadenoma. Cell atypia of the invasive cancer is obvious, mitosis is easily seen, and negative for P63.

Managing cancer in fibroadenomas often adopts corresponding programs according to the type, scope, and hormone receptors of the cancer. Simple tumor resection is recommended for lobular carcinoma *in situ* within fibroadenoma [10,11]. However, simple mastectomy should be considered when the tumor is large, multifocal, or in the center of the breast. Compared with the same type of breast cancer, fibroepithelial intratumoral cancer is less biologically aggressive. This may be related to the envelope of fibroepithelial tumors, restricting cancer growth [12], but further confirmation is needed. When a fibroadenoma suddenly enlarges or is found to be accompanied by calcification on radiography, a fine-needle needle biopsy should be performed to determine the nature of the mass.

Declarations

Acknowledgements

Not applicable.

Author Contributions

Bin Zhou and Luoyan Wu, writing the manuscript. Liyuan Liu, Zhi Zhang and Minshi Ye, conducting the main experiments in this work. Ying Yang, Fangli Wei and Guijie Zhang, Data collection. Dongmei Ye, manuscript writing and critical review of manuscript. Li Qingwu: conceiving and designing the study, providing financial support. All authors read and approved the final manuscript.

Funding

Our study was supported by the Science and Technology Project of Jiangxi Provincial Health and Family Planning Commission (NO. 20184018).

Availability of data and materials

All data are fully available without restriction.

Ethics approval and consent to participate

All ethical approval and consent procedures were approved by the Nanchang First Hospital. We have obtained the patient's informed consent for publishing this article.

Consent for publication

All authors consent for publication.

Competing interests

The authors have declared that no competing interest exists.

References

1. Tan PH. Fibroepithelial lesions revisited: implications for diagnosis and management. *Mod Pathol*. 2021;34(Suppl 1):15-37.
2. Krings G, Bean GR, Chen YY. Fibroepithelial lesions; The WHO spectrum. Semin Diagn Pathol. 2017;34(5):438-452.
3. Onstad M, Stuckey A. Benign breast disorders. Obstet Gynecol Clin North Am. 2013;40(3):459-473.
4. Tan PH, Ellis I, Allison K, et al. The 2019 World Health Organization classification of tumours of the breast. Histopathology. 2020;77(2):181-185.
5. Guerry P, Erlandson RA, Rosen PP. Cystic hypersecretory hyperplasia and cystic hypersecretory duct carcinoma of the breast. Pathology, therapy, and follow-up of 39 patients. Cancer-Am Cancer Soc. 1988;61(8):1611-1620.
6. Kuijper A, Preisler-Adams SS, Rahusen FD, et al. Multiple fibroadenomas harbouring carcinoma in situ in a woman with a family history of breast/ovarian cancer. J Clin Pathol. 2002;55(10):795-797.

7. Saadallah F, Bouraoui I, Naija L, et al. Coexistence of invasive ductal breast carcinoma and fibroadenoma. *Pan Afr Med J*. 2019;33:139.
8. Pick PW, Iossifides IA. Occurrence of breast carcinoma within a fibroadenoma. A review. Arch Pathol Lab Med. 1984;108(7):590-594.
9. Javed A, Jenkins SM, Labow B, et al. Intermediate and long-term outcomes of fibroadenoma excision in adolescent and young adult patients. *Breast J*. 2019;25(1):91-95.
10. Sokolova A, Lakhani SR. Lobular carcinoma in situ: diagnostic criteria and molecular correlates. *Mod Pathol*. 2021;34(Suppl 1):8-14.
11. Rosen PP, Kosloff C, Lieberman PH, et al. Lobular carcinoma in situ of the breast. Detailed analysis of 99 patients with average follow-up of 24 years. *Am J Surg Pathol*. 1978;2(3):225-251.
12. Wu YT, Chen ST, Chen CJ, et al. Breast cancer arising within fibroadenoma: collective analysis of case reports in the literature and hints on treatment policy. World J Surg Oncol. 2014;12:335.

Figures

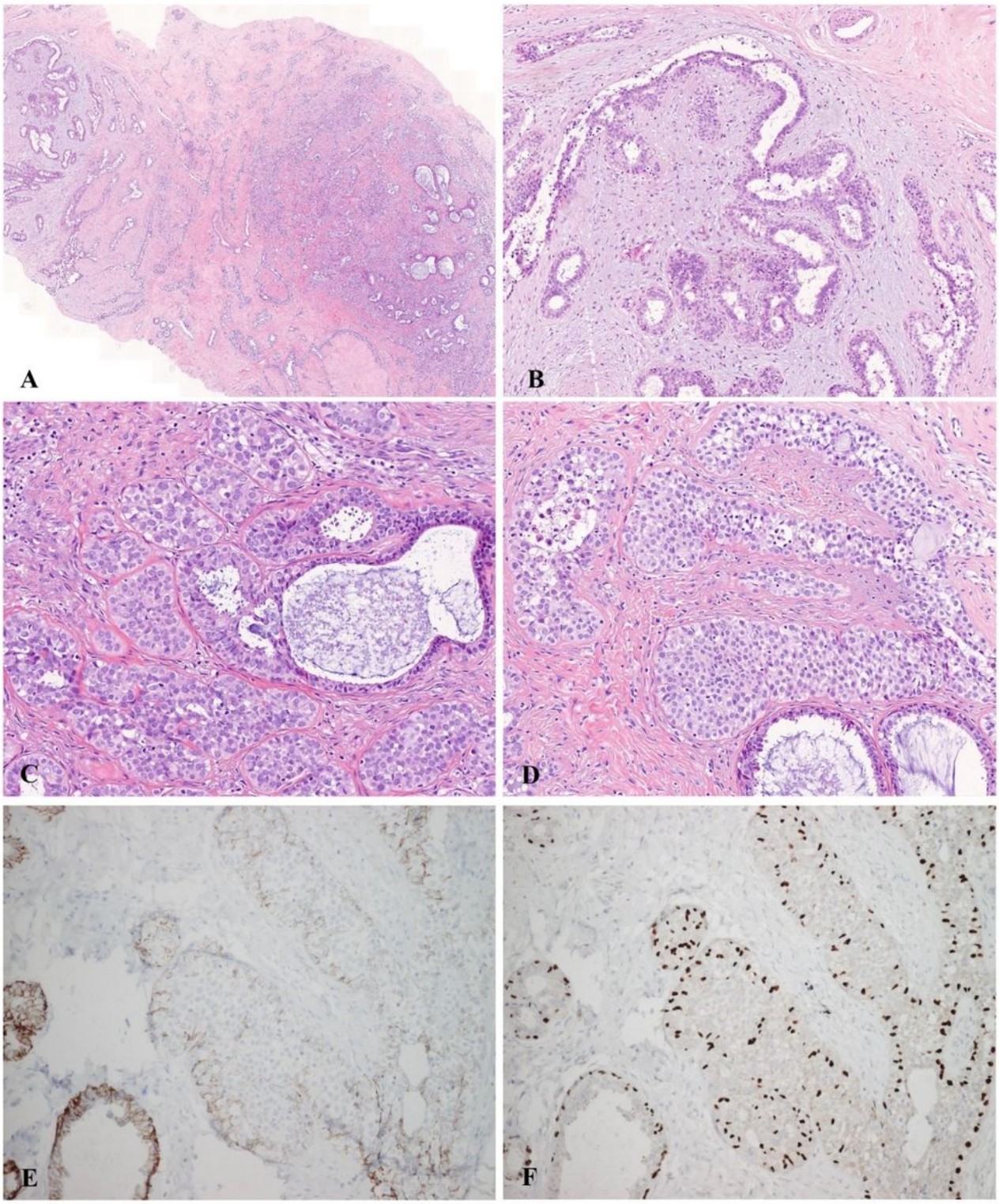

Figure 1

(A) At low magnification, a breast fibroadenoma was found on the left side, while the right side had a large number of cells and deep staining. (B) Epithelial component of the fibroadenoma area had a peripheral growth pattern, with mucinous changes in the interstitium. (C) At a high magnification of the hyperchromatic area, the acinar swelling around the duct was found to be filled with round and uniformly sized cells, that is, lobular carcinoma *in situ*. (D) Lobular carcinoma *in situ* involved the terminal duct. The

results of immunohistochemistry showed that the cells in the terminal duct were negative for E-cadherin (E), while the outer myoepithelial cells were positive for P63 (F).