A novel retractor for reducing operation time and radiation exposure in percutaneous pedicle screw placement

Lei Niu
University of Science and Technology of China
Rui He (179644522@qq.com)
https://orcid.org/0000-0001-5214-1743
Wenzhi Zhang
University of Science and Technology of China
Liqun Duan
University of Science and Technology of China
Xu Li
University of Science and Technology of China
Haiping Cai
University of Science and Technology of China

Research article

Keywords: percutaneous pedicle screw, novel retractor, surgery time, fluoroscopy shot time, thoracolumbar vertebral fracture

Posted Date: February 27th, 2020

DOI: https://doi.org/10.21203/rs.2.24709/v1

Abstract

Background : Percutaneous pedicle screw fixation is less damage to the surrounding musculature and can decrease both blood loss and recovery time, but depends heavily on fluoroscopic guidance. An efficient instrument or system that allows for accurate pedicle screw placement and reduction in the fluoroscopy shot time would therefore be of value.

Methods: 126 patients with single segment thoracolumbar vertebral fracture were surgically treated with percutaneous pedicle screws through our novel retractor technique（group A） or traditional fluoroscopic method(group B), the operation time and fluoroscopy shot times were compared, and the accuracy of screw placement were assessed.

Results : There was no serious complications occurring during our study, such as infection, blood vessel injury, spinal cord or nerve root injury. We did not find any statistically difference between the two groups in corrected rate of regional Cobb's angle or vertebral body height percentage(P>0.05); however, the mean operation time was found to be 75.9±2.37min in the novel retractor method group and 94.2±2.19min in the traditional method group. The difference was statistically significant (p＜0.001). Fluoroscopy shot times averaged 9.01±0.41 in the novel retractor group versus 16.8±0.56 in the traditional group (P < 0.001), the novel retractor group had apparent advantages over the traditional method in postoperative improvement on visual analog scale (VAS) scores and Oswestry Disability Index (ODI) at 2days, 3month after operation and last follow-up (P<0.05). There was no statistical difference between the novel retractor group and traditional method group in the radiographic results and screw position violation grade.

Conclusion: The novel retractor method had several advantages, including shorter operation time, less fluoroscopy shot times, and better postoperative improvement on visual analog scale(VAS) score and Oswestry Disability Index (ODI). It provides a new alternative method for effective management of thoracolumbar fractures.

Background:

Percutaneous pedicle screw fixation offer a less traumatic approach resulting in less damage to the surrounding musculature and a decrease in both blood loss and recovery time[1–5]. These characteristics might translate into better long-term results with a decrease in the muscle denervation, atrophy, and pain. During the traditional percutaneous procedures[6–8], visualization of the bony landmarks depends heavily on fluoroscopic guidance[3, 9], which could result in significant levels of radiation exposure to both the surgeon and assistant[7, 10]. An efficient instrument or system that allows for accurate pedicle screw placement and a reduction in the fluoroscopic time would therefore be of value[1, 4, 11]. In this article, a novel hand-held retractor was designed to help exposing the spinal anatomical landmarks. The aim of the present study was to compare the clinical outcomes, fluoroscopy shot times, operative time,

and the accuracy of the novel hand-held retractor method with the traditional fluoroscopic technique for percutaneous pedicle screw placement.

Methods:

General information

126 patients with thoracolumbar vertebral fracture who underwent posterior percutaneous transpedicular screw fixation were retrospectively reviewed in spinal surgery department of the first affiliated hospital of university of science and technology of China from March 2014 to January 2018. Patient inclusion criteria were: (1) acute or subacute thoracolumbar fracture (T10–L2) at a single level; (2) clinical and imaging data were complete; (3) follow-up period of more than 12 months. We excluded patients with severe osteopenia (defined as bone mineral density [BMD] t score <–2.5), pathologic fractures, spinal cord or cauda equine injury, or those who previously received spine surgery due to trauma.

All patients underwent posteroanterior and lateral X-ray examination, computed tomography (CT) scan (including CT in combination with a 3-dimensional reconstruction), BMD measurement, and magnetic resonance imaging (MRI) examination. The injury severity was determined by The thoracolumbar injury classification system (TLICS)[12–14]. Within the 126 patients, 57 cases received surgery with the application of the novel retractor (novel retractor group, group A), the other 69 patients were treated through the traditional fluoroscopic method (traditional group, group B). The general character and distribution of fractured vertebra were demonstrated in Table 1.

Table 1
Overview of patient's demographic and distribution of fractured vertebra in Group A and Group B

	Novel retractor group (group A)	Traditional group (group B)	P value
Patients(n)	57	69	
Age	45.2 ± 1.94	44.7 ± 1.40	0.830
Gender (male/%)	37 (64.9%)	46 (66.7%)	
Injured spinal level			
T11	5	8	
T12	22	25	
L1	26	28	
L2	4	8	
TLICS score	4.5 ± 0.17	4.6 ± 0.15	0.874
Preoperative duration (days)	5.2 ± 2.0	5.1 ± 2.5	0.833

The character of the novel retractor system

The retractor system consist of a series of ten "s" shaped retractors; for each retractor, it was constituted of two straight heads and a slender shaft, The length of the head increased 2 cm step by step, change from 2 cm to 10 cm, for each retractor, the width of one head was 1 cm, and 1.5 cm for the other head; for all retractor heads, an inside learning angle of 30°was designed in the distant 5 mm end. The retractor can be used to pull soft tissue, and the head of the retractor can be stuck in the base of transverse process, thus Herringbone crest, namely pedicle screw entrance point can be fully exposed(The character of the novel retractor was illustrated in Fig. 1:a-b).

Surgical procedure

All surgical procedures were performed under general anesthesia. Patients were placed in hyperextension in the prone position with abdomen hanging free through a bolster set under the chest and ilium. The pedicles of the fractured vertebra and those of the vertebra above and below the injury level (referred as upper and lower vertebra, respectively) were positioned by C-arm X-ray examination, and were marked on the corresponding skin. Pressure was then applied to the spinous process of the fractured vertebra.

In traditional method group, the skin was incised approximately 1 cm lateral to the corresponding skin marker of pedicle. Lumbodorsal fascia was then shorn. Under the C-arm guidance, the needle was passed through the pedicle into the vertebral body, whereby a guide wire was then inserted into the vertebral body. The dilation tubes were gradually placed through the guide wire, and the last one was withheld. Pedicles

advancing to the junctions between the pedicles and vertebral body were tapped for screw insertion; the hollow pedicle screws were then inserted into the pedicles and vertebral body. Finally, the guide wire and dilation tubes were removed. 4 monoaxial screws were inserted into the upper and lower vertebra, 2 polyaxial pedicle screws were inserted into the fractured vertebra. Neither cross-linking nor drainage was involved. After inserting, the pedicle screws were positioned by C-arm X-ray examination, and were then fixed with rods. The rods were pre-flexed according to the approximate normal sagittal spinal curvature of the fracture region, finally, cephalic and caudalis distractions were performed, respectively.

In novel retractor group, after the incision of skin and lumbodorsal fascia, the space between the multifidus and the longissimus muscles was separated with the index finger, the facet joint was located with the help of the finger, with one retractor of suitable length and width stuck in the base of transverse process, the multifidus was pulled to the lateral of facet joint, another retractor was used to pull the longissimus muscle to the medial, separation was then performed till the outer edge of the facet joint through the intermuscular plane between the multifidus and the longissimus muscles, then the pedicle entry point was exposed clearly, after preparation of the pedicle with a tap, the pedicle screw was inserted by freehand under direct vision; likewise, after the procedure of rod installation and distraction for restoration, positions of pedicle screws and height of the fractured vertebrae were confirmed using C-arm X-ray examination again(The use of novel retractor in percutaneous pedicle screw placement was illustrated in Fig. 1:c-f).

Evaluation methods

The operation time and fluoroscopy shot times of the two groups were recorded. Each screw position was assessed based on the CT scans obtained after the surgery, a 4-point grading scale[15, 16] was used as follows: grade 0 (ideal): accurate screw with no perforation through any cortex; grade 1 (minimally displaced): safe screw with cortical perforation of < 3 mm; grade 2 (moderately displaced): displaced by ≥ 3 mm but ≤ 5 mm; and grade 3 (critical perforation): displaced by > 5 mm. Sagittal regional Cobb angle and the anterior column height of the fractured vertebra were evaluated through the preoperative and postoperative lateral X radiograph. The anterior column height of the fractured vertebra was defined as half of the sum of the heights of upper and lower vertebra. The anterior column height percentage of fractured vertebra was calculated as the ratio of the actual height of the fractured vertebra to the reference anterior column height. Sagittal regional Cobb angle was calculated as the angle between the superior endplate and inferior endplate of the fractured vertebra. visual analog scale (VAS) scores and Oswestry Disability Index (ODI) before surgery, 2 days, 3 months after operation, and last follow-up were assessed. Two independent, experienced spine surgeons, who were not involved with the surgical procedures, examined all of the images twice within an interval of two weeks. Each second examination was blinded to the previous results of each examiner. The average of the four measurements was determined as the final grade.

Statistical analysis

Statistical analysis was done using SPSS 22.0. The accuracy of the screws in the two groups was statistically compared using a rank-sum test with $p < 0.05$ considered significant. Clinical and radiographic data were expressed as mean ± SE, Two-sample-t test was used to compare the measurements between the two groups. $P < 0.05$ was considered statistically significant.

Results

In this study, a total of 342 and 414 pedicle screws were percutaneously placed in group A and B, respectively. The mean operation time of the was found to be 75.9 ± 2.37 min in the novel retractor method group (group A) and 94.2 ± 2.19 min in the traditional method group (group B). These differences were statistically significant (p 0.001). Fluoroscopy shot times averaged 9.01 ± 0.41 times in the novel retractor group versus 16.8 ± 0.56 times in the traditional group ($P < 0.0001$) (Table 2). This represents an average decrease of 7.7 (45.8%) fluoroscopy shot times with the use novel retractor. Of those pedicle screws, 292 screws (85.4%) in group A and 349 screws (84.3%) in group B were perfectly located within the pedicle (grade 0), and the rest were misplaced with a variable degrees and directions. Most pedicle violations were Grade 1 (37(10.8%) screws in group A, 45(10.9%) screws in group B), without any grade 3 displacement. There was no statistical difference between group A and B in the screw position of grade 0 and violation grade (grade 1, 2, and 3) ($Z = 0.452$, $p = 0.651$). The complete information about pedicle violations is demonstrated in Fig. 2.

Differences were not found in Cobb's angle and vertebral body height percentage between the two groups at different time points (Table 2) ($P > 0.05$). All patients were followed up for 12 to 30 months. with an average of 15.5 months in group A, and 15.9 months in group B. The VAS score and ODI of the two groups were shown in Table 2. VAS score and ODI of the two groups were significantly improved 2 days after surgery compared with the preoperative level, and VAS score and ODI of group A were significantly lower than that of group B, with statistically significant difference ($P < 0.05$). VAS score and ODI score of the two groups were further improved 3 months after the operation and at the last follow-up, and the results of group A were significantly better than that of group B. Except for ODI at the last follow-up, the differences between the two groups were statistically significant ($P < 0.05$).

Table 2
Comparison of the outcomes between novel retractor group (group A) and conventional fluoroscopic method group (group B).

	novel retractor group (group A)	**Conventional group (group B)**	**P value**
surgery time(min)	75.9 ± 2.37	94.2 ± 2.19	< 0.001
fluoroscopy Shot times	9.01 ± 0.41	16.8 ± 0.56	< 0.001
Follow-up duration (months)	15.5 ± 0.65	15.9 ± 0.67	0.679
anterior column height percentage (%)			
preoperative	69.4 ± 1.36	68.9 ± 1.26	0.808
2 days postoperative	92.9 ± 0.90	90.7 ± 0.84	0.07
3 months postoperative	90.4 ± 1.75	90.2 ± 0.64	0.908
Last follow-up	90.0 ± 0.64	89.0 ± 0.57	0.243
Sagittal regional Cobb angle (°)			
preoperative	16.2 ± 0.60	16.6 ± 0.58	0.628
2 days postoperative	8.9 ± 0.34	9.4 ± 0.38	0.441
3 months postoperative	10.2 ± 0.25	9.7 ± 0.37	0.284
Last follow-up	10.3 ± 0.25	10.1 ± 0.37	0.630
VAS score			
Preoperative	4.90 ± 0.16	4.73 ± 0.16	0.457
2 days postoperative	2.53 ± 0.11	3.0 ± 0.10	0.002
3 months postoperative	1.6 ± 0.14	2.3 ± 0.13	0.002
Last follow-up	1.1 ± 0.11	1.5 ± 0.09	0.012
ODI			
Preoperative	57.0 ± 2.00	55.2 ± 1.60	0.481
2 days postoperative	23.3 ± 1.25	27.2 ± 1.27	0.031
3 months postoperative	11.7 ± 0.41	14.1 ± 0.50	< 0.001
Last follow-up	10.4 ± 0.47	10.8 ± 0.36	0.619

Discussion

Percutaneous technique of pedicle screw insertion was initially introduced by Magerl[17] in 1977 as a temporary external fixation for the spinal fracture and spondylodiscitis. Different studies[6–8, 18] have shown that this technique improved the perioperative outcomes by reducing the blood loss and transfusion. Furthermore, it improved the postoperative outcomes by reducing the back pain and hospital stays, with similar surgical efficacy compared with the traditional open pedicle screw fixation[18]. More importantly, the rate of the neurological injury risk had been shown to be as less as open techniques[19].

The percutaneous pedicle screw placement had significant potential limitations as well. These limitations included[1, 3, 10, 20]: longer operation time and greater fluoroscopy frequencies for both medical staffs and the patients. The traditional percutaneous methods showed a high incidence of erroneous placement[21] of the pedicle screws and a steep learning curve[22]. In the traditional method, the accurate percutaneous pedicle screw placement relies heavily on fluoroscopy in order to obtain a proper screw trajectory. The insertion of guide-wire into the vertebral pedicle required numerous radiographic images in a trial-and-error fashion[23]. In recent years, a lot of systems or equipment[11, 24, 25] were introduced to facilitate the placement of percutaneous pedicle screw. These systems might improve the safely and decrease the radiation exposure, but added a significant amount of time to the operative procedure at the same time, what’s more, most hospitals cannot afford the purchase cost of these systems. Compared with these complicated systems, our novel retractor was relatively simple and practical, and affordable for every patient. The exposure of the entry point was facile with the help of our novel retractor. The feasibility and practicability of our novel retractor significantly reduce the operation time and radiation exposure in comparison with the traditional fluoroscopic method, in our study, the operation time in novel retractor group was 81.5% of that of traditional group, the fluoroscopic shot times was 43.8% less compared with traditional group.

VAS scores were significantly different between group A and B. The results showed that our novel retractor method was advantageous in this aspect over the traditional method. In our novel retractor method, we can set the percutaneous pedicle screw through the paraspinal sacrospinalis-splitting approach between the multifidus and the longissimus, from which the transverse process and facet joint could be easily exposed, making a good operative field and the pedicle screws could be inserted precisely. But in the traditional group, repeated punctures were always needed before the needle passing through the pedicle into the vertebral body in satisfactory position and direction, which was associated with facet joint capsule damage[26], it was a common cause of low back pain in adults and may lead to chronic pain and disability[27]. In the traditional group, in the dilation tubes expanding and screw-in process of the percutaneous pedicle screw, it may not pass through the intermuscular space between the multifidus and the longissimus accurately, causing extensive stripping of paraspinal muscle, resulting in severe back pain and longer hospitalization time.

The novel percutaneous placement tool was particularly suitable for an accurate percutaneous pedicle screw placement in the obese patients. The intraoperative fluoroscopic or radiographic identification of

the anatomical landmarks were frequently blurred in the obese patients and the quantity of the multifidus muscle was a significant risk factor for the pedicle screw misplacement[28, 29]. These results inferred that the fluoroscopic images were frequently blurred in bulky patients and the procedures were more difficult to be performed in a deeper space. In our novel retractor method, the longest head was 10 cm, it was long enough to reach the facet joint directly. The novel technique could be very demanding as it providing gross visualization and tactile feel, by using the novel retractor, we could expose the entry point effectively and thus the percutaneous pedicle screws could be accurately placed.

What's more, no difference was found in correcting rate of Cobb's angle and vertebral body height percentage between the two groups, suggesting that novel retractor method was similar to the traditional method in radiographic outcomes. Currently the major limitation of the novel retractor is that it is not suitable for posterior laminectomy and posterolateral fusion. Therefore, our inclusion criteria were strictly limited to cases of single segment thoracolumbar vertebral fractures.

Conclusion

Compared with the traditional fluoroscopic method, the novel retractor method has several advantages, including shorter operative time, less fluoroscopy shots, and improved visual analog scale (VAS) scores and ODI. It provides a new alternative operation method for effective management of thoracolumbar fractures.

Abbreviations

VAS
Visual Analog Scale
ODI
Oswestry Disability Index
TLICS
Thoracolumbar Injury Classification and Severity Score

Declarations

Ethics approval and consent to participate

Our study was approved by the Institutional Review Board of The First Affiliated Hospital of USTC (University of Science and Technology of China). Written informed consent was obtained for every patient in our study.

Consent for publication

All patients in this study signed informed consent for print and electronic publication.

Availability of data and materials

The original reports, laboratory studies, imaging studies and outpatient clinic records are retained as per normal procedure within the medical records of our institution. All data generated or analyzed during this study are available from the corresponding author on reasonable request.

Competing interests

The authors declare that they have no competing interests.

Funding

The study was not funded.

Authors' contributions

LN and **RH:** Concept and design of the study, manuscript writing; **WZ:** collection of data, data analysis; **LD:** manuscript writing; **XL** and **HC:** discuss the design and revise this paper.

All authors interpreted data, drafted or revised the article critically for important intellectual content, and approved the final version of the manuscript.

Acknowledgements

Not Applicable.

Authors' information

Lei Niu and Rui He contributed equally to this work.

Affiliations

[1]Spine Center, Department of Orthopedics, The First Affiliated Hospital of USTC, Division of Life Sciences and Medicine, University of Science and Technology of China, Hefei, Anhui, 230036, China.

Lei Niu (MD)[1], Rui He(MD)[1], Wenzhi Zhang(MD, PhD)[1], Liqun Duan(MD, PhD)[1], Xu Li(MD, PhD)[1]& Haiping Cai(MD)[1]

References

1. Ishii K, Kaneko Y, Funao H, Ishihara S, Shinohara A, Nakanishi K, Hikata T, Fujita N, Iwanami A, Hosogane N *et al*: A Novel Percutaneous Guide Wire (S-Wire) for Percutaneous Pedicle Screw Insertion: Its Development, Efficacy, and Safety. *Surgical innovation* 2015, 22(5):469-473.
2. Chapman TM, Blizzard DJ, Brown CR: CT accuracy of percutaneous versus open pedicle screw techniques: a series of 1609 screws. *European spine journal* 2016, 25(6):1781-1786.

3. Gu G, Zhang H, He S, Cai X, Gu X, Jia J, Fu Q, Zhou X: Percutaneous Pedicle Screw Placement in the Lumbar Spine: A Comparison Study Between the Novel Guidance System and the Conventional Fluoroscopy Method. *Journal of spinal disorders & techniques* 2015, 28(9):E522-527.
4. Ishii K, Shiono Y, Funao H, Singh K, Matsumoto M: A Novel Groove-Entry Technique for Inserting Thoracic Percutaneous Pedicle Screws. *Clinical spine surgery* 2017, 30(2):57-64.
5. Alander DH, Cui S: Percutaneous Pedicle Screw Stabilization: Surgical Technique, Fracture Reduction, and Review of Current Spine Trauma Applications. *J Am Acad Orthop Surg* 2018, 26(7):231-240.
6. Li K, Li Z, Ren X, Xu H, Zhang W, Luo D, Ma J: Effect of the percutaneous pedicle screw fixation at the fractured vertebra on the treatment of thoracolumbar fractures. *International orthopaedics* 2016, 40(6):1103-1110.
7. Phan K, Rao PJ, Mobbs RJ: Percutaneous versus open pedicle screw fixation for treatment of thoracolumbar fractures: Systematic review and meta-analysis of comparative studies. *Clinical neurology and neurosurgery* 2015, 135:85-92.
8. Wang H, Zhou Y, Li C, Liu J, Xiang L: Comparison of Open Versus Percutaneous Pedicle Screw Fixation Using the Sextant System in the Treatment of Traumatic Thoracolumbar Fractures. *Clinical spine surgery* 2016,6(2):186-94.
9. Tsuang F-Y, Chen C-H, Kuo Y-J, Tseng W-L, Chen Y-S, Lin C-J, Liao C-J, Lin F-H, Chiang C-J: Percutaneous pedicle screw placement under single dimensional fluoroscopy with a designed pedicle finder-a technical note and case series. *The spine journal : official journal of the North American Spine Society* 2017, 17(9):1373-1380.
10. Zhang L, Zhou X, Cai X, Zhang H, Fu Q, He S: Reduction in radiation during percutaneous lumbar pedicle screw placement using a new device. *Minimally invasive therapy & allied technologies : MITAT : official journal of the Society for Minimally Invasive Therapy* 2014, 23(3):173-178.
11. Richter PH, Gebhard F, Salameh M, Schuetze K, Kraus M: Feasibility of laser-guided percutaneous pedicle screw placement in the lumbar spine using a hybrid-OR. *Int J Comput Assist Radiol Surg* 2017, 12(5):873-879.
12. Park HJ, Lee SY, Park NH, Shin HG, Chung EC, Rho MH, Kim MS, Kwon HJ: Modified thoracolumbar injury classification and severity score (TLICS) and its clinical usefulness. *Acta Radiol* 2016, 57(1):74-81.
13. Joaquim AF, de Almeida Bastos DC, Jorge Torres HH, Patel AA: Thoracolumbar Injury Classification and Injury Severity Score System: A Literature Review of Its Safety. *Global spine journal* 2016, 6(1):80-85.
14. Pneumaticos SG, Karampinas PK, Triantafilopoulos G, Koufos S, Polyzois V, Vlamis J: Evaluation of TLICS for thoracolumbar fractures. *European spine journal* 2016, 25(4):1123-1127.
15. Innocenzi G, Bistazzoni S, D'Ercole M, Cardarelli G, Ricciardi F: Does Navigation Improve Pedicle Screw Placement Accuracy? Comparison Between Navigated and Non-navigated Percutaneous and Open Fixations. *Acta neurochirurgica Supplement* 2017, 124:289-295.

16. von Jako R, Finn MA, Yonemura KS, Araghi A, Khoo LT, Carrino JA, Perez-Cruet M: Minimally invasive percutaneous transpedicular screw fixation: increased accuracy and reduced radiation exposure by means of a novel electromagnetic navigation system. *Acta neurochirurgica* 2011, 153(3):589-596.
17. Magerl FP: Stabilization of the lower thoracic and lumbar spine with external skeletal fixation. *Clin Orthop Relat Res* 1984(189):125-141.
18. Sun XY, Zhang XN, Hai Y: Percutaneous versus traditional and paraspinal posterior open approaches for treatment of thoracolumbar fractures without neurologic deficit: a meta-analysis. *European spine journal* 2017, 26(5):1418-1431.
19. Yang M, Zhao Q, Hao D, Chang Z, Liu S, Yin X: Comparison of clinical results between novel percutaneous pedicle screw and traditional open pedicle screw fixation for thoracolumbar fractures without neurological deficit. *International orthopaedics* 2019, 43(7):1749-1754.
20. Mobbs RJ, Raley DA: Complications with K-wire insertion for percutaneous pedicle screws. *Journal of spinal disorders & techniques* 2014, 27(7):390-394.
21. Zhao Q, Zhang H, Hao D, Guo H, Wang B, He B: Complications of percutaneous pedicle screw fixation in treating thoracolumbar and lumbar fracture. *Medicine (Baltimore)* 2018, 97(29):e11560-e11560.
22. Fan Y, Zhang J, He X, Huang Y, Wu Q, Hao D: A Comparison of the Mini-Open Wiltse Approach with Pedicle Screw Fixation and the Percutaneous Pedicle Screw Fixation for Neurologically Intact Thoracolumbar Fractures. *Medical science monitor : international medical journal of experimental and clinical research* 2017, 23:5515-5521.
23. Smith BW, Joseph JR, Kirsch M, Strasser MO, Smith J, Park P: Minimally invasive guidewireless, navigated pedicle screw placement: a technical report and case series. *Neurosurgical focus* 2017, 43(2):E9.
24. Molliqaj G, Schatlo B, Alaid A, Solomiichuk V, Rohde V, Schaller K, Tessitore E: Accuracy of robot-guided versus freehand fluoroscopy-assisted pedicle screw insertion in thoracolumbar spinal surgery. *Neurosurgical focus* 2017, 42(5):E14-E14.
25. Tian W, Fan M-X, Liu Y-J: Robot-assisted Percutaneous Pedicle Screw Placement Using Three-Dimensional Fluoroscopy: A Preliminary Clinical Study. *Chinese medical journal* 2017, 130(13):1617-1618.
26. Jones-Quaidoo SM, Djurasovic M, Owens RK, 2nd, Carreon LY: Superior articulating facet violation: percutaneous versus open techniques. *Journal of neurosurgery Spine* 2013, 18(6):593-597.
27. Snidvongs S, Taylor RS, Ahmad A, Thomson S, Sharma M, Farr A, Fitzsimmons D, Poulton S, Mehta V, Langford R: Facet-joint injections for non-specific low back pain: a feasibility RCT. *Health Technol Assess* 2017, 21(74):1-130.
28. Kim MC, Chung HT, Cho JL, Kim DJ, Chung NS: Factors affecting the accurate placement of percutaneous pedicle screws during minimally invasive transforaminal lumbar interbody fusion. *European spine journal* 2011, 20(10):1635-1643.
29. Mobbs RJ, Sivabalan P, Li J: Technique, challenges and indications for percutaneous pedicle screw fixation. *J Clin Neurosci* 2011, 18(6):741-749.

Figures

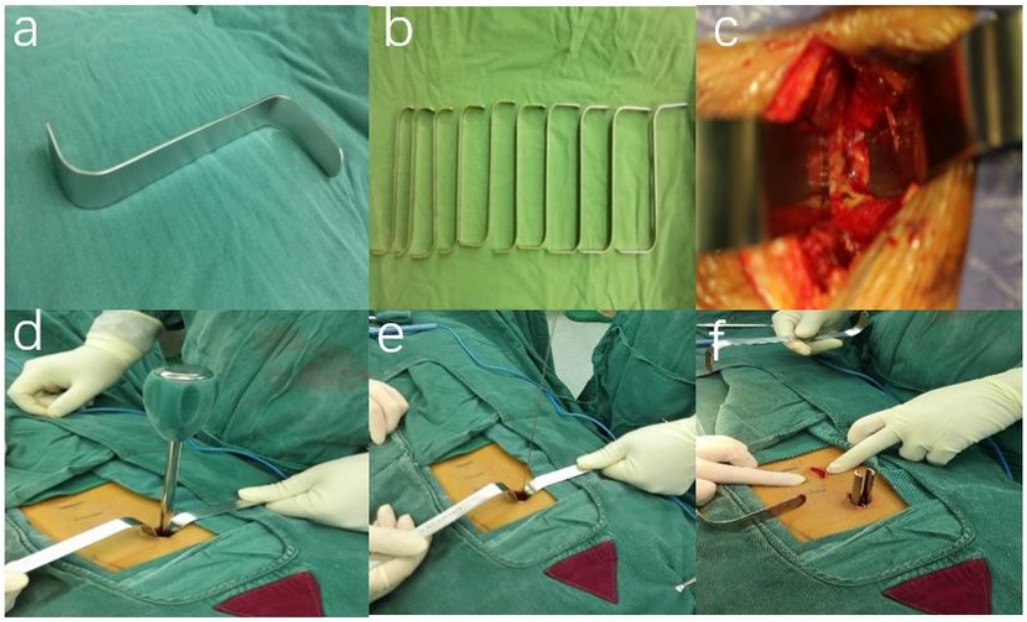

Figure 1

The series of novel retractors and their application in the surgery a. The “s” shaped single retractor; b. The series of ten retractors with different length and width of head; c. With the help of two retractors, the Herringbone crest, thus entry point of pedicle screw, can be exposed; d. Preparation of the pedicle with a tap; e. After conforming that there was no penetration with a probe, the guide-wire was inserted into the pedicle; f. The pedicle screw was inserted freehand.

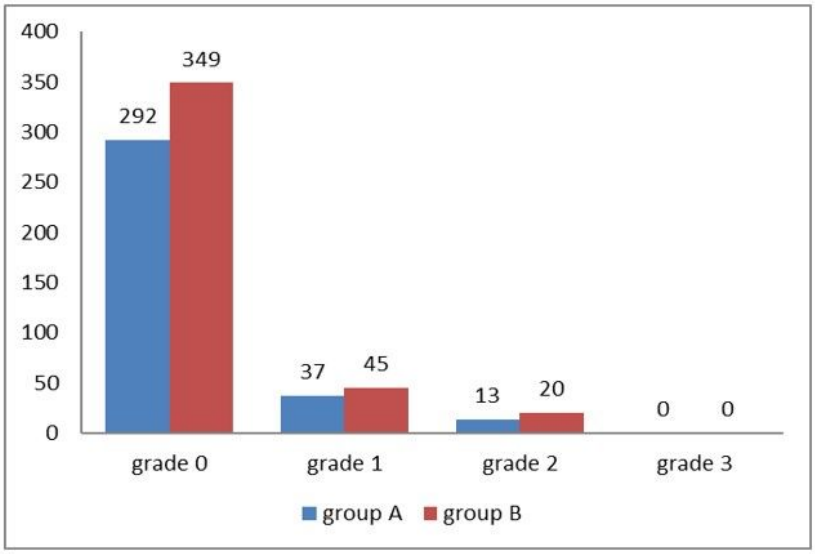

Figure 2

A bar graph representation of the amount of screws classified according to Gertzbein-Robbins classification category

Supplementary Files

This is a list of supplementary files associated with this preprint. Click to download.

- supplementaldigitalcontent.pdf