Transsphincteric rectal resection techniques should be considered as sphincter-sparing surgical procedures in lower rectal cancer cases with external sphincteric invasion because the invased proximal sphincteric segment can be resected

Ali Naki Yücesoy (alinakiyucesoy@gmail.com)
Istanbul Bagcilar Training and Research Hospital

Farid Mohamad Hamad
Istanbul Bagcilar Training and Research Hospital

Nedim Polat
Beykent University

Research Article

Keywords: Lower rectal cancer, Transsphincteric rectal resection, Intersphincteric rectal resection, External anal sphincteric invasion,Proximal segmental sphincteric excision

Posted Date: April 12th, 2022

DOI: https://doi.org/10.21203/rs.3.rs-1526965/v1

Abstract

Purpose: Tumor invasion of the external anal sphincteric muscle in patients with lower rectal cancer is one of the most important contraindications for the intersphincteric resection technique, which is the most common sphincter-sparing method in lower rectal cancer surgery. The main purpose of this article is showed that in lower rectum patients with external anal sphincter invasion, the tumoral lower rectal segment can be excised together with the invaded proximal segment of the external anal sphincter muscle system using the transsphincteric rectal resection surgeries performed with combined abdominal and perineal access, and it is highlighted that they can be considered as sphincter-sparing surgical procedures in these cases.

Methods: This study includes the retrospective evaluation of 4 male and 1 female patient with advanced lower rectal adenocarcinoma detected external anal sphincteric invasion on their preoperative MRI results who underwent proximal segmental sphincteric excision and sphincter-sparing rectal resection operations in transsphincteric plan after neoadjuvant chemoradiotherapy.

Results: In the postoperative follow-up of patients; Perineal fistula developed in 3 patients. Anastomotic stenosis developed in 2 patients, one of whom developed a perineal fistula. No external sphincteric invasion was detected in the postoperative histopathological evaluation of 1 patient. In the anal sphincteric pressure measurements made in the postoperative period, partial decreases were observed in the resting and maximal squeezing anal pressures of the patients. In the clinical follow-up of the patients whose ileostomy was closed, it was determined that sufficient continence was achieved. One patient died at postoperative 8th month following systemic metastases occurring at postoperative 5th month.

Conclusion: Invased proximal sphincteric segment can be resected by using transsphinteric rectal resection techniques in advanced lower rectal cancer cases.

Introduction

Low rectal cancer can be defined as any malignant tumor that arises in 4-6 cm distal part of the rectum between the anal verge and the puborectal muscle. Recently, it has been possible to provide gastrointestinal continuity at the levels below the puborectal muscle, thanks to various technological developments such as the use of staplers and new surgical techniques such as transanal access, and sphincter-sparing surgical procedures performed at these levels are called ultra-low anterior rectal resection [1]. Despite the decrease observed in the proportion of patients who underwent permanent colostomy due to the development of sphincter-sparing surgical techniques, still 20% of patients with rectal cancer require abdominoperineal excision. Sphincter-sparing surgical methods for cancers localized in the lower rectum have higher rates of rectal amputation, recurrence, and fecal incontinence compared to cancers in other regions of the rectum, due to the difficulties encountered in surgical access due to the anatomical localization of the lower rectum, as well as its close proximity to the anal sphincteric muscles and pelvic floor [2].

Anatomically, after passing through the rectum, abdominal and pelvic cavities, it opens into the anatomical anal canal after forming an important part of the surgical anal canal in the ischioanal fossa below the level of the puborectal muscle. The 2/3 distal part of the lower rectum, which is located in the ischioanal fossa and opens into the anal canal, together with the external anal sphincteric musculature surrounding it, constitutes an important component of the surgical anal canal. In this sense, it can be roughly thought that the surgical anal canal is formed by two intertwinning cylindrical muscular tubes. The outer cylindrical muscular tube is formed by the external anal sphincteric muscle and has a reel-like structure that expands at the lower and upper poles between the puborectal muscle and the anal verge. The inner muscular tube is formed by the 2/3 distal part of the lower rectum below the level of the puborectal muscle and the anatomical anal canal [3]. The potential space between both cylindrical muscular tubes is called the intersphincteric space and the intersphincteric dissection technique is performed in this potential space. Intersphincteric dissection can usually be performed using perabdominal and peranal accesses [4,5]. Coloanal anastomoses following distal rectal resections performed in the intersphincteric plane below the level of the puborectal muscle are usually performed peranally with the aid of a circular stapler or hand-sewn following anal dilatation with the help of retractors [6]. In the recently developed transanal total mesorectal excision technique, the abdominopelvic cavity is reached after performing distal rectal dissection in the intersphincteric plane by peranal way [7].

While rectal dissection is performed in the intersphincteric plane, the external anal sphincteric musculature remains outside the surgical field of vision. The surgical anal canal is anatomically located in the ischioanal fossa. With anterior or posterior perineal access, direct surgical access can be achieved in the ishioanal fossa where there is no direct surgical access with the intersphincteric dissection technique, and on the surgical anal canal in the extrasphincteric plane. Surgical interventions for the lower rectum at this level are performed in the transsphincteric plane. In transsphincteric rectal resection techniques that can be performed with anterior or posterior perineal access, coloanal anastomosis can be performed by resection of the distal rectum in two different ways, after surgical vision is obtained in the ischioanal fossa over the external anal sphincteric system on the extrasphincteric plane . As in Mason's original description, after providing of the surgical dissection in the extrasphincteric plane with perineal access and the transition to the intersphincteric plane by cutting the external sphincteric muscle, the dissection line in the intersphincteric plane is combined with the abdominopelvic dissection line extending to the same plane. Subsequent distal resection and coloanal anastomosis are performed in the intersphincteric plan with perineal access, and following the coloanal anastomosis, the external anal sphincter muscle is repaired and the surgical procedure is completed (Figure 1) [8]. Or, after dissection in the extrasphincteric plane in the ischioanal fossa by perineal access, the distal resection line is determined. Afterwards, abdominopelvic and perineal dissection lines are connected by releasing the fibrous ligaments between the puborectal muscle and the external anal sphincteric muscles. In this way, the distal rectum is mobilized to the level of the subcutaneous external anal sphincter in the extrasphincteric plane, together with external anal sphincter surrounding it. When the rectosigmoid resection is completed in the transsphincteric plane from the determined distal resection line, the lower

rectal segment between the puborectal muscle level and the distal resection level as distal part of the resected specimen is excised together with the proximal external sphincteric segment surrounding it, and a coloanal anastomosis is made by using perineal access(Figure 2)[9,10].

Currently, sphincter-sparing surgical interventions for lower rectal cancers are generally performed in the intersphincteric dissection plane using perabdominal or peranal accesses. For sphincter-sparing surgery performed in the intersphincteric space, absolute contraindications are T4 tumors, invasion of external anal sphincter, fixed tumors in digital examination, poorly differentiated tumor, poor preoperative sphincter function, distant metastases and presence of mental disease [11,12]. Anal sphincteric muscle invasion is usually seen 3 in lower rectal cancers localized below the level of the puborectal muscle. The 2/3 distal part of the lower rectum, which forms the inner tubular component of the surgical anal canal, is completely surrounded by the external anal sphincteric musculature (EAS). In this localization, there is no fatty tissue or mesorectal tissue around the lower rectum, and it is directly adjacent to the EAS via the potential intersphincteric space. Cancers originating from the lower rectal mucosa, after spreading radially in the intestinal wall, may invade the EAS locally by direct proximity. Therefore, EAS invasion can be encountered in locally advanced cancers located in the lower rectum, unlike cancers localized in other regions of the rectum. EAS invasion constitutes one of the most important contraindications for the intersphincteric dissection technique [11,12,13]. In cases of lower rectal cancer encountered with EAS invasion, the cylindrical rectal amputation technique performed in the extrasphincteric plane is the prominent surgical intervention in current treatment [14,15,16]. However, recently, sphincter-sparing surgical techniques performed in the transsphincteric plane by combining anterior or posterior perineal access with abdominal access have attracted attention in the surgical treatment of cancers localized in the lower rectum [17,18]. With sphincter-sparing surgical techniques performed in the transsphincteric plane using combined abdominal and perineal accesses, the distal surgical dissection is performed in the extrasphincteric plane as in cylindrical rectal amputation. In this way, it is possible the excision of the invading proximal sphincteric segment together with the lower rectal segment surrounded it by using the surgical advantages of the extrasphincteric dissection plane unlike the intersphincteric dissection technique [9,10].

Patİents And Methods

Study Design

This study includes a retrospective evaluation of the clinical, operative and postoperative findings in the low rectal cancer patients who had external anal sphincteric invasion on their preoperative MRI, and underwent to proximal segmental sphincteric excision and sphincter-sparing operations in the transsphincteric plane performed in Bağcılar Education and Training Hospital between September 2020 and December 2021. The study was conducted in accordance with the tenets of the Declaration of Helsinki. Given that transsphincteric resection removes the part of the external anal sphincter, the patients was carefully informed in regard to morbidity and functional outcomes following this procedure, and informed consent was obtained from all individual participants. 4 men and 1 woman patient with lower

rectal cancer, localized at a distance of 2.5 - 3.5 cm from the anal verge, with external anal sphincter invasion detected according to MRI results who underwent to transsphincteric ultra-low anterior rectal resection with proximal sphincteric segmental excision, following neoadjuvant chemo-radiotherapy was evaluated retrospectively. The mean age of the patients was 59 years. Using combined abdominal and anterior perineal accesses, the invasive proximal segment of the external anal sphincter muscle between the corresponding puborectal muscle and the distal resection line was excised in the transsphincteric plane, and a coloanal anastomosis was performed. Afterwards, a covering ileostomy was opened. After the macroscopic evaluation of the resection materials in the pathology department following the operations, the findings related to the presence of external sphincter invasion and the circumferential resection margine involvement in the resection materials were evaluated histopathologically. The patients were discharged after clinic healing. The ileostomies were closed after anal sphincteric pressure measurements were made, and this procedure was delayed in the cases who developed anal fistula and anal stenosis secondary to the surgery until recovery was achieved.

Operative Findings

Preoperative full bowel preparation and antibiotic prophylaxis were applied to all patients. Operations were performed in two phases, abdominal and anterior perineal, in patients prepared in the Lloyd-Davis lithotomy position. Open, laparoscopic or robotic methods can be used for the abdominal phase and all have similar surgical procedures. In 3 of our patients, the abdominal phase was completed by laparoscopic, and in 2 of them, the abdominal phase was converted to the open method with midline incision. In the abdominal phase, the left colon and splenic flexure were mobilized. Inferior mesenteric vessel was ligated and divided. The sigmoid colon and rectum, along with intact mesorectal tissue, were liberalized at the pelvic floor up to the level of the puborectal muscle. Following the completion of the abdominal phase, the perineal phase was started. For the perineal phase, the ischioanal fossa was reached with anterior perineal access, using elliptical incisions made at the posterior vaginal fourchet level in women and vertical incisions made between the scrotum and anal verge in men. The distal rectum, surrounded by EASM in the iscioanal fossa, was dissected in the extrasphincteric plane, preserving the pudendal nerve branches. The dissection plan was continued up to the level of the puborectal muscle above and the subcutaneous external anal sphincteric muscle below, and the distal rectum localised below the level of the puborectal muscle was liberalize 360 degrees in the extrasphincteric plane (Figure 3). Then, the fibrous ligaments between the puborectal muscle and the deep external anal sphincteric muscle fibers were opened. The abdominopelvic dissection line and the perineal access route and the extrasphincteric dissection lines provided in the ischioanal fossa were combined. In this way, the abdominopelvic and ischioanal cavities were combined at the level of the puborectal muscle, and total rectal mobilization was achieved up to the level of the subcutaneous external anal sphincteric muscle. The distal resection line was determined according to the localization of the tumor in the lower rectum, and a full-thickness distal rectal resection was performed in the transsphincteric plane by transection from this level (Figure 4). After the rectosigmoid colon and intact mesorectal tissue, which had already been liberated in the abdominal phase in the abdominopelvic cavity, were extracted through the perineal incision, the rectosigmoid resection was completed via perineal

access (Figure 5). In this way, the surgical specimen was extracted from the perineal incision without the need for any additional incision in the abdominal wall in cases whose abdominal phase was completed laparoscopically. Unlike the intersphincteric dissection technique, the tumoral segment localized in the lower rectum was excised together with the invasive proximal EASM segment surrounding it. Puborectal and levator muscles were preserved. Internal anal sphincteric muscle was usually preserved or partially resected proximal, depending on the resection level. After the distal resection line was determined to be clean according to the frozen-section result, a hand-sewn double-layer colo-anal anastomosis was performed between the colon and the distal anal segment surrounded by the distal external anal sphincteric segment using the perineal access (Figure 6). Covering ileostomy was routinely performed in all patients. After the abdominal and perineal drains were placed, the incisions were closed.

Results

All patients underwent sphincter sparing surgical procedures in the transsphincteric plane and at ultralow level, including the proximal segment of the external anal sphincteric musculature. No patients converted to the abdominoperineal resection. The mean tumor localization was 3 cm from the anal verge. Following rectal resection, the distal rectal cuff length was not sufficient for stapler application, so manual coloanal anastomosis was performed. The surgical specimens were sent to the pathology department for macroscopic and histopathological evaluation after the operations. There was no perioperative mortality. The patients were discharged on average 10-15 days after the surgery to come for follow-up. In the postoperative period, anterior perineal fistula developed in 3 patients, and mild degree anastomotic stricture developed in 2 patients.

Macroscopic Findings: In order to evaluate the radial spread of the tumor and the presence of external sphincter invasion after the operations, multiple sections were taken and the specimens were examined macroscopically on the table. In the macroscopic examination, the invasive areas in the resected proximal external anal sphincteric segment surrounding the advanced tumor localized in the lower rectum were also reviewed. The local invasive areas in the resected proximal external anal sphincteric segment which is ocurred by advanced low rectal cancer through the direct neighborhood from the intersphincteric space were remarkable (Figure 7). Another remarkable feature unlike the intersphincteric resection technique was that the circumferential resection margin in the examined specimens was formed by the external surface of the external anal muscle, which completely surrounded the lower rectum below the puborectal muscle level.

Microscopic Findings: In the histopathological examination, tumoral local invasion criteria such as radial spread of tumor localized in the lower rectum, areas showing the external anal sphinteric muscular invasion, and circumferential resection magrine involvement were evaluated in the foreground, rather than lymphatic invasion. No external anal sphincteric muscle invasion was detected microscopically in 1 patient. Tumoral cells invading the striated muscle tissue of the external anal sphinteric system were detected in two patients, and mucin pooling (chemoradiotherapy effect) in two patients. Although there was external sphincteric muscle invasion, the circumferential resection margine was negative in all

patients when the extrasphincteric dissection plan of the resected proximal EAS segment was considered as the circumferential resection margine.

Postoperative Findings: Postoperative findings are given in Table 1. No postoperative mortality was encountered in the early period. The patients were discharged to come for controls after being hospitalized for an average of 10-15 days. Perineal fistula opening to the incision line in the perineum occurred following perineal sepsis in the postoperative period in 3 patients, 1 female and 2 males. Patients who developed perineal fistula were followed by weekly. Perineal fistulas closed spontaneously in periods ranging from 2 months to 6 months. Systemic metastases arose in the 5th postoperative month in a female patient who developed a perineal fistula and whose perineal fistula was closed in the postoperative 2nd month, and died in the postoperative 8th month following a rapid course. In the follow-up of 2 male patients who developed perineal fistula, the stenosis developed in the anastomosis line, which narrowed the lumen between 30-50%. Anal stenoses were treated with repeated anal dilatations. After anal sphincteric pressure measurements, ileostomy was closed in 3 patients. One patient's ileostomy status is ongoing. In anal sphincteric pressure measurements, an average of 10 mmHg decrease was detected in maximum squeezing pressure values, despite the application of proximal external anal sphincteric excision. No significant decreases were observed in resting anal pressure values. After ileostomy reversal the patients have had enough continence to gas, solid and liquid stool. In clinical follow-ups of the ileostomy reversal patients, as well as rare gas incontinence, the sudden need to defecate and fecal incontinence emerging in patients who hold their stool for a long time were thought to be secondary to decreased rectal capacitance and weakening of the rectoanal inhibitory reflex.

Discussion

The lower rectum is one of the anatomical regions where surgical access is difficult due to its deep pelvic location and close proximity to the pelvic floor muscles and anal sphincter muscles in which it is partially located. After surgery for lower rectal cancers, higher rates of permanent colostomy, fecal incontinence and loregional recurrence is observed, and the anatomical localization of the lower rectum plays an important role in the occurrence of this condition. It is a fact that many physiological, psychological and social problems can be encountered during the postoperative periods in the patients who undergo permanent colostomy. Especially in young patients, the anxiety and depression due to the decline in quality of life brought by permanent colostomy requires serious and effective treatment programs [19]. For this reason, the ensuring bowel continuity in rectal cancer patients is one of the primary requests of patients, as well as rectal cancer treatment. In the history of rectal cancer surgery, we can see that peranal and perineal (anterior or posterior) accesses have been frequently used by surgeons in addition to abdominal access to ensure bowel continuity, especially in sphincter- sparing surgical procedures for the lower rectum.

Currently, intersphincteric resection techniques come to the fore as the most frequently used surgical methods in the surgical treatment of lower rectal cancers, and combined peranal access with abdominal access is often preferred [4,5,7]. In transsphincteric rectal resection techniques, surgical procedures are

performed by combining abdominal access with anterior or posterior perineal access [8,9,10,17,18]. Anterior or posterior perineal access provides surgical exposure on the surgical anal canal in the extrasphincteric plane in the ischioanal fossa , allowing the surgical treatment of pathologies localized especially in the lower rectum. The most important point to be considered to perform the proximal segmental sphincteric excision with the transsphincteric rectal resection technique is to perform the distal rectal resection after separating the fibrous ligaments between the puborectal muscle and the EAS and joining the abdominopelvic and ischioanal compartments. It should be remembered that the fibrous ligaments between the EAS and the puborectal muscle in female patients are looser than in male patients and surgical dissection at this level is easier. However, the male pateints have tight fibrous ligaments in this level, and the surgical dissection is more difficult than in females. It is a fact that transsphincteric rectal resection techniques have stayed in the back plan compared to intersphincteric rectal resection techniques in rectal cancer surgery and have higher morbidity rates compared to surgical procedures performed in the intersphincteric plane. Perineal fistula and anastomotic stricture are the main problems that may be encountered in the postoperative period in patients who have been operated with transsphincteric rectal resection techniques. In particular, the treatment of postoperative perineal fistula requires an extra effort in this period, as well as an annoying and prolonged postoperative recovery period for both of the patient and the surgeon.

The presence of the tumor cells at the radial border of the resected specimen (circumferential resection margine- CRM-positivity) is one of the most important risk factors for locoregional recurrences in rectal cancer patients [20,21,22]. From another perspective, CRM positivity is an indirect indicator of remnant tumoral cells that may have remained in the perirectal tissue after rectal resection. It is a fact that the extraluminally emerging locoregional recurrence shows subsequent luminal invasion in crm-positive rectal cancer cases who have been provided of the intestinal continuity. In patients operated with the intersphincteric dissection technique, the circumferential resection margine for the distal rectum segment below the level of the puborectal muscle is the adventitial outer surface of the lower rectum adjacent to the potential intersphincteric space where the intersphincteric dissection technique is performed. In patients operated with the transsphincteric rectal resection technique, where proximal segmental sphincteric excision can be performed, this border is formed by the outer surface of the resected external anal sphincteric segment, adjacent to the extrasphincteric dissection plane, as in the cylindrical rectal amputation technique. From this point of view, it is possible to achieved a wider circumferential resection margine with transsphincteric rectal resection surgeries performed by proximal segmental sphincter excision for lower rectal cancer. In this manner, it is possible to encounter lower CRM positivity, especially in cancers localized in the lower rectum, and to perform safer oncological operations [15,16,23].

Contraindications to the performance of ISR are the presence of fecal incontinence, T4 lesions, undifferentiated tumors, as well as tumors invading the puborectalis and the external anal sphincter [11,12]. Anal sphincteric muscular invasion is a clinical condition that occurs especially in locally advanced lower rectal cancers. Magnetic Resonance Imaging (MRI) is one of the most important imaging modalities used alongside endoanal ultrasound in determining the presence of sphincter invasion in patients with lower rectum cancer. In the MRI evaluation performed by Holzer et al. in 40

patients with lower rectal cancer: An infiltration of the sphincter ani internus was observed in 11 cases (28%), and a combined infiltration of the sphincter ani internus and externus Despite the low number of patients included and the high morbidity encountered in the postoperative period, we think that this retrospective evaluation is valuable that in terms of showing the invasive proximal sphinteric segment can be excised in the cases of lower rectal cancer with external sphincteric invasion. This study showed us that the distal anal segment is sufficient for continence despite partial decreases in maximum squeezing pressures, as predicted by Ahmed Shafik [25]. We suggest that transsphincteric rectal resection techniques should be considered as sphincter-saving surgical procedures in low rectal cancer cases with external sphincteric invasion because of intersphincteric rectal resection is contrendicated in these cases. Another expectation is that with the widespread and development of the technique, lower postoperative morbidity rates will be achieved in these cases.

Conclusion

Sphincter-sparing rectal resections performed in the transsphincteric plane have higher complication and morbidity rates compared to rectal resection techniques performed in the intersphincteric plane. However, considering the features such as performing the surgeries in an extrasphincteric dissection plan and performing proximal segmental sphincteric excision, they can be preferred as alternative sphincter-preserving methods in lower rectal cancer cases showing locally advanced and external sphincter invasion.

Declarations

Conflict of Interest: The authors have no conflicts of interest to declare.

Funding Declaration : The authors declared that this study had received no financial support.

Author contribution:

All authors contributed to the study conception and design. Operations were performed by ANY and FMH.

Histopathologic evaluation was done by NP. Material preparation, data collection and analysis were performed

by all authors. All authors read and approved the final manuscript.

References

1. Eric Rullier, Quentin Denost, Veronique Vendrely, Anne Rullier, Christope Laurent (2013) Low rectal cancer: classification and standardization of surgery. Dis Colon Rectum 56(5):560-7.

2. Stephen P Sharp, Robert Malizia, Matthew Skancke, Elliot G Arsoniadis, Ashar Ata, Steven C Stain, Brian T Valerian, Edward C Lee, Steven D Wexner (2020) A NSQIP analysis of trends in surgical outcomes for rectal cancer: What can we improve upon? Am J Surg 220(2):401-407.
3. Moore KL, Dalley AF (2014) Clinically Oriented Anatomy.7rd ed. Lippincott Williams@Wilkins.
4. Schiessel R, Karner-Hanusch J, Herbst F, Teleky B, Wunderlich M (1994) Intersphincteric resection for low rectal tumours. Br J Surg 81:1376-1378.
5. Teramoto T, Watanabe M, Kitajima M (1997) Per Anum intersphincteric rectal dissection with direct coloanal anastomosis for lower rectal cancer.The ultimate sphincter-preserving operation. Dis Colon Rectum 40:43-47.
6. Parks AG (1972) Transanal technique in low rectal anastomosis. Proc R Soc Med 65(11):975-976
7. Sylla P, Rattner DW, Delgado S, Lacy AM (2010) NOTES transanal rectal cancer resection using transanal endoscopic microsurgery and laparoscopic assistance. Surg Endosc 24:1205-1210.
8. Mason AY (1972) Trans-sphincteric exposure of the rectum. Ann R Coll Surg Eng 51:320-33.4
9. A Pena, A Hong (2003) The posterior sagittal trans-sphincteric and trans-rectal approaches. Tech Coloproctol 7(1):35-44.
10. AN Yücesoy (2018) Anatomical, surgical and clinical considerations related with operative procedures performed in combined abdominal and perineal approaches for treatment of lower rectal cancer. J Coloproctol 38 (1):82-89.
11. Constantine P Spanos (2012) Intersphincteric Resection for Low Rectal Cancer: An Overview. Int J Surg Oncol:241512.
12. Nikoletta Dimitriou, Othon Michalis, John Griniatsos (2015) Low rectal cancer: Sphincter preserving techniques-selection of patients, techniques and outcomes. World J Gastrointest Surg 7(7):55-70.
13. ST Martin, HM Heneghan, and DC Winter (2012) Systematic review of outcomes after intersphincteric resection for low rectal cancer. Br J Surg 99(5):603-12.
14. Norbert Garcia-Henriquez, Daniel J Galante, John RT Monson (2020) Selection and Outcomes in Abdominoperineal Resection. Front Oncol 10:1339.
15. Stelzner S, Hellmich G, Schubert C, Puffer E, Haroske G (2011) Short-term outcome of extra-levator abdominoperineal excision for rectal cancer. Int J Colorectal Dis 26:919-925.
16. West NP, Finan PJ, Anderin C, Lindholm J, Holm T, Quirke P (2008) Evidence of the oncologic superiority of cylindrical abdominoperineal excision for low rectal cancer. J Clin Oncol 26:3517-3522.
17. Williams NS, Murphy J, Knowles CH (2008) Anterior perineal plane for ultra-low anterior resection of the rectum (the APPEAR technique): a prospective clinical trial of a new procedure. Ann Surg 247:750-758.
18. Qu Hao, Du Yan-Fu, Li Min-Zhe, Zhang Yu-Dong, Shen Jian (2014) Laparoscopy-assisted posterior low anterior resection of rectal cancer. BMC Gastroenterol 14:158.

19. S *Ayaz-Alkaya* (2018*) Overview* of *psychosocial problems* in *individuals* with *stoma: A review* of *literature.* Int Wound J 16: 243-249.
20. Nagtegaal ID, van de velde CJH, Marijnen CAM, van KriekenJHJM, Quirke P (2005) Low rectal cancer: a call for a change of approach in abdominoperineal resection. J Clin Oncol 23:9257-64.
21. Nagtegaal ID, Quirke P (2008) What is the role for the circumferential margin in the modern treatment of rectalcancer? J Clin Oncol 26:303-12.
22. Quirke P, Durdey P, Dixon MF et al. (1986) Local recurrence of rectal adenocarcinoma due to inadequate surgical resection. Histopathological study of lateral tumour segment and surgical excision. Lancet 2: 996-9.
23. Adam IJ, Mohamdee MO, Martin IG, Scott N, Finan PJ, JohnstonD, et al.(1994) Role of circumferential margin involvement in the local recurrence of rectal cancer. Lancet 344:707–711.
24. Brigitte Holzer, Michael Urban, Nikolaus Hölbling, Wolfgang Feil, Gabriele Novi, Walter Hruby, Harald R Rosen, Rudolf Schiessel (2003) Magnetic resonance imaging predicts sphincter invasion of low rectal cancer and influences selection of operation. Surgery 133(6):656-61.
25. Shafik A. (1975) A new concept of the anatomy of the anal sphincter mechanism and the physiology of defecation. The external anal sphincter: a triple-loop system. Invest Urol 12(5):412-9.

Tables

Table 1 is available in the Supplemental Files section.

Figures

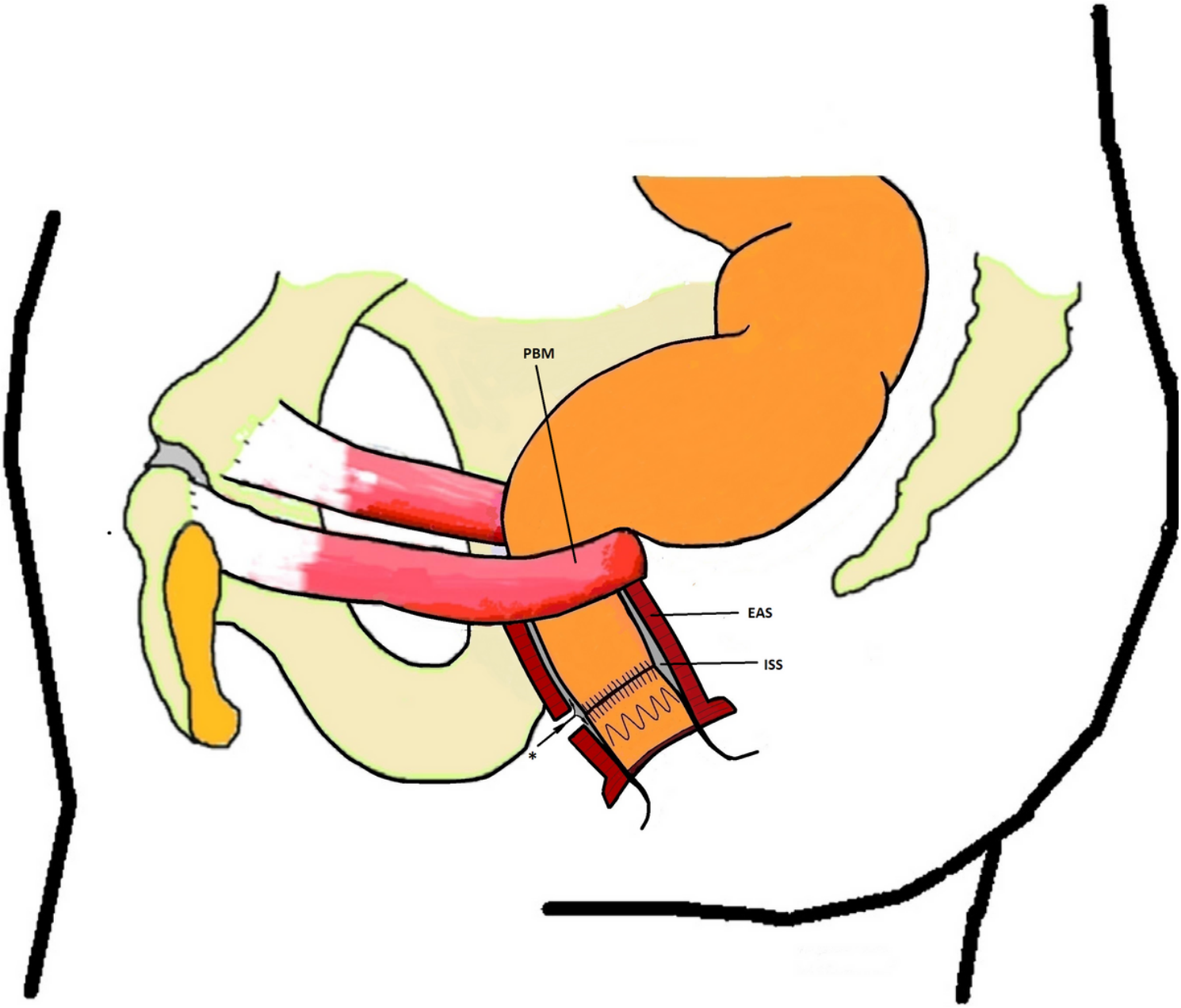

Figure 1

Illustration of the distal rectal resection and anastomosis after transitioning to the intersphincteric plane via the transsphincteric route following extrasphincteric dissection (*- transsphincteric resection line, ISS-intersphincteric space, EAS-external anal sphincteric musculature, PBM-puborectal muscle).

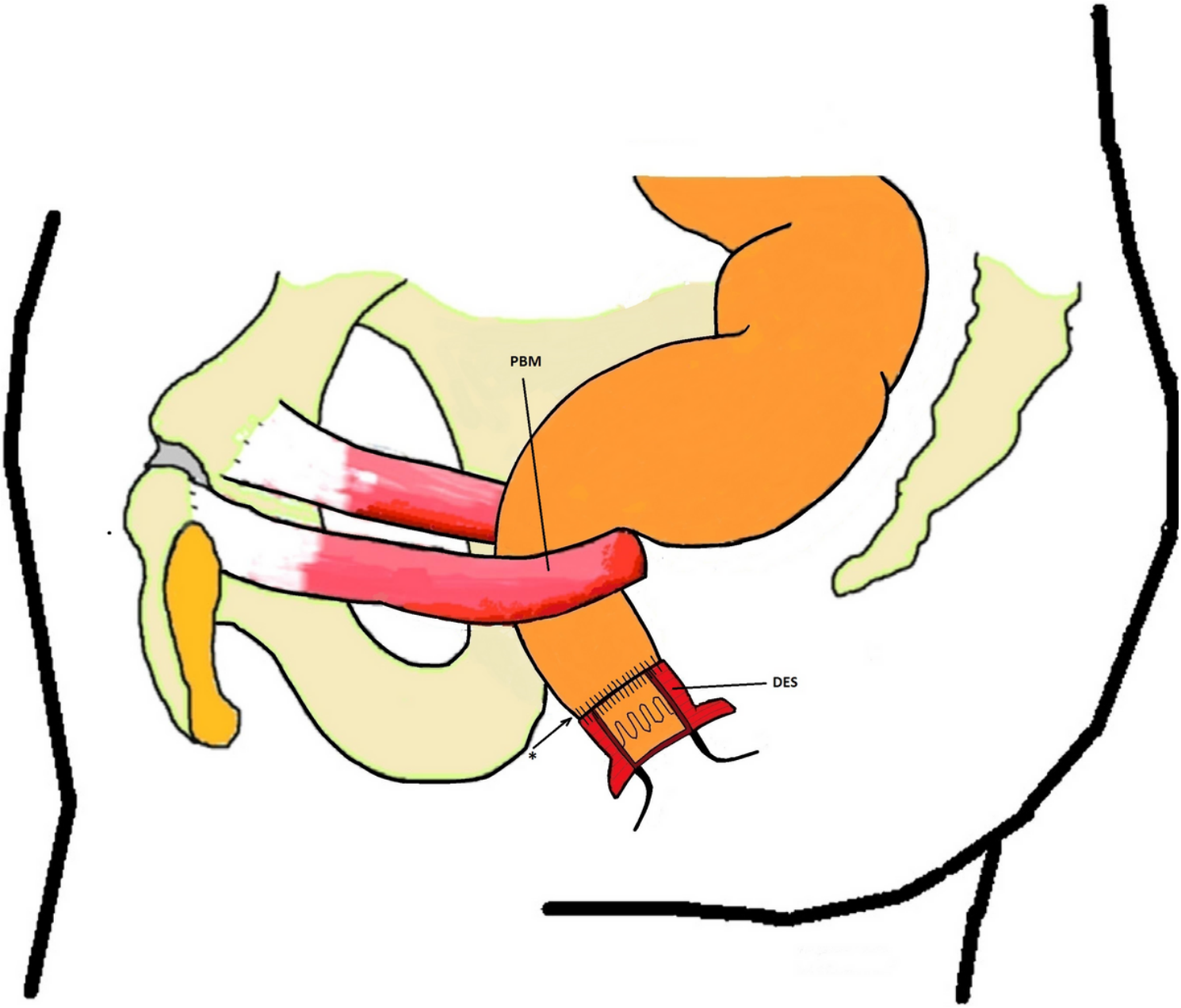

Figure 2

Illustration of the transsphincteric distal rectal resection following extrasphincteric dissection and proximal segmental sphincteric excision (*-transsphincteric resection line, DES-distal external anal sphincteric segment, PBM-puborectal muscle).

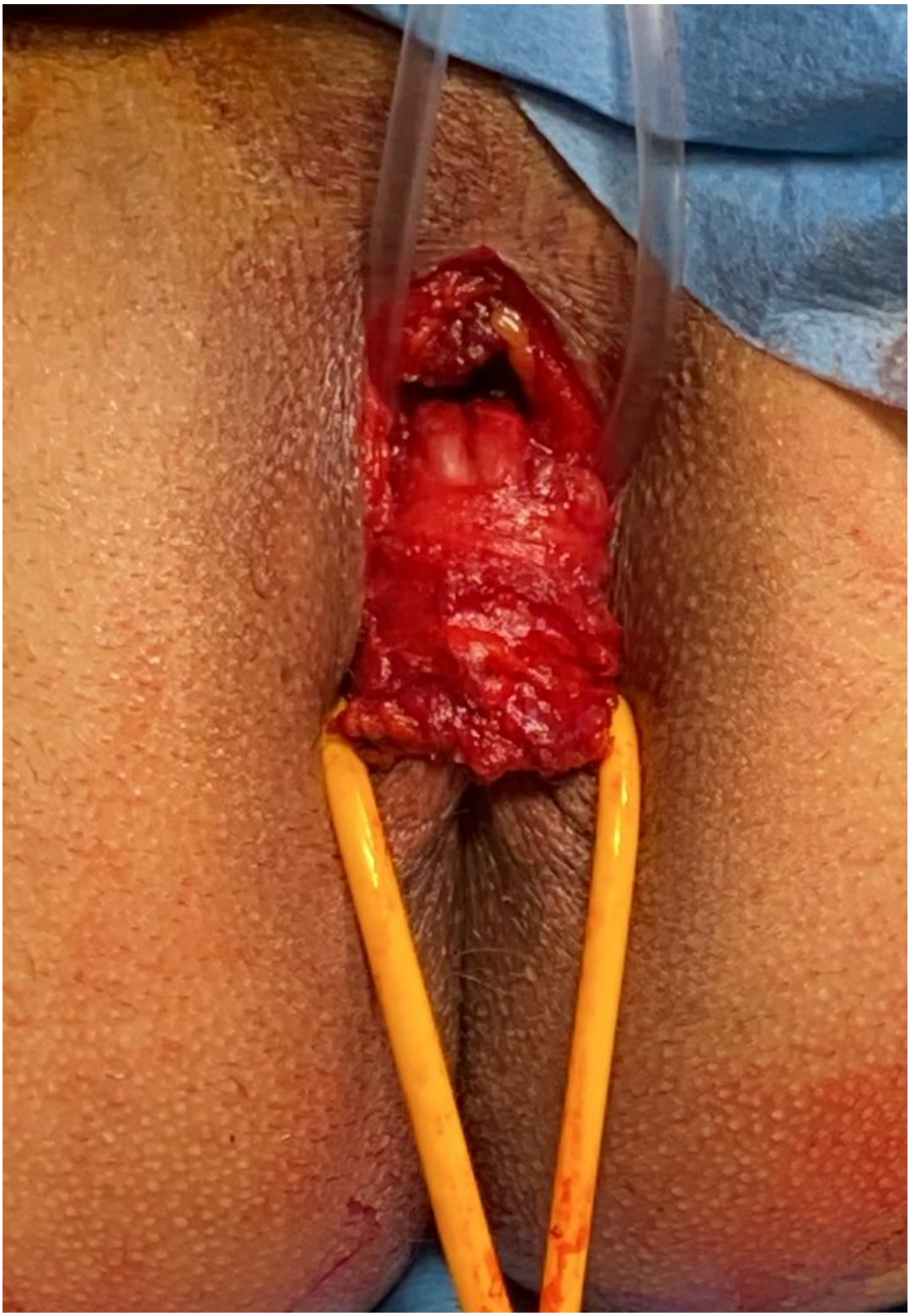

Figure 3

Extrasphincteric rectal dissection using perineal access in a male patient after the determination of the distal resection line (the clear tape is in the intrasphincteric plane and the yellow tape is in the extrasphincteric plane)

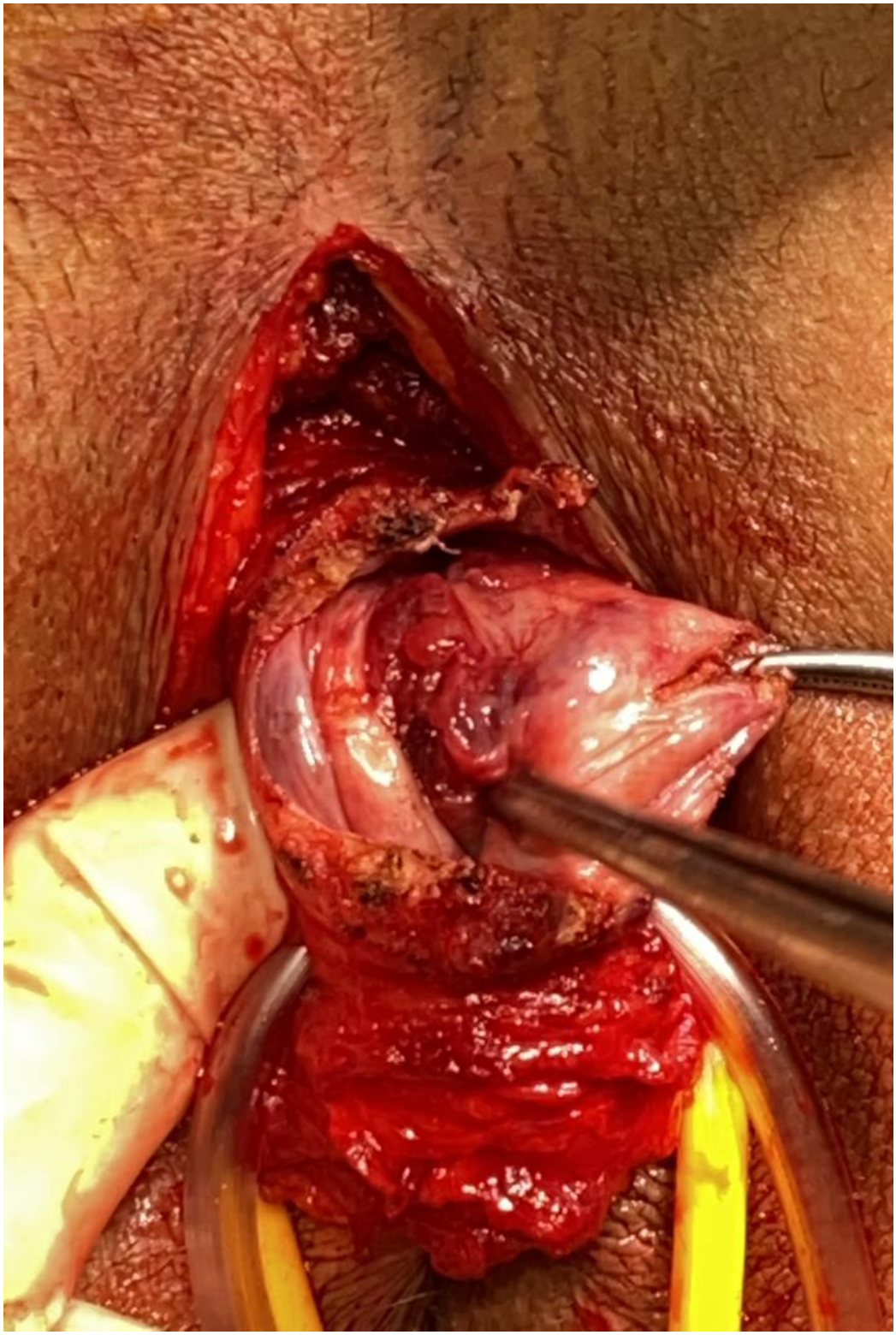

Figure 4

The intraluminal appearance of cancer extending to the lower rectum while performing distal rectal resection in the transsphincteric plane following extrasphincteric dissection with perineal access in a male patient.

Figure 5

Determination of the proximal resection line by perineal extraction of the specimen after distal rectal resection in the transsphincteric plane and release of the fibrous ligaments between the puborectal muscle and EAS in a female patient.

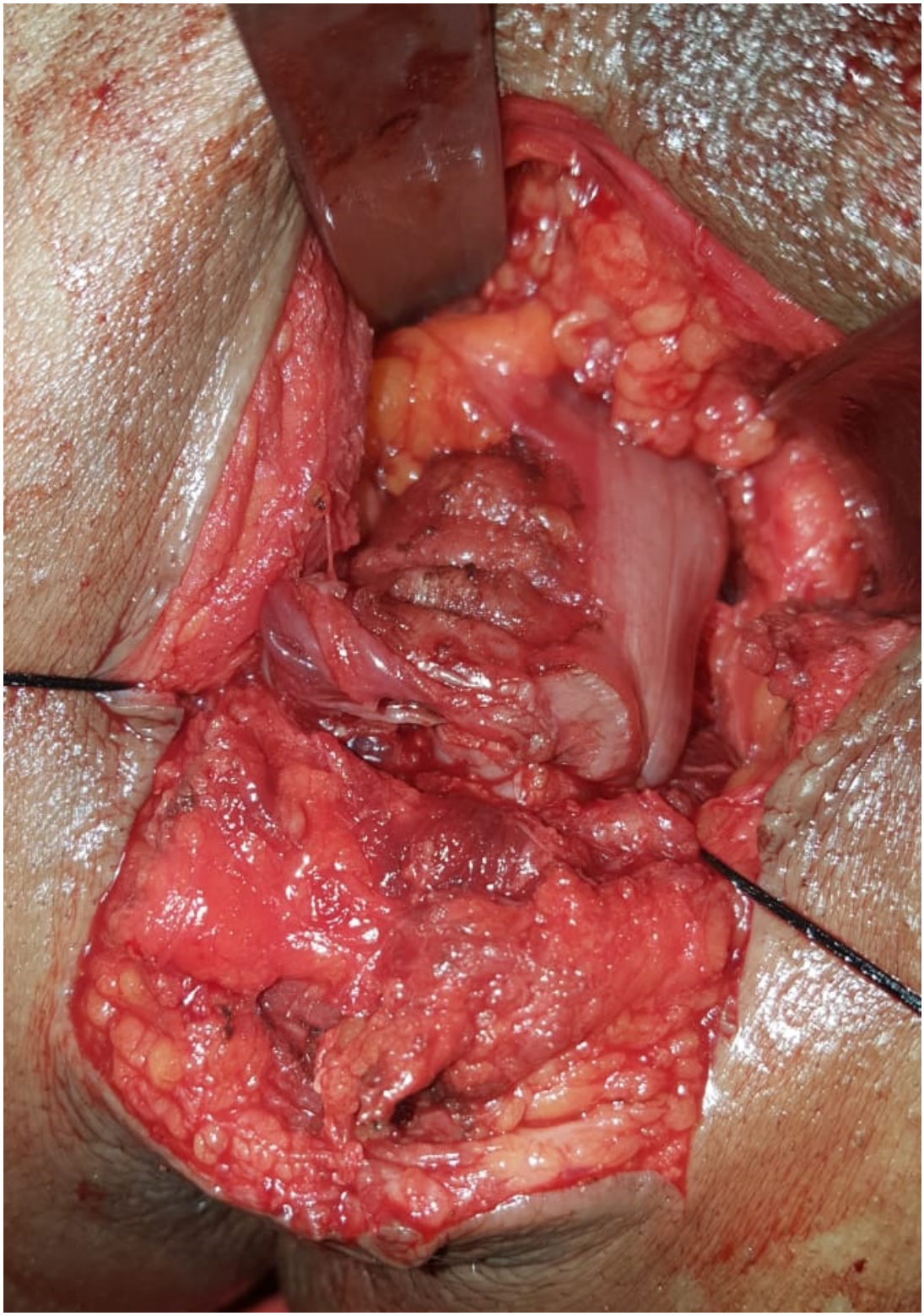

Figure 6

Perineal coloanal anastomosis following the proximal segmental sphincteric excision in the transsphincteric plane in a male patient.

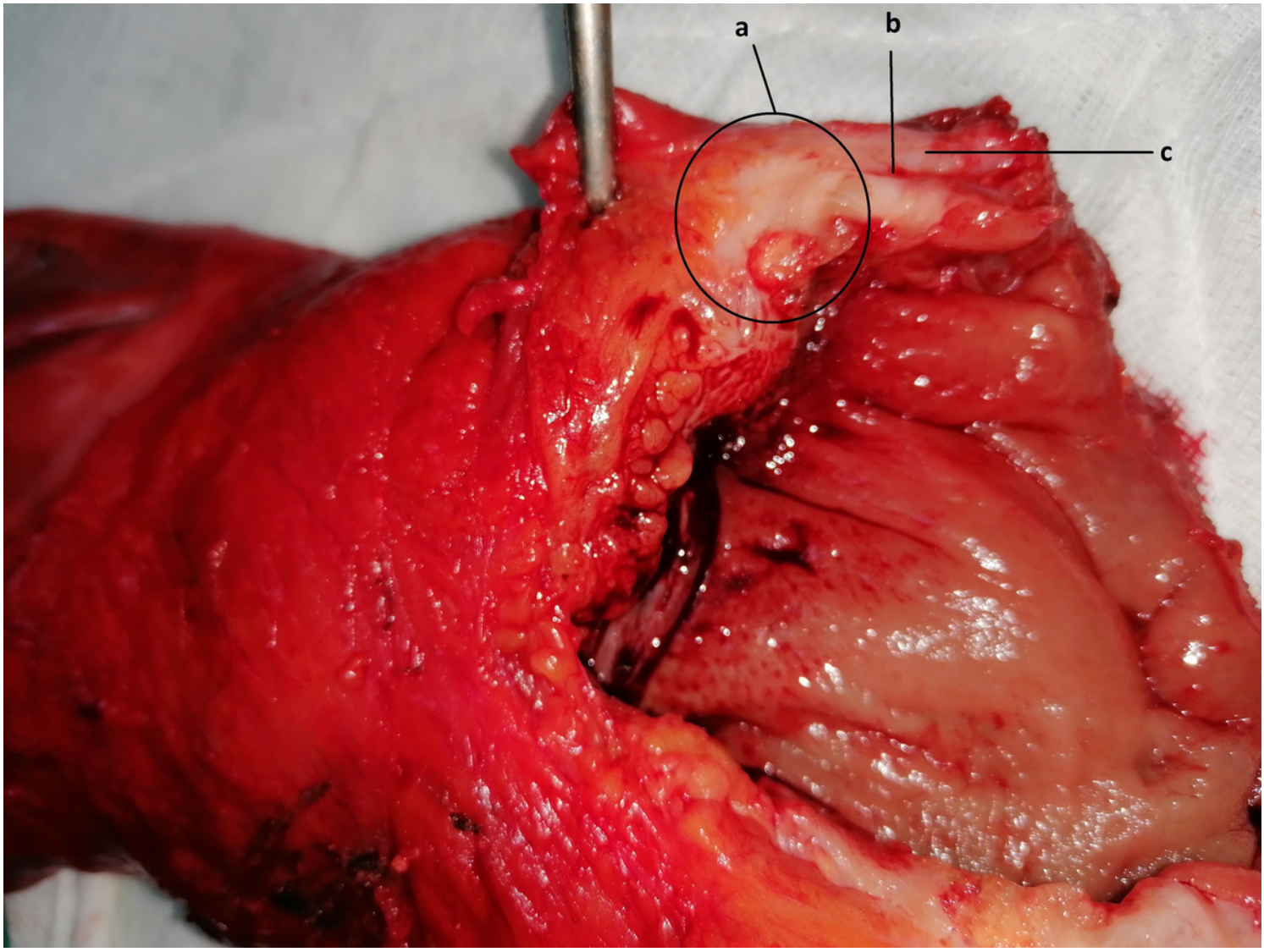

Figure 7

Postoperative demonstration of the excised proximal external anal sphincteric segment, intersphincteric plane and invasive areas in the resected sphincteric segment following transsphincteric rectal resection in a male patient's specimen (a-invasion area of the lower rectal cancer in the external anal sphincter via intersphincteric space, b-intersphincteric space, c- resected proximal external anal sphincteric segment).

Supplementary Files

This is a list of supplementary files associated with this preprint. Click to download.

- anyKopya.tif