# Predictors of root resorption in lateral incisors adjacent to maxillary impacted canines in CBCT images: A retrospective study

**Mahkameh Moshfeghi**
Department of Oral and maxillofacial radiology, School of Dentistry, Shahid Beheshti University of Medical Sciences, Tehran, Iran

**Maryam Hosseini**
DDS, School of Dentistry, Shahid Beheshti University of Medical Sciences, Tehran, Iran

**Negin Eslamiamirabadi**
DDS, MSc, School of Dental Medicine and Oral Health Sciences, McGill University, Montreal, Quebec, Canada

**Mina Biria** ( biriam@sbmu.ac.ir )
Department of Pediatric Dentistry department, School of Dentistry, Shahid Beheshti University of Medical Sciences, Tehran, Iran

**Research Article**

**Keywords:** root resorption, cone-beam computed tomography, impacted tooth, cuspid, maxilla

**Posted Date:** April 27th, 2022

**DOI:** https://doi.org/10.21203/rs.3.rs-1527122/v1

# Abstract

**Background:** Diagnosis and early treatment of impacted teeth are crucial for preventing their pathological complications such as root resorption. This study aimed to assess the predictive factors of root resorption in lateral incisors adjacent to impacted maxillary canines using cone-beam computed tomography.

**Methods:** In this retrospective descriptive-analytic study, 150 samples of impacted canines from 138 CBCT images were collected from the files of 12–35-year-old patients. The association between the severity and location of root resorption in lateral incisors adjacent to impacted maxillary canines and the patients' age, sex, impacted canine's angulation, position and follicle size was evaluated. Position and angulation of the impacted teeth were measured using the OnDemand3Dä software. Kruskal Wallis test, Fisher's exact test, Mann-Whitney test, Kolmogorov-Smirnov test, Spearman's rank correlation coefficient and multinomial logistic regression were used for data analysis.

**Results:** The probability of resorption in the middle-third of the roots of lateral incisors decreased by 20% with each millimeter of increase in the distance between the impacted canines' cusp tip from the occlusal plane (P=0.009). There was a significant association between the severity of lateral incisors' root resorption and sex; root resorption was significantly more severe in females (P=0.029). No significant differences were observed between the lateral incisors' root resorption and age, sagittal and transverse positions of the impacted canine, its follicle size, and the angle between the long axis of canines with the midline, occlusal plane and the long axis of lateral incisors (P>0.05).

**Conclusion:** Among the evaluated variables, the vertical position of the impacted canine influenced the location of the lateral incisors' root resorption. The severity of root resorption was higher in females.


# Introduction

The maxillary canine tooth has the longest and most tortuous eruption path among permanent teeth. Its mineralization commences in the fourth or fifth months of fetal age and its eruption occurs at 12 years of age; that is, 6 years after the eruption of the mandibular 1st molar, which mineralizes at the same time as the maxillary canine (1).

Impaction of a permanent tooth usually occurs due to the tooth's failure to move and reach its correct position in the dental arch during the eruption period (2, 3). Maxillary canine impaction is the second most common eruption failure, affecting 1–3% of the population (4), and can lead to pathological problems (2, 5). The most important irreversible adverse effect of maxillary canine impaction is the root resorption of its adjacent teeth, especially the lateral incisor, which can lead to lateral incisor tooth loss (6). To date, several risk factors have been identified with regards to the root resorption of lateral incisors, while its causal factor remains unknown (1). These risk factors are either local or systemic. Local risk factors include lack of space in the dental arch, trauma, ankylosis of primary teeth, ectopic tooth bud, inflammation, pathologic lesions, and mesial movement of the adjacent teeth, all of which may lead to

premature loss of these teeth. Systemic risk factors include malnutrition, anemia, rickets, vitamin D deficiency, endocrine diseases, syndromes such as turner (7), and specific infections such as syphilis and tuberculosis(8). Genetic factors can also have a role in lateral incisor root resorption (8).

Early diagnosis of root resorption may not be possible as it is often asymptomatic; even though resorption can reach the dental pulp, no clinical symptoms may be evident. Consequently, the lesion is usually diagnosed when the tooth needs to be extracted (2, 4). Due to the rapid progress of root resorption of teeth adjacent to impaction, identifying teeth with a high risk of root resorption is essential for early intervention and treatment (5). Knowledge regarding the effects of maxillary canine impaction on the adjacent lateral root resorption (ALRR) and awareness of root resorption risk factors can provide efficient clinical guidance for clinicians to determine the prognosis, treatment planning and the appropriate timing for intervention (9).

Two-dimensional imaging approaches such as periapical, panoramic and occlusal radiographs can be helpful with the diagnosis and follow up of tooth eruption conditions and evaluating treatment results (8). However, they have limitations such as dimensional distortions and superimpositions, which may render them inadequate for diagnosis and treatment in most cases (8). Root resorption can be immediately identified using three-dimensional imaging techniques such as cone beam computed tomography (CBCT)(1). CBCT radiographs have higher sensitivity and accuracy in the diagnosis of root resorption compared to two-dimensional radiographic techniques (6). Studies have indicated that resorption of roots with a diameter of less than 0.6mm and a depth of less than 0.3mm cannot be easily identified in two-dimensional radiographic images, especially if the impacted tooth is buccally positioned (1). Moreover, CBCTs can provide three-dimensional details regarding the position of the impacted maxillary canine (IMC) and the adjacent lateral incisor, their position towards the floor of the nasal foramina, maxillary sinus and mandibular canal, and these details can be observed from different angles (8, 10, 11).

The association between ALRR and some variables including the position and angle of the impacted tooth, patient's sex and age, the distance between IMC and the midline and the occlusal plane, as well as the IMC's follicle size has been evaluated in previous studies (2, 3, 12). However, none of the previously conducted studies have evaluated all these variables in a single population. Moreover, no study has yet been conducted that would evaluate all these variables in a single Iranian population with an adequate sample size.

This study aimed to evaluate the association between the abovementioned factors and ALRR in a sample of the Iranian population. The results of this study can help clinicians to make early interventions and appropriate treatment plans to prevent ALRR in patients with IMC.

# Methods And Materials

A retrospective descriptive-analytic design was chosen for this study. The sample size was calculated as 150 according to the formula ($n = \frac{z^2_{1-\frac{\alpha}{2}} \times P \times (1-P)}{d^2}$) with a confidence interval of 95% ($z_{1-\frac{\alpha}{2}}$) =1.96 and a P (impaction prevalence) = 0.4 (13) and an estimation error of d = 0.08. CBCT images of patients were studied using non-probability convenience sampling while conserving confidentiality and anonymity. The study was conducted after its experimental protocol being approved by the committee for ethics in research, school of dentistry, Shahid Beheshti University of Medical Sciences (IR.SBMU.DRC.REC.1398.198).

Data was collected using the documents in the CBCT archive of the department of oral and maxillofacial radiology, Faculty of Dentistry, Shahid Beheshti Medical University, Tehran, Iran, from Sep 2018 to May 2020. Patients between 12–35 years of age who had taken CBCT images due to different diagnostic reasons and had at least one IMC adjacent to a lateral incisor were included in this study. The presence of a maxillary first molar to determine the occlusal plane was among the inclusion criteria. The exclusion criteria included patients under orthodontic treatment, having a pulp-treated lateral incisor adjacent to IMC, having a craniofacial anomaly, hereditary syndromes, systemic diseases that might affect tooth and bone growth and formation, and low-quality radiographic images.

CBCT images of 138 patients (including 150 MICs), taken with standard resolution and field of view (FOV) of 12×8mm with a voltage of 110 kVp obtained through the NewTom VGI device (QR, Verona, Italy) were evaluated in this study. Data were collected through patient records and observation and measurement of their CBCT images using the OnDemand3D™ software. Observation and measurement of CBCT images were conducted by a senior dental student at Shahid Beheshti Dental School. She had received specific training for observing, diagnosis, and analysis of CBCT images, under the supervision of an experienced associate professor of the oral and maxillofacial radiology department. The reliability of our data was tested on 30 samples with an interval of 21 days. Inter-observer and intra-observer agreements were evaluated to ensure the reliability of the findings.

The Kurol-Ericson scale was used for measuring the severity of ALRR. This scale has 4 categories, from “no resorption” to “severe resorption” (Fig. 1) (13).

The angle between the long axis of IMC and the lateral incisor (CAL) and also the angle between the long axis of IMC and the midline (CAM) were measured in the coronal plane of the CBCT images using the tools of the software (Fig. 2).

The software enabled the evaluation of 3D images in coronal and sagittal planes. The transverse and vertical position and the distance between the cusp tip and apex of IMC and the midline were recorded in the coronal plane. The angle between the long axis of IMC and the occlusal plane (CAO) was measured in the sagittal plane using the software (Fig. 3).

Using the images in the axial view, the size of the canine dental follicle and the severity of ALRR were evaluated. The severity of root resorption was also evident in sagittal images which helped to ensure the

accuracy of the diagnosis (Fig. 4).

# Data analysis

Kolmogorov-Smirnov test was used to evaluate the normal distribution of continuous data, and the intraclass correlation coefficient (ICC) was used to evaluate data reliability. The reliability of continuous variables was evaluated using ICC. Reliability scores higher than $n > 0.75$ were considered excellent agreement according to Rosner's division (14). Kappa coefficient was used to evaluate the reliability of categorical data, kappa $\geq 0.6$ was considered acceptable (15). To evaluate the effect of the independent variables on the location of ALRR, Fisher's exact test and multinomial logistic regression were used. Kruskal Wallis test, Mann-Whitney test and Spearman's rank correlation coefficient were used to evaluate the association of continuous and categorical variables with the severity of root resorption. Type 1 error was set at $\alpha = 0.05$, so p- value $< 0.05$ was considered significant. The SPSS software™ version 20 was used for statistical analysis.

# Results

### Descriptive statistics

In this retrospective study, 150 CBCT images of 112 female (74.7%) and 38 male (25.3%) patients with an average age of 24.16 ± 8.00 years were evaluated. 24 IMCs (16%) were labially and 126 (84%) were palatally positioned. In 23 patients (15.3%), the vertical position of the IMC towards the adjacent lateral incisor roots was in the apical third, in 83 samples (55.3%) in the middle third and in 44 patients (29.3%) in the incisal third. Degrees of 1,2,3 and 4 of ALRR had an incidence of 109 (72.9%), 20 (13.1%), 10 (6.7%) and 11 (7.3%), respectively. With regards to the resorption location, in 18 patients (12%) resorption was located in the apical third, in 22 patients (14.7%) in the middle third, and only in one patient (0.7%) in the incisal third of the root.

### Inter-observer and Intra-observer agreement:

Kolmogorov-Smirnov test revealed the normal distribution of our continuous variables ($p > 0.05$). Therefore, the ICC reliability coefficient was used to evaluate the reproducibility of the data. All ICC reliability coefficients were more than 0.75, which was reported excellent agreement according to Rosner's division (14). For all five variables of sagittal, vertical and transverse canine position, severity and location of resorption, the kappa coefficient was > 0.8.

### Sex, age and follicular size

The results indicated higher severity of ALRR in females (Table 1). There was no significant association between the location of ALRR and the patients' sex (Table 2).

In addition, no significant association was observed between the variables of age and canine follicle size with the severity and location of ALRR ($P > 0.05$).

### Transverse, sagittal and vertical position

There was no significant association between the severity of ALRR and transverse, sagittal and vertical position of IMC (Table 1). In addition, no significant relationship was found between transverse, sagittal and vertical position of IMC and the location of ALRR (Table 2).

### Impacted canine distance to the midline and occlusal plane

No significant relationship was observed between the severity of ALRR and the distance from the cusp tip and apex of IMC to the occlusal plane and to the midline ($P > 0.05$).

The distance between the canine cusp tip and the occlusal plane was significantly associated with the location of ALRR ($P = 0.009$). In other words, each millimeter of increase in the distance between the cusp tip of IMC and the occlusal plane decreased the probability of resorption in the middle third of the lateral incisor's root by 20% (OR = 0.777, 95%CI: (0.643–0.937)).

Evaluation of the association between the distance of the apex and the cusp tip of IMC from the midline and the location of ALRR indicated no significant statistical association ($P > 0.05$).

### Impacted canine angulation to the midline, occlusal plane and lateral tooth long axis

No significant association was observed between the severity of ALRR and the angle between the long axis of IMC and the lateral incisor (CAL), the occlusal plane (CAO), and the midline (CAM) ($P > 0.05$). In addition, no relationship was found between the location of ALRR and the above-mentioned angles.

Table 1
Distribution of degrees of root resorption severity according to impacted canine position and sex (Mann-Whitney U test)

| | | Resorption degree | | | | Total | P-value |
|---|---|---|---|---|---|---|---|
| | | 1 | 2 | 3 | 4 | | |
| Vertical position | Apical | 17 (73.9%) | 3 (13.0%) | 1(4.3%) | 2(8.7%) | 23 | 0.29 |
| | Middle | 56(67.5%) | 14(16.9%) | 7(8.4%)7 | 6(7.2%) | 83 | |
| | Occlusal | 36(81.8%) | 3(6.8%) | 2(4.5%) | 3(6.8%) | 44 | |
| Sagittal position | Labial | 16(66.7%) | 3(12.5%) | 3(12.5%) | 2(8.3%) | 24 | 0.43 |
| | Palatal | 93 (73.8%) | 17 (13.5%) | 7 (5.6%) | 9 (7.1%) | 126 | |
| Transverse position | Mesial | 84 (71.2%) | 16 (13.6%) | 9 (7.6%) | 9 (7.6%) | 118 | 0.42 |
| | Distal | 25 (78.1%) | 4 (12.5%) | 1 (3.1%) | 2 (6.3%) | 32 | |
| sex | Female | 76 (67.8%) | 18 (16.2%) | 9 (8.1%) | 9 (8.1%) | 112 | 0.03 |
| | Male | 33 (86.8%) | 2 (5.3%) | 1 (2.6%) | 2 (5.3%) | 38 | |

Table 2
Distribution of location of root resorption according to the impacted canine position and sex (Fisher's exact test)

| | | Resorption location | | | Total | P-value |
|---|---|---|---|---|---|---|
| | | No resorption | Apical | Middle | | |
| Vertical position | Apical | 17 (77.3%) | 0 (0%) | 5 (22.7%) | 22 | 0.09 |
| | Middle | 56 (67.5%) | 13 (15.7%) | 14 (16.9%) | 83 | |
| | Incisal | 36(81.8%) | 5(11.4%) | 3(6.8%) | 44 | |
| Sagittal position | Labial | 16 (66.7%) | 5 (20.8%) | 3 (12.5%) | 24 | 0.36 |
| | Palatal | 93 (74.4%) | 13 (10.4%) | 19 (15.2%) | 125 | |
| Transverse position | Mesial | 84 (71.8%) | 16 (13.7%) | 17 (14.5%) | 117 | 0.58 |
| | Distal | 25 (78.1%) | 2 (6.3%) | 5 (15.2%) | 32 | |
| Sex | Female | 76 (68.4%) | 16 (14.5%) | 19 (17.3%) | 111 | 0.08 |
| | Male | 33 (86.8%) | 2 (5.3%) | 3 (7.9%) | 38 | |

*Since root resorption in the incisal one-third was observed in only one sample, this case was excluded and the number of samples was considered 149 for this table.

# Discussion

Early diagnosis of maxillary canine impaction and its associated factors is crucial for preventing its consequent adverse effects. Since these risk factors have not been specifically evaluated in the Iranian population, this study aimed to evaluate all these variables in a sample of Iranian patients. Awareness of risk factors related to root resorption of the lateral tooth adjacent to IMC can help dentists and dental specialists choose the appropriate treatment plan and make early interventions.

In our study, CBCT images of 138 patients with 150 MICs were evaluated; 12 patients had bilateral maxillary canine impaction. The female to male ratio was 3:1. Studies of Kanavakis (2015), Dagsuyu (2017), and Andersen et al (2021) were in line with this study, indicating that the impaction of maxillary canine is more common in females (3, 16, 17). It is speculated that variations in genetics or craniofacial growth patterns between males and females may be the cause for the aforementioned difference (2, 17). However, female patients being more attentive to aesthetics and more willing to receive orthodontic treatment can also be the reason for this difference (12, 18).

Alqerban et al's study in 2016 showed that ALRR due to impaction is more common in females (4). Considering that in our study, the number of females was higher than males, a comparison cannot be made between the two sexes. Nevertheless, since impacted canines are more prevalent among females than males, ALRR might also be more prevalent among females (4).

According to Alqerban in 2016, Guarnieri in 2016, and Ucar et al in 2017, no significant association was observed between sex and the location of root resorption, which is in accordance with our study (4, 11, 19). Moreover, these studies revealed that in cases with ALRR, the severity of resorption in females was significantly higher, which is in line with our results (1).

Since the delayed eruption of maxillary canines is usually noted after the age of 11(20) and the probability of root resorption in teeth adjacent to an impacted tooth increases with time (1), the age range of our samples was limited to 12–35 years. In accordance with studies of Dogramaci (2015), Rafflenbeul (2019), and Kalavritinos (2020), our study showed no association between the patients' age and the severity and location of ALRR (5, 6, 21).

In our study, most IMCs were palatally positioned (84%), which is in accordance with Brosson (2020) and Hadler-Olsen's (2015) studies (22, 23). Buccal impaction is usually related to insufficient space in the dental arch, while palatal impaction may occur even with adequate space (12).

In this study, the highest prevalence of the vertical position of IMC towards the adjacent lateral incisor was in the middle third (55.3%), incisal third (29.3%) and apical third (15.3%), respectively. These results are in accordance with the studies of Rafflenbeul (2019) and Andresen (2021) (5, 16).

In the 150 samples evaluated in this study, 109 (72.9%) of adjacent lateral incisors had no root resorption. This is in accordance with Liu et al's study in 2008 in which 210 impacted canines were evaluated and the prevalence of maxillary lateral root resorption was 27.2%(24). Moreover, in the present study, among the teeth with root resorption, 20 (13.1%) showed slight, 10 (6.7%) moderate and 11 (7.3%) severe root resorption. Strbac et al's study in 2012 obtained similar results (25).

In accordance with the studies of Bin (2015), Guarnieri (2016), and Rafflenbeul (2019), in our study, the rate of ALRR was higher in the middle (14.7%), apical (12%), and incisal third (0.7%), respectively (5, 19, 26). Similar to our findings, no significant association was observed between the vertical position of IMC and the severity and location of ALRR in the studies of Cuminetti (2017), Kalavritinos (2020) and Bin (2015) (1, 6, 26).

The results of the present study showed that the IMC's follicle size was not significantly associated with the severity and location of ALRR. This finding is in accordance with the results of Cuminetti (2017), Rafflenbeul (2019) and Kalavritinos (2020)'s studies (1, 5, 6). Nevertheless, Chaushu et al's study in 2015 showed a significant association between IMC's follicle size and severe ALRR (27). This difference could be due to the fact that in our study, all resorption degrees were reported, from no to severe, unlike the abovementioned study in which only severe degrees were reported.

Ucar et al (2017) reported that neither the transverse position of IMC nor the distance between the cusp tip and apex of IMC from the midline were associated with the severity and location of ALRR (11) which is in line with the findings of the present study.

Cuminetti et al (2017) showed that the mean value of CAM was lower in patients with severe ALRR (1). However, similar to our study, Cuminetti et al found no significant association between the transverse position of IMC and ALRR (1).

Our study showed no significant association between the sagittal position of IMC and the severity and location of ALRR. This finding is in line with the studies of Jawad (2016), Ucar (2017) and Hadler-Olsen (2019)(11, 23, 28). The findings of Ardakani et al's study is however at odds with our findings; their study showed that the buccal positioning of IMC can increase the severity of ALRR (12). This difference can be due to Ardakani et al's smaller sample size (40 samples) or their sample's different age range (11–45 years).

The present study showed that an increase in the distance of the canine cusp tip from the occlusal plane decreases the probability of ALRR in the middle third of the root. Our team found no previous studies evaluating the relationship between the vertical position of IMC and the location of ALRR.

Our study showed no significant association between the severity and location of ALRR and CAL, CAO, CAM. This finding is in accordance with the studies of Hadler-Olsen (2015), Ucar (2017) and Ardakani (2021) (11, 12, 23). Moreover, Guarnieri et al's study in 2016 showed no significant association between ALRR and CAM and CAO (18). However, they reported that if the angle between the long axis of IMC and the adjacent lateral incisor is higher than 54°, the probability of ALRR exceeds by 61% (19).

According to the results of our study, the distance between the cusp tip of the IMC and the occlusal plane can be used as an index for early detection and prevention of ALRR, especially in female patients with IMC. If this distance is high in a patient, periodic examinations may be required to prevent the impaction conditions from deteriorating and to reduce the risk of ALRR to the minimum.

This study had limitations. Evaluating the changes in the severity of ALRR due to IMC in one person during the time would have led to more reliable findings. Due to the hazards of X-ray exposure in several imagings, this study could not be conducted with a longitudinal approach (10, 11).

# Conclusion

The main findings of this retrospective study were as follows:

- The prevalence ratio of maxillary canine impaction in palatal position compared to the buccal position was 5:1.
- The severity of adjacent lateral root resorption had a significant relationship with sex and was higher in females.
- The distance between the impacted canine cusp tip and the occlusal plane was associated with the location of adjacent lateral root resorption. An increase in this distance decreased the probability of resorption in the middle third of the lateral incisor.

# Abbreviations

CBCT: Cone beam computed tomography

IMC: Impacted maxillary canine

ALRR: Adjacent lateral incisor root resorption

CAL: The angle between the long axis of canine and long axis of lateral incisor

CAO: The angle between the long axis of canine and occlusal plane

CAM: The angle between the long axis of canine and midline

# Declarations

**Ethics approval and consent to practice:**

This was a retrospective cross-sectional study, and its design was in accordance with the Helsinki Declaration of Human Rights and its subsequent revisions. The study was conducted in accordance with the STROBE statement, after its experimental protocol being approved by the committee for ethics in research, school of dentistry, Shahid Beheshti University of Medical Sciences (IR.SBMU.DRC.REC.1398.198).

**Consent for publication:**

Not applicable

**Availability of data and materials:**

The datasets used and analyzed during the current study are available from the corresponding author on reasonable request.

**Competing interests:**

The authors declare that they have no competing interests.

**Funding:**

Not applicable

**Authors' contributions:**

MM and MH conceptualized and designed the methodology. NE and MB interpreted the data and were major contributors in writing the manuscript. All authors read and approved the final manuscript.

**Acknowledgements:**

Not applicable

# References

1. Cuminetti F, Boutin F, Frapier L. Predictive factors for resorption of teeth adjacent to impacted maxillary canines. Int Orthod. 2017;15(1):54–68.
2. Ali IH, Al-Turaihi BA, Mohammed LK, Alam MK. Root Resorption of Teeth Adjacent to Untreated Impacted Maxillary Canines: A CBCT Study. Biomed Res Int. 2021:6635575.
3. Dağsuyu İ M, Okşayan R, Kahraman F, Aydın M, Bayrakdar İ, Uğurlu M. The Relationship between Dental Follicle Width and Maxillary Impacted Canines' Descriptive and Resorptive Features Using Cone-Beam Computed Tomography. Biomed Res Int. 2017:2938691.
4. Alqerban A, Jacobs R, Fieuws S, Willems G. Predictors of root resorption associated with maxillary canine impaction in panoramic images. Eur J Orthod. 2016;38(3):292–9.
5. Rafflenbeul F, Gros CI, Lefebvre F, Bahi-Gross S, Maizeray R, Bolender Y. Prevalence and risk factors of root resorption of adjacent teeth in maxillary canine impaction, among untreated children and adolescents. Eur J Orthod. 2019;41(5):447–53.
6. Kalavritinos M, Benetou V, Bitsanis E, Sanoudos M, Alexiou K, Tsiklakis K, et al. Incidence of incisor root resorption associated with the position of the impacted maxillary canines: A cone-beam computed tomographic study. Am J Othord Dentofacial Orthop. 2020;157(1):73–9.
7. Russell KA. Orthodontic treatment for patients with Turner syndrome. Am J Othord Dentofacial Orthop. 2001;120(3):314–22.
8. Sarica I, Derindag G, Kurtuldu E, Naralan ME, Caglayan F. A retrospective study: Do all impacted teeth cause pathology? Niger J Clin Pract. 2019;22(4):527–33.
9. Patel S, Saberi N. The ins and outs of root resorption. Br Dent J. 2018;224(9):691–9.
10. Schroder AGD, Guariza-Filho O, de Araujo CM, Ruellas AC, Tanaka OM, Porporatti AL. To what extent are impacted canines associated with root resorption of the adjacent tooth?: A systematic review with meta-analysis. J Am Dent Assoc. 2018;149(9):765 – 77.e8.
11. Ucar FI, Celebi AA, Tan E, Topcuoğlu T, Sekerci AE. Effects of impacted maxillary canines on root resorption of lateral incisors: A cone beam computed tomography study. J Orofac Orthop. 2017;78(3):233–40.
12. Ardakani MP, Nabavizadeh A, Iranmanesh F, Hosseini J, Nakhaei MJPBeOeCI. Relationship of angulation of maxillary impacted canines with maxillary lateral incisor root resorption. Oral Radiol. 2021;21.
13. Dağsuyu İ M, Kahraman F, Okşayan R. Three-dimensional evaluation of angular, linear, and resorption features of maxillary impacted canines on cone-beam computed tomography. Oral Radiol. 2018;34(1):66–72.

14. Rosner B. On the estimation and testing of interclass correlations: the general case of multiple replicates for each variable. Am J Epidemiol. 1982;116(4):722–30.
15. Seigel DG, Podgo MJ, Remaley NA. Acceptable values of kappa for comparison of two groups. Am J Epidemiol. 1992;135(5):571–8.
16. Andresen AKH, Jonsson MV, Sulo G, Thelen DS, Shi XQ. Radiographic features in 2D imaging as predictors for justified CBCT examinations of canine-induced root resorption. Dentomaxillofac Radiol. 2022;51(1):20210165.
17. Kanavakis G, Curran KM, Wiseman KC, Barone NP, Finkelman MD, Srinivasan S, et al. Evaluation of crown-root angulation of lateral incisors adjacent to palatally impacted canines. Prog Orthod. 2015;16:4.
18. Moshfeghi M, Rahimi H, Rahimi H, Nouri M, Bagheban AA. Predicting mandibular growth increment on the basis of cervical vertebral dimensions in Iranian girls. Prog Orthod. 2013;14(1):3.
19. Guarnieri R, Cavallini C, Vernucci R, Vichi M, Leonardi R, Barbato E. Impacted maxillary canines and root resorption of adjacent teeth: A retrospective observational study. Med Oral Patol Oral Cir Bucal. 2016;21(6):e743-e50.
20. Ericson S, Kurol J. Radiographic assessment of maxillary canine eruption in children with clinical signs of eruption disturbance. Eur J Orthod. 1986;8(3):133–40.
21. Doğramaci EJ, Sherriff M, Rossi-Fedele G, McDonald F. Location and severity of root resorption related to impacted maxillary canines: a cone beam computed tomography (CBCT) evaluation. Aust Orthod J. 2015;31(1):49–58.
22. Brorsson Y, Naoumova J. Delayed diagnosis of displaced and impacted canines - a prospective longitudinal study. Acta Odont Scand. 2020;78(3):165–72.
23. Hadler-Olsen S, Pirttiniemi P, Kerosuo H, Bolstad Limchaichana N, Pesonen P, Kallio-Pulkkinen S, et al. Root resorptions related to ectopic and normal eruption of maxillary canine teeth - A 3D study. Acta Odont Scand. 2015;73(8):609–15.
24. Liu DG, Zhang WL, Zhang ZY, Wu YT, Ma XC. Localization of impacted maxillary canines and observation of adjacent incisor resorption with cone-beam computed tomography. Oral Surg Oral Med Oral Pathol Oral Radiol Endod. 2008;105(1):91–8.
25. Strbac GD, Foltin A, Gahleitner A, Bantleon HP, Watzek G, Bernhart T. The prevalence of root resorption of maxillary incisors caused by impacted maxillary canines. Clin Oral Investig. 2013;17(2):553–64.
26. Yan B, Sun Z, Fields H, Wang L. [Maxillary canine impaction increases root resorption risk of adjacent teeth: A problem of physical proximity]. Orthod Fr. 2015;86(2):169–79.
27. Chaushu S, Kaczor-Urbanowicz K, Zadurska M, Becker A. Predisposing factors for severe incisor root resorption associated with impacted maxillary canines. Am J Orthod Dentofacial Orthop. 2015;147(1):52–60.
28. Jawad Z, Carmichael F, Houghton N, Bates C. A review of cone beam computed tomography for the diagnosis of root resorption associated with impacted canines, introducing an innovative root

resorption scale. Oral Surg Oral Med Oral Pathol Oral Radiol. 2016;122(6):765–71.

# Figures

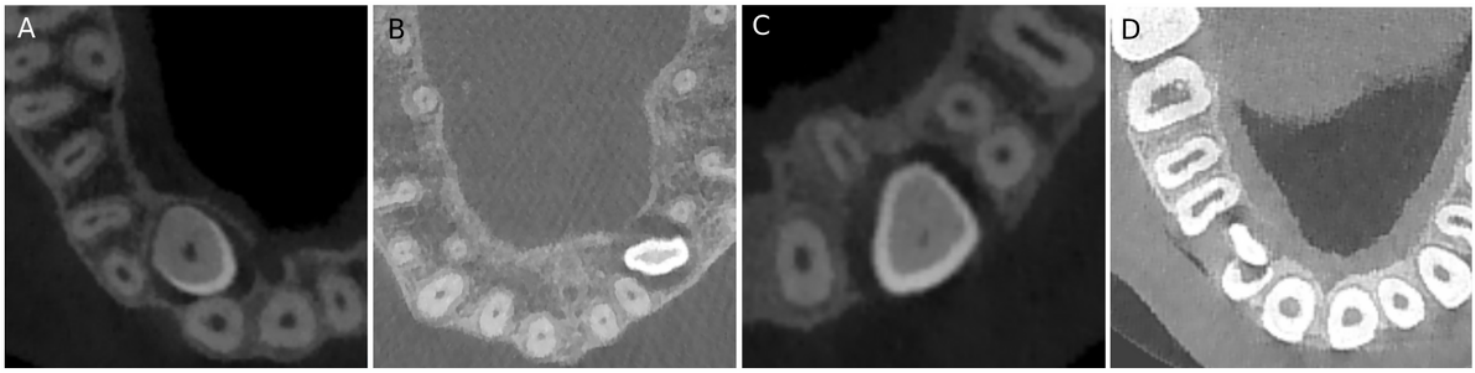


**Figure 1**

Axial view of root resorption.

(A) grade 1=no root resorption; (B) Grade 2 = slight root resorption (up to half of the dentinal width); (C) Grade 3 = moderate root resorption (half or more of the dentinal width, not involving the dental pulp); and (D) Grade 4 = severe root resorption (with dental pulp involvement).

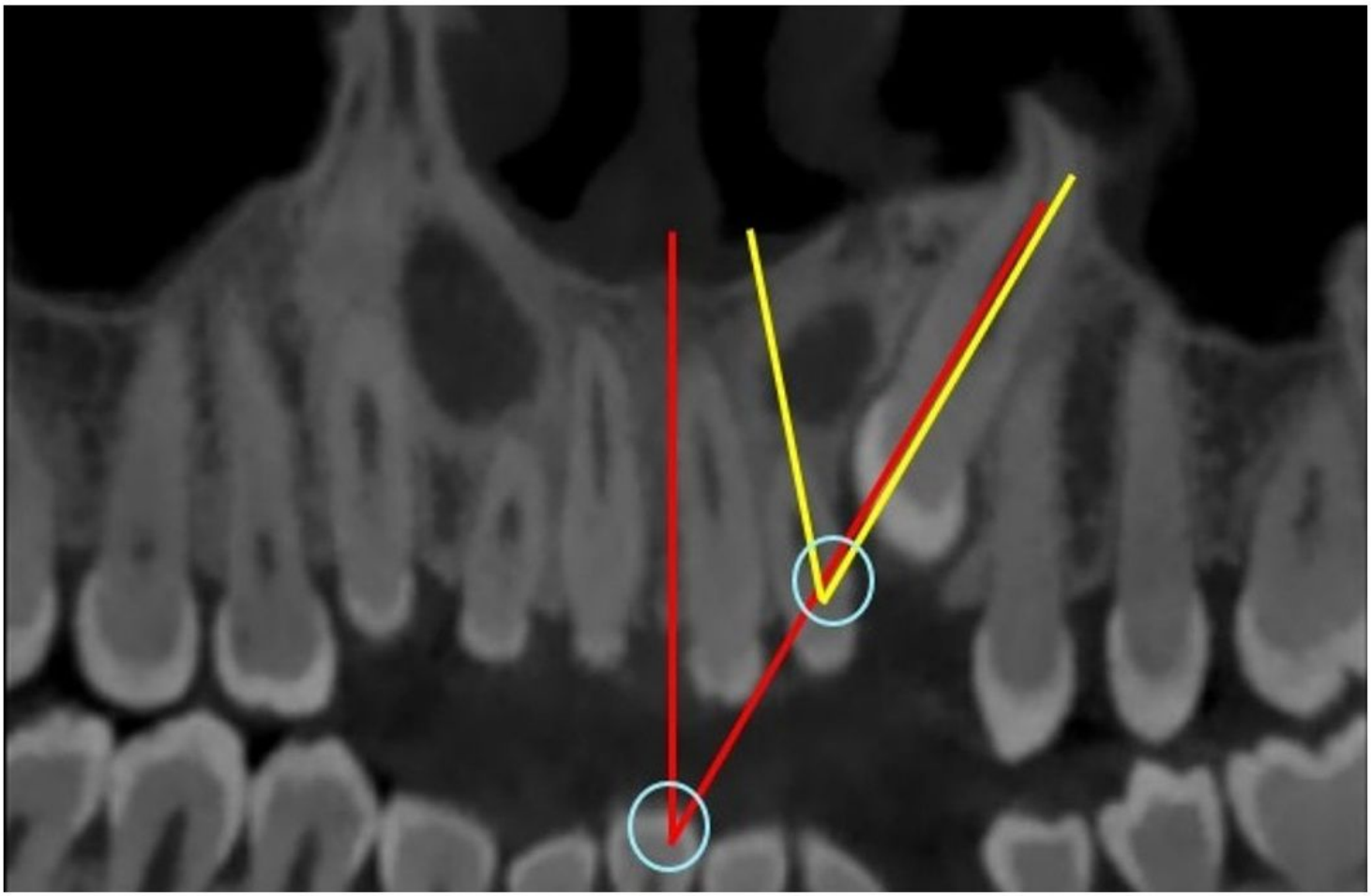

**Figure 2**

IMC position in coronal view

Measurement of the angle between the long axis of IMC and the adjacent lateral tooth (CAL) (yellow) and the midline (CAM) (red) in the coronal views obtained from CBCTs.

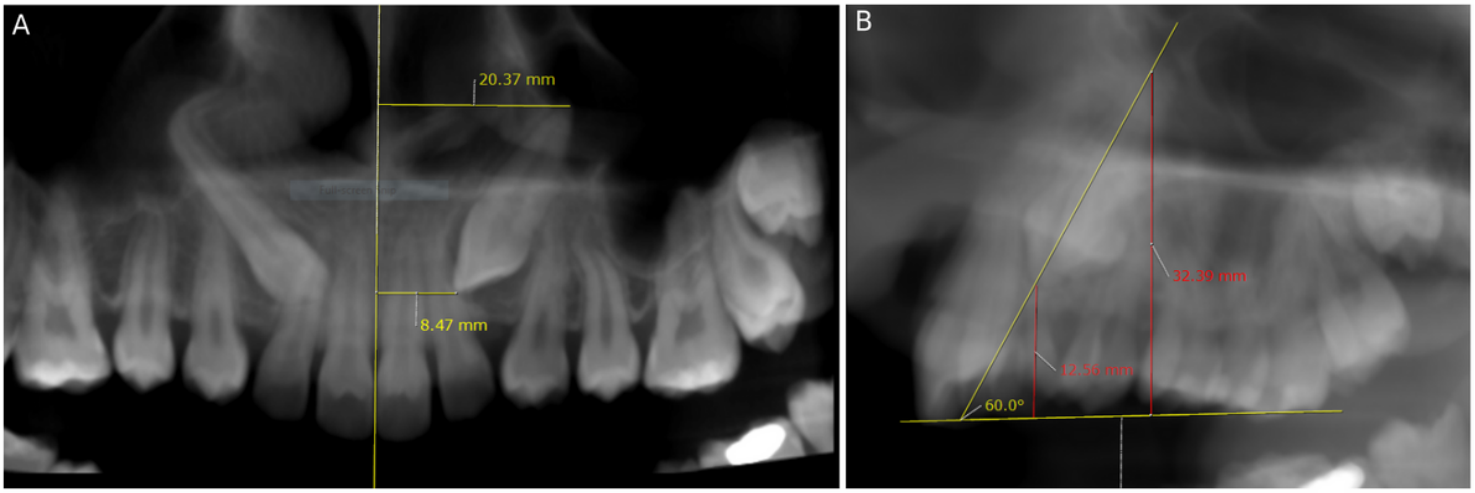


**Figure 3**

IMC location in coronal and sagittal views

(A), The distance between the cusp tip and the root apex from the midline in the coronal view, (B) the distance of the same points from the occlusal plane and the angle between the long axis of IMC and the occlusal plane (CAO) in the sagittal view.

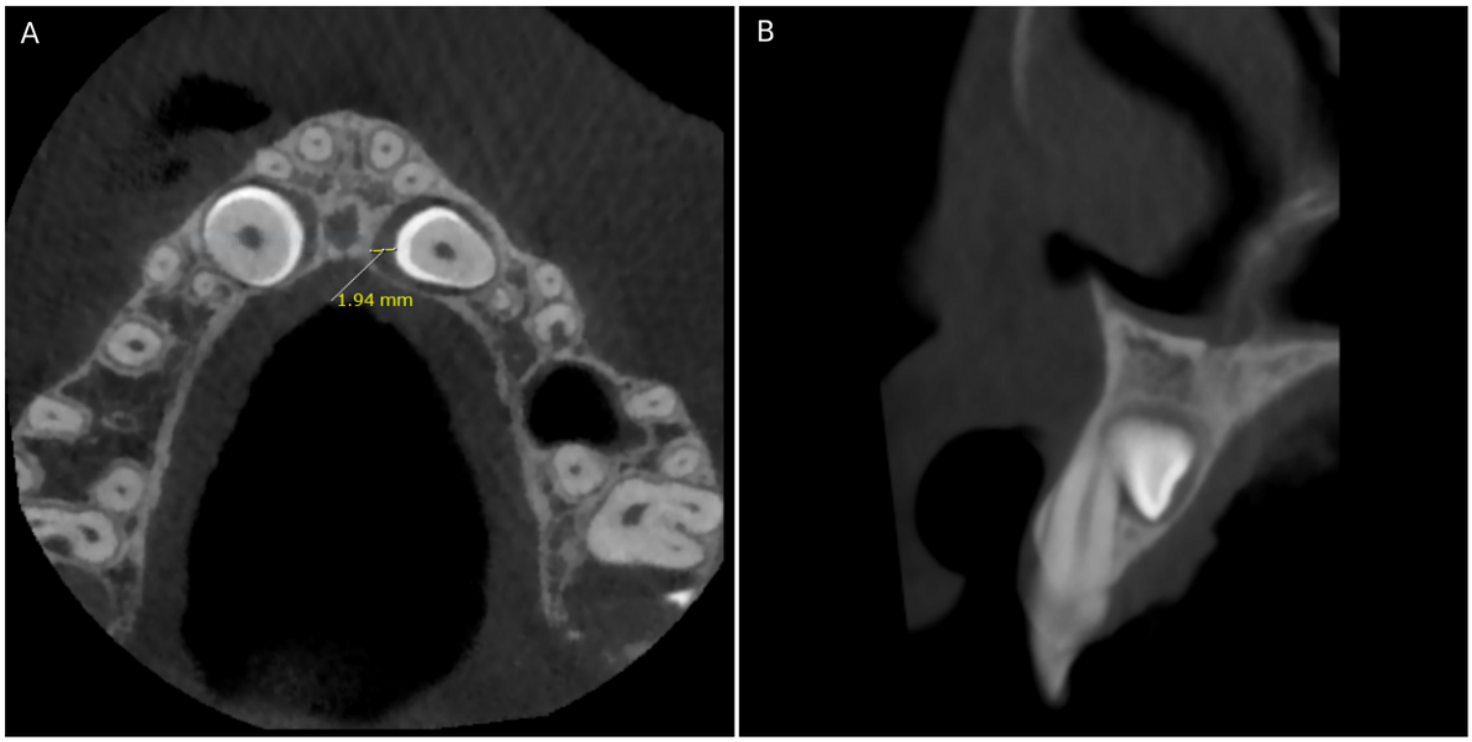


**Figure 4**

Follicle size of IMC and it’s relation with ALRR

(A): Evaluating IMC’s follicle size and the severity of ALRR in the axial view; (B) evaluating the severity of ALRR and the sagittal position of the IMC in relation to the adjacent lateral incisor in the cross-sectional view.