Comparison between Three Cannulated Screws and Targon Locking Plate for Displaced Intracapsular Hip Fracture: A Retrospective Study

Xiuxiu Hou (z17761505299@163.com)
Cangzhou Hospital of integrated traditional Chinese medicine and Western medicine

Guojun Shi
Cangzhou Hospital of integrated traditional Chinese medicine and Western medicine

Yadi Zhang
Cangzhou Hospital of integrated traditional Chinese medicine and Western medicine

Baorui Xing
Cangzhou Hospital of integrated traditional Chinese medicine and Western medicine

Dingli Xu
Affiliated Hospital of Ningbo University

Research Article

Keywords: Displaced intracapsular hip fracture, Cannulated screw, Targon locking plate, Femoral neck shorting

Posted Date: April 8th, 2022

DOI: https://doi.org/10.21203/rs.3.rs-1528403/v1

Abstract

Purpose: The aim of this retrospective study was to compare the clinical and radiological outcomes between three cannulated screws (TCS) and two cannulated screws combined one fully threaded cannulated screw with TARGON locking plate (TCS-TLP) for the displaced intracapsular hip fracture.

Methods: 75 patients underwent displaced intracapsular hip fracture were treated with operation from January 2013 to January 2019. 35 patients underwent TCS-TLP and others 40 patients treated with TCS. Injuries were assessed based on AO classification, and the outcomes measurements including modified Harris hip score (MHHS), visual analogue score (VAS) and the radiological data.

Results: There were significantly better MHHS improvement in the TCS-TLP group than TCS group at the 12 months (85.6 VS 75.6, $P<0.05$) and 24 months (89.4 VS 81.1, $P<0.05$). And a total of 5 patients had complications in TCS-TLP group whilst 14 cases in the TCS group ($P<0.05$), similarly, the femoral neck shorten rate was significantly less in the TCS-TLP group at each follow-up visit ($P<0.05$).

Conclusion: Patients treated with two cannulated screws combined one fully threaded cannulated screw with Targon locking plate can have better function improvement, less orthopedic complications and prevent femoral neck shorting.

Introduction

Intracapsular hip fracture is a prevalent injury which commonly induced significant morbidity and mortality in elderly population especially females over 75 years.[1] Whilst, the medicine cost was towering up as the number of intracapsular hip fractures increasing which caused a large social burden.[2] Recently, the treatment methods for intracapsular hip fracture were still challengeable and remain controversial. The major strategies are total hip arthroplasty, hemiarthroplasty and multiple cannulated screw and many researchers reported that those methods yield satisfied clinical outcomes.[3] Whereas, there are some disadvantages and complications including implement failure, malunion and hip neck shorting after operation and the total complication rate are around 26～65%.[4, 5]

Recently, more and more researchers interested in Targon locking plate for the treatment of intracapsular hip fracture which can provide superior rotational stability and minimized complications, Parker et al reported that 320 patients using a Targon locking plate and there were 252 (78.8%) cases healed uneventfully, 35 (11.6%) nonunion and 28 (8.8%) had avascular necrosis at two years follow-up.[6] Whereas, Matar et al found that less complication rates in patients treated with Targon locking plate system. There were 2 cases developed avascular necrosis, 2 were nonunion and 1 patient had screw cutout in 43 patients.[7] What's more, some finite element analysis also showed it can perform better rotational stability and resisting shearing.[8] Moreover, some researchers reported that fully threaded cannulated screws can also minimized the complications including femoral neck shorting and pain, Weil et al reported that 24 patients underwent internal fixation with fully threaded cannulated screws and other

41 were treated with partial threaded cannulated screw. And found that there were significantly less femoral neck shorting and screw pull-out in patients with fully threaded cannulated screw than partial threaded cannulated screw ($P < 0.05$).[9] Kanthasamy et al reported that Targon device can protect non-union rate compared with cannulated screws for intracapsular hip fractures[10]. Hereunto, there was little published article about the clinical efficacy of fully threaded cannulated with Targon locking plate.

So, this study was aimed to compare the clinical and radiological outcomes of three cannulated screw and two cannulated screws and one fully threaded cannulated screw with Targon locking plate for patients with displaced intracapsular hip fractures.

Materials And Methods

This is a retrospective study and all details of patients with displaced intracapsular hip fracture who underwent three cannulated screw and two cannulated screws combined one fully threaded cannulated screw with Targon locking plate from January 2014 to January 2019 were obtained from medical records, and this study was promised by Ethics committee of Cangzhou Hospital of integrated traditional Chinese medicine and Western medicine (No.2019007). And the need for informed consent was waived by institutional review board of our Hospital given its retrospective design.

The inclusion criteria were as follow: 1) freshly closed displaced intracapsular hip fractures; 2) Age under 75 years old; 3) treated with three cannulated screws or two cannulated screws combined one fully threaded cannulated screw with Targon locking plate; 4) with intact medical records and more than 24-month follow-up visit. According these criterias, a total of 107 patients diagnosed as displaced intracapsular hip fracture were enrolled in this study. Patients were excluded if they refused involvement, surgery history in the hip, long-time hormone use or combined with disease which may affect the clinical outcome, such as renal osteopathy, diabetes and rheumatoid arthritis. Finally, 32 patients were excluded, and 75 patients were suitable in this study.

Surgical procedure

All patients in two groups were given spinal anesthesia and positioned supine on treatment table. Reduction of fractured limb was achieved by gradual longitudinal traction and rotation under fluoroscopic control.

In the TCS-TLP group

Patients around 5cm incision and lateral approach under vastus lateralis was made to place a 130^0 alignment jig. Then a K-wire was inserted into the above the level of less trochanter, and the K-wire was in a middle position of femoral neck which testified by the C-arm fluoroscopy. The Targon locking plate (Fig. 1) and alignment jig were positioned on the lateral proximal femoral, and others three K-wires were inserted through the plate up to the femoral neck. After the K-wires were measured and the screw holes are drilled, removed the K-wires and inserted two cannulated screws and one fully threaded cannulated

screw. Finally, the two distal screws were placed through the plate for fixing the plated to the lateral proximal femoral cortex (Fig. 2).

In the TCS group

After exposure the skin and muscle, find and marked the level of the lesser trochanter and a K-wire was inserted by free hand to achieve a central position testified by the C-arm fluoroscopy. Then others three guide K-wire were inserted as an inverted triangle around in an anteversion angle of 15^0 and gantry angle of 127^0. Finally, those guide K-wires were measured and drilled, in order to three cannulated screws were inserted under C-arm fluoroscopy (Fig. 3).

The postoperative rehabilitation principle was as follow, in the 1 week postoperative, patients were asked to exercise quadriceps and ankle, and ambulation with sticks was encouraged after 3 to 4 weeks for all patients. But full weight bearing was not allowed during first 6 weeks.

Outcome evaluation

The pain was evaluated by visual analogue scale (VAS) which was a self-assessed questionnaire and the scale ranges from 0 to 10 points.[11] The recovery of hip function was assessed by modified Harris hip score which scored from 0 (worst functional and maximum pain) to 100 (best functional and minimum pain) points.[12] The general data including age, gender, fracture side and type, operation time and blood loss were collected from medical record in both groups, and radiological data including X-ray and CT-scan were obtained at preoperative, immediately after operative, 1, 6, 12 and 24 month follow-up visit and performed by two experienced orthopedic surgeons (DC Huang and GQ Jiang). The tip-apex distance and orthopedic complications such as nonunion, malunion and implement failure were analyzed, as well. Bone union was defined that restoration of cortical continuity and absence of visible fracture line; malunion is defined as collodiaphyseal angle less than 120^0 or less than 50% contact between the proximal and distal fragments; nonunion is defined as lack of union or displacement of fracture after 12 months follow-up visits; implement failure including screw cutout, leakage and break.

The femoral neck shortening was measured on an anterior-posterior radiograph of pelvis at 6 months follow-up visit. The shorting was measured from the femoral head center along the femoral neck axis until touching the femoral shaft axis and compared with unfractured site in immediate postoperative X-ray. And in the cases with screw cutout, the shorting was measured with the greatest amount of lateral protuberance[13]. The distance more than 5mm defined as femoral neck shorting.[14]

Statistics

In this study, all data were showed as Mean ± standard deviated and statistical analysis was performed using SPSS for Windows version 25. The baseline characteristics and complication outcomes of all patients were analyzed by the $\chi 2$ test, the paired-T test was used to compare the outcomes of preoperative and each follow-up visit in each group, and the clinical evaluations at each follow-up visit

were compared by using independent T-test. The p-value less than 0.05 was considered as statistically significant.

Result

Totally 75 patients were enrolled in this study and all patients with displaced intracapsular hip fracture who have underwent three cannulated screw or two cannulated screws combined one fully threaded cannulated screw with Targon locking plate were followed-up for least 2 years. There was no significantly difference in general data including age, gender, body mass index, time from injury to operation, fracture side and type between two groups ($P > 0.05$) (Table.1). Similarly, no significantly difference was detached in preoperative data between two groups such as VAS, MHHS ($P > 0.05$).

A significantly difference was detected in operation time (57.4 ± 12.9 VS 45.7 ± 16.4, $P < 0.05$) and blood loss (68.4 ± 25.7 VS 36.4 ± 8.7, $P < 0.05$) in the TCS-TLP group compared with TCS group. And there was no significantly in minimal (5.4 ± 1.2 VS 5.7 ± 0.9, $P > 0.05$) and maximal (11.5 ± 3.6 VS 12.1 ± 2.8, $P > 0.05$) tip-apex distance between two groups (Table 2). Significantly better recovery in MHHS was found in the TCS-TLP group than TCS group at 12 and 24 months follow-up visit ($P < 0.05$), but there was no statistical difference at 1 and 6 months follow-up between two groups ($P > 0.05$). The VAS was significantly decreased in two groups group after operation and statistically difference was detected at 1 month follow-up visit (2.2 ± 1.7 VS 2.6 ± 1.4, $P < 0.05$), whereas, no significantly difference between two groups at others follow-up visit time ($P > 0.05$).

Table 1
Comparison of baseline characteristic of two group

Characteristic	TCS group (n = 40)	TCS-TLP group (n = 35)	P-value
Age,yrs(SD)	59.5 ± 13.5	61.3 ± 12.8	0.81
Gender,n(%)			
Male	17(42.5)	15(42.9)	0.58
Female	23(57.5)	20(57.1)	
BMI (SD)	23.7 ± 2.4	23.1 ± 1.9	0.23
Fracture side,n(%)			
Left	26(65)	19(54.3)	0.16
Right	14(35)	16(45.7)	
Fracture type,n(%)			
Garden III	28(70)	23(65.7)	0.44
Garden IV	12(30)	12(34.3)	
Injury to operation,ds(SD)	1.5 ± 0.5	1.7 ± 0.3	0.48

Table 2
Comparison of clinical and radiological outcomes of two groups

Characteristic	TCS group (n = 40)	TCS-TLP group (n = 35)	P-value
Operation time,mins(SD)	45.7 ± 16.4	57.4 ± 12.9	0.04*
Blood loss,ml(SD)	36.4 ± 18.7	68.4 ± 25.7	0.03*
TAD			
Minimal,mm(SD)	5.4 ± 1.2	5.7 ± 0.9	0.57
Maximal,mm(SD)	11.5 ± 3.6	12.1 ± 2.8	0.39
MHHS (SD)			
Preoperation	37.4 ± 3.1	36.1 ± 2.8	0.48
1 month	71.5 ± 5.4	74.5 ± 3.1	0.15
6 months	73.7 ± 5.8	79.7 ± 3.3	0.61
12 months	75.6 ± 2.7	85.6 ± 3.7	0.03*
24 months	81.1 ± 3.2	89.4 ± 2.1	0.04*
VAS (SD)			
Preoperation	6.4 ± 2.5	6.7 ± 2.8	0.38
1 month	2.2 ± 1.7	2.6 ± 1.4	0.04*
6 months	1.2 ± 1.4	1.5 ± 1.7	0.14
12 months	0.8 ± 0.6	0.7 ± 0.5	0.72
24 months	0.5 ± 0.3	0.6 ± 0.4	0.86
TAD: Tip-apex distance; *: P < 0.05			

The complications rate in TCS group was 35% (14 of 40), and 2 patients occurred wound infection which managed conservatively, 3 were malunion, 1 was nonunion, 2 were screw cutout, 4 were screw loosening, 1 was refractured and 1 had avascular necrosis. In the TCS-TLP group, there were 5 of 35 (14.3%) patients had complications during follow-up time including 1 patient occurred wound infection and 1 patient were malunion at the final follow-up visit based on radiological outcomes. What's more, the patient with avascular necrosis treated with total hip replacement and the patient who refractured in the operated site due to fallen was treated with conservative. There was significantly less femoral shorting rate in the TCS-TLP group compared with TCS group ($P < 0.05$), 3 patients occurred femoral neck shorting in the TCS-TLP group, and 15 patients in TCS group (Table 3).

Table 3
Comparison of complications and femoral neck shorting of two groups

Characteristic	TCS group (n = 40)	TCS-TLP group (n = 35)	P-value
Complications,n			
Wound infection	2	1	< 0.05*
Malunion	3	1	
Nonunion	1	0	
Screw cutout	2	0	
Screw loosening	7	0	
Refracture	1	0	
Avascular necrosis	1	0	
Femoral neck shorting			
<5 mm	25	32	0.003*
>5 mm	15	3	
*: P < 0.05			

Discussion

Nowadays, there are towering up number of displaced intracapsular hip fracture which will have a significantly impact on the life level of patients and cast a huge economic burden on society, and the displaced intracapsular hip fracture is still a challenge of orthopedic surgeons because patients may occur many complications even refracture after operation. Three cannulated screw were usually performed for displaced intracapsular hip fracture in elder, Wani et al reported that 50 patients with displaced fracture of the femoral neck were underwent closed reduction and internal fixation with cannulated screw. The patients had yield satisfied clinical outcome, such as the HHS was improved to 90.6 ± 2.2 at the final follow-up visit time but there were 4 patients occurred nonunion and 6 were avascular necrosis.[15] Similarly, Dong et al reported that 30 patients with displaced intracapsular hip fracture (Pauwels's III) underwent ordinary cannulated screw fixation. They have got significantly improvement in HHS and EQ-5D but 17/30 patients occurred femoral neck shorting (> 5mm) at final follow-up visit.[16]

In order to minimize the orthopedic complications and femoral neck shorting, more and more surgeons are focus on the Targon locking plate and fully threaded cannulated screw for displaced intracapsular hip fracture. Parker et al reported that 208 patients with displaced intracapsular hip fracture underwent internal fixation with Targon locking plate. There was significantly recovery in pain mobility score and 148 of 208 (71.1%) patients were uneventful fracture healing.[17]

And some finite-element studies also demonstrated that Li et al reported a finite-element analysis about comparison of ordinary cannulated screw, dynamic hip screw with derotational screw and cannulated screw with Targon locking plate. And found that cannulated screw with Targon locking plate can perform better in resisting shearing and rotational force.[18] Boraiah et al had retrospectively collected 54 patients younger than 65 years old treated with open reduction and internal fixation using fully threaded cannulated screw. A total of 51/54 patients were healed successfully without any complications, and the average shorten of femoral neck was 0.54 mm (Range from 0 to 2.7).[19]

In this study, a total of 75 patients with displaced intracapsular hip fracture who underwent internal fixation were enroll in our study and 35 were two cannulated screws combined one fully threaded cannulated screw with Targon locking plate, others 40 patients were treated with three cannulated screws.

Our outcome shown that TCS-TLP group have a better improvement in hip function, decreased the orthopedic complication and minimized femoral neck shorting. At 12 and 24 months followed-up visit, the MHHS were significantly better increased in TCS-TLP group than TSC group ($P < 0.05$). Similarly, 15 of 40 patients was detected femoral neck shorting more than 5 mm and 3 of 35 patients in the TCS-TLP group ($P < 0.05$). Moreover, there were total of 5 patients presented orthopedic complications and 1 patient had wound infection in the TCS-TLP group, whereas, 15 patients occurred orthopedic complications and 2 had wound infection in the TCS group. Some already published articles reported similarly outcomes, Warschawski et al documented that there were 23 (28.4%) patients had orthopedic complications in patients with cannulated screws and 6 (17.6%) patients in the patients treated with Targon locking plate. But the patients using Targon locking plated had more pain score than patients treated with cannulated screws. Whereas they didn't have measured the femoral neck shorting.[20] And Thein et al retrospectively collected 31 patients treated with Targon FN and other 47 patients were underwent internal fixation using multiple cannulated screws, and detected that patients treated with Targon FN had significantly less orthopedic complication rate and revision than patients underwent multiple cannulated screws ($P < 0.05$).[21]

In our study, the femoral neck shorting rate was 37.5%, and others articles reported similarly outcomes that the femoral neck shorting rate is around 27%~31% in femoral neck fracture patients treated with multiple cannulated screws.[22] And there were only 3 (8.6%) patients underwent two cannulated screws combined one fully threaded cannulated screw with Targon locking plate had femoral neck shorting. Wang et al reported that 8 of 34 (23.5%) patients treated with three partial threaded cannulated with dynamic screws occurred femoral neck shorting.[23] And Alves et al found fully threaded cannulated screw can provide better biomechanical support and prevent femoral neck shortening in femoral neck fractures receiving internal fixation.[24] Similarly, Alshameeri et al reported that patients treated with Targon lock plated shown less rate of non-union and reoperation than patients with cannulated cancellous screws.[25]

The possible reason for more orthopedic complications occurred in patients treated with three cannulated screws maybe insufficient resisting shearing and rotational force. Whereas, the Targon locking plate can

not only provident stronger support in the femoral neck, but also prevent the loosening or cut-out of screws.[23] Three screws inserted in an inverted triangle can keep stability in the fractured site, and one fully threaded cannulated screw can avoid femoral neck collapse after operation.[9] So that Targon locking plate show superior improvement in diminish orthopedic complication and achieved better clinical efficacy than three cannulated screws infixation.

Some limitations of this study are as follow, this study was conducted in a single center and the sample size is small. It could be better to set patients treated with three partial threaded cannulated screw with dynamic locking screw as control group but the cases are few in our hospital. Finally, biomechanical or finite element analysis should be further conducted to analyze the force distribution after operation.

Conclusion

Targon locking plate fixation can significantly improve hip function, minimize orthopedic complications and prevent femoral neck shorting than three cannulated screws for displaced intracapsular hip fracture. What's more, furthermore studies are needed to testify the efficacy of Targon locking plate fixation for treating displaced intracapsular hip fracture.

Abbreviations

TCS: three cannulated screws; TCS-TLP; two cannulated screws combined one fully threaded cannulated screw with TARGON locking plate; MHHS: modified Harris hip score; VAS: visual analogue score.

Declarations

Thanks for the contribution of the tracking system.

Acknowledgements

We would like to thank Drs Guangpu Han for insightful conversations.

Authors' contributions

HXX (Data collection, Writing original manuscript); SGJ (Methodology); YDZ (Software measure, statistical analysis); XBR,DLX (prepared the figures, revised the manuscript). All authors read and approved the final manuscript.

Funding

None

Availability of data and materials

The patients' dataset are confidential and are privately held for patients confidentiality safeguard. As such, the datasets generated and/or analysed during the current study are not publicly available but are available from the corresponding author on reasonable request.

Ethics approval and consent to participate

This study was approved by the medical ethics review board of Cangzhou Hospital of integrated traditional Chinese medicine and Western medicine.

All methods in the study were carried out in accordance with the Helsinki guidelines and declaration.

All procedures were undertaken by the senior author after obtaining informed consent for all patients.

Consent for publication

We acquired informed written consent for publication of this report and accompanying images from the patients.

Competing interests

No competing interest to report.

References

1. Alexiou KI, Roushias A, Varitimidis SE, et al. Quality of life and psychological consequences in elderly patients after a hip fracture: a review. *Clinical interventions in aging* 2018; 13: 143-150. 2018/02/09. DOI: 10.2147/cia.s150067.
2. Wang Y, Cui H, Zhang D, et al. Hospitalisation cost analysis on hip fracture in China: a multicentre study among 73 tertiary hospitals. *BMJ open* 2018; 8: e019147. 2018/04/29. DOI: 10.1136/bmjopen-2017-019147.
3. Beebe MJ, Bauer JM and Mir HR. Treatment of Hip Dislocations and Associated Injuries: Current State of Care. *The Orthopedic clinics of North America* 2016; 47: 527-549. 2016/06/01. DOI: 10.1016/j.ocl.2016.02.002.
4. GK C, SS M, T C, et al. Total hip replacement versus open reduction and internal fixation of displaced femoral neck fractures: a randomized long-term follow-up study. *The Journal of bone and joint surgery American volume* 2012; 94: 1921-1928.
5. Bigoni M, Turati M, Leone G, et al. Internal fixation of intracapsular femoral neck fractures in elderly patients: mortality and reoperation rate. *Aging clinical and experimental research* 2020; 32: 1173-1178. 2019/06/09. DOI: 10.1007/s40520-019-01237-z.
6. M P, S C and V P. Internal fixation of intracapsular fractures of the hip using a dynamic locking plate: Two-year follow-up of 320 patients. *The bone & joint journal* 2013; null: 1402-1405.

7. HE M and P C. Outcomes of internal fixation of intracapsular hip fractures using dynamic locking plate system (Targon FN). *Journal of orthopaedics* 2018; 15: 829-831.
8. J L, Z Z, P Y, et al. Comparison of three different internal fixation implants in treatment of femoral neck fracture-a finite element analysis. *Journal of orthopaedic surgery and research* 2019; 14: 76.
9. Weil YA, Qawasmi F, Liebergall M, et al. Use of fully threaded cannulated screws decreases femoral neck shortening after fixation of femoral neck fractures. *Archives of orthopaedic and trauma surgery* 2018; 138: 661-667. 2018/02/11. DOI: 10.1007/s00402-018-2896-y.
10. Kanthasamy S, To K, Webb JI, et al. Timing of surgery for internal fixation of intracapsular hip fractures and complications at 1 year; a 32 year clinical study of 2,366 patients at a single center. *Injury* 2021 2021/12/19. DOI: 10.1016/j.injury.2021.11.038.
11. Brokelman RB, Haverkamp D, van Loon C, et al. The validation of the visual analogue scale for patient satisfaction after total hip arthroplasty. *European orthopaedics and traumatology* 2012; 3: 101-105. 2012/07/17. DOI: 10.1007/s12570-012-0100-3.
12. Vishwanathan K, Akbari K and Patel AJ. Is the modified Harris hip score valid and responsive instrument for outcome assessment in the Indian population with pertrochanteric fractures? *J Orthop* 2018; 15: 40-46. 2018/01/13. DOI: 10.1016/j.jor.2017.12.001.
13. DJ S, KA L, DE D, et al. Incidence, Magnitude, and Predictors of Shortening in Young Femoral Neck Fractures. *Journal of orthopaedic trauma* 2015; 29: e293-298.
14. Y L, ZS A, J S, et al. Femoral neck shortening after internal fixation. *Acta orthopaedica et traumatologica turcica* 2013; 47: 400-404.
15. Wani IH, Sharma S, Latoo I, et al. Primary total hip arthroplasty versus internal fixation in displaced fracture of femoral neck in sexa- and septuagenarians. *J Orthop Traumatol* 2014; 15: 209-214. DOI: 10.1007/s10195-013-0278-3.
16. Dong Q, Han Z, Zhang YG, et al. Comparison of Transverse Cancellous Lag Screw and Ordinary Cannulated Screw Fixations in Treatment of Vertical Femoral Neck Fractures. *Orthopaedic surgery* 2019; 11: 595-603. 2019/07/25. DOI: 10.1111/os.12503.
17. Parker M, Cawley S and Palial V. Internal fixation of intracapsular fractures of the hip using a dynamic locking plate: Two-year follow-up of 320 patients. *The bone & joint journal* 2013; 95-b: 1402-1405. 2013/10/01. DOI: 10.1302/0301-620x.95b10.31511.
18. Li J, Zhao Z, Yin P, et al. Comparison of three different internal fixation implants in treatment of femoral neck fracture-a finite element analysis. *J Orthop Surg Res* 2019; 14: 76. 2019/03/16. DOI: 10.1186/s13018-019-1097-x.
19. Boraiah S, Paul O, Hammoud S, et al. Predictable healing of femoral neck fractures treated with intraoperative compression and length-stable implants. *The Journal of trauma* 2010; 69: 142-147. 2009/12/17. DOI: 10.1097/TA.0b013e3181bba236.
20. Warschawski Y, Sharfman ZT, Berger O, et al. Dynamic locking plate vs. simple cannulated screws for nondisplaced intracapsular hip fracture: A comparative study. *Injury* 2016; 47: 424-427. 2015/11/28. DOI: 10.1016/j.injury.2015.10.054.

21. Thein R, Herman A, Kedem P, et al. Osteosynthesis of unstable intracapsular femoral neck fracture by dynamic locking plate or screw fixation: early results. *Journal of orthopaedic trauma* 2014; 28: 70-76. 2013/07/19. DOI: 10.1097/BOT.0b013e3182a225fa.
22. Tidermark J, Ponzer S, Svensson O, et al. Internal fixation compared with total hip replacement for displaced femoral neck fractures in the elderly. A randomised, controlled trial. *The Journal of bone and joint surgery British volume* 2003; 85: 380-388. 2003/05/06. DOI: 10.1302/0301-620x.85b3.13609.
23. Wang Z, Yin Y, Li Q, et al. Comparison of early complications between the use of a cannulated screw locking plate and multiple cancellous screws in the treatment of displaced intracapsular hip fractures in young adults: a randomized controlled clinical trial. *J Orthop Surg Res* 2018; 13: 201. 2018/08/15. DOI: 10.1186/s13018-018-0901-3.
24. Alves T, Neal JW, Weinhold PS, et al. Biomechanical comparison of 3 possible fixation strategies to resist femoral neck shortening after fracture. *Orthopedics* 2010; 33 2010/04/27. DOI: 10.3928/01477447-20100225-07.
25. Alshameeri Z, Elbashir M and Parker MJ. The outcome of intracapsular hip fracture fixation using the Targon Femoral Neck (TFN) locking plate system or cannulated cancellous screws: A comparative study involving 2004 patients. *Injury* 2017; 48: 2555-2562. 2017/09/19. DOI: 10.1016/j.injury.2017.08.063.

Figures

Figure 1

The diagram of Targon locking plate.

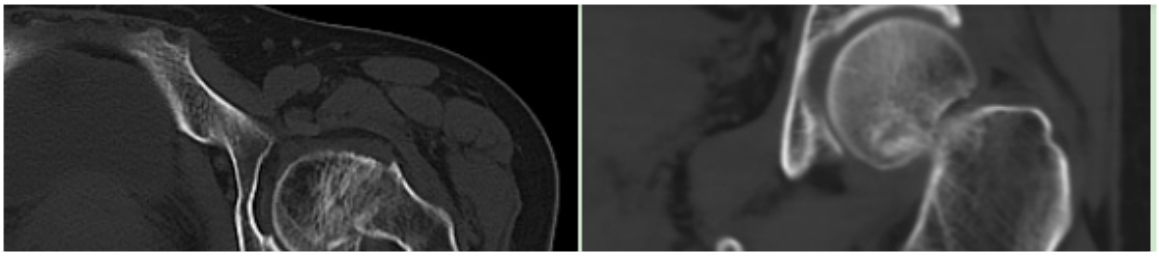

Figure 2

2a and 2b: Preoperative hip CT scan of a 54 years old female patient with displaced intracapsular hip fracture. 2c and 2d: The 3 months postoperative X-ray showed fracture healed without orthopedic complications. 2e: The 2 years postoperative X-ray shown the fractured site was bone union without implement failure or femoral neck shorting.

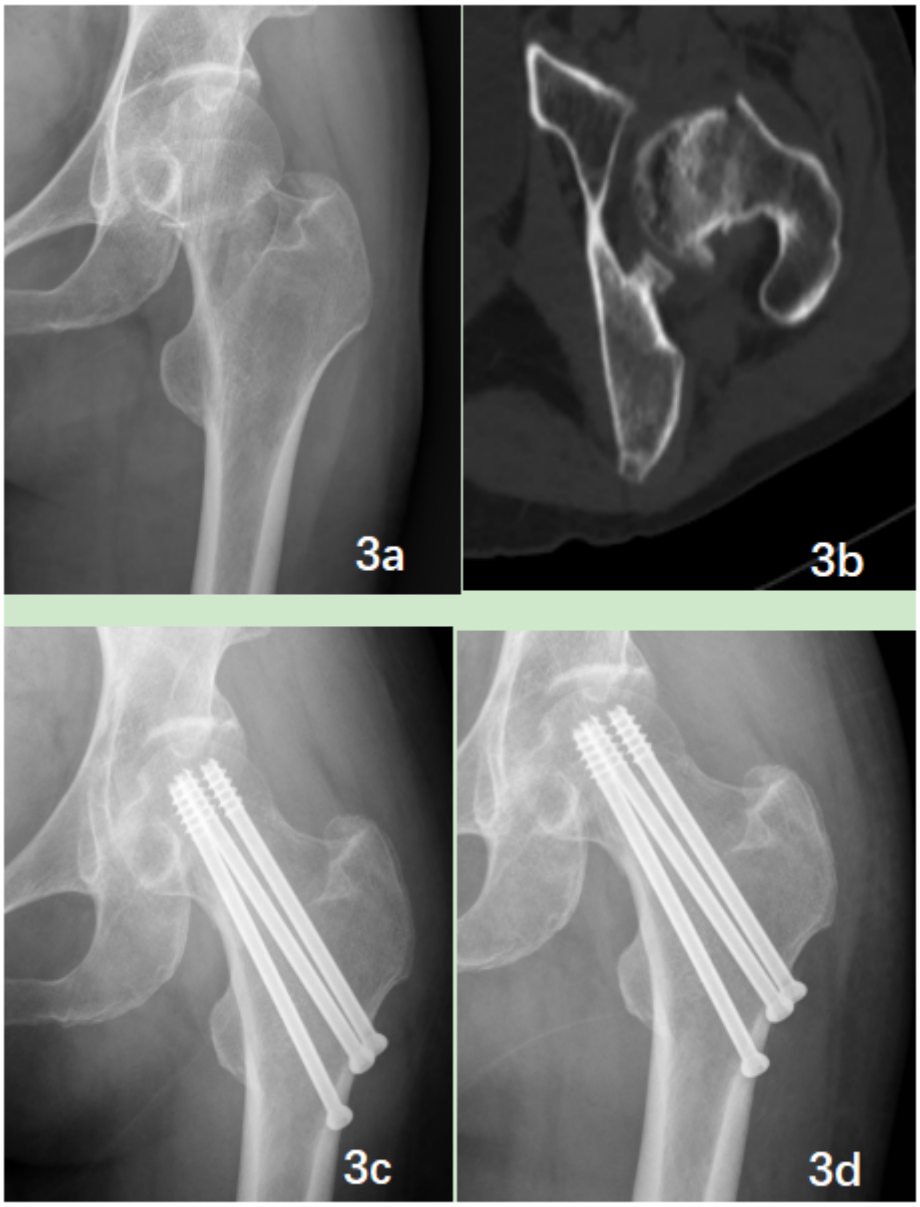

Figure 3

3a and 3b: Preoperative hip X-ray and CT scan of a 49 years old male patient with displaced intracapsular hip fracture. 3c and 3d: The 1 year and 2 years postoperative X-ray showed fracture healed without orthopedic complications