Anaplastic Thyroid Carcinoma With Ilium and Cervical Lymph Nodes Metastases: A Case Report and Literature Review

Yi Gong
Department of Thyroid Surgery, The Second Xiangya Hospital, Central South University
Wanlin Tan
Department of Ultrasound Diagnosis, The Second Xiangya Hospital, Central South University
Liyan Liao
Department of Pathology, The Second Xiangya Hospital, Central South University
Yan Xu
Department of Ultrasound Diagnosis, The Second Xiangya Hospital, Central South University
Xiaodu Li
Department of Ultrasound Diagnosis, The Second Xiangya Hospital, Central South University
Qi Zhang
Department of Ultrasound Diagnosis, The Second Xiangya Hospital, Central South University
Chengcheng Niu (niuchengcheng@csu.edu.cn)
Department of Ultrasound Diagnosis, The Second Xiangya Hospital, Central South University

---

Research Article

Keywords: anaplastic thyroid carcinoma (ATC), squamous cell carcinoma, lung and ilium metastases, cancer immunotherapy, cervical lymph nodes metastases

Posted Date: April 20th, 2022

DOI: https://doi.org/10.21203/rs.3.rs-1528699/v1

Abstract

Introduction

Anaplastic thyroid carcinoma (ATC) is a rare and clinically aggressive thyroid carcinoma with highly mortality. However, no matter the diagnosis or therapy of this disease was still a dilemma.

Case report

We present a 79-year-old female patient with progressively enlarged thyroid nodules and diagnosed as tracheal stenosis. Two years ago, the patient had presented in our hospital with right ilium pain and diagnosed as poorly differentiated squamous cell carcinoma of lung with right ilium and cervical lymph nodes metastases. Then, the patient received intensity-modulated radiotherapy (IMRT) and cancer immunotherapy with pembrolizumab. Twenty months later, a total thyroidectomy and cervical lymph nodes dissection were undertaken, the histopathologic and immunohistochemical evaluations confirmed the diagnosis of ATC with local squamous cell carcinoma differentiation. Postoperatively, the patient received a cancer immunotherapy with anlotinib and envafolimab, but the patient died 6 weeks after surgery.

Conclusion

We have reported a case of ATC with local squamous cell carcinoma differentiation, which was misdiagnosed as lung squamous cell carcinoma with extensive metastases and treated by cancer immunotherapy, the overall survival of this patient was more than 24 months.

Introduction

Anaplastic thyroid carcinoma (ATC) is a rare and aggressive thyroid malignancy with high mortality, accounts for approximately 1–2% of thyroid carcinoma [1, 2]. Despite multimodality treatment, the median overall survival of ATC was 4 months, the 6-month overall survival is 35%, and disease-specific mortality is 98–99% [3, 4]. Owing to the its highly dedifferentiation, few characteristics of noncancerous thyroid cells are remained in ATC, which may mimic other differentiated origins, including primary thyroid lymphoma, squamous cell carcinoma of head and neck, and lung metastatic cancer, thus, a definitive diagnosis of ATC could be a challenge [1].

Thyroid ultrasonography as a recommended method for evaluating the thyroid nodules classification, provided some typical malignant features for differentiated thyroid cancer (DTC) [5]. However, patients with ATC are often difficult to diagnose due to lack of typical imaging findings[6]. Here, we reported a case of ATC with local squamous cell carcinoma differentiation, which presented mixed-echoic appearance and without a malignant feature of DTC on thyroid ultrasonography, thus they were classified as benign nodules with very low suspicious (< 3%) according to thyroid imaging Reporting and data system (TI-RADS) classification [7]. According to the findings of positron emission tomography–

computed tomography (PET/CT), thyroid ultrasonography and histopathology, the patient was misdiagnosed as lung squamous cell carcinoma with ilium and cervical lymph nodes metastases, and treated by intensity-modulated radiotherapy (IMRT) and cancer immunotherapy with pembrolizumab, which was also reported that have a positive therapeutic effect for ATC [8]. At the end, the overall survival of this patient was more than 24 months, which was far longer than the median overall survival of ATC [1, 2].

Case Report

A 79-year-old female patient presented to our hospital with thyroid nodules more than ten years and progressively enlargement for half of month, and diagnosed as tracheal stenosis. Two years ago, the patient had presented in our hospital with right ilium pain for three months. PET/CT with 18F-fluorodeoxyglucose (18F-FDG) was performed to assess for extent of disease and showed extensive hypermetabolic lesions in left lung (Fig. 1A), right ilium (Fig. 1B), right thyroid lobe and cervical lymph nodes (Fig. 1C). Thyroid ultrasonography was performed and revealed a heterogeneous echoic thyroid mass in the right lobe with a rich blood flow signal inside this mass on color doppler flow imaging (CDFI) mode (Fig. 2A and 2B), a heterogeneous echoic thyroid nodule showed in the left lobe with a rich blood flow signal around this nodule on CDFI mode (Fig. 2C and 2D). Both of the thyroid nodes on bilateral thyroid were diagnosed as TI-RADS 3 according to TI-RADS classification[7], which means they were benign possibility. Then, needle biopsy was performed for the right ilium and cervical lymph nodes immediately. The immunohistochemical stains of right ilium were positive for cytokeratin (CK) 7, CD10, P40, CAM5.2 and paired box gene (PAX-8), and negative for thyroid transcription factor (TTF-1), thyroglobulin (TG), parathyroid hormone (PTH), Calcitonin and Caudal homeobox transcription factor 2 (CDX-2), combined with the morphology of the initial hematoxylin and eosin (H&E), this ilium tissue tends to metastatic tumor. The immunohistochemical stains of right cervical lymph nodes were positive for epidermal growth factor receptor (EGFR), anaplastic lymphoma kinase (ALK), programmed cell death protein 1 ligand (PD-L1), P40, CK7, CD10, CK5/6, CK pan, and Ki67 proliferative index was about 60%. And the lymph nodes were negative for TTF-1, programmed cell death protein 1 (PD-1), Napsin A and CK20, combined with the initial H&E, this cervical lymph nodes tend to origin from poorly differentiated squamous cell carcinoma. According to the findings of PET/CT, thyroid ultrasonography and histopathology, the patient was diagnosed as lung squamous cell carcinoma with extensive metastases. Then, the IMRT was performed for the right ilium at 3000cGy/10F, 5 times per week. Ten days later, the patient was undergone the cancer immunotherapy with pembrolizumab due to the tumor proportion score of PD-L1 expression more than 90%. Twenty-one days later after the first time of cancer immunotherapy, the second time of cancer immunotherapy was carried out.

Until now, 20 months later after the second time of cancer immunotherapy, this patient presented to our hospital with progressively enlarged thyroid nodules and diagnosed as tracheal stenosis. Neck computed tomography (CT) was carried for evaluating the thyroid nodules and their relationship with the surrounding tissues. CT of the neck revealed swelled thyroid with lots of large thyroid nodules and multiple enlarged cervical lymph nodes (Fig. 3A and 3B). Thyroid and cervical lymph nodes

ultrasonography was performed and revealed heterogeneous echoic thyroid masses in the both thyroid lobe with a rich blood flow signal inside and around these masses, and multiple enlarged lateral cervical lymph nodes in the bilateral neck. (Fig. 3C, 3D and 3E). Besides that, right internal jugular vein was complete occlusion by tumor invasion. Then, the contrast enhanced ultrasound (CEUS) demonstrated a heterogeneous enhancement of the lymph node, indicating the normal lymph node structure was destroyed and instead of lots of neovascularity and necrosis with malignant cancer cells (Fig. 3F). Thus, a total thyroidectomy and cervical lymph nodes dissection were undertaken (Fig. 4A). Pathology report revealed a 6.0 cm poorly differentiated carcinoma on the left and a 5.5 cm poorly differentiated carcinoma on the right with metastatic involvement of 22 of 23 lymph nodes. According to the seventh/eighth edition of the American Joint Committee on Cancer/Tumor Lymph Node Metastasis (TNM) staging system, the patient was in TNM stage IVc (Any T, Any N, M1) [1, 9, 10]. H&E staining showed a poorly differentiated carcinoma with obvious atypia tumor cells, frequent mitoses, focal coagulation necrosis, tumor thrombus formation and a small amount of hyperplastic thyroid follicular epithelium around the tissue. The immunohistochemical staining of thyroid were positive for Vimentin, PAX-8, CD10, CAIX, P53 and CAM5.2, partial positive for CK pan, CK7, CK5/6, TG and P40, negative for TTF-1, Naspin A and Calcitonin, and Ki67 proliferative index was about 60% (Fig. 4B-J), consistent with an aggressive ATC with local squamous cell carcinoma differentiation. Next generation sequencing (NGS) testing results demonstrated her TP53 and EGFR mutations with tumor mutational burden (TMB) of 2.99 mutations/Mb. After surgery three weeks, the patient got obviously better and received a cancer immunotherapy with anlotinib (tyrosine kinase inhibitor therapy) and envafolimab (anti-PD-L1). Three weeks later, the patient presented to our hospital again with progressively enlarged neck and severe lung infection. Neck CT was carried and revealed multiple enlarged cervical lymph nodes on the left neck (Fig. 5A and 5B). After 2 days of anti-infection therapy, the patient died from severe lung infection and respiratory failure.

Discussion

ATC is an aggressive tumor with a very poor prognosis, patients with ATC rarely survive more than 2 years after diagnosis [1]. In most cases, extrathyroidal invasion occurs at the first diagnosis, with symptoms such as vocal hoarseness, swallowing and breathing difficulties occur due to compression or involvement of surrounding tissues and organs[10]. Distant metastases also frequently occur, the most common site is the lung, followed by the bone [3].

Because ATC is in a dedifferentiated state, partially or completely losing thyroid differentiation, thus it has various morphological manifestations, leading to difficulty in distinguishing it from benign nodules by preoperative radiological imaging [1]. Neck ultrasonography may be helpful in providing rapid evaluation of the primary thyroid tumor and assessing involvement of the central and lateral lymph nodes [1, 5, 11]. PET/CT with 18F-FDG is particularly valuable in evaluating metastatic sites for whole body[12, 13]. Contrast enhanced CT of chest, abdomen, and pelvis is a critical preoperative study; alternatively, contrast enhanced MRI can be substituted [14]. In this case, we offered the radiological images of ultrasonography, PET/CT and CT for ATC. On the neck ultrasonography, a heterogeneous echoic thyroid

mass in the right lobe with a rich blood flow signal inside two years ago, while a mixed-echoic thyroid nodule with cystic change in the left lobe, showing very low suspicious. Two years later, progressively enlarged heterogeneous echoic solid thyroid masses showed in the bilateral lobes with a very rich blood flow signal. However, few studies reported about the sonographic features of ATC. Hahn et al. reported that ATC often showed large size, solitary nodules, heterogeneous and hypo-echogenicity, which was consistent with this case, yet no mentioned the blood flow features [6]. Nevertheless, these above features of ATC with poor specificity also frequently showed in benign nodular goiters. On 18F-FDG PET/CT, extensive hypermetabolic lesions gathered at the left lung, right ilium, right thyroid lobe and cervical lymph nodes, which has a great help in disease detection and tumor staging of patient with ATC. Some studies also reported that 18F-FDG PET/CT has an impact on the management of patients with ATC [13, 15, 16]. On Neck CT, swelled thyroid with lots of large thyroid nodules and multiple enlarged cervical lymph nodes were clearly observed, which played an important role in preoperative and post-therapeutic elevation of ATC. Thus, preoperative multimodal radiological tests should be performed expeditiously for suspicious patient of ATC.

Given its poor prognosis and clinical outcome, a clear pathological diagnosis has profound significance for its treatment and prognosis. The histological features of ATC depend on the composition of the three main cellular components: spindle cells, squamous or epithelioid cells, and giant cells [17]. The immunophenotype of ATC is complex and diverse. The positive rate of epithelial-derived marker CK varies from 40–100%, single CK staining are often inconsistent. Usually, the detection rate can be improved by combining several CK packages[18]. Epithelial membrane antigen (EMA) is mainly expressed in epithelioid or squamous differentiated cells (30%-50%), while the mesenchymal marker Vimentin is expressed in all spindle cells[19]. Tumor cells do not express tissue-specific markers such as TG, Calcitonin, and TTF-1, but consistently and strongly express TP53[18, 20]. A transcription factor PAX-8 was expressed in 76% of ATC (100% with squamous differentiation) but not in other squamous cell carcinomas of the head and neck [21]. In this case, the immunohistochemical stains of right ilium were positive for CK7, CD10, P40, CAM5.2 and PAX-8, and negative for TTF-1, TG, PTH, Calcitonin and CDX-2. The immunohistochemical stains of right cervical lymph nodes were positive for EGFR, ALK, PD-L1, P40, CK7, CD10, CK5/6, CK pan, and Ki67 proliferative index was about 60%, and negative for TTF-1, PD-1, Napsin A and CK20, combined with the initial H&E, this cervical lymph nodes tend to origin from poorly differentiated squamous cell carcinoma. According to the findings of PET/CT, thyroid ultrasonography and histopathology, the patient was diagnosed as lung squamous cell carcinoma with extensive metastases. Except the immunohistochemical stains marker of PAX8, other markers were all consistent with lung squamous cell carcinoma, leading to misdiagnosis of this case two years ago.

The most common genetic alterations in thyroid carcinoma associated with mitogen-activated protein kinase (MAPK) and phosphoinositide-3-kinase (PI3K), activated by tyrosine kinase receptors, promote the progression of DTC. Further genetic events, especially involving p53, epigenetic alteration, and infiltration of immune cells, promote the onset of ATC [22]. In this case, NGS testing demonstrated that TP53 and EGFR mutations with tumor mutational burden (TMB) of 2.99 mutations/Mb. The tumor suppressor TP53 is a transcription factor involved in the control of the cell cycle and apoptosis, with the high

prevalence of TP53 mutations in ATCs (40–80%) for promoting tumor progression [23, 24]. EGFR is overexpressed in the majority of ATC. Epidermal growth factor (EGF), as its ligand, activates a signaling cascade that results in the enhanced migration and invasiveness of thyroid carcinoma[25]. Although ATCs have an approximately sixfold higher TMB than PTC, most ATCs do not meet the formal criterion for high TMB (> 10 mutations/Mb), which is consistent with this case [1].

Recent years, the median overall survival of patients with ATC has an obvious increase due to the treatment of ATC by primarily palliation and hospice care to effective molecular-based personalized therapies (such as targeted therapy, immunotherapy drugs and neoadjuvant therapy) and surgery when appropriate, regardless of disease stage [3]. Pembrolizumab, as a monoclonal antibody against the PD-1 receptor, approved by the FDA in the treatment of several cancers[2]. Some studies reported that pembrolizumab may be an effective salvage therapy added to kinase inhibitors or chemoradiotherapy at the time of progression on these drugs [8, 26]. Capdevila et al. demonstrated the efficacy of checkpoint blockade using inhibitors of the PD-1/PD-L1 axis in ATC [27]. In this case, the patient treated with pembrolizumab twice and the overall survival was more than 24 months, which is far longer than the median overall survival of ATC, indicating the cancer immunotherapy maybe play an important role in treating advanced ATC.

Conclusion

ATC is an extremely rare and aggressive tumor, has various morphological manifestations, leading to difficulty in distinguishing it from benign nodules by preoperative radiological imaging. Our case presents the radiological images of ultrasonography, PET/CT and CT for ATC, suggesting that preoperative multimodal radiological tests should be performed expeditiously for suspicious patient of ATC. If the ATC could be identified at the early stage and combined with highly specialized personalized therapies, the survival time of ATC maybe can further extend.

Declarations

Data availability

No datasets were generated or analyzed for this study.

Ethics statement

This study represents a case report. All the procedures in this case were conducted according to guidelines and according to clinical practice. All procedures performed in studies involving human participants were in accordance with the ethical standards of the Ethics Committee of Second Xiangya Hospital, Central South University, China and with the 1964 Helsinki declaration and its later amendments or comparable ethical standards. A written informed consent was obtained from the patient for the publication of this case report and any potentially-identifying images/information.

Author contributions

All authors listed have made a substantial, direct and intellectual contribution to the work, and approved for publication.

Funding

This project was funded by the National Natural Science Foundation of China (81974267) and the Science and Technology Innovation Program of Hunan Province (2021RC3033).

Conflict of Interest Disclosures

The authors declare that the research was conducted in the absence of any commercial or financial relationships that could be construed as a potential conflict of interest.

References

1. Bible KC, Kebebew E, Brierley J, Brito JP, Cabanillas ME, Clark TJ, Jr., Di Cristofano A, Foote R, Giordano T, Kasperbauer J *et al*: **2021 American Thyroid Association Guidelines for Management of Patients with Anaplastic Thyroid Cancer**. Thyroid 2021, **31**(3):337–386.
2. Lim AM, Solomon BJ: **Immunotherapy for Anaplastic Thyroid Carcinoma**. J Clin Oncol 2020, **38**(23):2603–2604.
3. Maniakas A, Dadu R, Busaidy NL, Wang JR, Ferrarotto R, Lu C, Williams MD, Gunn GB, Hofmann MC, Cote G *et al*: **Evaluation of Overall Survival in Patients With Anaplastic Thyroid Carcinoma, 2000–2019**. JAMA Oncol 2020, **6**(9):1397–1404.
4. Lin B, Ma H, Ma M, Zhang Z, Sun Z, Hsieh IY, Okenwa O, Guan H, Li J, Lv W: **The incidence and survival analysis for anaplastic thyroid cancer: a SEER database analysis**. Am J Transl Res 2019, **11**(9):5888–5896.
5. Haugen BR, Alexander EK, Bible KC, Doherty GM, Mandel SJ, Nikiforov YE, Pacini F, Randolph GW, Sawka AM, Schlumberger M *et al*: **2015 American Thyroid Association Management Guidelines for Adult Patients with Thyroid Nodules and Differentiated Thyroid Cancer: The American Thyroid Association Guidelines Task Force on Thyroid Nodules and Differentiated Thyroid Cancer**. Thyroid 2016, **26**(1):1–133.
6. Hahn SY, Shin JH: **Description and Comparison of the Sonographic Characteristics of Poorly Differentiated Thyroid Carcinoma and Anaplastic Thyroid Carcinoma**. J Ultrasound Med 2016, **35**(9):1873–1879.
7. Kwak JY, Han KH, Yoon JH, Moon HJ, Son EJ, Park SH, Jung HK, Choi JS, Kim BM, Kim EK: **Thyroid imaging reporting and data system for US features of nodules: a step in establishing better stratification of cancer risk**. Radiology 2011, **260**(3):892–899.
8. Iyer PC, Dadu R, Gule-Monroe M, Busaidy NL, Ferrarotto R, Habra MA, Zafereo M, Williams MD, Gunn GB, Grosu H *et al*: **Salvage pembrolizumab added to kinase inhibitor therapy for the treatment of**

anaplastic thyroid carcinoma. J Immunother Cancer 2018, **6**(1):68.

9. Lamartina L, Grani G, Arvat E, Nervo A, Zatelli MC, Rossi R, Puxeddu E, Morelli S, Torlontano M, Massa M *et al*: **8th edition of the AJCC/TNM staging system of thyroid cancer**: **what to expect** (**ITCO#2**). *Endocr Relat Cancer* 2018, **25**(3):L7-L11.
10. Lebastchi AH, Callender GG: **Thyroid cancer**. Curr Probl Cancer 2014, **38**(2):48–74.
11. Tessler FN, Middleton WD, Grant EG, Hoang JK, Berland LL, Teefey SA, Cronan JJ, Beland MD, Desser TS, Frates MC *et al*: **ACR Thyroid Imaging, Reporting and Data System (TI-RADS): White Paper of the ACR TI-RADS Committee**. J Am Coll Radiol 2017, **14**(5):587–595.
12. Bogsrud TV, Karantanis D, Nathan MA, Mullan BP, Wiseman GA, Kasperbauer JL, Reading CC, Hay ID, Lowe VJ: **18F-FDG PET in the management of patients with anaplastic thyroid carcinoma**. Thyroid 2008, **18**(7):713–719.
13. Nguyen BD, Ram PC: **PET/CT staging and posttherapeutic monitoring of anaplastic thyroid carcinoma**. Clin Nucl Med 2007, **32**(2):145–149.
14. Miyakoshi A, Dalley RW, Anzai Y: **Magnetic resonance imaging of thyroid cancer**. Top Magn Reson Imaging 2007, **18**(4):293–302.
15. Mosci C, Iagaru A: **PET/CT imaging of thyroid cancer**. Clin Nucl Med 2011, **36**(12):e180-185.
16. Yurkiewicz IR, Ganjoo KN, Iagaru A: **Anaplastic Thyroid Cancer With Extensive Skeletal Muscle Metastases on 18F-FDG PET/CT**. Clin Nucl Med 2018, **43**(4):e113-e114.
17. Begum S, Rosenbaum E, Henrique R, Cohen Y, Sidransky D, Westra WH: **BRAF mutations in anaplastic thyroid carcinoma: implications for tumor origin, diagnosis and treatment**. Mod Pathol 2004, **17**(11):1359–1363.
18. Deeken-Draisey A, Yang GY, Gao J, Alexiev BA: **Anaplastic thyroid carcinoma: an epidemiologic, histologic, immunohistochemical, and molecular single-institution study**. Hum Pathol 2018, **82**:140–148.
19. Ragazzi M, Ciarrocchi A, Sancisi V, Gandolfi G, Bisagni A, Piana S: **Update on anaplastic thyroid carcinoma: morphological, molecular, and genetic features of the most aggressive thyroid cancer**. Int J Endocrinol 2014, **2014**:790834.
20. Takano T, Ito Y, Matsuzuka F, Miya A, Kobayashi K, Yoshida H, Miyauchi A: **Quantitative measurement of telomerase reverse transcriptase, thyroglobulin and thyroid transcription factor 1 mRNAs in anaplastic thyroid carcinoma tissues and cell lines**. Oncol Rep 2007, **18**(3):715–720.
21. Bishop JA, Sharma R, Westra WH: **PAX8 immunostaining of anaplastic thyroid carcinoma: a reliable means of discerning thyroid origin for undifferentiated tumors of the head and neck**. Hum Pathol 2011, **42**(12):1873–1877.
22. Lorusso L, Cappagli V, Valerio L, Giani C, Viola D, Puleo L, Gambale C, Minaldi E, Campopiano MC, Matrone A *et al*: **Thyroid Cancers: From Surgery to Current and Future Systemic Therapies through Their Molecular Identities**. Int J Mol Sci 2021, **22**(6).

23. Tirro E, Martorana F, Romano C, Vitale SR, Motta G, Di Gregorio S, Massimino M, Pennisi MS, Stella S, Puma A *et al*: **Molecular Alterations in Thyroid Cancer: From Bench to Clinical Practice**. Genes (Basel) 2019, **10**(9).
24. Prete A, Matrone A, Gambale C, Torregrossa L, Minaldi E, Romei C, Ciampi R, Molinaro E, Elisei R: **Poorly Differentiated and Anaplastic Thyroid Cancer: Insights into Genomics, Microenvironment and New Drugs**. Cancers (Basel) 2021, **13**(13).
25. Zhang Z, Liu ZB, Ren WM, Ye XG, Zhang YY: **The miR-200 family regulates the epithelial-mesenchymal transition induced by EGF/EGFR in anaplastic thyroid cancer cells**. Int J Mol Med 2012, **30**(4):856–862.
26. Chintakuntlawar AV, Yin J, Foote RL, Kasperbauer JL, Rivera M, Asmus E, Garces NI, Janus JR, Liu M, Ma DJ *et al*: **A Phase 2 Study of Pembrolizumab Combined with Chemoradiotherapy as Initial Treatment for Anaplastic Thyroid Cancer**. Thyroid 2019, **29**(11):1615–1622.
27. Capdevila J, Wirth LJ, Ernst T, Ponce Aix S, Lin CC, Ramlau R, Butler MO, Delord JP, Gelderblom H, Ascierto PA *et al*: **PD-1 Blockade in Anaplastic Thyroid Carcinoma**. J Clin Oncol 2020, **38**(23):2620–2627.

Figures

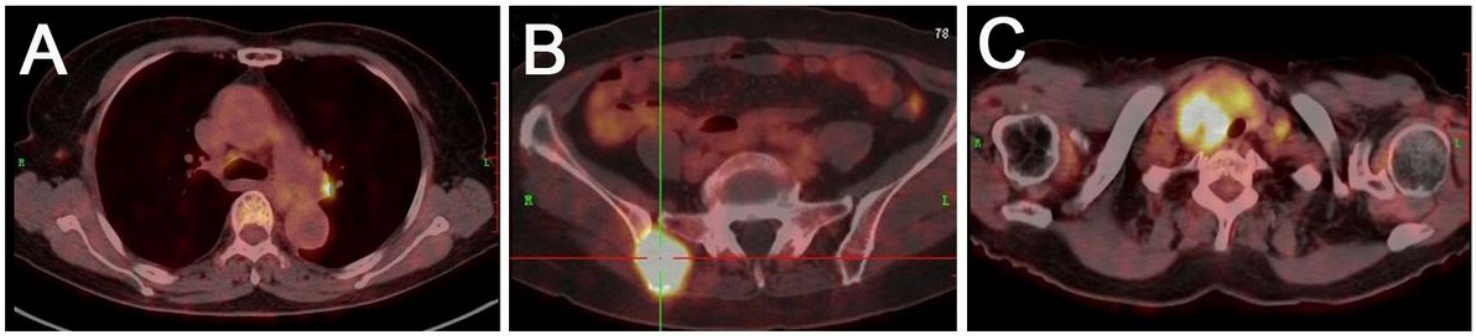

Figure 1

PET/CT images of the lung, ilium and thyroid of the patient. (A) Increased 18F-FDG metabolism showed in the left upper lobe of the lung. (B) Increased 18F-FDG metabolism showed in the right ilium. (C) Increased 18F-FDG metabolism showed in the right lobe of the thyroid and cervical lymph nodes.

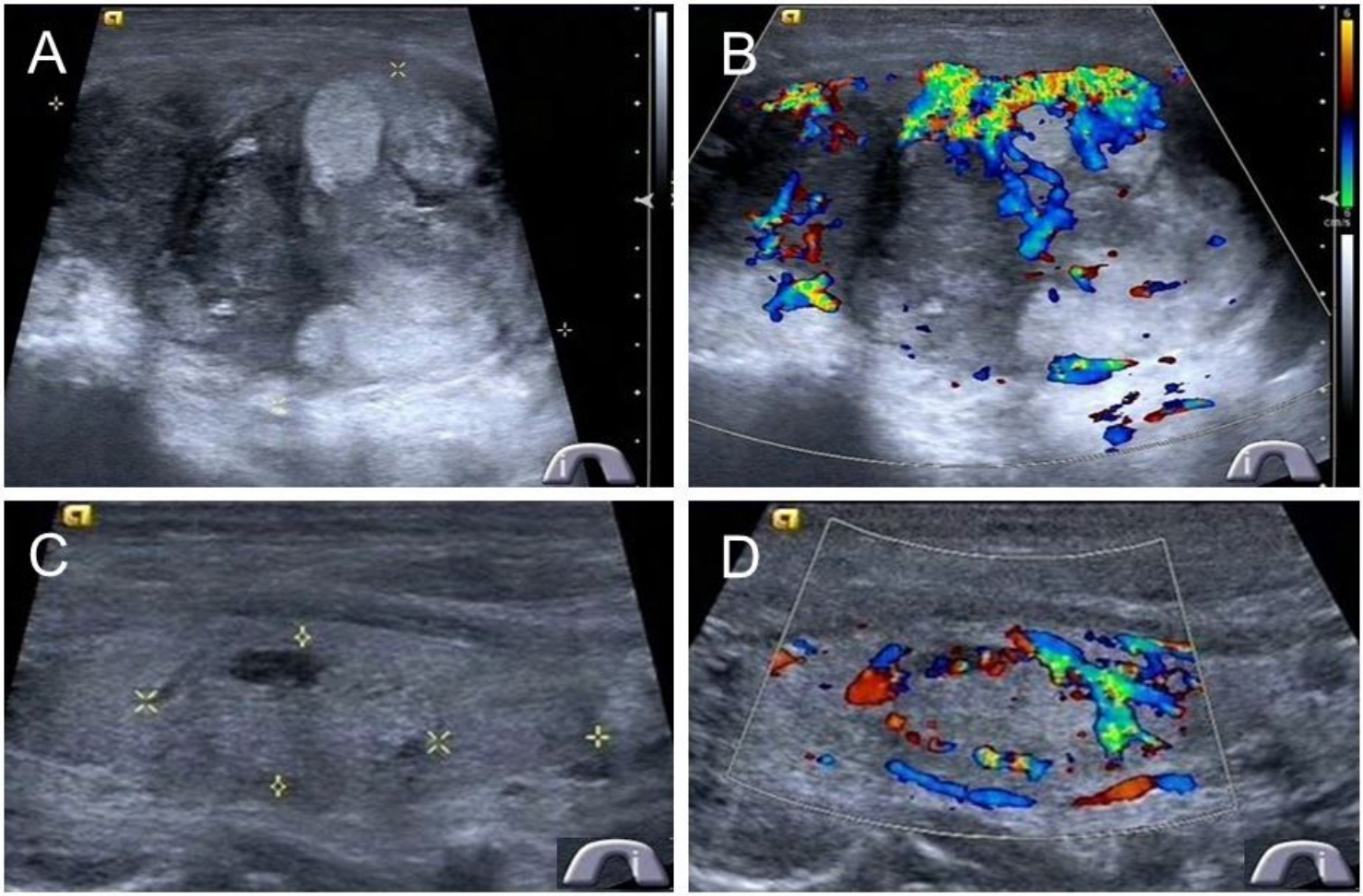

Figure 2

Ultrasonographic images of the bilateral thyroid nodules. (A) Longitudinal gray-scale sonography revealed a heterogeneous echoic thyroid mass in the right lobe. (B) CDFI showed a rich blood flow signal inside this mass. (C) Longitudinal gray-scale sonography revealed a mixed- echoic thyroid nodule in the left lobe. (D) CDFI showed a rich blood flow signal around this nodule.

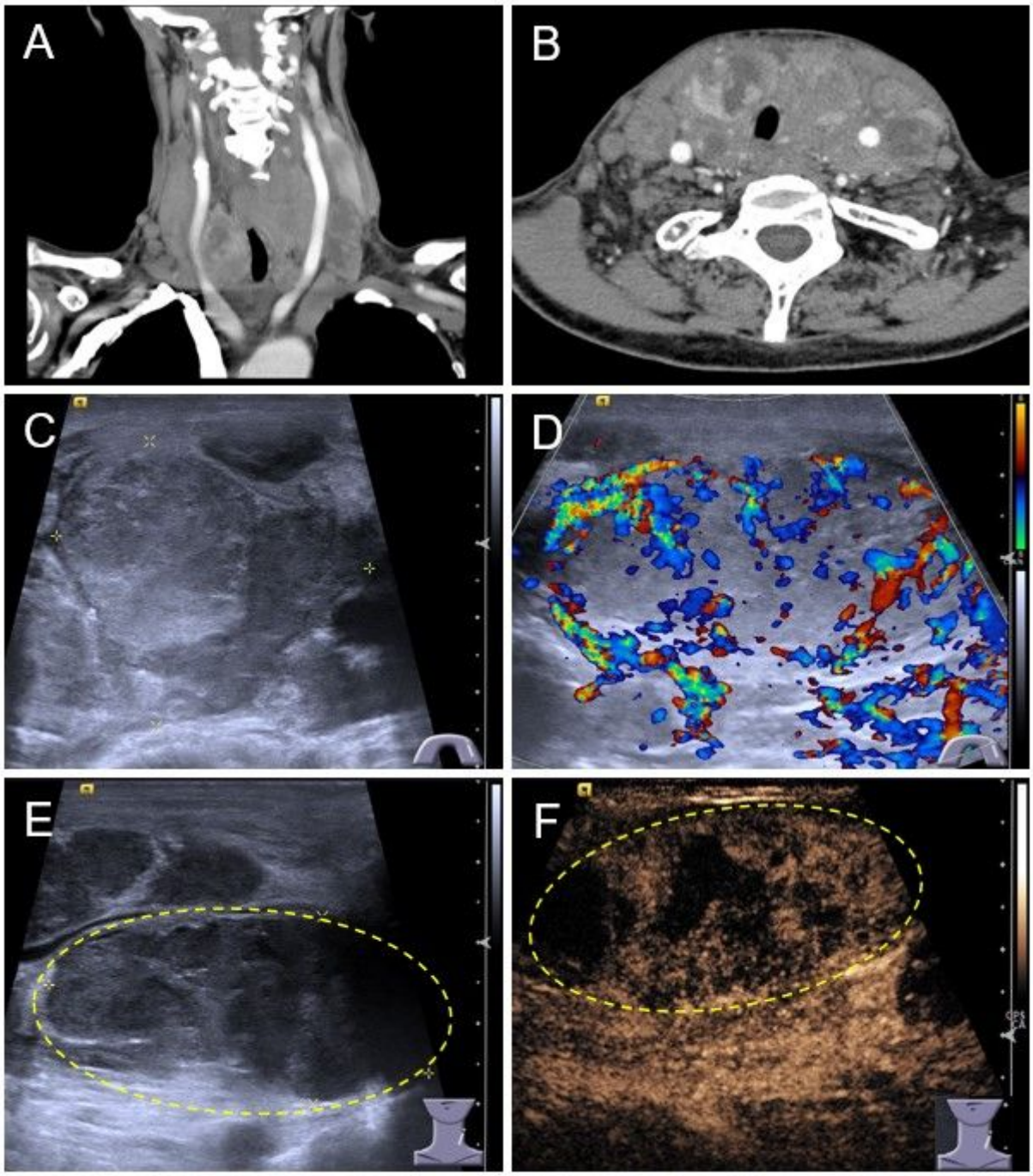

Figure 3

CT and ultrasonographic images of the neck before surgery. (A) Coronal and (B) axial sections of the neck revealed swelled thyroid with lots of large thyroid nodules and multiple enlarged cervical lymph nodes. (C) Gray-scale sonography revealed a solid heterogeneous echoic thyroid mass in the left lobe. (D) CDFI showed a rich blood flow signal inside and around this mass. (E) Gray-scale sonography demonstrated multiple enlarged lateral cervical lymph nodes in the left neck. (F) CEUS image showed a heterogeneous enhancement of the lymph node.

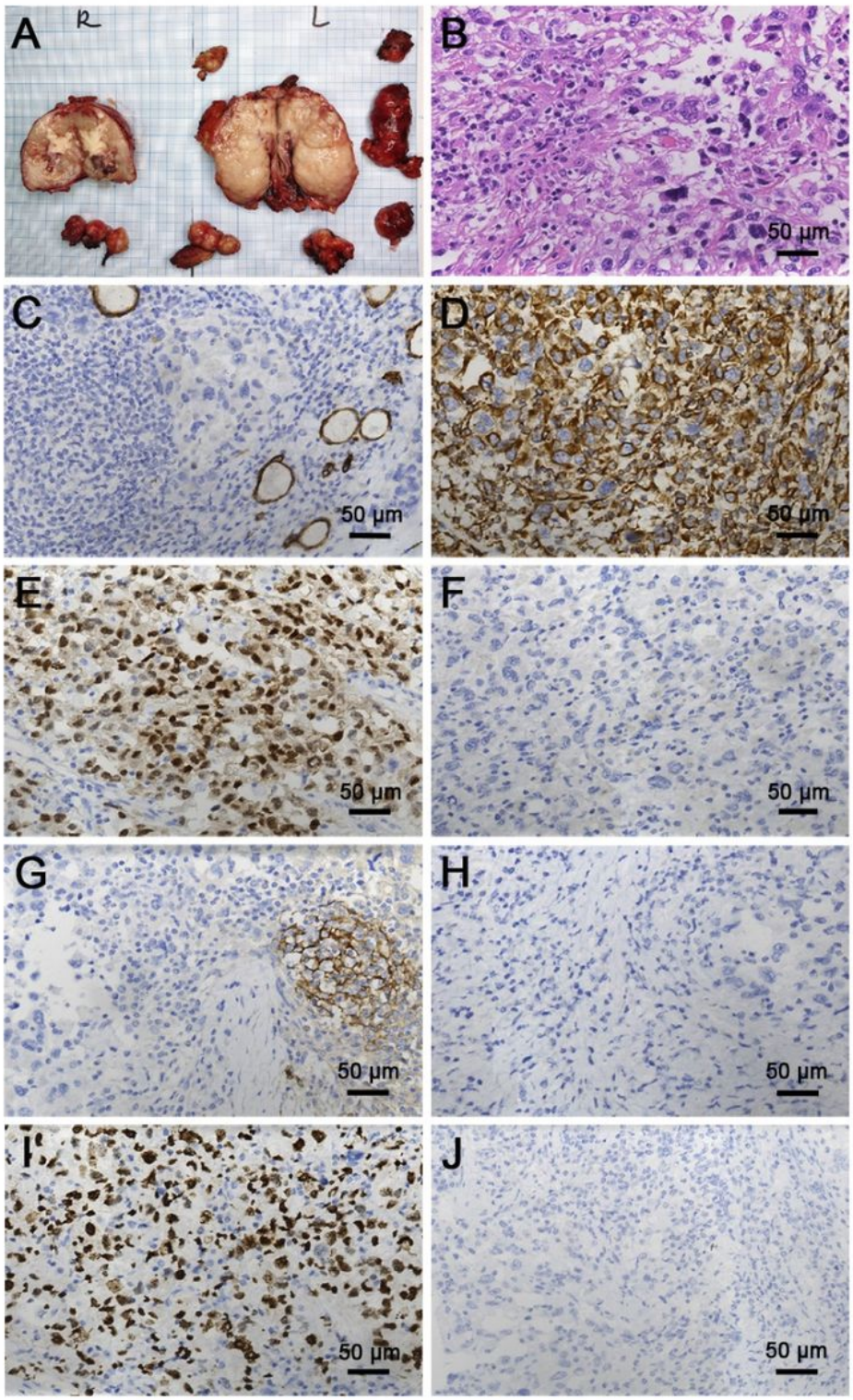

Figure 4

Gross surgical specimen and histopathological sections of anaplastic thyroid carcinoma. (A) Gross surgical specimen of the bilateral thyroid lobes. (B) H&E staining of anaplastic thyroid carcinoma, magnification × 400. Immunohistochemical (IHC) staining of anaplastic thyroid carcinoma (magnification × 400) for (C) CK5/6, (D) Vimentin, (E) PAX-8, (F) TTF-1, (G) TG, (H) Napsin A, (I) Ki67, (J) Calcitonin, and CK5/6 and TG were partially stained (partial positive), Vimentin and PAX-8 were deeply

stained (positive), Ki67 proliferation index was 60%, TTF-1, Napsin A and Calcitonin didn’t stain (negative).

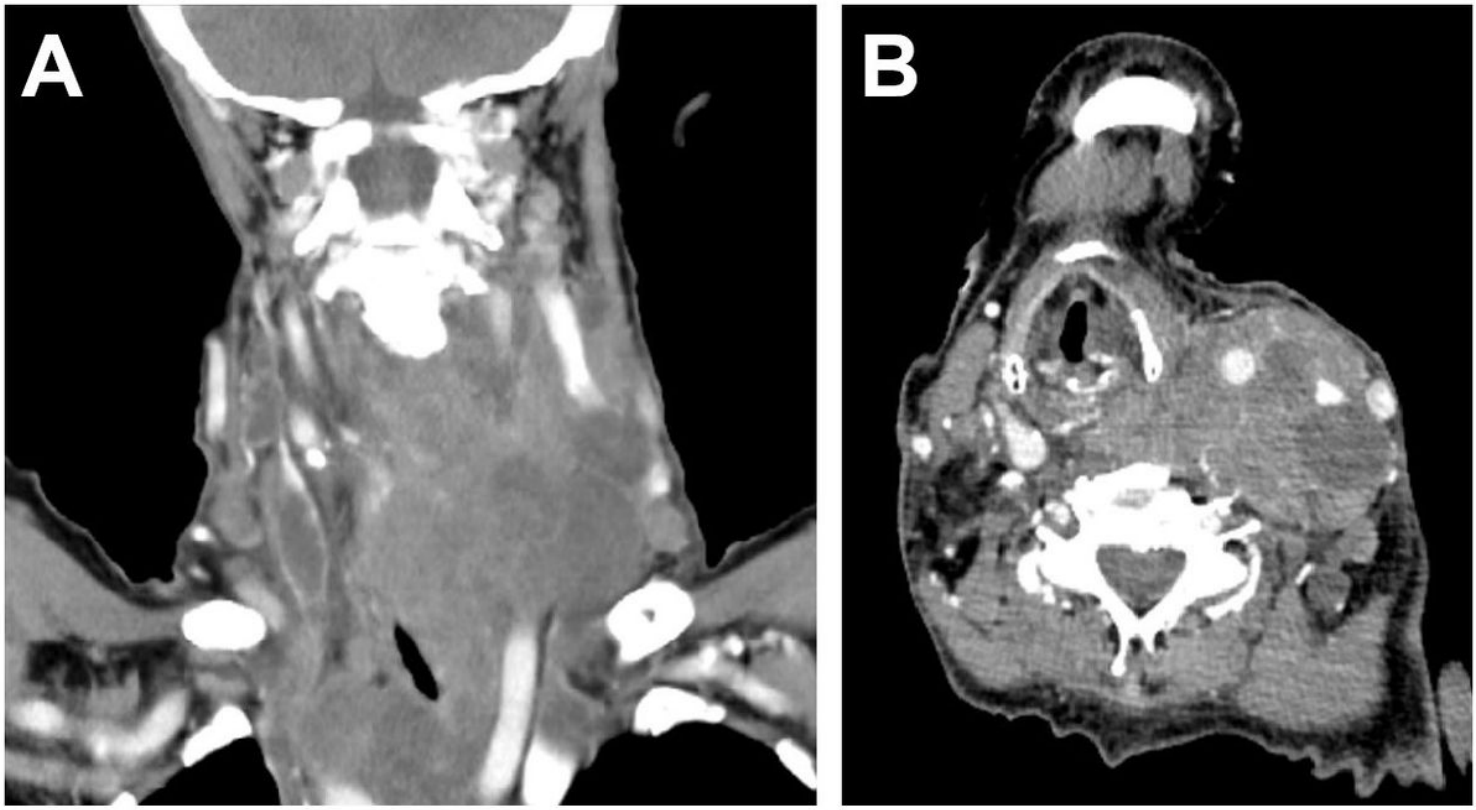

Figure 5

CT images of the neck after surgery 6 weeks. (A) Coronal and (B) axial planes of the neck revealed multiple enlarged cervical lymph nodes in the left neck.