Early postoperative hydrocephalus and its management after resection of vestibular schwannomas using the suboccipital retrosigmoid approach

Kamil Krystkiewicz (kamil.krystkiewicz@gmail.com)
Copernicus Memorial Hospital
Dawid Wrona
Copernicus Memorial Hospital
Marcin Tosik
Copernicus Memorial Hospital
Marcin Birski
10 th Military Clinical Hospital
Łukasz Szylberg
Collegium Medicum in Bydgoszcz, Nicolaus Copernicus University
Anna Morawska
10 th Military Clinical Hospital
Jacek Furtak
10 th Military Clinical Hospital
Cezary Wałęsa
10 th Military Clinical Hospital
Konrad Stopa
10 th Military Clinical Hospital
Marek Harat
Collegium Medicum of the Nicolaus Copernicus University

Research Article

Keywords: hydrocephalus, obstructive hydrocephalus, vestibular schwannoma, suboccipital retrosigmoid approach, external ventricular drainage

Posted Date: April 14th, 2022

DOI: https://doi.org/10.21203/rs.3.rs-1538563/v1

Abstract

Background

A hydrocephalus is one of the clinical presentations of large vestibular schwannomas. However, the literature lacks data concerning early postoperative hydrocephalus in that group of patients and its late consequences.

Methods

Retrospective analysis of the past medical records and radiological examinations of 116 patients.

Results

In 6 patients (5%), external ventricular drainage was employed postoperatively - in 2 patients on the first, in 3 cases on the second and in 1 case on the fourth day after the surgery. One patient developed a postoperative hematoma, in another one massive edema of the cerebellar hemisphere was found. In 4 cases, some degree of edematous changes in the cerebellar hemisphere were noted. Based on the clinical course, the patients were divided into 2 groups. The first one showed mild signs of intracranial hypertension. The second one developed a deep and rapid deterioration in the consciousness state. In the second group, drainage was maintained for 11 and 14 days. One patient died on the 11th postoperative day and in another case a ventriculoperitoneal shunt was placed. In the first group, drainage was removed on the 5th postoperative day in all cases. There were no complications related to that procedure. There was no correlation between age, size of the tumor, preoperative cerebellar edema, extent of the resection, preoperative size of the ventricles, cystic component of the tumor and preoperative obstruction of the aqueduct and postoperative hydrocephalus. The patients with postoperative hydrocephalus were hospitalized longer than the control group (p=0.001).

Conclusions

Two groups of patients with postoperative hydrocephalus were noted: the first one with acute and the second one with mild signs of intracranial hypertension. The presence of postoperative hydrocephalus does not depend on the analyzed preoperative factors.

Introduction

Hydrocephalus in one of clinical presentations of vestibular schwannoma (VS). It could be obstructive or communicating [1, 2]. From a historical point of view, obstructive hydrocephalus used to be more common than nowadays and its mechanisms are easily understood. Wide application of MRI reveals more cases with dilated ventricles and no proof of the cerebral aqueduct or 4th ventricle outlet compression by the tumor. That entity could be seen in 1.2–42% of cases [3–6]. Some authors advocate a treatment of hydrocephalus before the tumor resection, some of them perform resection at the first instance [2]. There are several options of hydrocephalus treatment in such cases – ventriculoperitoneal shunt (VPS), external ventricular drainage (EVD), or endoscopic third ventriculostomy. However, the literature lacks information about the postoperative hydrocephalus, which develops in the early postoperative course. There is no analysis of the risk factors, management and long follow-up, concerning the necessity of cerebrospinal fluid (CSF) diverging surgeries.

This is why we would like to present a study based on our experience of treating early postoperative hydrocephalus after the vestibular schwannoma resection.

Methods

Data source and study design

We analyzed retrospectively all patients operated on due to a cerebellopontine occupying lesion using suboccipital restrosigmoid approach in the single institution between January 2014 and June 2020. All patients were operated on in the supine position with the head rotated contralaterally. The inclusion criteria were: 1) histopathological confirmation of a schwannoma of the vestibular nerve, 2) ≥ 18 years of age, 3) exclusively retrosigmoid suboccipital craniotomy or craniectomy, translabyrinthine or middle fossa approaches were not analyzed 4) reoperation, second stage surgery, revision surgeries were excluded from the analysis, 4) preoperative and postoperative radiological imaging available, 5) at least one year follow-up.

Medical data base was researched using the D33.3 code from the International Statistical Classification of Diseases and Related Health Problems ICD-10. Patients with lesions occupying the cerebellopontine angle and histopathological confirmation of vestibular schwannoma were included into the study. Their age, size of the tumor, preoperative peritumoral edema (PTE), extent of the resection, preoperative size of the ventricles, cystic component of the tumor and preoperative obstruction of the aqueduct as well as postoperative hydrocephalus, symptoms of intracranial hypertension (headache, vomiting, disturbance of consciousness), length of hospitalization, intervention and complications were taken into analysis. The size and volume of the tumor were measured using the commercial software included in the neuronavigation system (Cranial v 4.0, BrainLab, Germany).

Gadolinium-enhanced MRI scans using T1-weighted sequence without and with contrast, T2 sequence, FLAIR preoperatively and postoperatively in 1 to 3 days after the surgery are performed in our institution. When MRI cannot be applied during the first day, non-contrast CT after 24 h and MRI is performed when it is possible. Radiological investigations were analyzed independently by the first author (KK) and consulting neuroradiologists (KS,CW) and were focused on the size of the ventricles and postoperative changes, preoperative and postoperative tumor characteristics (size according to the Hannover grading system, preoperative and postoperative cerebellar or brainstem edema, cyst presence, volume) and the extent of resection. The length of hospitalization took into account the patients' stay both in the neurosurgical unit and in other units (neurology, rehabilitation).

The ventricles were evaluated pre- and postoperatively using the Evans score. Ventricles with Evans score > 0.3 were categorized as enlarged. Each difference between the examinations was noted and compared to the clinical condition. Pre- and postoperative obstruction of the aqueduct and 4th ventricles outlets was evaluated. The surgical intervention used (EVD) was recorded with special concern on its length of application and complications. Long term follow-up of the patients with early postoperative hydrocephalus was conducted in the outpatient clinic. Because of the retrospective character of study, the patients' informed consent was not required. The Institutional Ethics Committee was informed about the ongoing study, and the Committee stated no need for its approval.

Statistical analysis

Continuous variables were presented as mean values with standard deviation. Univariate analyses were performed to compare the patient characteristics and the rate of complications between patients with and without hydrocephalus. Pearson's chi-square test and Fisher's exact test were used for the analysis of categorical data, in association with the occurrence of early postoperative hydrocephalus. Statistical significance was defined as a p-value of 0.05 or less.

Results

Patient and tumor characteristics

During the analyzed period of time, 116 patients met the inclusion criteria and were included in the analysis (Table 1.). Among these patients, 74 (64%) were women and 42 (36%) were men. The mean age was 47.3 ± 13.9 years. The mean tumor size was: 31.4 ± 11.4 mm in the anteroposterior dimension, 28.8 ± 9.8 mm in the mediolateral dimension, 28.6 ± 9.9 mm in the superior-inferior dimension. There were 63 tumors (54%) situated on the right side and 53 (46%) on the left side. The mean tumor volume was 13.73 ± 10.28 cm^3. According to the Hannover scale, 3 tumors (2.5%) were classified as grade T1, 3 (2.5%) as grade T2, 7 (6%) as grade T3a, 7 (6%) as grade T3b, 21(18%) as grade T4a and 67 as grade T4b (65%). The mean surgery time was 4 hours and 44 minutes ± 1 hour and 37 minutes. The mean length of stay (LOS) was 13.9 ± 9.8 days (range 6 to 76 days).

Table 1
Detailed analysis of patients, who needed EVD implantation.

	Sex	Age	Side	Hannover	Tumor volume	Evans preop.	Obturation	Edema preop.	Cysts	Degree of resection	Evans postop.	Edema postop.	Hematoma	Decreased consciousne
1.	F	57	Left	4b	12,7	27%	No	No	Yes	99%	29%	1	No	2
2.	M	28	Left	4b	17,76	27%	No	Yes	Yes	98%	30%	1	No	2
3.	M	54	Left	4b	2,39	37%	Yes	Yes	No	76%	40%	1	Yes	1
4.	M	34	Right	4b	35	25%	No	No	Yes	97%	26%	1	Yes	1
5.	F	55	Left	4a	5,73	22%	No	Yes	No	99%	25%	1	No	1
6.	F	56	Right	4a	16,3	28%	No	No	Yes	98%	30%	1	No	1

In 27 cases (23%), PTE around the tumor mass was seen. It was located in the cerebellar hemisphere or the middle cerebellar peduncle. For PTE evaluation purposes T2 and FLAIR sequence was used.

4 patients (3%) had VPS implanted before the tumor resection. All of those cases were operated on in other departments. In 1 (0.8%) case, endoscopic third ventriculostomy was performed preoperatively.

Hydrocephalus

Preoperative hydrocephalus was present in 18 cases (16%). Evident obstruction of the cerebral aqueduct and/or the 4th ventricle foramina was found in 11 cases (9%). In 7 cases (6%), there was no obstruction and the hydrocephalus was classified as communicating. The mean Evans index in the whole group was 0.28 ± 0.05. Regarding the hydrocephalic cases only, the mean Evans index was 0.33 ± 0.03.

Postoperative enlargement of the ventricles size was noted in 14 cases (12%), however, only in 8 cases (57% of that group, 7% regarding the whole cohort) disturbances of consciousness were observed. The remaining patients were asymptomatic with respect to the state of consciousness and ventriculomegaly was noted only in routine postoperative imaging. Headaches, nausea, vomiting as signs of increased intracranial pressure (ICP) were not specific and were noted also in the group with no ventriculomegaly and radiological signs of increased ICP.

Based on the pattern of consciousness decline we could distinguish 2 different clinical groups of patients with postoperative ventriculomegaly.

In 6 cases, we observed a mild decline of consciousness – rated as 13 and 14 Glasgow Coma Scale (GCS) points.

In 2 cases a severe deterioration was observed – less than 12 GCS points. Either group will be discussed separately.

Type I characteristics

All patients developed ventriculomegaly as compared to the preoperative imaging, however, in all cases supratentorial CSF reserve on the convexity was preserved. What is noteworthy, we have never noticed periventricular leukomalacia in that group. In every case there was edema of the ipsilateral cerebellar hemisphere, causing larger mass effect and displacement of the 4th ventricle than in the preoperative imaging (Fig. 1). No hematoma was noted.

In 2 (33%) cases in that group, the decline of consciousness was mild and patients were rated as 14 points in the GCS. Anti-edema therapy was employed with clinical improvement and these patients underwent conservative management.

In 4 patients anti-edema therapy was not successful and in those cases operative treatment was chosen. In 2 patients clinical worsening was noted on the 2nd postoperative day (POD), in 1 case on the 3rd POD and in the last one on the 4th POD. However, ventricular size enlargement and edema in the cerebellar hemisphere was noted in the MRI in the 1st POD in every case. In all of those cases external ventricular drainage was implanted. All patients improved immediately after the surgery. The drainage was removed after 5 days in every case. There were no complications related to the surgical procedure, nor the CNS infection. None of the patients needed other CSF diversion procedures during late follow-up.

Type II characteristics

The group consisted of 2 patients (Fig. 2.). In both cases the CSF reserve on the brain convexity was markedly reduced and in all cases supratentorial periventricular leukomalacia was seen. Extensive mass effect in the posterior fossa was observed in each case. One patient developed a postoperative hematoma in the postresection cavity and sudden comatose state several hours after extubation in the postoperative care unit. An extensive hematoma causing obstructive hydrocephalus was found in the postresection cavity in CT examination. The patient was immediately operated on – the EVD was implanted and the hematoma was removed. After the surgery the patient was in good clinical and neurological condition. The EVD was maintained for 14 days without complications. However, he developed communicating hydrocephalus and was scheduled to the VPS implantation.

In the second case, the patient developed coma and respiratory arrest on the 1st POD. A cerebellar edema, intracerebellar hemorrhage and obstructive hydrocephalus were found in CT investigation. He was reoperated emergently, posterior fossa decompression and external ventricular catheter were employed. After 14 days of treatment in the ICU the patient died. The cases which needed the EVD surgery are presented in Table 1.

Early postoperative hydrocephalus

There were no differences between the groups with and without early postoperative hydrocephalus regarding the age, size of the tumor, volume of the tumor, sex, preoperative Evans score, extent of resection of the tumor, PTE, preoperative obstruction of the ventricular system, cystic appearance of the tumor (Table 2.). The patients who were operated on and had EVD had statistically significantly larger postoperative ventricular system than the non-operated group (χ^2 p = 0.0015). Hematoma in the tumor bed was also a significant risk factor of EVD (χ^2 p = 0.0018). Moreover, group with the EVD was hospitalized significantly longer (U Mann Whitney test, p = 0.0019).

Table 2
Comparison between groups where EVD was not place and where there was a need for the EVD placement.

Variable	No EVD	EVD	Statistical analysis
	Average	Average	p
Length of hospitalization (days)	13,4 ± 9,8	19,6 ± 6,4	**0,0019** (U Mann-Whitney test)
Tumor volume (cm^3)	11,1 ± 10,2	15,2 ± 9,9	0,24 (U Mann-Whitney test)
Age (years)	47,5 ± 10,0	44,5 ± 12,0	0,59 (U Mann-Whitney test)
Anterior-posterior distance of tumor (mm)	30,78 ± 11,8	35,12 ± 5,91	0,27 (U Mann-Whitney test)
Left-right distance of tumor (mm)	28,6 ± 10,1	28,12 ± 6,96	0,88 (U Mann-Whitney test)
Superior-inferior distance of tumor (mm)	28,1 ± 10,2	32,12 ± 6,96	0,29 (U Mann-Whitney test)
Preoperative Evans ratio	0,28 ± 0.04	0,27 ± 0,05	0,70 (U Mann-Whitney test)
Degree of resection (%)	86 ± 22	86 ± 21	0,41 (U Mann-Whitney test)
Sex	Male – 39 (35%) Female – 71 (65%)	Male – 3 (50%) Female – 3 (50%)	p = 0.21, χ^2
Hannover scale	T1–3 (2%) T2–3 (2%) T3a – 7 (3%) T3b – 7 (4%) T4a – 19 (14%) T4b – 64 (75%)	T4a – 2 (33%) T4b – 4 (67%)	p = 0.95, χ^2
Cystic tumor	Yes – 23 (21%) No – 87 (79%)	Yes – 4 (67%) No – 2 (33%)	p = 0.18, χ^2
Obturation	Yes – 26 (24%) No – 84 (76%)	Yes – 1 (17%) No – 5 (83%)	p = 0.33, χ^2
Cerebellar edema	Yes – 26 (24%) No – 84 (76%)	Yes – 3 (50%) No – 3 (30%)	p = 0.21, χ^2
Extent of resection	GTR – 21 NTGR – 8 ST – 81	GTR – 0 NTGR – 0 ST – 6	p = 0.13, χ^2

Discussion

Hydrocephalus associated with vestibular schwannoma is a well described entity and its frequency varies between 1.2–42% [2–4, 7, 8]. Although the literature describes widely preoperative hydrocephalus and its management, there is no sufficient data about the early postoperative hydrocephalus.

Postoperative ventricles enlargement

In our institution we routinely perform preoperative MRI and postoperative MRI during the first 3 days after the surgery, or a CT examination during the 1 POD, if there is no possibility to perform MRI. We noticed that postoperative ventricles were larger in 14 cases (12%). However, only in 8 cases (57% of that group, 7% regarding the whole cohort) there were disturbances of consciousness. In 6 cases (5%), the EVD was placed, however, only 2 patients were in a severe condition (1%) and one of them died (0.5%). Huang et al. [9] had 14 cases (1.19%) of acute postoperative hydrocephalus, 8 of which were caused by a hemorrhage and 6 by cerebellar edema. However, the authors provide no further information about the outcome and clinical analysis in that group of patients. Mahboubi et al. [10] analyzed the overall complication rate in a group of 6553 cases operated on in California. Hydrocephalus was found in 3.6% of patients. Unfortunately, no further information could be found in that paper.

We have noticed that 42% of patients with postoperative ventriculomegaly did not have any signs of intracranial hypertension. That group of patients was managed conservatively using steroids (8 mg per day, twice a day) and mannitol (up to 1 g/kg, repeated q 6–8 hours). The rest of the patients in that group developed some signs of intracranial hypertension. Those patients could be divided into 2 distinct groups. The first one (type I hydrocephalus) was characterized by mild consciousness disturbances and some degree of edema in the ipsilateral cerebellar hemisphere. We observed 6 patients in that category. What is more, in 2 of them antiedema therapy was sufficient to improve the consciousness state and to control the symptoms. In 4 cases, pharmacological therapy was not successful, hence surgical treatment was employed. Still, all these patients were evaluated as 12 points or more in the GCS. In each case EVD was placed with immediate improvement after the surgery. All EVDs were removed on the 5th POD without further complications. The

second group (type II hydrocephalus) was characterized by a sudden and deep deterioration in the consciousness state, usually during the 1st POD. In our cohort, we observed one postoperative hematoma in the tumor bed and one case of large cerebellar hemisphere edema, probably due to venous stroke. In that group, there was a tendency for longer EVD duration and uncertain prognosis, depending on the cause of the hydrocephalus. In one case, there was a necessity to implant the VPS, because of posthemorrhagic communicating hydrocephalus.

Predictive factors for acute postoperative hydrocephalus evolution

Peritumoral edema is a reported radiological finding in VS. It could be visualized in 5–38% of cases [11–13]. Its role and influence on the treatment is under recent evaluation. Guo et al. [11] found that peritumoral cerebellar edema is an independent risk factor of postoperative hematoma and a risk of reoperation after the VS resection. They also revealed that it is a factor influencing the extent of resection. Samii et al. [12] evaluated a similar topic and found that the presence of edema tends to be associated with a higher risk of the postoperative hematoma. However, the differences were not significant statistically. Cases with PTE seem to have no arachnoidal plane between neurovascular structures and tend to be more hypervascular [12]. Recent data [14] suggest that tumors with higher presentation of VEGF (Vascular Endothelial Growth Factor) are more prone to have edema in the surrounding nervous tissue. To our knowledge, there is no data about correlation between PTE and postoperative hydrocephalus. PTE was seen in 23% of cases, which fits in the cited data. However, we did not see a correlation between preoperative edema and postoperative hydrocephalus. What is more, other preoperative and intraoperative factors such as age, sex, size of the tumor, volume of the tumor, preoperative Evans score, extent of resection of the tumor, obstruction of the ventricular system, cystic appearance of the tumor did not increase the risk of postoperative hydrocephalus. Postoperative hematoma in the tumor bed is the only condition, which poses a risk for acute hydrocephalus.

Based on our results, it is impossible to predict which patients would be in the risk group of acute postoperative hydrocephalus. Surgical technique seems to play role only in prevention of the second type of hydrocephalus. Protection of venous structures and meticulous hemostasis are mandatory in those cases. However, we could not find any technical nuances preventing the hydrocephalus described as first type. We routinely preserve the arachnoid plane, whenever it is present. However, we did not find lack of the arachnoid plane as a risk factor of hydrocephalus.

In our institution we used an algorithm of clinical management in that group of patients. We routinely perform contrast-enhanced MRI within the first 72 h after the surgery, in most cases on the day after the surgery. If there is no possibility to assess MRI on that day, we provide a non-enhanced CT investigation. If the imaging studies reveal an enlargement of the ventricular system, any signs of posterior fossa edema or aqueduct obstruction and the patient scores more than 14 points in the GCS, we try to manage such cases conservatively with clinical observation and anti-edema medication. If there is no improvement in the neurological status during the 6–12 h we perform the EVD. If there is an improvement, we continue the wait and watch strategy for 3 days. After that time, we perform CT and try to taper the antiedema medication. If the patient is evaluated as less than 14 points we place EVD and provide antiedema medication. Patients in the second group, with sudden loss of consciousness or a failure to regain it after anesthesia are candidates for urgent CT examination and neurosurgical evaluation – EVD and posterior fossa decompression, or hematoma evacuation.

Prognosis

As it follows from our experience, the patients qualified into the first group of postoperative hydrocephalus have good prognosis. Placement of the EVD is a procedure with low risk of complications. They usually need a short term maintenance of the drainage. In all of the cases in that group, EVD was removed on the 5th POD. That kind of hydrocephalus seems to pose no risk for further CSF diversion surgeries. None of the cases needed a VP shunt in late observation. Patients in the second group have uncertain prognosis, depending on the cause of the hydrocephalus. In our cohort we observed 2 patients in that group. One case was fatal because of prominent cerebellar edema, probably caused by venous infarction. The other case was an example of hematoma in the tumor bed, which necessitated VP after 2 weeks. In the late follow-up, the patient was evaluated as grade 0 in the mRankin scale. Based on our results, further CSF diversion surgeries depend on the cause of the postoperative hydrocephalus. Benign cases in the first group need only a temporary diversion surgery. The second group seems to be inhomogeneous in the etiology of hydrocephalus.

Definition

To our best knowledge, there is no accepted definition of acute postoperative hydrocephalus after VS resection. Based on our results, we could point out some typical characteristics of that condition. First of all, it is always obstructive in its pathophysiological mechanism. Postoperative edema of the ipsilateral cerebellar hemisphere, or a hematoma-like extracerebellar mass causes obstruction of CSF flow at the level of the aqueduct or the foramen of Luschka. What is more, some degree of intracranial hypertension signs must be present to diagnose the hydrocephalus. It is crucial, because 42% of cases with marked postoperative ventriculomegaly are asymptomatic and do not need surgical treatment. The signs of intracranial hypertension could be benign, like persistent headache not responding to pain medications or mild disturbances of consciousness, or severe like coma. We did not observe the hydrocephalus after the first 4 POD. On the basis of these findings, we could propose a definition of the early postoperative hydrocephalus after VS surgery. It is a condition after resection of the VS with marked symptomatic postoperative ventriculomegaly, caused by obstruction of the CSF flow in the posterior fossa during the first four POD.

Conclusions

Early postoperative hydrocephalus after VS surgery is always obstructive. Two types of clinical presentation, depending on the level of consciousness disturbances and radiological presentation, can be distinguished. The prognosis depends on which type is diagnosed. Both pharmacological and surgical treatment should be considered in the management of such cases.

Declarations

Ethical approval and Consent to participate

The Institutional Ethics Committee was informed about the ongoing study, and the Committee stated no need for its approval. Informed consent was obtained from all individual participants included in the study

Human and animal ethics

This study was performed in line with the principles of the Declaration of Helsinki. The Institutional Ethics Committee was informed about the ongoing study, and the Committee stated no need for its approval.

Consent for publication

Not applicable. No data, which could lead to identification of the patient (photographs, names) was used.
Availability of supporting data

Available

Conflicts of interest/Competing interests

The authors have no relevant financial or non-financial interests to disclose.

Funding

The authors did not receive support from any organization for the submitted work.

Authors' contributions:

Conceptualization: Kamil Krystkiewicz.
Methodology: Kamil Krystkiewicz.
Investigation: Kamil Krystkiewicz, Dawid Wrona, Marcin Tosik, Anna Morawska, Konrad Stopa, Cezary Wałęsa.
Formal analysis and investigation: Kamil Krystkiewicz, Marcin Birski, Łukasz Szylberg
Writing - original draft preparation: Kamil Krystkiewicz.
Writing - review and editing: Marcin Birski, Marcin Tosik, Marek Harat.
Resources: Kamil Krystkiewicz, Jacek Furtak, Marcin Birski, Marek Harat.
Supervision: Marek Harat.

Acknowledgements

None

Authors' information

Kamil Krystkiewicz, MD PhD, Address: Department of Neurosurgery and Neurooncology, Copernicus Memorial Hospital, Pabianicka 62, 95-513 Łódź, Poland

References

1. Rogg JM, Ahn SH, Tung GA, Reinert SE, Norén G (2005) Prevalence of hydrocephalus in 157 patients with vestibular schwannoma. *Neuroradiology.* 47(5):344–51. doi:10.1007/s00234-005-1363-y
2. di Russo P, Fava A, Vandenbulcke A, Miyakoshi A, Kohno M, Evins AI et al. (2021) Characteristics and management of hydrocephalus associated with vestibular schwannomas: a systematic review. *Neurosurg Rev.* 44(2):687–698. doi:10.1007/s10143-020-01287-2
3. Al Hinai Q, Zeitouni A, Sirhan D, Sinclair D, Melancon D, Richardson J et al. (2013) Communicating hydrocephalus and vestibular schwannomas: etiology, treatment, and long-term follow-up. *J Neurol Surg B Skull Base*. 74(2):68–74. doi:10.1055/s-0033-1333621
4. Fukuda M, Oishi M, Kawaguchi T, Watanabe M, Takao T, Tanaka R et al. (2007) Etiopathological factors related to hydrocephalus associated with vestibular schwannoma. *Neurosurgery.* 61(6):1186–1193. doi:10.1227/01.neu.0000306096.61012.22
5. Gerganov VM, Pirayesh A, Nouri M, Hore N, Luedemann WO, Oi S et al. (2011) Hydrocephalus associated with vestibular schwannomas: management options and factors predicting the outcome. *J Neurosurg.* 114:1209–1215. doi: 10.3171/2010.10.JNS1029.
6. Samii M, Matthies C. (1997) Management of 1000 vestibular schwannomas (acoustic neuromas): surgical management and results with an emphasis on complications and how to avoid them. *Neurosurgery.* 40(1):11–21. doi: 10.1097/00006123-199701000-00002.
7. Pirouzmand F, Tator CH, Rutka J. (2001) Management of hydrocephalus associated with vestibular schwannoma and other cerebellopontine angle tumors. *Neurosurgery.* 48(6):1246–53. doi: 10.1097/00006123-200106000-00010.
8. Briggs RJ, Shelton C, Kwartler JA, Hitselberger W. (1993) Management of hydrocephalus resulting from acoustic neuromas. *Otolaryngol Head Neck Surg.* 109(6):1020–4. doi: 10.1177/019459989310900608.
9. Huang X, Xu M, Xu J, Zhou L, Zhong P, Chen M et al. (2017) Complications and Management of Large Intracranial Vestibular Schwannomas via the Retrosigmoid Approach. *World Neurosurg.* 99:326–335. doi: 10.1016/j.wneu.2016.12.055.

10. Mahboubi H, Ahmed OH, Yau AY, Ahmed YC, Djalilian HR. (2014) Complications of surgery for sporadic vestibular schwannoma. *Otolaryngol Head Neck Surg.* 150(2):275–81. doi: 10.1177/0194599813512106.
11. Guo X, Zhu Y, Wang X, Xu K, Hong Y. (2021) Peritumoral Edema Is Associated With Postoperative Hemorrhage and Reoperation Following Vestibular Schwannoma Surgery. *Front Oncol.* 9;11:633350. doi: 10.3389/fonc.2021.633350.
12. Samii M, Giordano M, Metwali H, Almarzooq O, Samii A, Gerganov VM (2015) Prognostic Significance of Peritumoral Edema in Patients with Vestibular Schwannomas. *Neurosurgery.* 77(1):81–5. doi: 10.1227/NEU.0000000000000748.
13. Haque S, Hossain A, Quddus MA, Jahan MU (2011) Role of MRI in the evaluation of acoustic schwannoma and its comparison to histopathological findings. *Bangladesh Med Res Counc Bull.* 37(3):92–6. doi: 10.3329/bmrcb.v37i3.9120.
14. You HH, Chen XY, Chen JY, Bai Y, Chen FX (2021) The Relationship Between Peritumoral Brain Edema and the Expression of Vascular Endothelial Growth Factor in Vestibular Schwannoma. *Front Neurol.* 9;12:691378. doi: 10.3389/fneur.2021.691378.

Figures

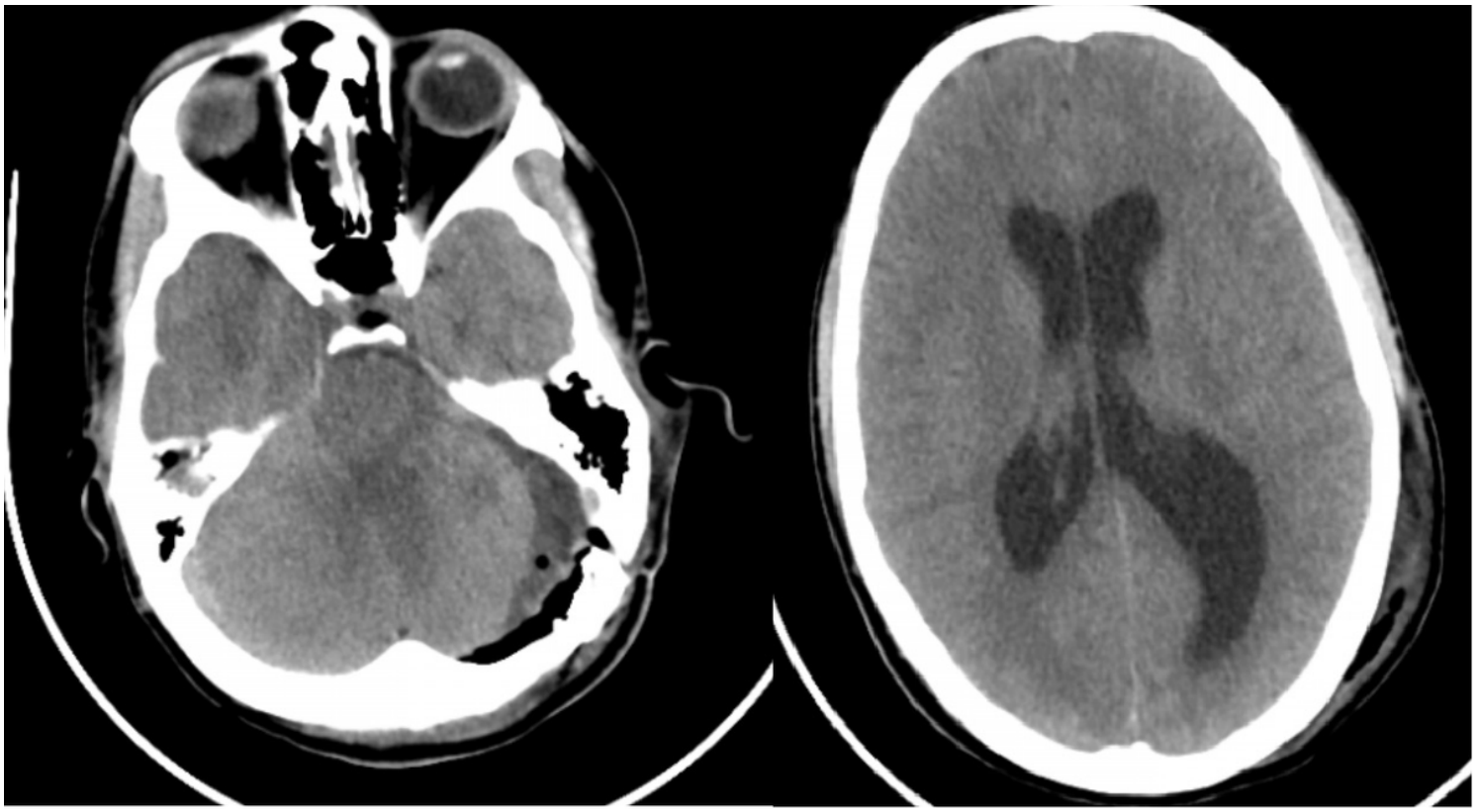

Figure 1

Example of the first group of postoperative hydrocephalus. Note mild edema in the left cerebellar hemisphere, compressed 4th ventricle and enlarged lateral ventricles.

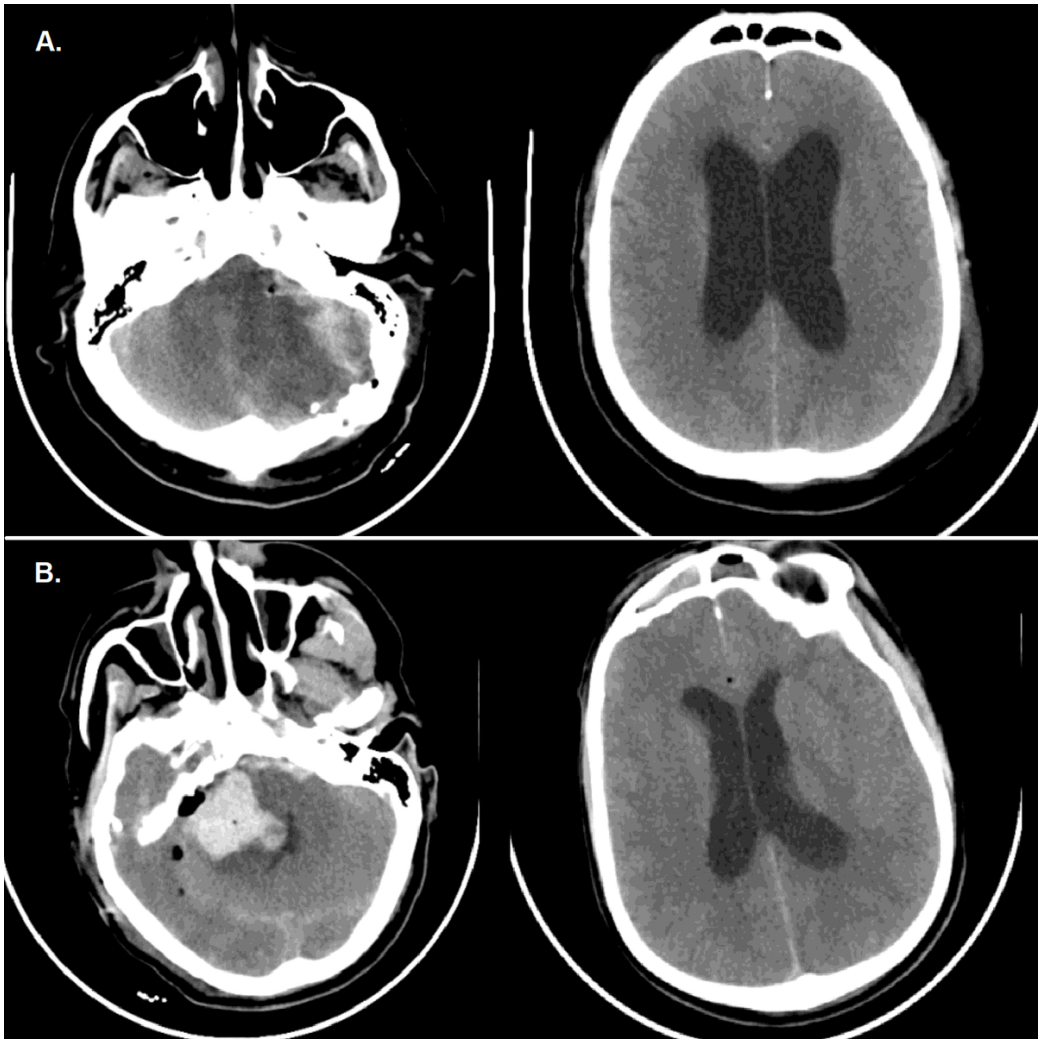

Figure 2

Upper. Case of the acute postoperative hydrocephalus classified as 2nd group. Note the marked edema and hemorrhagic changes in the left hemisphere associated with the venous stroke.

Lower. Hematoma in the post resection cavity. 4th ventricle is compressed but still visible.