Patient positioning during Extracorporeal Shock Wave Lithotripsy for distal ureteric stone: transgluteal vs transabdominal approach

Leonid Boyarsky (Dr.boyarsky@yahoo.com)
Hadassah Medical Center
Amitay Lorber
Hadassah Medical Center
Vladimir Yutkin
Hadassah Medical Center
Ofer Gofrit
Hadassah Medical Center
Mordechai Duvdevani
Hadassah Medical Center

Research Article

Keywords: Urolithiasis, Ureteral Stones, Extracorporeal Shock Wave Lithotripsy, Distal ureteral stone

Posted Date: April 11th, 2022

DOI: https://doi.org/10.21203/rs.3.rs-1540106/v1

Abstract

Objective

To evaluate the efficacy and the safety of transabdominal versus the transgluteal approach during extracorporeal shock wave lithotripsy (SWL) for distal ureteral calculi.

Material and methods

Retrospective analysis of 146 patients with a single distal ureteric stone, who underwent SWL in supine position, was performed. Stone dimensions, density, and the skin to stone distance (SSD) were obtained from preoperative computer tomography. In 76 cases, the procedure was performed using a transabdominal approach (Group 1). In 67 cases, SWL was performed via transgluteal approach, with shockwave source being placed below the patient (Group2). Stone-free rate (SFR), need for stenting, auxiliary procedures and complications rate was assessed for each group.

Results

Demographic characteristics and stone features were similar in both groups. The mean stone size was 6.14 (3.4-11.2) mm in group 1 and 6.17 (3.1-15.8) mm in group 2. The skin to stone distance was 114.23 ± 26.83 mm and 103.84 ± 14.69 mm for Group 1 and Group 2 respectively (p=0.004). The SFR was 54% and 85% for transabdominal and transgluteal approaches, respectively. (p=0.0004). Ureteral stenting was performed in 16% of transabdominal and in 4% of transgluteal interventions (p=0.03). Auxiliary intervention was performed in 25% of group 1 patients and in 8% of group 2. The complication rate was 16% and 7% for transabdominal and transgluteal and approaches, respectively. No serious postoperative complications were observed.

Conclusion

Supine, transgluteal position SWL for the distal ureteral stone had a higher stone-free-rate, lower complications rate and lower need stenting for additional procedures.

Introduction

Kidney stone disease is associated with substantial morbidity and has a significant economic burden on the health system in the western world [1]. Distal ureteral stones are a common cause of intervention [2].

The distal ureteral stones can be treated either by extracorporeal shockwave lithotripsy (SWL) or by ureteroscopy (URS) [3]. According to the AUA and EAU guidelines, both methods are acceptable as the primary approach, especially when the stone size is less than 10 mm [4, 5].

Distal ureteroscopy achieves superior success rates. However, the complication rate is slightly higher compared to SWL [6].

SWL is a less invasive procedure and can be performed in an outpatient setting using minimal sedation [7]. SWL can be used to treat stones localized anywhere along the ureter, as long as there is a path for the shockwave to reach the stone. The optimal SWL position to treat distal calculi is debatable.

A supine position, which is optimal for stones localized in the kidney or upper ureter, can be challenging when approaching lower ureteral stones. This is due to anatomical features of the bony pelvis which can, theoretically, interrupt the delivery of shockwaves to the distal ureter.

Since the beginning of the SWL era, it has been customary to treat patients with distal ureteral stones in the prone position. This was following the recommendations of SWL machines manufacturers [8, 9].

On the other hand, SWL for distal ureteral calculi in a prone position poses several problems, such as greater skin to stone distance (SSD), excessive intestinal gas, etc.

The purpose of this study is to evaluate the efficacy and the safety profile of transabdominal versus the transgluteal approach during SWL for distal ureteral calculi.

Methods

We retrospectively analyzed a total of 189 patients with a single distal ureteric stone, who underwent SWL in our institution using the Dornier Gemini lithotripter. Distal location was defined as stone located distal to the sacroiliac joint and proximal to the ureterovesical junction. Forty-six patients were excluded due to missing data and lack of computer tomography (CT) before treatment. All the patients were placed in the supine position during treatment. In 76 cases, the procedure was performed using a transabdominal approach (Group 1), during which the shock wave source is placed above the patient, while the shockwave propagates through the anterior abdomen (Figs. 1.1,1.2).

In the remaining 67 cases (Group 2), the source was placed below the patient, in the transgluteal position. In this case, the shock wave travels via the gluteus maximus muscle and through the greater sciatic foramen towards the stone in the distal ureter, thus not being reduced by the structure of the pelvic bones (Fig. 2).

The data were collected from digital medical files. Stone dimensions, density, and the SSD were obtained from preoperative non-contrast CT.

Stone-free state was defined as residual fragments less than 3 mm according to CT or kidney, ureter and bladder X-ray with ultrasound (KUB + US), performed 4–6 weeks after the treatment. A complication was defined as an episode of intractable pain, acute kidney injury, and post-procedural fever. An institutional review board (IRB) approval was obtained.

Results

The patient’s demographic characteristics and stone features were similar in both groups (Table 1).

Table 1
Demographic data

	Transabdominal (N = 76) (Group 1)			**Transgluteal (N = 67) (Group 2)**			
	N (%)	Mean ± SD	Range	N (%)	Mean ± SD	Range	p-value
Male (%)	67 (88.0)			56 (84.0)			0.4756
Age,years		48.9 ± 13.0	24–80		47.3 ± 11.5	22–76	0.4465

The mean stone size was 6.17 (3.1–15.8) mm for the transgluteal approach (group 1) and 6.14 (3.4–11.2) mm for the transabdominal approach (group 2). No significant difference was found between stone size, surface area or volume (Table 2).

Table 2
Preprocedural data

	Transabdominal (Group1) (N = 76)			**Transgluteal (Group 2) (N = 67)**			
	N (%)	Mean (SD)	Range	N (%)	Mean (SD)	Range	P-value
Stone size (mm)		6.14 ± 2.00	3.1–11.2		6.17 ± 2.52	3.4–15.8	0.93
Stone surface area(mm2)		24.77 ± 13.39	5.77–62.42		26.69 ± 22.65	7.06-127.59	0.54
Stone volume (mm3)		91.14 ± 74.24	12.72-342.79		142.14 ± 250.84	12.64-1627.95	0.11
HU > 1000	58(76.0)			42(63.0)			0.1
Stone to skin distatnce (mm)		114.23 ± 26.83	9.7-160.9		103.84 ± 14.69	75.3-141.2	0.004
Radiopaque	49 (64.0)			45 (67.0)			0.86
Left side	44 (58.0)			37 (55.0)			0.87
Not Pre-stented	73 (96.0)			63 (94.0)			0.71

The skin to stone distance was 103.84 ± 14.69 mm in group 1 and 114.23 ± 26.83 mm in group 2. This difference between the groups was statistically significant (p = 0.0043).

The stone-free rate (SFR) achieved after a single treatment session was 85% and 54% for transgluteal and transabdominal approaches, respectively. This difference was found to be statistically significant. (p = 0.0004)

In conformity with the SFR difference, the rate of auxiliary procedures varied between the groups. While only 8% in group 1 required complementary ureteroscopy, 25% in group 2 underwent auxiliary intervention (Table 3).

Table 3
Postprocedural data

	Transabdominal (Group1) **(N = 76)**	**Transgluteal (Group 2)** **(N = 67)**	**p-value**	**OR (95%CI)**	**OR p-value**
Use of Ureteral catheter	26 (34.0)	16 (24.0)	0.2008	0.60 (0.29–1.26)	0.1777
Post-op complications	12 (16.0)	5 (8.0)	0.1946	2.35 (0.77–6.99)	0.1328
Stone free	41 (54.0)	57 (85.0)	0.0004	4.96 (1.96–12.57)	0.0007
No auxiliary procedures	50 (75.0)	61 (92.0)	0.0091	4.15 (1.43–12.03)	0.0088
No Post -stenting	64 (84.0)	64 (96.0)	0.0311	4.00 (1.08–14.85)	0.0383

The complication rate was 7% and 16% for transgluteal and transabdominal approaches, respectively. No serious side effects were observed.

Discussion

The optimal treatment option for distal ureteric stones is still a subject of debate. According to the current guidelines, the treatment of choice can be both SWL and URS as a first-line [10]. Ureteroscopy has a higher success rate alongside being more invasive while the main advantage of SWL is non-invasiveness with good efficiency [11]. The optimal SWL position to treat distal calculi is debatable [12].

In the transabdominal approach, there is a risk of intestinal perforation [13–15] Moreover, the distance between the skin and the stone is significant in many cases. Another important limiting factor is that the medium between the source of the shock waves and the stone can be disturbed by the gas within the small bowel. On the other hand, treatment with a transgluteal approach might be less effective because of the bony frame of the pelvic girdle and the difficulty of passage of the shock waves to the stone.

In the past, we used to treat distal ureteric stones with SWL in a transabdominal approach, but in light of disappointing results and numerous publications that showed the advantages of the transgluteal approach which provides better results in a supine position, we changed the treatment protocol from transabdominal approach to transgluteal approach. In this case, the shockwave targets the stone in the distal ureter (Fig. 3) through the greater sciatic foramen [16].

In our study, we have demonstrated a significantly higher success rate when applying the transgluteal approach.

These results are consistent with results published in other large studies, including meta-analysis by Tao Li et al [12, 17]

These findings result from several causes, including the SSD in the transabdominal approach, which was found to be significantly greater in our study.

SSD was found to be a significant factor defining SWL success rates in many studies and therefore enters the guidelines as a factor of preference for one treatment over the other [4, 18].

Another important factor is small bowel gas interfering with progression of shock waves, hence, causing attenuation of the shock wave [19] and in a rare situation leading to small bowel perforation [20, 21].

Along with these results, we were able to demonstrate low complication rates in the transgluteal approach and a lesser need for a complementary procedure. Additionally, the need to insert a ureteral stent at the end of the procedure was lower compared to group 2. This fact is clinically important since avoiding post interventional stenting, significantly reduces the patient's morbidity [22, 23].

It is important to note that unlike the previous works in this field, all our interventions were performed in the supine position, including the transabdominal approach. The varying element was the positioning of the shockwave source. This fact might be of additional benefit keeping in mind that the prone position alters the position of the intestine compared to the supine position.

Among our study limitations, the retrospective nature of data collection should be mentioned. Additionally, treatment performed under general anesthesia did not allow us to assess the pain level during the procedure.

Conclusion

Supine, transgluteal position SWL for the distal ureteral stone had a higher stone-free-rate in comparison with the transabdominal approach. The complication rate was lower for the transgluteal approach group, and no serious adverse effects were noticed. SWL remains an important, available and efficient tool in the treatment of distal ureteric calculi.

References

1. Kim MM, Harvey J, Gusev A, Norton JM, Miran S, Bavendam T. A Scoping Review of the Economic Burden of Non-Cancerous Genitourinary Conditions. Urology. 2021 Oct 22;
2. Perez Castro E, Osther PJS, Jinga V, Razvi H, Stravodimos KG, Parikh K, et al. Differences in ureteroscopic stone treatment and outcomes for distal, mid-, proximal, or multiple ureteral locations: the Clinical Research Office of the Endourological Society ureteroscopy global study. Eur Urol. 2014 Jul;66(1):102–109.
3. Pearle MS, Nadler R, Bercowsky E, Chen C, Dunn M, Figenshau RS, et al. Prospective randomized trial comparing shock wave lithotripsy and ureteroscopy for management of distal ureteral calculi. J Urol. 2001 Oct;166(4):1255–1260.
4. Turk C, Neisius A, Petrik A, Seitz C,Skolarikos A, Thomas K, et al. EAU Guidelines on Urolithiasis 2020
5. Kidney Stones: Surgical Management Guideline - American Urological Association [Internet]. [cited 2021 Dec 17]. Available from: https://www.auanet.org/guidelines/guidelines/kidney-stones-surgical-management-guideline
6. Hendrikx AJ, Strijbos WE, de Knijff DW, Kums JJ, Doesburg WH, Lemmens WA. Treatment for extended-mid and distal ureteral stones: SWL or ureteroscopy? Results of a multicenter study. J Endourol. 1999 Dec;13(10):727–733.
7. Jermini FR, Danuser H, Mattei A, Burkhard FC, Studer UE. Noninvasive anesthesia, analgesia and radiation-free extracorporeal shock wave lithotripsy for stones in the most distal ureter: experience with 165 patients. J Urol. 2002 Aug;168(2):446–449.
8. Jenkins AD, Gillenwater JY. Extracorporeal shock wave lithotripsy in the prone position: treatment of stones in the distal ureter or anomalous kidney. J Urol. 1988 May;139(5):911–915.
9. Zehntner CH, Marth D, Zingg EJ. ESWL treatment with ventral shock-wave application: therapy of iliac and distal ureteral calculi. Urology. 1991 Jul;38(1):51–53.
10. Verze P, Imbimbo C, Cancelmo G, Creta M, Palmieri A, Mangiapia F, et al. Extracorporeal shockwave lithotripsy vs ureteroscopy as first-line therapy for patients with single, distal ureteric stones: a prospective randomized study. BJU Int. 2010 Dec;106(11):1748–1752.
11. Aboumarzouk OM, Kata SG, Keeley FX, Nabi G. Extracorporeal shock wave lithotripsy (ESWL) versus ureteroscopic management for ureteric calculi. Cochrane Database Syst Rev. 2011 Dec 7;(12):CD006029.
12. Istanbulluoglu MO, Hoscan MB, Tekin MI, Cicek T, Ozturk B, Ozkardes H. Shock wave lithotripsy for distal ureteric stones: supine or prone. Urol Res. 2011 Jun;39(3):177–180.
13. Kurz W, Klein B, Rumstadt B. [Colonic perforation after extracorporeal shock wave lithotripsy]. Dtsch Med Wochenschr. 2009 Feb 17;134(9):401–403.
14. Klug R, Kurz F, Dunzinger M, Aufschnaiter M. Small bowel perforation after extracorporeal shockwave lithotripsy of an ureter stone. Dig Surg. 2001;18(3):241–242.
15. Kajikawa T, Nozawa T, Owari Y, Fujisawa H, Kaneko T, Noro K, et al. [Bowel perforation after extracorporeal shock wave lithotripsy: a case report]. Nippon Hinyokika Gakkai Zasshi. 2001 Jul;92(5):586–588.

16. Lu J, Sun X, He L. Sciaticum majus foramen and sciaticum minus foramen as the path of SWL in the supine position to treat distal ureteral stone. Urol Res. 2010 Dec;38(6):417–420.
17. Li T, Gao L, Chen P, Bu S, Cao D, Yang L, et al. Supine versus Prone Position during Extracorporeal Shockwave Lithotripsy for Treating Distal Ureteral Calculi: A Systematic Review and Meta-Analysis. Urol Int. 2016;97(1):1–7.
18. Phipps S, Stephenson C, Tolley D. Extracorporeal shockwave lithotripsy to distal ureteric stones: the transgluteal approach significantly increases stone-free rates. BJU Int. 2013 Jul;112(2):E129–33.
19. Kamel M, Salem EA, Maarouf A, Abdalla M, Ragab A, Shahin AMS. Supine transgluteal vs prone position in extracorporeal shock wave lithotripsy of distal ureteric stones. Urology. 2015 Jan;85(1):51–54.
20. Mueller SC, Wilbert D, Thueroff JW, Alken P. Extracorporeal shock wave lithotripsy of ureteral stones: clinical experience and experimental findings. J Urol. 1986 Apr;135(4):831–834.
21. Guntekin E, Kukul E, Kayacan Z, Baykara M, Sevuk M. Morbidity associated with patient positioning in extracorporeal shock wave lithotripsy of distal ureteral calculi. Int Urol Nephrol. 1994;26(1):13–16.
22. Sfoungaristos S, Gofrit ON, Pode D, Landau EH, Yutkin V, Latke A, et al. History of Ureteral Stenting Negatively Affects the Outcomes of Extracorporeal Shockwave Lithotripsy. Results of a Matched-pair Analysis. Prague Med Rep. 2015;116(3):225–232.
23. Wagenius M, Jakobsson J, Stranne J, Linder A. Complications in extracorporeal shockwave lithotripsy: a cohort study. Scand J Urol. 2017 Oct;51(5):407–413.

Figures



Figure 1

(A) Transabdominal approach

(B) Transabdominal approach

Figure 2

Transgluteal approach

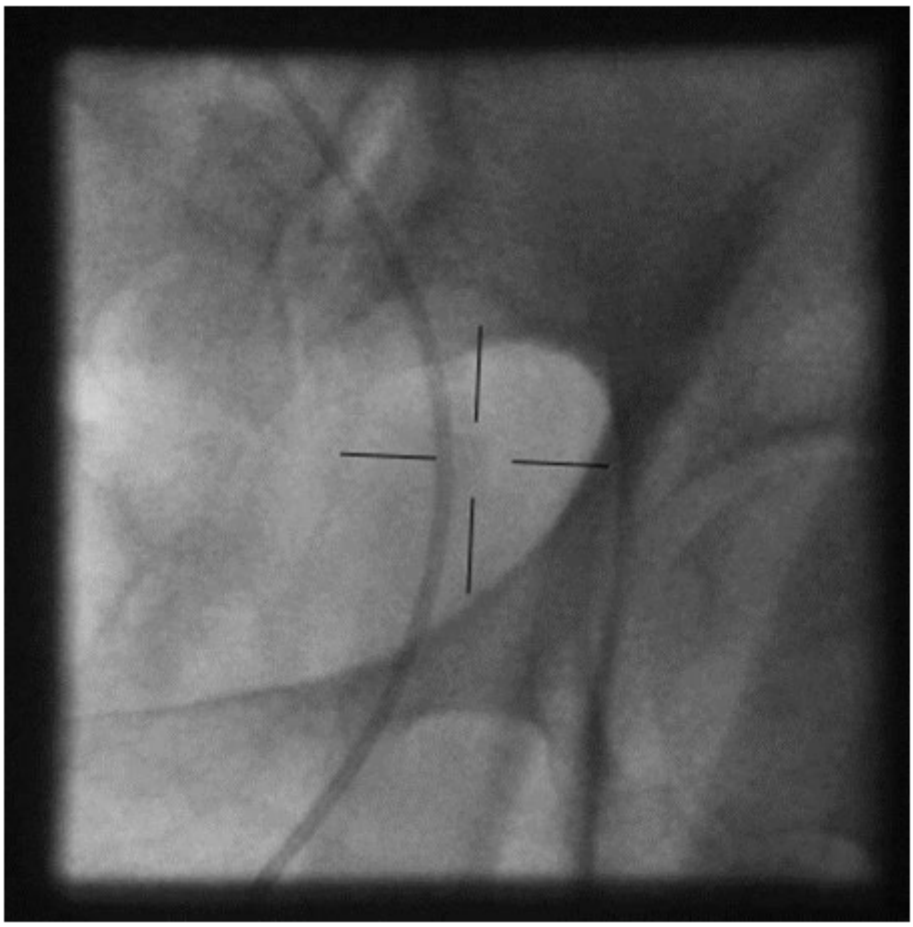

Figure 3

Distal ureteral stone targeting