Retroperitoneal Robot-Assisted Laparoscopic Partial Nephrectomy for Horseshoe Kidney: A Case Report

Dongxu Zhang
Qindao University Medical College Affiliated Yantai Yuhuangding Hospital https://orcid.org/0000-0003-3649-9686

Youyi Lu
Qindao University Medical College Affiliated Yantai Yuhuangding Hospital

Fengze Sun
Qindao University Medical College Affiliated Yantai Yuhuangding Hospital

Di Wang
Qindao University Medical College Affiliated Yantai Yuhuangding Hospital

Xingjun Bao
Qindao University Medical College Affiliated Yantai Yuhuangding Hospital

Kai Sun
Qindao University Medical College Affiliated Yantai Yuhuangding Hospital

Jitao Wu
Qindao University Medical College Affiliated Yantai Yuhuangding Hospital

Jipeng Wang (2410954455@qq.com)
Qindao University Medical College Affiliated Yantai Yuhuangding Hospital

---

Case report

Keywords: horseshoe kidney, renal tumor, robot-assisted laparoscopic partial nephrectomy, retroperitoneal

Posted Date: January 29th, 2021

DOI: https://doi.org/10.21203/rs.3.rs-154087/v1

Abstract

Background: Horseshoe kidney (HSK) have always been a challenge for urologists depending on its particular anatomy. We report a case of renal tumor in a patient with HSK, who underwent tumor resection by retroperitoneal robot-assisted laparoscopic partial nephrectomy.

Case Presentations: A 47-year-old man presented to our hospital with a solid renal mass. Computed tomography urography (CTU) showed a 4.3 × 4.4 cm mass in the upper pole of the right kidney. Patients received a retroperitoneal robot-assisted laparoscopic partial nephrectomy on basis of three-dimensional (3D) reconstructions.

Conclusion: The present case report highlights the feasibility of robot-assisted laparoscopic partial nephrectomy for horseshoe kidney, and the advantages of preoperative 3D reconstructions.

Introduction

Horseshoe kidney is an anatomical deformities, which was originated from renal fusion anomaly [1]. Over the past ten years, the therapeutic treatments of renal tumor associated with horseshoe kidney are limited reported, further more, the treatments correlative with robotic-assisted laparoscopic surgery were seldom [2-3]. Horseshoe kidney's vascular distribution is extraordinary complicated and challenged diverse medical treatment. Besides, on account of the multiple blood provision, the method of clamping renal artery are various.

Recently, three dimension construction has been becoming a hotpot among the partial nephrectomy, besides, several cases were reported to describe its significant effect in selective artery clamping and renal parenchyma protection, moreover, all above cases indicated this reconstruction technique contributed to renal function [4-6]. In general, three dimension reconstruction is more suitable for tumors associated with horseshoe kidney because of its complex vascular anatomy, theoretically, appropriate artery clamping can protect the renal function in maximum for this kind of disease.

Nowadays, a case which described a right side clear-cell carcinoma in a horseshoe kidney were managed robotic-assist partial nephrectomy in our center. In addition, we reviewed the operation details, especially the means of selectively clamping the artery, and combined with the three dimension reconstruction image aiming at propagating our center's experiences for curing this rare diseases.

Case Report

A 47 year-old man was referred to our clinic with HSK because a solid renal mass measuring 4.1cm × 4.3cm incidentally found on CT. Patients have no hematuria and loin pain. Blood test revealed leukocytosis (12.51×10^9 white blood cells (WBC)/L), while other laboratory tests were all negative, such as urine culture and cytology. In addition, the patient had a medical history of hypertension and cerebral.

Preoperative CT urography (CTU) showed the lower pole of the both kidneys fusion anomaly and a 4.3 × 4.4 cm mass in the upper pole of the right kidney (Fig. 1A). The CT angiography (CTA) was performed with contrast medium, revealing one artery supplied the isthmus from the abdominal aorta and no other obvious abnormalities were observed in both renal arteries (Fig.1B, 2B). On three-dimensional (3D) reconstructions, the right renal artery has three branches, one of which supplies the mass (Fig. 2A).

Surgical procedure were performed using da Vinci robot-assisted laparoscopic partial nephrectomy. The patients was placed in the left lateral decubitus position. We performed the operation through retroperitoneal access and four trocars (Fig. 3). The skin was incised at the costal margin on the posterior axillary line (Fig. 3) and the retroperitoneal space was created by compressing the balloon dilator. A 12-mm trocar was placed 5 cm above the iliac crest in the midaxillary line for placement of the laparoscope. The robotic trocar was placed at 2 cm below the costal margin of the anterior axillary line, 2 cm below the costal margin of the mid axillary line, and 2 cm below the costal margin of the posterior axillary line respectively. The distance between each trocar is about 8 cm. Then, the surgeon cleaned the extraperitoneal fat and opened the perirenal fascia. Via removing perirenal fat, the two renal arteries were exposed. The tumor, about 3*3cm in size, is located at the upper pole of the kidney. The adipose tissue around the mass was dissociated and the adipose tissue on the surface of the tumor was retained. According to the applied 3D reconstructions, the two renal arteries were blocked with vascular. Next, The surgeon removed the tumor along the edge of the tumor and the resection edge was at least 0.5 cm from the tumor margin. The wound was closed with absorbable thread continuous suture. A drainage tube was placed in the incision above the iliac crest of the right midaxillary line. The surgery was lasted for approximately 150 min with 100 ml of intraoperative bleeding. Post-operative recovery was uneventful and patient was discharged at day 6 after the operation with no complications. Pathologic examination of cores indicated renal clear cell carcinoma (Fuhrman grade Ⅱ).

Discussion

HSK is a common congenital renal malformation, which is mostly developed in early fetal life. Its main anatomical features are complicated vascular networks. Prior reports have shown that the number of renal arteries in HSK is twice that of normal kidney [7]. In addition, patients with HSK have an increased risk of infection, stones and even tumors due to abnormal fusion of the kidneys on both sides, resulting in changes in the position of the kidney, ureter and pelvis [8]. Among them, the incidence of hydronephrosis is about 14% to 35%. There is no consensus on the risk of tumor in patients with HSK. Therefore, the difficulty of the laparoscopic partial nephrectomy increased significantly due to unique anatomy of HSK. In our case, we chose to perform retroperitoneal robot-assisted laparoscopic partial nephrectomy.

Several lines of evidence suggested that better results in robotic than laparoscopic partial nephrectomies [9,10]. The robotic systems was designed to reduce the challenges posed by the complex anatomical structures of HSK. The main advantage of this procedure is that it provides a wide surgical view. Surgeons can use robotic arms to dissect blood vessels and resect lesions more flexibly. Given that the complex anatomy of HSK and its blood supply, we suggested that 3D reconstructions was applied before

surgery, because it can clearly visualize the three-dimensional anatomy of the procedure area and aid surgeons in identifying complex horseshoe vascular system preoperatively better. In this case, we selectively occluded the branches of the renal artery rather than the trunk of the renal artery referring to the reconstructed 3D images, thereby decreasing the damage due to ischaemia–reperfusion injury in other nephron. A growing body of evidence also emphasized the importance of preoperative 3D reconstructions for patients with partial nephrectomy of HSK in surgical planning. [2,11]. Furthermore, our case indicated that retroperitoneal access was an effective approach for carcinoma in HSK. Although the transperitoneal approach can provide the operator with a better surgical field, there is also an increased risk of visceral damage and ileus after surgery. Retroperitoneal approach can better process blood vessels, avoid viscera damage and reduce post surgical adhesions [12]. Molina WR et al. [13] also documented that retroperitoneal approach may work better for tumors located in posterolateral side. Until now, there are only 4 cases that characterizes robot-assisted partial or heminephrectomy for renal tumors with fusion anomalies of the kidney [2, 14-16]. Three of them reported the surgery was performed through a transperitoneal approach [14-16]. To our knowledge, this is the first study reported retroperitoneal robot-assisted laparoscopic partial nephrectomy with HSK.

Conclusions

We demonstrated that retroperitoneal robotic-assisted laparoscopic partial nephrectomy combined with 3D reconstructions for HSK with renal tumor is feasible procedure.

Declarations

Ethics approval and consent to participate

Not applicable.

Consent for publication

Written informed consent for publication was obtained from the participant.

Availability of data and materials

The datasets generated during and/or analyzed during the current study are available from the corresponding author on reasonable request.

Conflict of interest:

No.

Funding

This work was supported by grants from the National Nature Science Foundation of China (Nos. 81572835; 81870525), Taishan Scholars Program of Shandong Province (No.tsqn201909199) and Yantai Science and Technology Bureau (2018SFGY117).

Author Contributions

WJP and WJT designed the research and revised the paper. LYY, SFZ, WD, BXJ and SK collected and analyzed the patient data. ZDX drafted the paper. All of the authors approved the submitted and final versions.

Acknowledgments:

All authors have no acknowledgements to disclose.

References

1. Natsis K, Piagkou M, Skotsimara A, Protogerou V, Tsitouridis I, Skandalakis P. Horseshoe kidney: a review of anatomy and pathology.2014 Aug;36(6):517–26. doi: 10.1007/s00276-013-1229-7.
2. Raman A, Kuusk T, Hyde ER, Berger LU, Bex A, Mumtaz F. Robotic-assisted Laparoscopic Partial Nephrectomy in a Horseshoe Kidney. A Case Report and Review of the Literature.Urology. 2018 Apr;114:e3-e5. doi: 10.1016/j.urology.2017.12.003.
3. Yoshino T, Wake K, Sugitani T, Kodama K, Shiina H, Yasumoto H, Kadowaki A, Kawakami K. Laparoscopic Pyelolithotomy in a Horseshoe Kidney: A Case Report and Review of the Literature.Hinyokika Kiyo. 2017 Apr;63(4):157–161. doi: 10.14989/ActaUrolJap_63_4_157.
4. Ukimura O, Nakamoto M, Gill IS. Three-dimensional reconstruction of renovascular-tumor anatomy to facilitate zero-ischemia partial nephrectomy. Eur Urol. 2012;(1):211–7. doi:10.1016/j.eururo.2011.07.068.
5. Francesco Porpiglia C, Fiori E, Checcucci D, Amparore R, Bertolo. Hyperaccuracy three-dimensional reconstruction is able to maximize the efficacy of selective clamping during robot-assisted partial nephrectomy for complex renal masses. Eur Urol. 2018;(5):651–60. doi:10.1016/j.eururo.2017.12.027.
6. Wang J, Lu Y, Wu G, Wang T, Wang Y, Zhao H, Zhou Z, Wu J. The role of three-dimensional reconstruction in laparoscopic partial nephrectomy for complex renal tumors. World J Surg Oncol. 2019;17(1):159. doi:10.1186/s12957-019-1701-x.
7. Majos M, Polguj M, Szemraj-Rogucka Z, et al. The level of origin of renal arteries in horseshoe kidney vs. in separated kidneys: CT-based study. Surg Radiol Anat. 2018 Oct;4010(10):1185–91. doi:10.1007/s00276-018-2071-8.

8. CSRamesh Babu V, Sharma OP, Gupta. Renal Fusion Anomalies: A Review of Surgical Anatomy. Anat Physiol 5: S5-001: 564–572. doi: 10.4172/2161-0940.S5-00.
9. Luciani LG, Chiodini S, Mattevi D, et al. Robotic-assisted partial nephrectomy provides better operative outcomes as compared to the laparoscopic and open approaches: results from a prospective cohort study. J Robot Surg 2017 Sep;113(3) :333–339. doi: 10.1007/s11701-016-0660-2.
10. Leow JJ, Heah NH, Chang SL, et al. Outcomes of Robotic versus Laparoscopic Partial Nephrectomy: an Updated Meta-Analysis of 4,919 Patients. J Urol 2016 11;1965(5) :1371–1377. doi: 10.1016/j.juro.2016.06.011.
11. Nikoleishvili D, Koberidze G. Retroperitoneoscopic Partial Nephrectomy for a Horseshoe Kidney Tumor. Urol Case Rep. 2017 Apr 15;13:31–33. doi: 10.1016/j.eucr.2017.03.013.
12. Lee JW, You SH, Han DY, et al. Retroperitoneoscopic nephrectomy for a horseshoe kidney with unilateral severe hydronephrosis and ureteral hypoplasia. Korean J Urol. 2009;50:512–5.
13. Molina WR, Gill IS. Laparoscopic partial nephrectomy in a horseshoe kidney. J Endourol. 2003 Dec;17(10):905–6. doi:10.1089/089277903772036244.
14. Fujihara A, Hongo F, Narukawa T, et al. Robot-assisted laparoscopic partial nephrectomy for horseshoe kidney: A case report. IJU Case Rep. 2019 Jul 23;2(6):308–311. doi: 10.1002/iju5.12108.
15. Rogers CG, Linehan WM, Pinto PA. Robotic nephrectomy for kidney cancer in a horseshoe kidney with renal vein tumor thrombus: novel technique for thrombectomy. J Endourol. 2008 Aug;22(8):1561–3; discussion 1563. doi: 10.1089/end.2008.0043.
16. Kumar S, Singh S, Jain S, et al. Robot-assisted heminephrectomy for chromophobe renal cell carcinoma in L-shaped fused crossed ectopia: Surgical challenge. Korean J Urol. 2015 Oct;56(10):729–32. doi:10.4111/kju.2015.56.10.729.

Figures

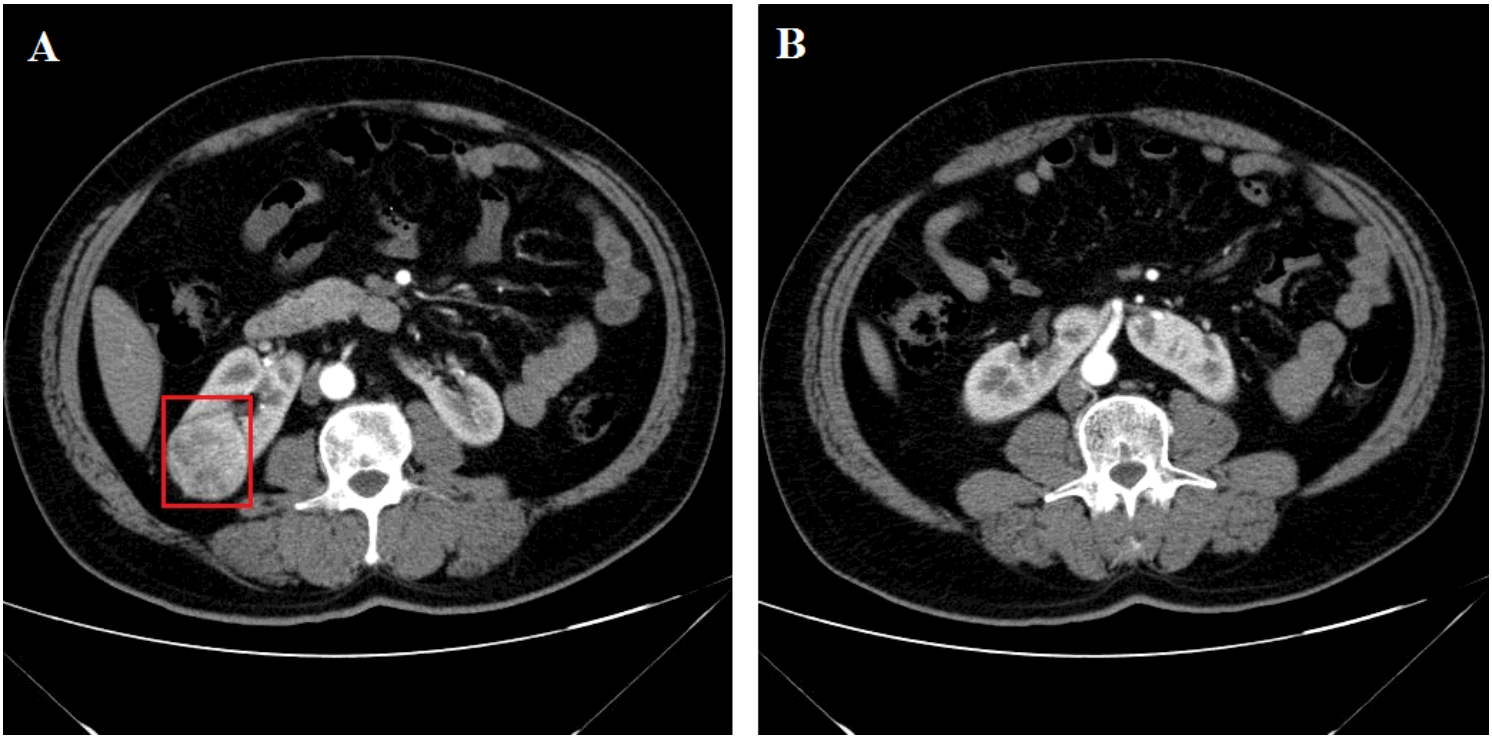

Figure 1

Kidney CTA of the patient. (A) A 4.3 cm mass is located in the right kidney (red square). (B) Axial section reveals the vascular supply of isthmus. (C) Coronal section reveals the tumor arising from upper pole of the right kidney.

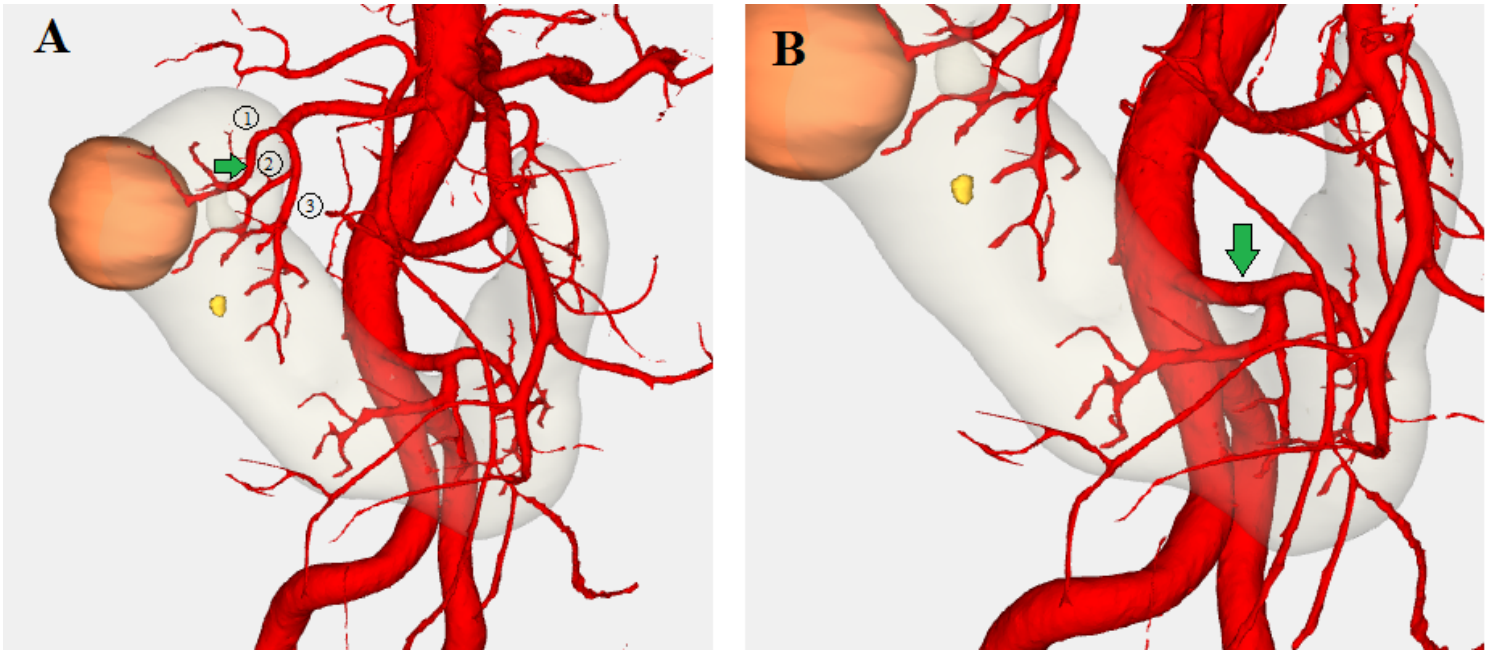

Figure 2

3D reconstructions of the patient. (A) A branch artery from right renal artery supplies the mass (green arrow). (B) One artery arising from abdominal aorta supplies the isthmus (green arrow).(orange: renal tumor, grey: kidney, red: artery)

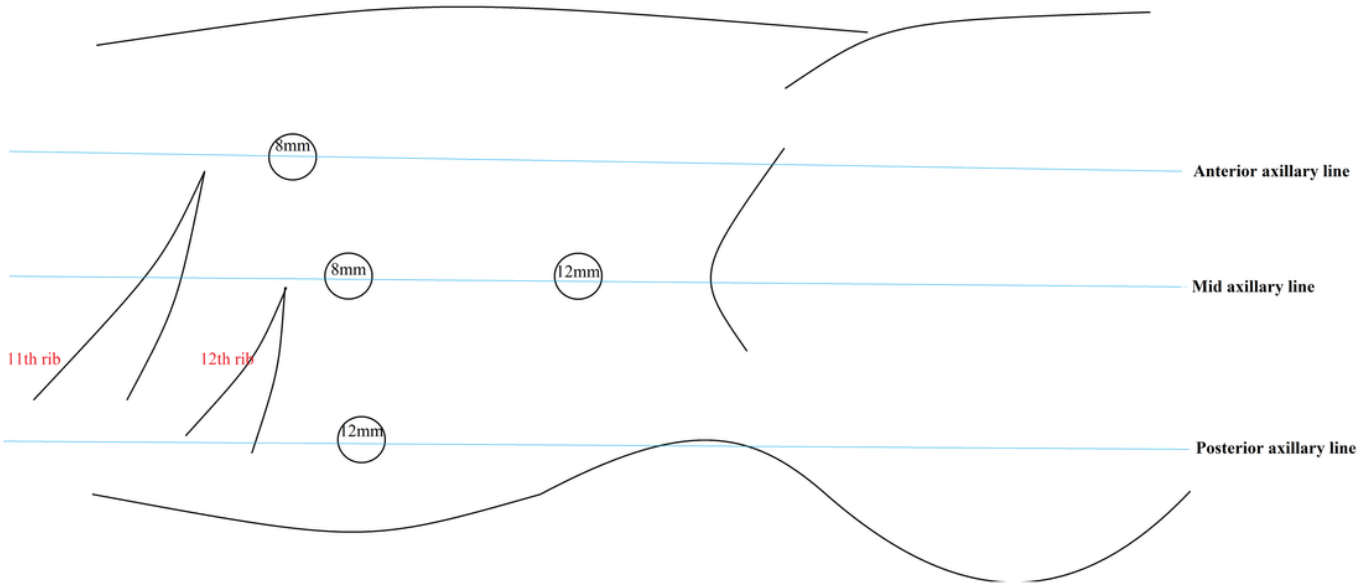

Figure 3

Ports for robot-assisted laparoscopic partial nephrectomy.