

T-cell Non-Hodgkin Lymphoma of the Ileum Presenting as Perforation and Peritonitis: A Case Report

Tian Yong (✉ 406072790@qq.com)

Tongren University

Zhang Zheng Xiang

Tongren University

Li, Chuan Fang

Tongren University

Tian Qing Ming

Tongren University

Ye Gang

Tongren University

Qiao Song

Tongren University

Case report

Keywords: T-cell lymphoma, Intestinal perforation, Peritonitis, Acute Abdominal Syndrome, Case report

Posted Date: January 29th, 2021

DOI: <https://doi.org/10.21203/rs.3.rs-154094/v1>

License: © ⓘ This work is licensed under a Creative Commons Attribution 4.0 International License.

[Read Full License](#)

Abstract

Background

Non-Hodgkin Lymphoma (NHL) of the ileum presenting as perforation and peritonitis is a rare disease, derived from intestinal intraepithelial T lymphocytes. The degree of malignancy is extremely high. The pathogenic factors of ileal perforation caused by NHL are not clear yet, Chromosome and immune system abnormalities, which may be related to the NHL, are indistinguishable from other benign and malignant conditions and clinically nonspecific.

Case presentation

Here, We described an 84 year old male with abdominal pain for four days and aggravating for three hours. The pain was initially considered as gastrointestinal perforation, and was initially located at the upper abdomen area. The persistent insidious pain, and was accompanied by nausea, vomiting and fever. According to the abdominal physical examination, the patient had pain all over his abdomen, rebound pain and muscle tension, and bowel sounds were reduced on auscultation. The abdominal CT scan showed abdominal cavity free gas. We diagnosed the patient with peritonitis due to the perforation of the hollow viscus. We promptly performed exploratory laparotomy. Intraoperative findings, showed perforations in the ileum that were approximately 40 cm from the ileocecal region and had a size of 3×8 mm. Segmental distribution was observed, and the intestinal contents overflowed with purulent mass around the perforation surface. Resection and ileostomy were performed as intervention, and the clinical histopathological examination showed the T-cell lymphoma.

Conclusion:

Timely emergency surgery is the key to the treatment of the ileal perforation caused by T-cell lymphoma. Resection and ileostomy were performed as intervention, and the subsequent histopathological examination showed T-cell lymphoma. Clinical follow-up was performed, and the patient was advised to go to the oncology department for further chemotherapy.

1. Background

Non-Hodgkin Lymphoma (NHL) of the ileum is an intestinal tumour of intraepithelial T lymphocytes, usually presenting as a neoplasm composed of large lymphoid cells and often associated with necrosis and an inflammatory background, including large numbers of histiocytes and eosinophils [1]. Small intestinal perforation is caused by the primary T-cell lymphoma, which is an extremely rare disease that is strongly related with celiac disease. The primary T-cell lymphoma has very poor prognosis and high mortality rate [2].

In our daily clinical work, most of acute abdomen syndromes are characterized by pain, which requires early diagnosis and treatment, while most of them need emergency surgery. Common acute abdominal

diseases include appendicitis, gastric and intestinal perforation, volvulus, acute pancreatitis, and ectopic pregnancy. Therefore, in the majority of cases, the intestinal perforation can only be detected by laparotomy, and a definite diagnosis can be made only after histopathological examination[3]. We report the rare case of a male suffering from peritonitis with Non-Hodgkin Lymphoma located in small intestine and reported the case in accordance with the SCARE 2018 guidelines[4].

We treat an uncommon case of an 84-year old male suffering from perforation and peritonitis with T-cell lymphoma located in the small intestine in Tongren People's Hospital in September 2020. The medical history, clinical symptoms, signs, laboratory results, imaging data, and histopathological examination results are reported as follows.

2. Case Presentation

An 84-year old male patient presented to the hospital with abdominal pain for four days and aggravating for three hours. Pain was initially located at the upper abdomen area, and persistent insidious pain. The patient felt unbearable pain accompanied with nausea, vomiting, and fever due to the gradual deterioration of the disease. The patient had valvular heart disease and coronary atherosclerosis 10 years ago. no history of peptic disease or black feces. no weight and appetite loss. no history of hepatitis, tuberculosis, and typhoid. no smoking and drinking habit. and no familial hereditary disease. The clinical examination revealed a heart rate of 132 per minute, respiratory rate of 22 per minute, blood pressure of 130/80 mmHg, and temperature of 36.5 °C. The abdominal physical examination showed that the patient had pain all over the abdomen, rebound pain, and muscle tension. The liver and the spleen were not touched, and percuss showed the drum sound around the umbilicus. The shifting dullness was negative, and bowel sounds were reduced on auscultation. Other systems were normal. There were no palpable lymph nodes in the cervical, axillary, or inguinal regions.

The complete blood count with leukocytes was 20.01×10^9 with a neutrophil composition of 94.4% and hemoglobin content of 86 g/L. Biochemical indices were within normal limits. C-reactive protein content was 255.55 mg/L. The coagulation function was normal. The patient was negative for hepatitis B and syphilis, and human immunodeficiency virus (HIV). The electrocardiogram and chest X-ray were also normal. The abdominal CT scan showed abdominal cavity free gas (**Fig 1**). We diagnosed the patient with peritonitis suspected due to the perforation of the hollow viscus.

After improving the relevant preoperative preparation, we immediately planned to perform exploratory laparotomy and selected the right rectus abdominis incision and opening of the abdomen in layers. Approximately 400 mL of bowel content was found in the abdominal cavity. There were more perforations was observed in the ileum approximately 40 cm from the ileocecal region with a size of 3×8 mm, which showed segmental distribution, and the intestinal contents overflowed, with purulent mass around the perforation surface (**Fig 2**). No perforation or tumor was observed in the stomach, liver, spleen and peritoneum. According to the intraoperative findings, we considered that the small intestinal perforation might be caused by Crohn's disease, intestinal tuberculosis or ileotyphus.

We performed the resection of the ileum segment and its mesentery, and ileostomy was performed on the left lower abdomen. The resected ileum specimen was sent to the laboratory of pathology department. Ten days after the operation, the histopathological examination of the specimens revealed the features of malignant non-Hodgkin lymphoma (NHL) of the T-cell type, and immunohistochemistry staining showed that the leucocyte antigen was positive (CD45R0, Bcl-22, CD3, CD5, CD10, CD15, Ki-67, CD138, TIA-1, CKi67[40%]), on the tumour cell and negative (CyclinD1, CD56, and CD30; Fig 3), indicating that the lesion had a T-cell origin, and not a B-cell origin or Hodgkin lymphoma type.

The patient was discharged home eight days postoperative with a good condition, and had no special discomfort, good spirit and diet. The patient was advised to go to the oncology department for further chemoradiotherapy.

3. Discussion

Acute abdomen signify the need for prompt diagnosis and early treatment, not necessarily always surgical, pain is the main symptom and complaint of most patients[5].

In clinical work, Perforation of the digestive tract caused by lymphoma are uncommon, the small intestine (particularly the proximal jejunum) is the most common site of involvement followed by stomach, colon, and rectum[[6-7]. The small intestinal lymphoma is predominantly in the ileum (60%–65%) followed by the jejunum (20%–25%), duodenum (6%–8%) and other sites (8%–9%) [8].

Previous research reports that the primary intestinal lymphoma is a male predominant disease, and the male:female ratio is 2.5:1, the clinical presentation of small intestinal lymphoma is nonspecific and the patients have mainly acute abdominal pain symptoms (70%–80%), weight loss (30%), hematochezia (25.9%) and diarrhea (16.9%) nausea, vomiting, bad appetite[9-11], rarely perforation, acute obstructive symptoms[12]. The nonspecific clinical manifestations of NHL make the preoperative diagnosis is extremely difficult, and diagnosis only can be confirmed using pathological examination after operation.

We report the case of an 84-year old male patient with primary ileum T-cell lymphoma. The first symptom is acute abdominal pain, and has gradually manifested as peritonitis. We have excluded relevant contraindications and identified numerous perforation in the ileum by performing laparotomy in emergency, which requires ileum resection and ileostomy. We conclude that a temporary enterostomy may be a better choice for those patients with unexplained intestinal spontaneous perforation, rather than intestinal resection and intestinal anastomosis.

Given its rareness and low incidence rate, the Intestinal perforation caused by lymphoma is often neglected and difficult to distinguish from Crohn's disease, intestinal tuberculosis, intestine typhoid and other types of gastrointestinal disease. For patients with abdominal pain, fever, gastrointestinal perforation and bloody stool, especially when multiple ulcers of intestinal wall are observed through colonoscopy, the possibility of the disease should be considered. Therefore, gastrointestinal surgery

doctors should improve their proper understanding of the disease, especially our young doctors. Timely intervention, and good clinical management will yield favourable results.

Surgery followed by chemotherapy is the recommended treatment, surgery was followed by adjuvant multiagent chemotherapy (CHOP) which have led to improved outcomes. The NHL is usually based on anthracycline based consisting of CHOP (cyclophosphamide, doxorubicin, vincristine, prednisolone) in most cases [13-14].

In conclusion, the prognosis for patients with NHL patients remains exceedingly poor. This results in an extremely variable 5-years survival of NHL patients between 8% and 60% [15-16].

4. Conclusion

The clinical presentation of the primary small intestinal lymphoma is usually nonspecific, which easily leading to delayed disease and misdiagnosis. Early diagnosis and treatment are important to improve the prognosis of the bowel perforation in patients with NHL. Surgery followed by chemotherapy is the recommended treatment method, to improve the overall overall survival of patients.

Abbreviations

NHL
Non-Hodgkin Lymphoma;

Declarations

Ethics approval and consent to participate

Written informed consent was obtained from the participant, and the study protocol was approved by the Research Ethics Board of the Tongren City People's Hospital, Tongren City, Guizhou, China.

Authors' contributions

Yong Tian studied the literature and wrote the manuscript. Yong Tian, Chuan Fang Li, QingMing Tian, ZhengXiang Zhang and Gang Ye operated on the patient and had the idea for this case report. Song Qiao checked the manuscript and made corrections. All authors read and approved the final manuscript.

Funding

No funding or sponsorship.

Competing interests

The authors declare that they have no conflict of interests.

Acknowledgment

We acknowledge Professor Xiaolong Ji of The General Hospital of the People's Armed Police of China for reading the pathological section and making pathological diagnosis.

Availability of data and materials

There is no dataset as this is a case report. Data/details of the patient available upon request.

Consent for publication

The patient provided consent for publication of this case report.

Author details

Yong Tian,Chuan Fang Li, QingMing Tian, Gang Ye, ZhengXiang Zhang,Song Qiao, Department of Gastrointestinal Surgery,Tongren City People's Hospital, Tongren City,554300, Guizhou Province,China.

References

1. Ferreri Andrés JM, Zinzani Pier Luigi,Govi Silvia. et al. Enteropathy-associated T-cell lymphoma. [J]CritRevOncolHematol. 2011;79:84–90.
2. Gou Hong-Feng,Zang Jian,Jiang Ming, et al. Clinical prognostic analysis of 116 patients with primary intestinal non-Hodgkin lymphoma.[J]Med Oncol, 2012, 29: 227–34.
3. Warsinggih D, Suluh,Prihantono et al. Non-Hodgkin Lymphoma of the jejunum presenting as perforation peritonitis: A case report.[J].Ann Med Surg (Lond), 2020, 55: 131–134.
4. Agha Riaz A, Borrelli Mimi R, Farwana Reem, et al. The SCARE 2018 statement: Updating consensus Surgical CAse REport (SCARE) guidelines.[J]. Int J Surg. 2018;60:132–6.
5. W.Silen,Cope's Early Diagnosis of the Acute Abdomen,Oxford University Press,Inc, Twenty-sec, 2010 New York.
6. Sieniawski M, Angamuthu N, Boyd K, et al. Evaluation of enteropathy-associated T-cell lymphoma comparing standard therapies with a novel regimen including autologous stem cell transplantation. Blood May. 2010;6(18):3664–70. 115(.[PMID: 20197551.
7. Zettl A, deLeeuw R, Haralambieva E, Mueller-Hermelink HK. Enteropathy-type T-cell lymphoma. Am J Clin Pathol May. 2007;127(5):701–6.
8. Pandey Manoj,Swain Jyoti,Iyer Hema Malini. et al. Primary lymphoma of the colon: report of two cases and review of literature.[J]. World J Surg Oncol. 2019;17:18.
9. Ara Cengiz,Coban Sacid,Kayaalp Cuneyt. et al. Spontaneous intestinal perforation due to non-Hodgkin's lymphoma: evaluation of eight cases.[. J]DigDisSci. 2007;52:1752–6.
10. Ding Dongbing,Pei Wenju,Chen Wenbin. et al. Analysis of clinical characteristics, diagnosis, treatment and prognosis of 46 patients with primary gastrointestinal non-Hodgkin lymphoma.

[J]MolClinOncol. 2014;2:259–64.

11. Wang Guo-Bao,XuGuo-Liang,Luo Guang-Yu et al. **Primary intestinal non-Hodgkin's lymphoma: a clinicopathologic analysis of 81 patients.**[J].World J. Gastroenterol.2011,17: 4625-31.
12. Li Bo,ShiYuan-Kai,He Xiao-Hui et al. Primary non-Hodgkin lymphomas in the small and large intestine: clinicopathological characteristics and management of 40 patients.[J]. Int. J. Hematol,2008, 87: 375–381.
13. **Sun Zhi-Huan,Zhou Hai-Meng,Song Guo-Xin et al. Intestinal T-cell lymphomas: a retrospective analysis of 68 cases in China.**[J].World J Gastroenterol,2014,20: 296–302.
14. **Pandey Manoj,Swain Jyoti,Iyer Hema Malini. et al.** Primary lymphoma of the colon: report of two cases and review of literature.[J]. World J Surg Oncol. 2019;17:18.
15. Spijkerman Marleen,Tan Ineke L, Kolkman Jeroen J, et al. A large variety of clinical features and concomitant disorders in celiac disease - A cohort study in the Netherlands.[J].Dig Liver Dis, 2016, 48:499–505.
16. d'Amore Francesco,Relander Thomas,Lauritzsen. Grete F, et al.Up-front autologous stem-cell transplantation in peripheral T-cell lymphoma: NLG-T-01.[J].Clin.Oncol, 2012, 30: 3093-9.

Figures

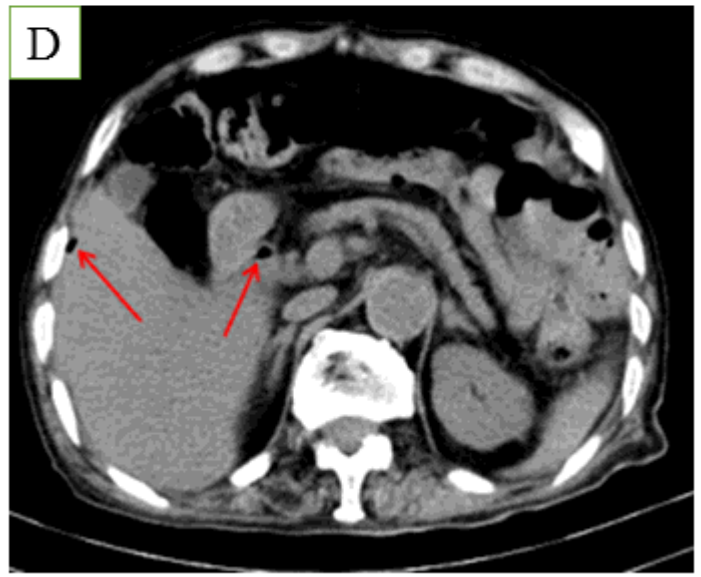
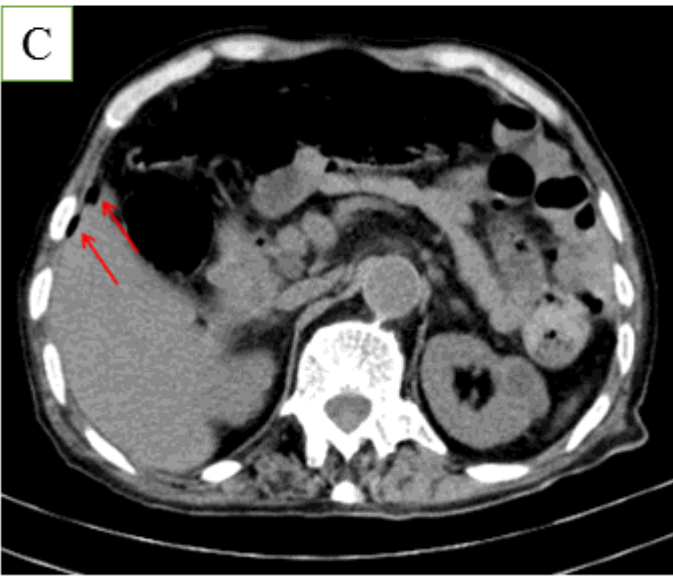
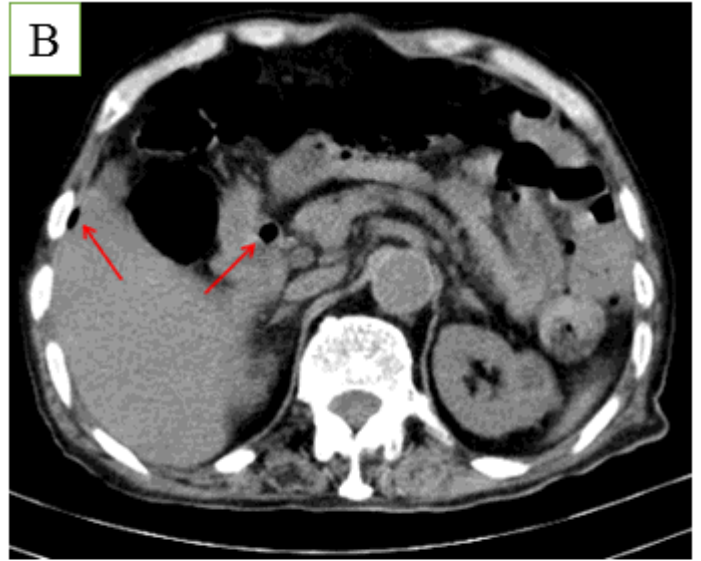
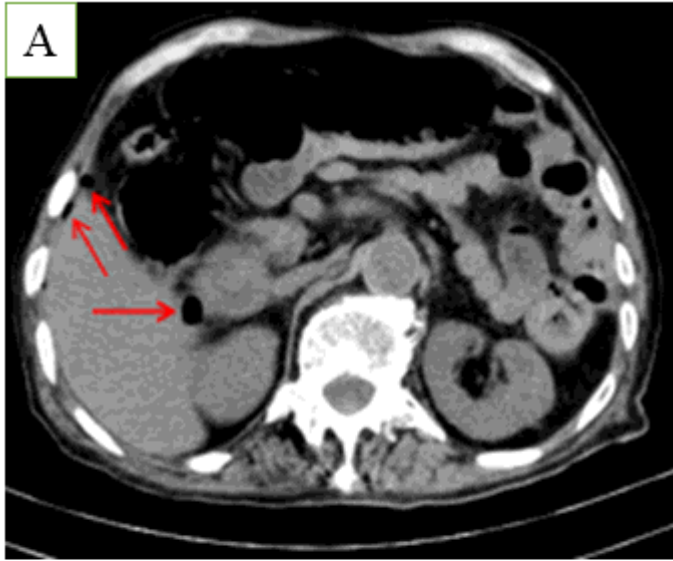


Figure 1

Abdominal CT:Abdominal CT scan showed that free gas in the abdominal cavity (red arrow)

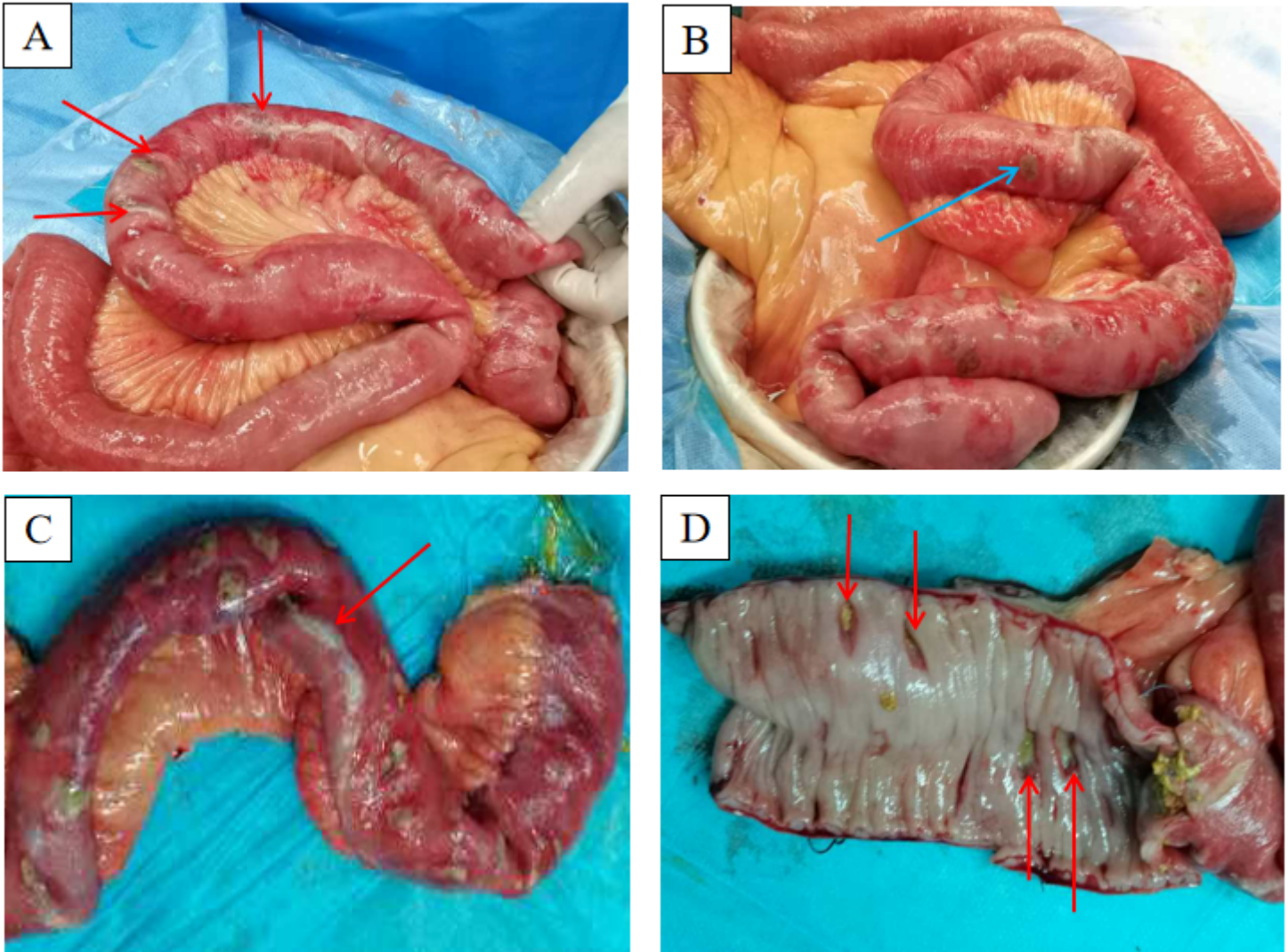


Figure 2

Intraoperative finding. A. Ileum perforation (red arrow) with no discrete mass lesion. B. Perforation focal at ileum approximately 30 cm (blue arrow) and away from the ileocecal region about 40 cm (blue arrow). C. A large number of purulent masses were found in the intestinal wall and perforation focal. D. Ulcers were seen in the ileum mucosa and penetrated differing levels, including the full thickness of the bowel wall.

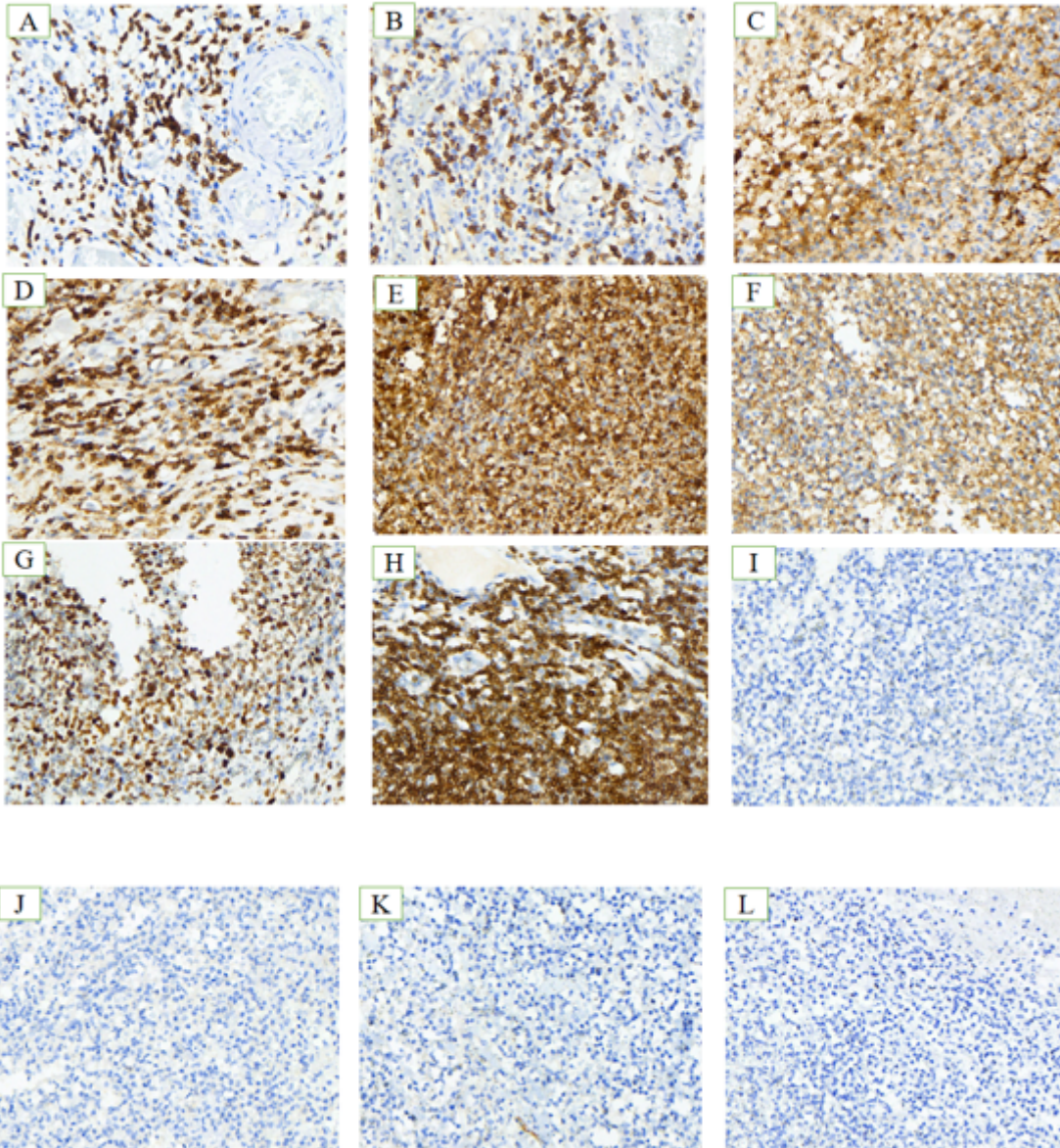


Figure 3

Immunohistochemistry: Histopathological examination showed hematoxylin and eosin stain (H&E \times 40). The neoplastic lymphocytes are small-to medium-sized with dark staining nuclei, conspicuous nucleoli, and scarce cytoplasm and infiltrated all layers of the jejunal wall. Immunohistochemical characteristics of tumor cells. A–I: immunohistochemical stain is strongly positive for neoplastic cells. J–L: immunohistochemical stain is negative. Positive: A, CD3; B, CD5; C, CD10; D, CD45R0; E, CD15; F, TIA-1; G, Ki-67 (40%); H, Bcl-22; I, CD138. Negative: J, Cyclin D1; K, CD56; L, CD30.