“A Modified Anterolateral Swashbuckler Approach for Distal Femoral Fractures: Description and Outcomes”

Stefano Ghirardelli
Stanford University School of Medicine
GEORGIOS TOULOUPAKIS
San Carlo Borromeo Hospital: Azienda Ospedaliera San Carlo Borromeo
EMMANOUIL THEODORAKIS
San Carlo Borromeo Hospital, Milan
Guido Antonini
San Carlo Borromeo Hospital, Milan
Bruno Violante
IRCCS: IRCCS Ospedale San Raffaele
Pier Francesco Indelli (pindelli@stanford.edu)
Stanford University https://orcid.org/0000-0002-4752-8027

Technical advance

Keywords: tibial tuberosity osteotomy, swashbuckler, computerized tomography

Posted Date: January 27th, 2021

DOI: https://doi.org/10.21203/rs.3.rs-154105/v1

Abstract

Background: The treatment of distal femur fractures represents a challenging task. General and local factors, including bone quality, articular surface involvement, fracture comminution, associated soft tissue injuries and ultimately fixation system, all play a role in the final clinical outcome. Current surgical approaches often undermine patellar vascularization and integrity of the extensor apparatus, not guaranteeing sufficient visualization of the medial condyle. This technical note presents the efficacy and safety a new surgical technique to address distal femoral fractures.

Methods: The original "swashbuckler" surgical approach was modified in order to obtain a better visualization of the lateral and medial femoral condyles without affecting the knee extensor mechanism and the anastomotic arterial supply of the patella. This modified surgical approach was utilized in a consecutive series of patients presenting with a Müller AO 33 distal femur or periprosthetic fracture of the knee. The final outcome was recorded according to a functional evaluation scoring system.

Results: Twelve patients (2 males and 10 females) with a mean age of 67,8 years (min. 18; max 90 years) were included in this series. The same, modified "swashbuckler" surgical approach was applied in all cases. Multiple internal fixation techniques, including a single lateral plate, a combination of a lateral and medial plate, a single lateral plate associated with lag screws, were used to obtain a satisfactory stabilization of the fracture site. All patients were reviewed at a minimum one-year follow up (median 15 months): all patients regained their level of activities of daily living. No major intraoperative or postoperative complications were recorded.

Conclusions: The modified swashbuckler approach allows anatomical reduction and appropriate fixation with minimal severance of the blood supply to the patella and ensures rapid weight bearing resumption thanks to an intact extensor mechanism.

Background

The treatment of distal femur fractures represents a challenging task, as the outcome is influenced by numerous factors: bone quality, patient’s age, articular surface involvement, presence of small fragments, fixation system and associated soft tissue injuries, all play a role in the final clinical result [1][2]. Traditionally, obtaining an anatomical reduction is a priority that must be achieved without compromising the soft tissues and knee vascularization [3]. In addition to classical fractures, trauma surgeons are often asked to treat complex distal femur periprosthetic fractures or other complicated cases, such as non-unions or malunions. Different strategies have been described to solve these challenges, as the choice of an adequate surgical approach represents the first step to achieve satisfying reduction and fixation [4][5].

The aim of this study it to present a modification of the classical “swashbuckler” approach to the distal femur, highlighting its main features when compared to the other approaches and presenting the clinical results in a retrospective case series.

Methods

All patients aged 16 years and older that had presented with a distal femoral fracture at the first author Institution between January 1017 and December 2019 were potentially eligible for study. Patients were identified through a diagnosis registry, including both in-hospital stays and outpatient visits. Only patients with distal femoral fracture who underwent osteosynthesis through a modified “swashbuckler” approach were included.

The pre-operative radiologic images of all the eligible patients were obtained from the Picture Archiving and Communication System (PACS, GE Healthcare, USA) and examined in at least two standard projections (anteroposterior and lateral views of the distal femur and knee) and a computerized tomography (CT) scan allowing 3D reconstruction. The fractures were classified according to the AO Foundation/Orthopaedic Trauma Association (AO/OTA) classification system [6] Periprosthetic fractures of the distal femur were classified according to the Lewis and Rorabeck Classification [7]. Patient characteristics at the time of fracture were obtained from hospital files, including data on age, gender, weight, risk factors and comorbidities.

Patients were followed for a minimum of 12 months postoperatively. Each follow up visit consisted of an outpatient consultation with a careful clinical and radiological examination (two weight-bearing anteroposterior and lateral radiographic projections of the distal femur including the knee were performed) at an interval of 1, 3, 6, 12 months postoperatively and thereafter depending on the necessity of further control. Clinical outcomes and complications, such as infections, implant failure, osteolysis, bone collapse, skin necrosis, knee stiffness and quadriceps hypotrophic changes were all recorded. The final outcome was classified according to the functional evaluation scoring system described by Sanders et al [8].

Description of the modified swashbuckler approach

The patient is placed supine onto a radiolucent table; a roll is positioned beneath the knee, to maintain a flexion of approximately 30° of both hip and knee. A radiolucent bump is placed under the ipsilateral buttock to avoid excessive external rotation of the lower limb. In order to prevent quadriceps medial retraction and avoid ischemic damage to the tissues, no tourniquet is used [7]. Starting at the lateral aspect of the tibial tuberosity, a blunt incision, which maintains a distance of about 2 cm from the lateral border of the patellar tendon, is made; at the base of the patella the incision deviated slightly, aiming for the posterior depression of the vastus lateralis until it reached the anterolateral aspect of the thigh, about 5 fingerbreadths from the patella (Fig. 1); the incision continued along thigh anterolateral aspect as proximal as needed.

Subsequently the approach is developed from proximal to distal. The incision is extended deep to the quadriceps fascia, which is incised, exposing the quadriceps muscle belly. The iliotibial band is bluntly separated from the vastus lateralis muscle and retracted laterally. The lateral intermuscular septum, which separates the anterior and posterior compartments of the thigh, usually relates directly to the

iliotibial band distally at the level of the patella. A blunt dissection is used to divide the septum from the vastus lateralis until the anterolateral aspect of femoral shaft is exposed and visualized according to the surgeon's need. After the vastus lateralis has been detached from the lateral intermuscular septum, Hohmann retractors were used to displace the quadriceps muscle medially and to expose distal femur. The superior lateral geniculate artery is easily identified before it joins the anastomotic lateral circle and was ligated.

The distal extension of the subcutaneous dissection must be performed carefully and precisely to minimize the disruption of the patellar arterial supply. Parapatellar arthrotomy is performed at least 2 cm from the lateral patellar margin in order to preserve the integrity of the peripatellar vascular anastomotic ring (Fig. 2). The integrity of the lateral descending and the transverse infrapatellar artery are thought to be pivotal in maintaining patellar vascularization on both sides of the anastomotic ring. The lateral inferior geniculate artery, which crosses the surgical incision perpendicularly at the height of the lateral meniscus, is ligated. We recommend preserving, if possible, the anterior tibial recurrent artery which usually crosses the surgical field at the height of the tibial tuberosity, in order to maintain a better vascularization of the peripatellar anastomotic ring [8, 9].

If a wider visualization of the medial side of the distal femur is required, the vastus intermedius muscle could be stripped from the femoral anterior cortex, as there are no attachments distally. The last step to increase exposure of the medial condyle, was to bend the knee few degrees in association with a medial sliding of the extensor apparatus in order to avoid unnecessary stress at the fracture site. Adductor magnus and biceps femoris brevis muscles usually remain intact at the posterior aspect of the femur, as there is no need to further expose both these structures. A retractor is useful to move the patella medially. Before skin suture, the retinaculum is closed with absorbable sutures with special attention not to damage the lateral circulatory anastomosis of the patellar network.

Postoperative management

A single daily dose of low-molecular-weight heparin12 hours after the operation was administered as a prophylaxis to prevent deep venous thrombosis of lower extremities. No drainage tube was placed in any patient. The skin stitches were removed two weeks after the procedure or later if the surgical wound has not healed. The postoperative weight-bearing status was regulated according to the stability of fracture fixation, the general condition of the patients, and the healing process at the level of the osteosynthesis.

Results

The demographic data are illustrated in Table 1. Two males and ten females with a mean age of 67,8 (18 ~ 90) years were included in our study. All were closed fractures. The median delay from injury to surgical procedure was 2,8 (1 ~ 6) days. None of the patients had any neurological or vascular deficit at the time of admission. After a median follow-up of 14,9 (12 ~ 24) months, all patients regained their activities of daily living. No cases of major complications as infections, plate breakage or loosening, varus collapse, bone reabsorption were recorded. Three patients were treated with lateral plating, three patients with

medial plating and lag screws and 6 patients with double plating (lateral and medial) of the distal femur. Two patients who sustained a periprosthetic fracture complained of anterior knee pain since the 1 month follow-up consultation. When asked about the pain, both patients reported that it was present in the months following the TKA procedure. All incisions healed by first intention.

The postoperative joint function was graded according the functional evaluation scoring system described by Sanders: 4 cases excellent, 8 cases good, no cases with fair or poor scores. The mean score was 34,8 (30 ~ 40). Among them, 7 patients had maximal flexion of more than 120°, 5 patients had flexion between 90° and 120°, no patient showed a flexion below 90°.

Discussion

This study showed that the modification of the classical "*swashbuckler approach"* has allowed for an appropriate internal fixation of distal femoral fractures: the rate of complications, related to the surgical approach, was very low.

Displaced or comminuted distal femur fractures require anatomic reduction of the articular surface since literature agrees that articular incongruity leads to poor outcomes [9]. In order to achieve this goal, the surgeon must be able to fully visualize and address the proximal end of the knee joint. Historically, the direct lateral access proposed by Marcy in 1947 [10] has represented the gold standard in a distal femoral fracture scenario. Unfortunately, this approach lacks the visualization of the entire medial condyle and trochlea as well as the severance of multiple perforating arteries: its association with a medial parapatellar incision can be tempting but the soft tissue vascularization is exposed to a high risk of necrosis; moreover, its proximal extension is laborious and time wasting. The Olerud approach [11] guarantees visualization but the current authors believe that prolonged post-operative immobilization is not recommended for an elderly patient. Nevertheless, tibial tuberosity osteotomy (TTO) ensures wide intercondylar visualization but the integrity of the extensor apparatus is essential for weightbearing and early mobilization [11][12]. Starr et al [13] claimed that their "swashbuckler" approach allowed for wide visualization of the distal femur without damaging the extensor apparatus. Dugan et al. [14] reported poor knee ROM after this approach was applied to a series of patients; interestingly, Khalil and Ayoub [15] reported multiple complications, including infections, non-unions, delayed tibial tuberosity osteotomy healing, in several young patients who sustained 33-C3 fractures. On the other side, a TTO is useful in a periprosthetic fracture scenario but several authors reported severe complications [16][17] [18].

Beltran et al. [19] proposed a minimally invasive version of the classical *"Swashbuckler approach"*: this modification significantly reduced the length of the skin incision and quadriceps stripping from the meta-diaphyseal bone but it was found not useful in fractures with meta-diaphyseal extension. Several case reports and case series have confirmed the validity of the *"Swashbuckler approach"* proposed by Starr [20][21][22][3].

The main drawback of the *"Swashbuckler approach"* in all its modified versions is the inclusion of a lateral parapatellar arthrotomy which may undermine the lateral supply to the anastomotic patellar ring

[23]. In fact, recent literature has identified poor vascularization as one of the etiologies of postoperative anterior knee pain as well as patellar necrosis and stress fractures [24][25][26][27][28]. The current authors developed a modification of the *"Swashbuckler approach"* with the primary intention of not reducing blood flow to the patella while maintaining the ability to mobilize the extensor mechanism and gain access to the medial condyle. Lazaro et al [29] in their cadaveric study, defined patellar anastomotic ring "safety margins" while performing a knee arthrotomy: they found that a tissue cuff greater than 15 mm, both medially and laterally, ensured the patellar blood supply not be damaged. Based on these findings, the current authors decided to perform the arthrotomy with a minimum 2 cm margin. This choice did not lead to a reduction in the mobility of the extensor apparatus allowing the surgeon to perform double plates synthesis if indicated (Fig. 3a, 3b, 4a, 4b, 5a, 5b)s. In light of recent literature, internal fixation with a medial and lateral plate appears to be the gold standard in the treatment of distal femur fractures in the elderly population, which may benefit from early loading and mobilization in terms of lower mortality, inferior morbidity and overall better function [1][30][31] [32][33][34][35][36]. On the other side, if a TKA will be subsequently indicated, the surgeon could decide whether to perform a more familiar medial approach or a lateral one being not afraid of ischemic complications involving the patella and the adjacent soft tissues. The current authors made the same considerations with an inverse temporal order regarding double plating of periprosthetic fractures. Knowing that the anastomotic circle has been interrupted from the medial side, the authors were able to safely visualize and instrument the entire fracture by incising laterally, keeping the previously described arthrotomy margin [29].

There are a number of weaknesses in the present study. The authors sample size is small in order to draw conclusions applicable to the general population: although they did not encounter any difficulties in patellar mobilization during the surgical procedures, this statement should be verified and supported by future cadaveric studies [37]. In support of the authors conclusions, a contrast enhanced knee MRI study could be useful to verify the integrity of the peri-patellar circulation and a doppler ultrasound study could verify the intra-patellar blood flow [38][39]. Another limitation of the current study is the difference in the skin incision between the current authors and Starr et al [13] and by Beltran et al [19]: the current authors decided to make a skin incision 2 cm lateral to the patellar tendon. However, we do not believe that this can constitute a substantial difference in comparison with the other authors, although it makes a subsequent medial knee incision more feasible.

Conclusion

Fractures of the distal femur, whether on native bone or prosthetic implant, are increasing in number and their mortality is equal to those of the proximal femur. The authors believe that this modified approach represents a solution to meet the modern demands for robust fixation and early mobilization without incurring in ischemic damage to the patella and the periarticular soft tissues.

Abbreviations

TTO: tibial tuberosity osteotomy; AO/OTA: AO Foundation/Orthopaedic Trauma Association; CT: computerized tomography

Declarations

Ethics approval and consent to participate

This study was approved by the Department of Orthopedic Surgery, San Carlo Borromeo Hospital, Milano, Italy. Written informed consent was obtained from each patient and the study was conducted in accordance with the Declaration of Helsinki.

Consent for publication

Not applicable.

Availability of data and material

The datasets used and/or analyzed in the current study are available from the corresponding author on reasonable request.

Competing interests

The authors declare that they have no competing interests.

Funding

No funding was obtained for this study.

Authors' contributions

SG: Analysis of data and writing the manuscript; GT: Study conceptualization

and design. GA: Study conceptualization and design, Reviewing and editing

the draft manuscript; ET: Data collection and analysis; BV: Reviewing and editing the draft manuscript. PFI: Analysis of data and writing the manuscript; All authors agreed to submit the manuscript for publication in this journal. All authors read and approved the final manuscript.

Acknowledgements

The authors thank all clinical researchers involved in this study.

References

[1] S. M. Tarrant and Z. J. Balogh, “The Global Burden of Surgical Management of Osteoporotic Fractures,” *World J. Surg.*, vol. 44, no. 4, pp. 1009–1019, Apr. 2020, doi: 10.1007/s00268-019-05237-y.

[2] L. Bogunovic, S. M. Cherney, M. A. Rothermich, and M. J. Gardner, “Biomechanical Considerations for Surgical Stabilization of Osteoporotic Fractures,” *Orthopedic Clinics of North America*, vol. 44, no. 2. Orthop Clin North Am, pp. 183–200, Apr. 2013, doi: 10.1016/j.ocl.2013.01.006.

[3] M. S. Daroch, D. Vashisht, and S. Sreen, “Management of intra-articular fracture of distal femur with LCP and Lag screws in adults,” *Int. J. Res. Med. Sci.*, vol. 5, no. 4, p. 1434, 2017, doi: 10.18203/2320-6012.ijrms20171241.

[4] N. A. Ebraheim, L. H. Kelley, X. Liu, I. S. Thomas, R. B. Steiner, and J. Liu, “Periprosthetic Distal Femur Fracture after Total Knee Arthroplasty: A Systematic Review,” *Orthop. Surg.*, vol. 7, no. 4, pp. 297–305, 2015, doi: 10.1111/os.12199.

[5] A. Von Keudell, K. Shoji, M. Nasr, R. Lucas, R. Dolan, and M. J. Weaver, “Treatment options for distal femur fractures,” *Journal of Orthopaedic Trauma*, vol. 30. Lippincott Williams and Wilkins, pp. S25–S27, 2016, doi: 10.1097/BOT.0000000000000621.

[6] J. L. Marsh *et al.*, “Fracture and dislocation classification compendium - 2007: Orthopaedic Trauma Association Classification, Database and Outcomes Committee,” *Journal of Orthopaedic Trauma*, vol. 21, no. 10 SUPPL. Lippincott Williams and Wilkins, 2007, doi: 10.1097/00005131-200711101-00001.

[7] R. D. A. P. L. L. C H Rorabeck, “Fractures of the femur, tibia, and patella after total knee arthroplasty: decision making and principles of management - PubMed,” *Instr Course Lect.* , vol. 47, pp. 449–458, 1998.

[8] R Sanders , M Swiontkowski, H Rosen, D Helfet. Double-plating of comminuted, unstable fractures of the distal part of the femur. *J Bone Jt. Surg Am.*, vol. 73, no. (3), pp. 341–46, Mar. 1991.

[9] A. P. . Browner BD , Jupiter JB , Kretteck C, *Principles of Internal Fixa- tion. Skeletal Trauma: Basic Science, Management, and Reconstruction. 6th ed.* Philadelphia, PA: Elsevier, 2020.

[10] GH Marcy, "The posterolateral approach to the femur". *J Bone Jt. Surg Am.*, vol. 29, no. (3), pp. 676–678, Jul. 1947.

[11] S Olerud, "Operative treatment of supracondylar–condylar fractures of the femur. Technique and results in fifteen cases". *J Bone Jt. Surg Am.*, vol. 54, no. (5), pp. 1015–32, Jul. 1972.

[12] A. Khlopas, L. T. Samuel, A. A. Sultan, B. Yao, D. G. Billow, and A. F. Kamath, “The Olerud Extensile Anterior Approach for Complex Distal Femoral Fractures: A Systematic Review,” *J. Knee Surg.*, vol. 1, no. 212, 2019, doi: 10.1055/s-0039-3400954.

[13] A. J. Starr, “The ‘swashbuckler’: A modified anterior approach for fractures of the distal femur,” *J. Orthop. Trauma*, vol. 13, no. 2, pp. 138–140, 1998, doi: 10.1097/00005131-199902000-00012.

[14] T. R. Dugan, M. G. Hubert, P. A. Siska, H. C. Pape, and I. S. Tarkin, “Open supracondylar femur fractures with bone loss in the polytraumatized patient - Timing is everything!,” *Injury*, vol. 44, no. 12, pp. 1826–1831, Dec. 2013, doi: 10.1016/j.injury.2013.03.018.

[15] A. E. S. Khalil and M. A. Ayoub, “Highly unstable complex C3-type distal femur fracture: Can double plating via a modified Olerud extensile approach be a standby solution?,” *J. Orthop. Traumatol.*, vol. 13, no. 4, pp. 179–188, 2012, doi: 10.1007/s10195-012-0204-0.

[16] C. B. L. Zonnenberg, L. A. Lisowski, M. P. J. van den Bekerom, and P. A. Nolte, “Tuberositas osteotomy for total knee arthroplasty: a review of the literature.,” *The journal of knee surgery*, vol. 23, no. 3. J Knee Surg, pp. 121–129, Sep. 2010, doi: 10.1055/s-0030-1267472.

[17] S. R. Piedade, A. Pinaroli, E. Servien, and P. Neyret, “Tibial tubercle osteotomy in primary total knee arthroplasty: A safe procedure or not?,” *Knee*, vol. 15, no. 6, pp. 439–446, Dec. 2008, doi: 10.1016/j.knee.2008.06.006.

[18] K. C. Chun, S. H. Kweon, D. J. Nam, H. T. Kang, and C. H. Chun, “Tibial Tubercle Osteotomy vs the Extensile Medial Parapatellar Approach in Revision Total Knee Arthroplasty: Is Tibial Tubercle Osteotomy a Harmful Approach?,” *J. Arthroplasty*, vol. 34, no. 12, pp. 2999–3003, Dec. 2019, doi: 10.1016/j.arth.2019.07.015.

[19] M. J. Beltran, J. A. Blair, J. Huh, J. M. Kirby, and J. R. Hsu, “Articular exposure with the swashbuckler versus a ‘mini- swashbuckler’ approach,” *Injury*, vol. 44, no. 2, pp. 189–193, 2013, doi: 10.1016/j.injury.2012.10.021.

[20] B. Harna, A. Goel, P. Singh, and D. Sabat, “Pediatric conjoint Hoffa’s fracture: An uncommon injury and review of literature,” *J. Clin. Orthop. Trauma*, vol. 8, no. 4, pp. 353–354, 2017, doi: 10.1016/j.jcot.2016.12.001.

[21] R. Singh, R. B. Singh, and M. Mahendra, “Functional outcome of isolated hoffa fractures treated with cannulated cancellous screw,” *Malaysian Orthop. J.*, vol. 11, no. 2, pp. 20–24, 2017, doi: 10.5704/MOJ.1707.016.

[22] G. K. Gupta and R. V. Jacob, “Demographic profile and functional outcome following fixation of distal femur fractures by locking compression plate,” *Int. J. Orthop. Sci.*, vol. 6, no. 1, pp. 79–82, 2020, doi: 10.22271/ortho.2020.v6.i1b.1843.

[23] H. DeBell *et al.*, “Vascular supply at risk during lateral release of the patella during total knee arthroplasty: A cadaveric study,” *J. Clin. Orthop. Trauma*, vol. 10, no. 1, pp. 107–110, 2019, doi: 10.1016/j.jcot.2017.11.009.

[24] B. S. W. Noorpuri and M. Maqsood, “Osteonecrosis of the patella and prosthetic extrusion after total knee arthroplasty,” *J. Arthroplasty*, vol. 17, no. 5, pp. 662–663, 2002, doi: 10.1054/arth.2002.33270.

[25] S. Putman, F. Boureau, J. Girard, H. Migaud, and G. Pasquier, “Patellar complications after total knee arthroplasty,” *Orthopaedics and Traumatology: Surgery and Research*, vol. 105, no. 1. Elsevier Masson SAS, pp. S43–S51, Feb. 01, 2019, doi: 10.1016/j.otsr.2018.04.028.

[26] J. P. hilip. Schüttrumpf *et al.*, “Radiologically hyperdense zones of the patella seem to be partial osteonecroses subsequent to fracture treatment,” *J. Knee Surg.*, vol. 26, no. 5, pp. 319–326, Oct. 2013, doi: 10.1055/s-0032-1332805.

[27] V. Sanchis-Alfonso, “Patellofemorale schmerzen,” *Orthopade*, vol. 37, no. 9, pp. 835–840, Sep. 2008, doi: 10.1007/s00132-008-1289-2.

[28] K. M. Baumgarten, M. A. Mont, A. Rifai, and D. S. Hungerford, “Atraumatic osteonecrosis of the patella,” *Clin. Orthop. Relat. Res.*, no. 383, pp. 191–196, 2001, doi: 10.1097/00003086-200102000-00021.

[29] L. E. Lazaro, M. B. Cross, and D. G. Lorich, “Vascular anatomy of the patella: Implications for total knee arthroplasty surgical approaches,” *Knee*, vol. 21, no. 3, pp. 655–660, 2014, doi: 10.1016/j.knee.2014.03.005.

[30] V. Peschiera, L. Staletti, M. Cavanna, M. Saporito, and M. Berlusconi, “Predicting the failure in distal femur fractures,” *Injury*, vol. 49, pp. S2–S7, 2018, doi: 10.1016/j.injury.2018.10.001.

[31] T. Jennison and M. Divekar, “Geriatric distal femoral fractures: A retrospective study of 30 day mortality,” *Injury*, vol. 50, no. 2, pp. 444–447, Feb. 2019, doi: 10.1016/j.injury.2018.10.035.

[32] A. Sain, V. Sharma, K. Farooque, M. V, and K. Pattabiraman, “Dual Plating of the Distal Femur: Indications and Surgical Techniques,” *Cureus*, vol. 11, no. 12, 2019, doi: 10.7759/cureus.6483.

[33] E. L. Steinberg, J. Elis, Y. Steinberg, M. Salai, and T. Ben-Tov, “A double-plating approach to distal femur fracture: A clinical study,” *Injury*, vol. 48, no. 10, pp. 2260–2265, Oct. 2017, doi: 10.1016/j.injury.2017.07.025.

[34] E. Yaacobi, D. Sanchez, H. Maniar, and D. S. Horwitz, “Surgical treatment of osteoporotic fractures: An update on the principles of management,” *Injury*, vol. 48, pp. S34–S40, Dec. 2017, doi: 10.1016/j.injury.2017.08.036.

[35] P. Consigliere, E. Iliopoulos, T. Ads, and A. Trompeter, “Early versus delayed weight bearing after surgical fixation of distal femur fractures: a non-randomized comparative study,” *Eur. J. Orthop. Surg. Traumatol.*, vol. 29, no. 8, pp. 1789–1794, Dec. 2019, doi: 10.1007/s00590-019-02486-4.

[36] P. Larsen, A. A. Ceccotti, and R. Elsoe, “High mortality following distal femur fractures: a cohort study including three hundred and two distal femur fractures,” *Int. Orthop.*, vol. 44, no. 1, pp. 173–177, Jan.

2020, doi: 10.1007/s00264-019-04343-9.

[37] J. M. Stevens, N. D. Clement, G. Macpherson, and J. T. Patton, “Comparison of two extensile approaches to the knee: a cadaveric study evaluating quadriceps snip and extensile medial parapatellar approach,” *J. Orthop.*, vol. 15, no. 2, pp. 416–419, Jun. 2018, doi: 10.1016/j.jor.2018.03.023.

[38] R. L. Nicholls, D. Green, and M. S. Kuster, “Patella intraosseous blood flow disturbance during a medial or lateral arthrotomy in total knee arthroplasty: A laser Doppler flowmetry study,” *Knee Surgery, Sport. Traumatol. Arthrosc.*, vol. 14, no. 5, pp. 411–416, 2006, doi: 10.1007/s00167-005-0703-0.

[39] N. C. Rollick *et al.*, “The effects of dual plating on the vascularity of the distal femur,” *Bone Jt. J.*, vol. 102 B, no. 4, pp. 530–538, 2020, doi: 10.1302/0301-620X.102B4.BJJ-2019-1776.

Tables

Table 1. General information of the patients

Item	
Gender (male/female)	2/10
Mean age (years)	67,8
Fracture region (left/right)	6/6
Injury cause	
Vehicular accidents	2
Fall injuries	10
AO/OTA classification: 33	
A2	1
A3	4
B2	1
C1	2
C3	1
Rorabeck-Lewis classification of supracondylar periprosthetic femoral fracture (Type II)	3

Table 2
Injury characteristics of the patients

Case	Age (Years)	Gender	Diagnosis	Treatment	Follow-up (months)	Major complications	Sanders Scoring System
1	18	M	AO 33 C1	Lateral plate	24	None	40
2	64	F	AO 33 B2	Media plate & lag screws	20	None	37
3	66	F	LR 2	Lateral & medial plate	16	Anterior Knee Pain	34
4	36	M	AO 33 A3	Lateral & medial plate	14	None	40
5	72	F	AO 33 B2	Media plate & lag screws	12	None	36
6	74	F	AO 33 A3	Lateral plate	20	None	33
7	90	F	LR 2	Lateral & medial plate	12	Anterior Knee Pain	34
8	82	F	AO 33 C3	Lateral & medial plate	12	None	37
9	90	F	AO 33 A3	Lateral & medial plate	12	None	28
10	88	F	LR2	Media plate & lag screws	12	None	34
11	45	F	AO 33 A3	Lateral plate	12	None	35
12	89	F	AO 33 A2	Lateral & medial plate	13	None	30

Figures

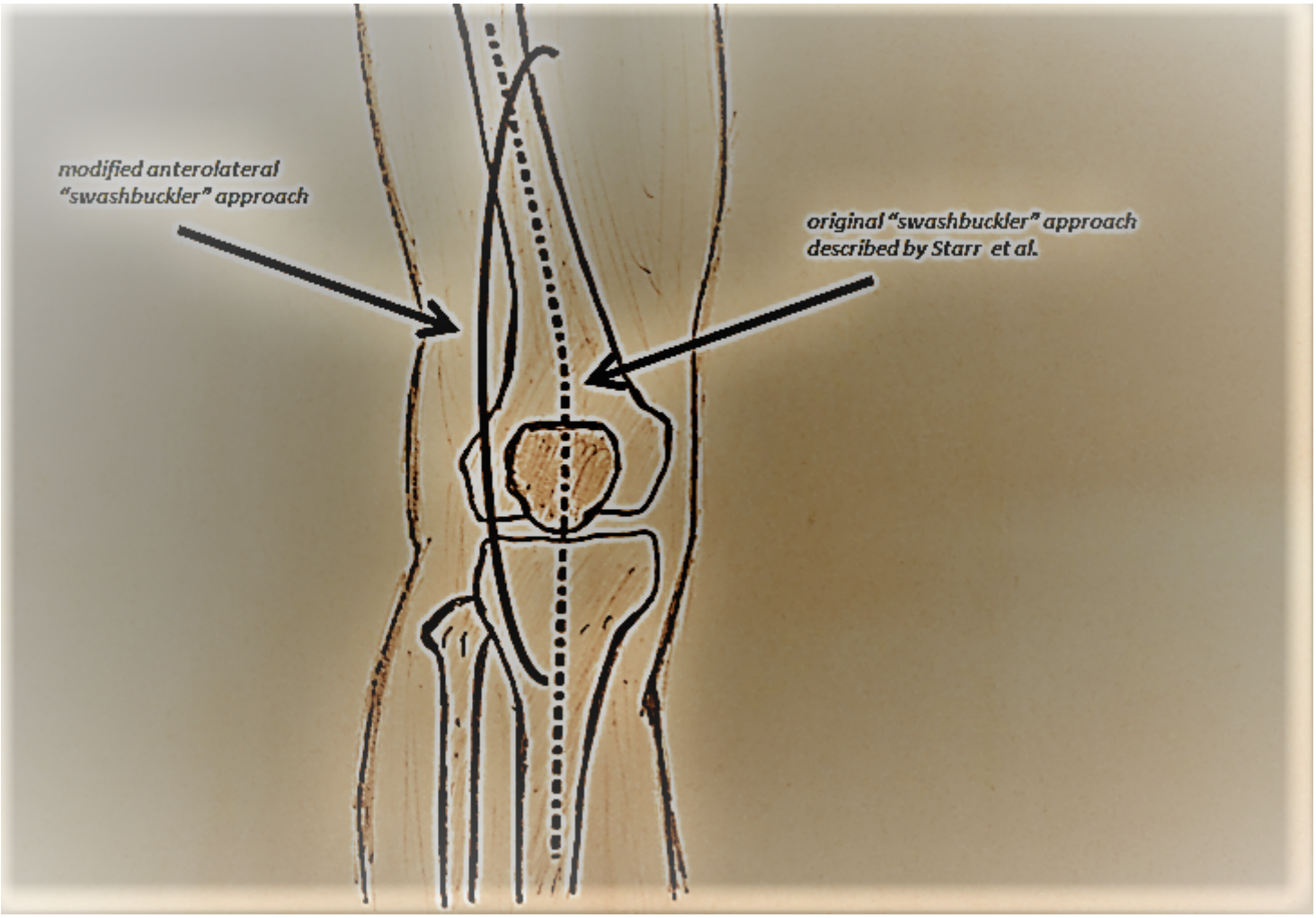

Figure 1

Modified anterolateral swashbuckler approach: a smooth curve incision which distally maintains a distance of about 2 cm from the lateral border of the patellar tendon.

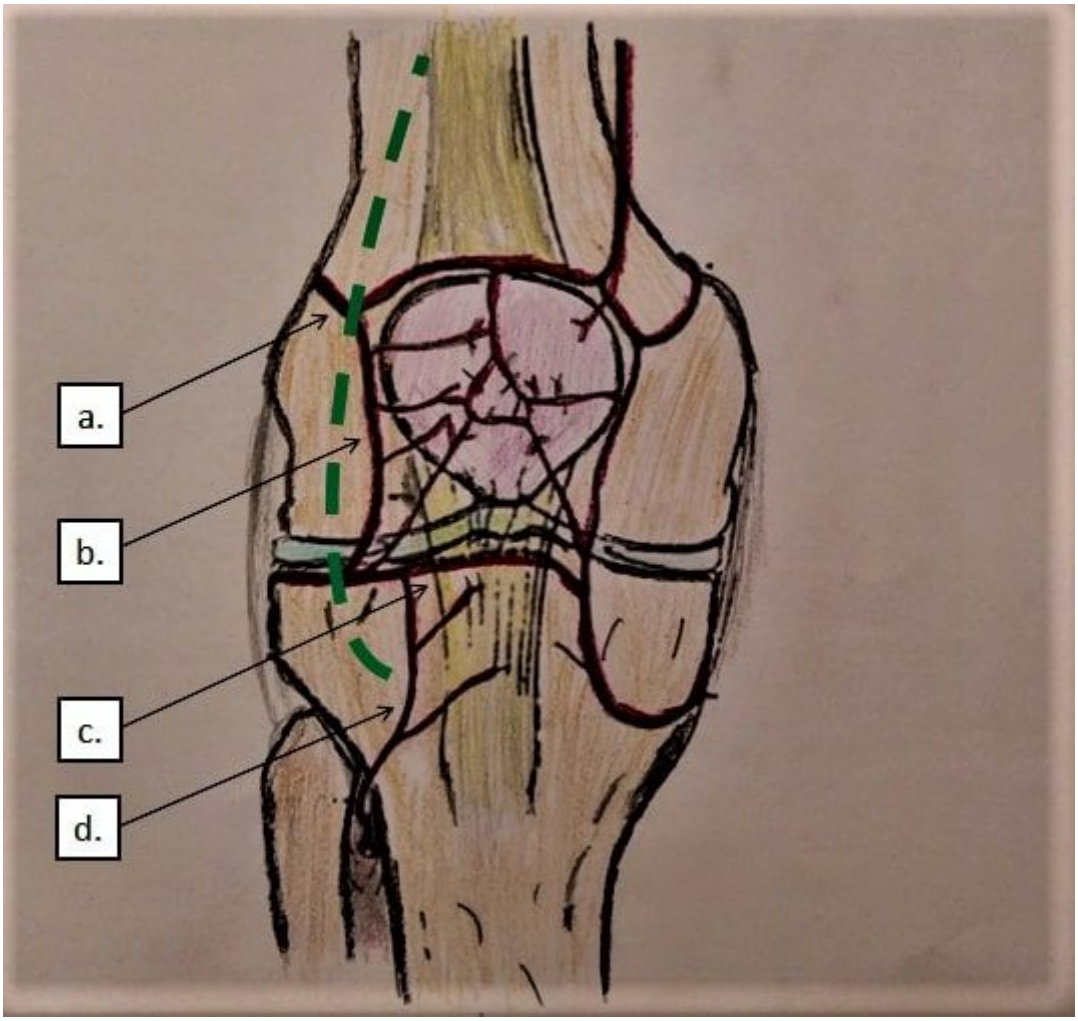

Figure 2

a. Lateral Superior Genicular Artery b. Lateral Ascending Parapatellar Artery c. Trasverse Infrapatellar Artery d. Anterior Tibial Reccurent Artery The superior lateral geniculate artery is ligated, whereas the lateral ascending artery, the transverse infrapatellar and the anterior tibial recurrent artery should be preserved.

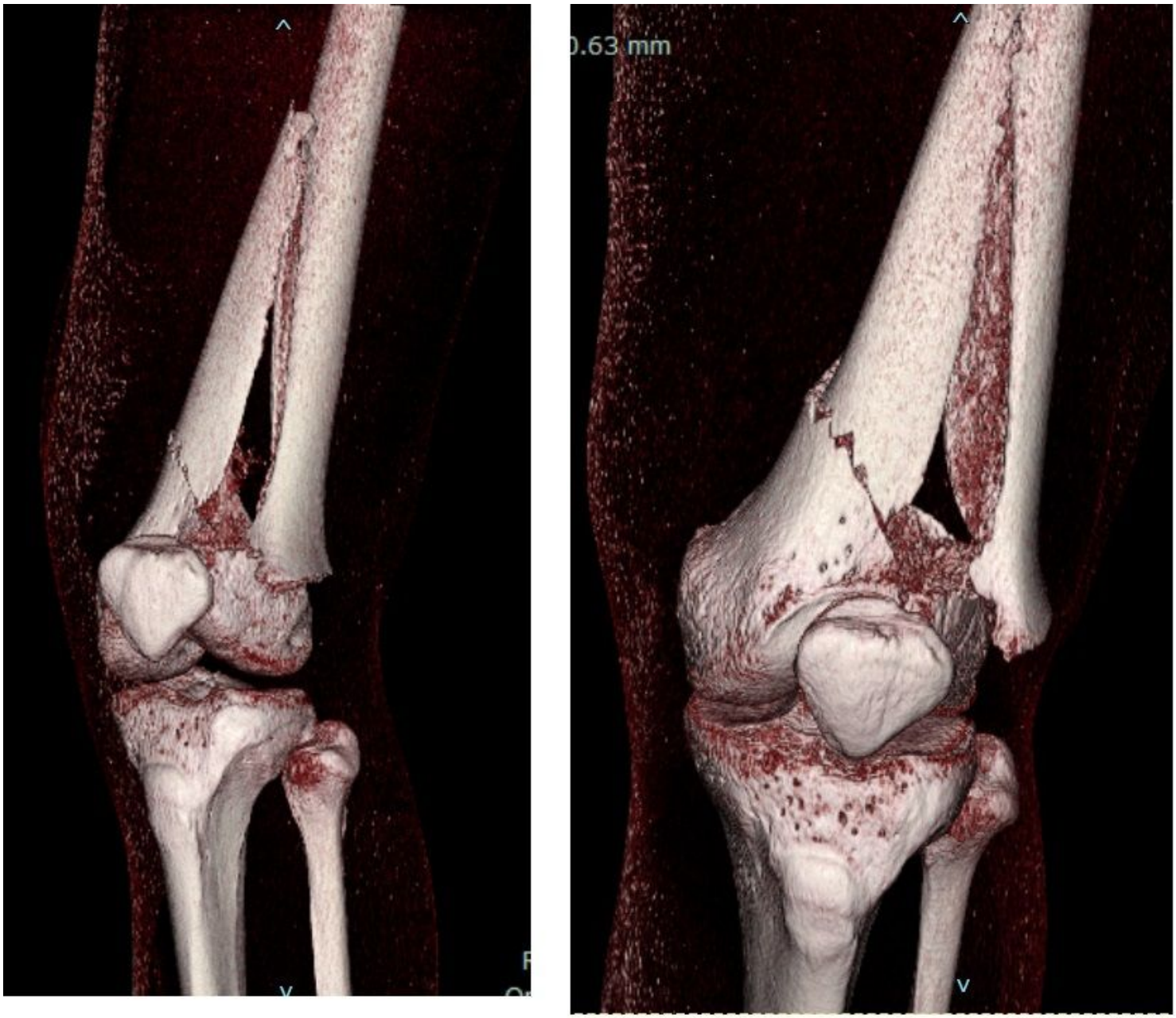

Figure 3

Male patient, 36 years old, AO 33 A3 type distal femur fracture according to the AO/OTA classification.

Figure 4

X-rays one month after surgery. Double plating fixation of the distal femur.

Figure 5

X-rays 12 months after surgery: the bone callus is visible with clear signs of fracture healing.