Radiographic assessment of different autogenous bone grafts in the alveolar cleft: a retrospective longitudinal study

Guilherme Strujak
Positivo University

Daniel Amaral Alves Marlière
State University of Campinas

Yuri de Lima Medeiros (yuri.medeiros@odontologia.ufjf.br)
A.C.Camargo Cancer Center

João Luiz Carlini
Federal University of Paraná

Antônio Adilson Soares de Lima
Federal University of Paraná

Research Article

Keywords: Bone graft, Cleft lip and palate, Bone resorption, Child

Posted Date: April 13th, 2022

DOI: https://doi.org/10.21203/rs.3.rs-1541451/v1

Abstract

Purpose: To assess feasibility and maintenance of bone after alveolar cleft reconstructions using graft from iliac crest and mandibular synthesis.

Methods: 51 alveolar clefts grafted with iliac crest and 51 ones grafted with mandibular symphysis bones were selected from patients aged between 7 and 12 years. At three (T1) and 12 months (T2) after surgeries, periapical radiographs were performed to measure the height of the grafted bone based on the Bergland scale. Chi-square and Mann-Whitney-Wilcoxon tests compared differences between T1 and T2 according to each bone graft.

Results: From the clefts grafted with mandibular symphysis bone, 47 were classified as type I (92.5%) and 04 as type II (7.84%) at T1. At T2, 36 were classified as type II (25.49%) and 02 as type III (3.92%). In the analysis of the clefts grafted with iliac crest at T1, 48 were classified as type I (94.11 %) and three as type II (5.88%). At T2, 37 classifieds as type I (72.54%), 12 as type II (23.52%) and two as type III (3.92%). There was no statistically significant difference between treatments.

Conclusions: It was concluded that iliac crest and mandibular symphysis are adequate areas from which bone grafts can be obtained for reconstruction of alveolar cleft.

Introduction

Orofacial clefts, especially cleft lip and palate, are the most prevalent congenital craniofacial defects as they have an overall prevalence of 0.45 in every 1,000 births [1]. The affected individuals may have difficulties in feeding and speaking as well as dental and hearing problems. The treatment of cleft lip and palate involves several craniofacial and dental surgeries associated with speech therapy. The surgical closure of the cleft lip and palate is performed in the first months of life, provided that the patient is able to undergo the procedures. Reconstruction of the alveolar cleft plays an important role [2].

Although there are multiple indications for bone reconstruction of alveolar cleft, the primary reason is to provide amount and quality of bone in the area of the defect in order to allow adjacent teeth to erupt and orthodontic movement. In addition, bone grafting is indicated for closure of nasal fistulas so that the base of the nose can be supported and to allow placement of osseous-integrated implants if teeth are missing [3, 4].

In the literature, there are various bone grafting options for reconstruction of alveolar crest [5]. However, none of them was proved to be superior or even equivalent to autogenous bone grafting [3, 6]. Iliac crest, mandibular symphysis, skull cap and rib can be the donor sites of autogenous bone, and they are chosen depending on several factors, such as experience and preference of the surgeon, amount of bone and morbidity associated with the bone removed from the donor site [7].

Despite the high rates of resorption and post-operative morbidity, the iliac crest bone is the most used as a grafting material [7, 8]. However, some studies show that mandibular symphysis is a viable source of bone graft for alveolar reconstruction [6, 9–13]. Therefore, the objective of the present study was to assess bone feasibility and maintenance after alveolar cleft reconstructions by using bone grafts from iliac crest and mandibular synthesis.

Materials And Methods

This study was approved by the Research Ethics Committee of the Health Science Department of the Federal University of Parana according to CAAE number 23304114,1,0000,0102 and following the World Medical Association's Declaration of Helsinki.

Sample Selection

Patients with alveolar cleft defects who were submitted to bone grafting treatment at the Centre for Cleft Lip and Palate Treatment (CAIF) in Curitiba, PR, in the period from January 2007 to December 2008 were evaluated for study.

Clinical records of both male and female patients, all presenting unilateral or bilateral transforamen clefts, aged between 7 and 12 years old and who underwent bone grafting treatment, in which iliac crest or mandibular symphysis were the donor sites, were included. Patients with insufficient radiographic documentation as well as those presenting syndromic oral clefts were excluded.

Prior to surgery for reconstruction of the alveolar cleft, the patients were submitted to surgical closure of the clef lip and palate, which was performed in the first years of life once they were able to undergo the procedures. The patients remained under multidisciplinary follow-up. In this context, each patient underwent orthodontic treatment when the first permanent teeth erupted so that possible transverse discrepancies between maxillary and mandibular arches could be corrected. Whenever necessary, the patients underwent maxillary expansion before bone grafting surgery. In this step, the chronological age and dental development of the patient should be taken into consideration. Moreover, bone grating surgery should be performed before the canine erupts in the region of the alveolar cleft.

Surgical Procedure

The same reconstruction technique was used in all patients, regardless of the donor site, which consisted in separating the mouth from the nasal cavity and filling the alveolar cleft with bone tissue. The surgery was performed under general anesthesia with nasotracheal tube placed into the nostril opposite to the cleft in unilateral patients and with orotracheal intubation in the bilateral ones.

After infiltration of local anaesthetic with adrenaline at a ratio of 1:200,000 (Cristália, Itapira, São Paulo, Brazil) in the cleft region and oropharyngeal packing, two vertical incisions were made (one in each edge of the cleft) with a scalpel blade #15 (Solidor, Diadema, São Paulo, Brazil) bilaterally along the prolongations of the sulci. The size of the intra-sulcular incision ranged depending on the size of the cleft,

which usually involves two neighbouring teeth on each side of the cleft. Next, sub-periosteal displacement was proceeded (Fig. 1A-C).

In this moment, oral mucosa was separated from the nasal mucosa, which was cut inferiorly in order to obtain an adequate amount of tissue for suture with Vicryl 4.0 (Ethicon, São Paulo, São Paulo, Brazil) and to reconstruct the nasal mucosa floor with no tension (Fig. 1D). Next, the bone graft was placed in the alveolar cleft and suture performed (Fig. 1E).

Regardless of the origin of the bone graft, immobilisation was performed using less fixation material as possible to keep the graft stable in position. Because both symphysis and iliac crest bone grafts were used as block, the form of fixation was chosen according to the following order until reaching the necessary stability: 1) under pressure, 2) with 1.5-mm fixation screw, 3) with two 1.5-mm fixation screws, and 4) with plate and at least three 1.5-mm fixation screws (MDT, Rio Claro, São Paulo, Brazil).

Some pointed edges were observed after fixation of the graft, which might cause injury to the lining mucosa. In these cases, a spherical diamond bur was used to erode them. Next, relieving incisions were made in the periosteum and the oral mucosa was sutured over the graft with single stitches by using nylon thread 4 – 0 (Ethicon, São Paulo, São Paulo, Brazil) (Fig. 1F). Patients with bilateral cleft were submitted to the same grafting technique, with the premaxilla (anterior dental segment) being repositioned.

The patients remained hospitalised for 24 hours and were medicated with antibiotic, anti-inflammatory and analgesic drugs. After discharge, the patients were instructed on oral care and how to clean the wound, which should be performed with gauze moistened with 0.12% chlorhexidine solution. The medications used by the patients after discharge were amoxicillin 250ml/5ml every 8 hours for 7 days and sodium dipyrone 500 mg/1mL every 6 hours for 3 days. Sutures were removed after two weeks from the surgery.

Radiographic Evaluation

Periapical radiographs were acquired three months after the surgery (T1) to evaluate the condition of the graft and to plan the removal of the fixation material. After 12 months from the surgery (T2), the patients were submitted again to periapical radiography, and the radiographs were digitalised with a HP scanner (Scanjet G4050, Hewlett-Packard Company, Palo Alto, CA, USA) at a resolution of 200 ppi and full scale.

The digitalised radiographs were evaluated by two surgeon-dentists (G.S. and D.A.A.M.) based on the Bergland scale,[14] which classifies the height of the grafted bone as type I (normal height), type II (up to ¾ of the normal height, type III (less than ¾ of the normal height) and type IV (no bone bridge) (Fig. 2). The surgeon-dentists were blinded to the identification of the patients and the group to which they belonged.

The upper central incisor on the side of the cleft was used as a reference to divide the granted bone into thirds for further classification, since T1 radiograph showed that the canine had not yet been erupted. For doing so, a line was drawn along the long axis of the central incisor and the thirds were divided equally

and perpendicularly to this line from the enamel-cement boundary. This change was made in order to evaluate the absence of the upper canine and to compensate any error in the standardised acquisition of radiographs, although the radiographic examination had been performed with a positioner and the same X-ray unit (Gnatus Timex 66, Ribeirão Preto, São Paulo, Brazil).

The Dental Imaging Software, version 6.13.3, (Rochester, NY, USA) was used for measuring the full-size radiographs. The two post-operative radiographs (i.e. T1 and T2) of each patient were examined and given scores. They were compared to know whether there was any change in the height of iliac and symphysis bone grafts inserted in the clefts only, since the quantification of resorption was not the aim of this study.

Data Collection and Assessment

The following data were collected from the clinical records of the patients: gender, age, graft type, presence of impacted canine, date of the first and last radiographs, follow-up length and Bergland scale [14]. Each patient received a number so that they could not be identified.

It was defined that 20 radiographs should be evaluated for calibration, thus the first 20 ones were selected and each examiner performed two evaluations with a 15-day interval between them. The examiners completed a table with data on type of graft and classification of the height of the alveolar bone septum. Next, the data were tabulated and submitted to weighted kappa test.

Statistical Analysis

Chi-square and Mann-Whitney-Wilcoxon tests were performed by using the Statgraphics Centurion XV software, version 15.1.02 (StatPoint Technologies, Inc, Warrenton, VA, USA), whereas kappa analysis was performed by using the statistical R software, version 3.0.0, (R Foundation for Statistical Computing, Vienna, Austria). Intra- and inter-rater agreements were calculated by using the intra-class correlation coefficient (ICC).

Because these data are categorical and do not follow a normal distribution (Kolmogorov-Smirnov test, $P < 0.001$), non-parametric tests were used for analysis.

Results

The results of ICC demonstrated that the examiners were calibrated as intra-rater reliability values were 0.82 and 0.80 for examines 1 and 2, respectively, and inter-rater reliability was 0.81, thus indicating excellent agreement.

A total of 186 patients were found after gathering data during the study period. Of these, clinical records of 40 patients were not found, 17 patients were older than the required age, 28 patients were excluded due to lack of radiographic documentation, 20 patients had incomplete pre-foramen clefts, five patients had bilateral clefts and absence of teeth in the pre-maxilla, and one patient had complex facial cleft.

Therefore, 75 patients were included for study in which 48 had unilateral cleft lip and palate (33 males and 15 females) and 27 had bilateral cleft lip and palate (18 males and 9 females). In the final, 102 cases of cleft lip and palate treated with each type of graft were evaluated (i.e. 51 with symphysis bone graft and 51 with iliac bone graft). Statistically significant differences were found regarding the interval between the acquisitions of radiographs, in which the follow-up length was longer in patients with iliac graft (Table I).

With regard to alveolar clefts grafted with symphysis bone, T1 radiographs showed that 47 were of type I (92.15%) and four of type II (7.84%), whereas T2 radiographs showed that 36 were of type I (70.58%), 13 of type II (25.49%) and two of type III (3.92%). As for alveolar clefts grafted with iliac crest bone, on the other hand, T1 radiographs showed that 48 were of type I (94.11%) and three of type II (5.88%), whereas T2 radiographs showed that 37 were of type I (72.54%), 12 of type II (23.52%) and two of type III (3.92%).

By analysing both variables for differences in the measurements made at T1 and T2, it was found that there were significant differences in patients treated with mandibular symphysis bone graft as well as in those treated with iliac crest bone graft, thus indicating presence of resorption in both groups of patients. When the scores of the radiographs showing clefts grafted with symphysis bone were compared to those showing clefts grafted with iliac bone, no statistically significant differences were observed between both groups (Table II).

Scores of types I and II were dichotomised as being a success, whereas types III and IV as being a failure, meaning that a new graft was necessary. No statistically significant differences were found between the results of the measurements made at T1 and T2 in both groups of patients (Table III).

There was no correlation between time interval of acquisition and results obtained ($P = 0.2824$).

Discussion

Secondary alveoloplasty with autogenous bone graft is the most commonly procedure used to reconstruct alveolar clefts [15]. Despite the resorption rates and post-operative morbidity, the iliac crest bone is the most used as a grafting material [7, 8], thus being the donor site preferred by the majority of the cleft treatment centres [16]. Nevertheless, the results presented in our study demonstrated that mandibular symphysis bone graft, when used to reconstruct alveolar clefts in patients aged between 7 and 12 years old, has a behavior similar to that of the iliac crest one.

Extraction of bone grafting material from the mandibular symphysis is described as being more advantageous than the iliac crest because of lower morbidity rate, shorter hospitalization and absence of skin scar [17], in addition to better bone incorporation as both mandible and maxilla have the same ectomesenchymal origin and intra-membranous ossification process [6]. Mandibular symphysis has a lower amount of bone available for grafting [6, 7, 17, 18], but it is a donor site near the operative field, which reduces the surgery and anaesthesia times [17].

Data on post-operative complications in the donor graft sites were not collected in the present study. Possible complications associated with the extraction of bone graft from the mandibular symphysis are lower lip ptosis, lesion in teeth adjacent to the donor site and lesion to the mentual nerve. On the other hand, extraction of bone graft from the iliac crest results necessarily in skin scar and the patients may also complain of post-operative pain, difficulty in walking [17, 19], sensorial loss, seroma, haematoma, fracture, abdominal herniation, contour defects, peritoneal perforation and keloids [8, 20].

Previous studies have determined that the age of 9–12 years old, i.e. before eruption of the canines, is the most suitable moment for performing alveolar grafting [14, 17, 21, 22]. Although our results were positive for patients with similar age (7–12 years old), Dissaux et al. [23] performed a tomographic analysis to show that alveolar bone grafts are successful when children are surgically treated earlier (i.e. around 5 years old) compared to those aged around 10 years old. Therefore, the upper lateral incisors can erupt through the grafted bone, which ensures better results in terms of residual bone height.

The results demonstrated that bone grafts from iliac crest and mandibular symphysis interfered with the upper canine eruption at the same frequency, that is, 19.6% in both groups of patients. These values were close to those reported by Sindet-Pedersen and Enemark [17], who found 15% and 20% of impacted upper canines in patients submitted to mandibular symphysis and iliac crest grafts, respectively. Sindet-Pedersen and Enemark [22] studied a sample of 28 patients with mandibular symphysis grafts and showed that all patients had the canines erupted in the grafted area, but they did not describe whether the teeth were surgically exposed or orthodontically pulled. Desai et al. [24] evaluated the eruption stage and changes in the position and pattern of canine eruption after alveolar graft from iliac crest in 30 patients aged between 9 and 13 years old. The authors found that the canine did not erupt in only 20% of the cases, demonstrating that eruption was satisfactory and the root grew continuously in the region of the grafted alveolar cleft. The risk of impacted canines is increased if they are unfavourably, either vertically or laterally, positioned before the surgery as they erupt continuously in the same graft angle.

The literature has long been evaluating the resorption of autologous bone grafts in alveolar clefts. Sindet-Pedersen and Enemark [25] compared radiographically the results of alveoloplasty with iliac crest grafting performed in patients before and after the eruption of upper canine. The authors used an approach similar to that in our study, but they divided the grafted area into quarters rather than into thirds. Of the patients with the age group and cleft classification similar to ours, they found 89.4% of type I, 9.67% of type II and 1.07 of type III. Despite the change in the classification, the results are compatible to those found at T1.

Bergland et al. [14] evaluated periapical radiographs of patients submitted to iliac crest grafting after at least 12 months from the surgery. Of the 143 patients aged 8–11 years old who underwent grafting before eruption of the canine in the area of cleft, 96% of the cases were successful, which is a result similar to ours. Enemark et al. [21] repeated the methodology used in the study by Sindet-Pedersen and Enemark [25], but with a 7-year follow-up. Among the 95 patients with cleft classification and age similar to those of our study, 71.57% were classified as type I, 23.15% as type II, 4.2% as type III and 1.05 as type

IV. Likewise, despite the different cleft classification, it should be noted that their result was worse than ours at T2. Sindet-Pedersen and Enemark [22] evaluated the radiographs of unilateral patients aged 8–15 years old for 8 months, on average, after mandibular symphysis bone grafting. Bergland scale was used and all 28 patients had their cleft categorised as type I (26 patients) or type II (2 patients). Sindet-Pedersen and Enemark [17] compared the radiographic images of unilateral cleft patients who were submitted to alveolar reconstruction. Twenty patients received the iliac crest bone graft and 20 received mandibular symphysis bone graft. The age of the patients ranged from 8 to 13 years old and the follow-up period lasted 19 months, on average. The alveolar clefts on the radiographs were classified in the same way as earlier and the authors found no significant difference in the bone height between both treatments, showing results similar to ours. One factor making it difficult to compare both groups of patients relies on the fact that the maxillary transverse discrepancies in patients with mandibular symphysis bone graft were not corrected prior to the surgery, differently from those patients with iliac crest bone graft. Such heterogeneity did not occur in our sample, thus making our assessment more reliable.

Trujillo et al. [12] used CBCT to compare the bone formation in cleft patients with mean age of 10 years old submitted to alveolar bone grafting using recombinant human bone morphogenetic protein-2 (rhBMP-2) and autogenous grafts obtained from iliac crest and mandibular symphysis. The higher mean amount of bone neoformation was achieved in patients with iliac crest bone graft (85.4%), followed by those with rhBMP-2 (81.22%) and with mandibular symphysis bone graft (80.56%). However, there was no statistically significant difference, which corroborates our findings. Lundberg et al. [26] used the Bergland scale to assess the results of the alveolar bone grafting with iliac crest bone graft in 91 patients with mean age of 9.2 years old after seven years from the surgery. The authors found a high rate of success (91%) and reported that a poor oral hygiene increased significantly the risk of surgical failure. This suggests that perioperative measures to maintain a good oral health can reduce such risk.

The rates of success found in the present study are compatible to the literature. However, it is difficult to compare it with other studies because of the different classification criteria used and differences in previous treatments before the grafting procedure. Notably, the majority of the cleft lip and palate centers perform alveoloplasty with bone from the iliac crest instead of mandibular symphysis [7, 16]. Nevertheless, the mandibular symphysis was shown to be a viable source of graft as the long-term results are compatible with those using iliac crest bones, in addition to the lower rates of complication [17, 19, 20]. Therefore, among the two options presented here, the choice of the graft donor site should be made on the basis of the necessary and available amount of bone.

Grafting procedures using bones from iliac crest and mandibular symphysis were considered to be viable when used for reconstruction of alveolar clefts in patients aged between 7 and 12 years old, since there were no statistically significant differences in the bone formation.

Declarations

Funding: This study did not receive any specific grant from funding agencies in the public, commercial, or not-for-profit sectors.

Competing Interests: The authors declare that they have no known competing financial interests or personal relationships which could have appeared to influence the work reported in this article.

Author Contributions: All authors contributed to the study conception and design. Material preparation, data collection and analysis were performed by Guilherme Strujak, João Luiz Carlini and Antônio Adilson Soares de Lima. The first draft of the manuscript was written by Guilherme Strujak, Yuri de Lima Medeiros and Daniel Amaral Alves Marlière and all authors commented on previous versions of the manuscript. All authors read and approved the final manuscript.

Ethics approval: This study was approved by the Research Ethics Committee of the Health Science Department of the Federal University of Parana (Decision no: 23304114,1,0000,0102). All procedures followed were in accordance with the ethical standards of the responsible committee on human experimentation (institutional and national) and with the Helsinki Declaration of 1975, as revised in 2008.

Consent to participate: Informed consent was obtained from all patients for being included in the study,

Consent to publish: The authors affirm that human research participants provided informed consent for publication.

Data availability statement: The datasets generated during and/or analysed during the current study are available from the corresponding author on reasonable request.

References

1. Salari N, Darvishi N, Heydari M, Bokaee S, Darvishi F, Mohammadi M (2021) Global prevalence of cleft palate, cleft lip and cleft palate and lip: A comprehensive systematic review and meta-analysis. J Stomatol Oral Maxillofac Surg 24:S2468-7855(21)00118-X.
2. Leslie EJ, Marazita ML (2013) Genetics of cleft lip and cleft palate. Am J Med Genet C Semin Med Genet 163:246–58.
3. Epker BN (2009) Alveolar-anterior maxillary cleft repair. Atlas Oral Maxillofac Surg Clin North Am 17:167–73.
4. McCrary H, Skirko JR (2021) Bone Grafting of Alveolar Clefts. Oral Maxillofac Surg Clin North Am 33:231–8.
5. Liang F, Leland H, Jedrzejewski B, Auslander A, Maniskas S, Swanson J et al (2018) Alternatives to Autologous Bone Graft in Alveolar Cleft Reconstruction: The State of Alveolar Tissue Engineering. J Craniofac Surg 29:584–93.

6. Wu C, Pan W, Feng C, Su Z, Duan Z, Zheng Q et al (2018) Grafting materials for alveolar cleft reconstruction: a systematic review and best-evidence synthesis. Int J Oral Maxillofac Surg 47:345–56.
7. Rawashdeh MA, Telfah H (2008) Secondary alveolar bone grafting: the dilemma of donor site selection and morbidity. Br J Oral Maxillofac Surg 46:665–70.
8. Boehm KS, Al-Taha M, Morzycki A, Samargandi OA, Al-Youha S, LeBlanc MR (2019) Donor Site Morbidities of Iliac Crest Bone Graft in Craniofacial Surgery: A Systematic Review. Ann Plast Surg 83:352–8.
9. Freihofer HP, Borstlap WA, Kuijpers-Jagtman AM, Voorsmit RA, van Damme PA, Heidbüchel KL et al (1993) Timing and transplant materials for closure of alveolar clefts. A clinical comparison of 296 cases. J Craniomaxillofac Surg 21:143–8.
10. Koole R, Bosker H, van der Dussen FN (1989) Late secondary autogenous bone grafting in cleft patients comparing mandibular (ectomesenchymal) and iliac crest (mesenchymal) grafts. J Craniomaxillofac Surg 17:28–30.
11. Lu M, Rabie AB (2004) Quantitative assessment of early healing of intramembranous and endochondral autogenous bone grafts using micro-computed tomography and Q-win image analyzer. Int J Oral Maxillofac Surg 33:369–76.
12. Trujillo RL, Kadioglu O, Currier GF, Smith KS, Yetkiner E (2018) Volumetric Cleft Changes in Treatment with Bone Morphogenic Protein/β-Tricalcium Phosphate Versus Grafts From the Iliac Crest or Symphysis. J Oral Maxillofac Surg 76:1991–7.
13. Wong RW, Rabie AB (1999) A quantitative assessment of the healing of intramembranous and endochondral autogenous bone grafts. Eur J Orthod 21:119–26.
14. Bergland O, Semb G, Abyholm FE (1986) Elimination of the residual alveolar cleft by secondary bone grafting and subsequent orthodontic treatment. Cleft Palate J 23:175–205.
15. Rychlik D, Wójcicki P (2012) Bone graft healing in alveolar osteoplasty in patients with unilateral lip, alveolar process, and palate clefts. J Craniofac Surg 23:118–23.
16. Witsenburg B (1985) The reconstruction of anterior residual bone defects in patients with cleft lip, alveolus and palate. A review. J Maxillofac Surg 13:197–208.
17. Sindet-Pedersen S, Enemark H (1990) Reconstruction of alveolar clefts with mandibular or iliac crest bone grafts: a comparative study. J Oral Maxillofac Surg 48:554–8.
18. McIntyre GT, Devlin MF (2010) Secondary alveolar bone grafting (CLEFTSiS) 2000–2004. Cleft Palate Craniofac J 47:66–72.
19. Enemark H, Jensen J, Bosch C (2001) Mandibular bone graft material for reconstruction of alveolar cleft defects: long-term results. Cleft Palate Craniofac J 38:155–63.
20. Joshi A, Kostakis GC (2004) An investigation of post-operative morbidity following iliac crest graft harvesting. Br Dent J 196:167–71.

21. Enemark H, Sindet-Pedersen S, Bundgaard M (1987) Long-term results after secondary bone grafting of alveolar clefts. J Oral Maxillofac Surg 45:913–9.
22. Sindet-Pedersen S, Enemark H (1988) Mandibular bone grafts for reconstruction of alveolar clefts. J Oral Maxillofac Surg 46:533–7.
23. Dissaux C, Bodin F, Grollemund B, Bridonneau T, Kauffmann I, Mattern JF et al (2016) Evaluation of success of alveolar cleft bone graft performed at 5 years versus 10 years of age. J Craniomaxillofac Surg 44:21–6.
24. Desai SK, Adirajaiah S, Desai AK, Kumar N (2021) Observing the Eruption of Canine After Secondary Alveolar Bone Grafting. J Oral Maxillofac Surg 79:2562–73.
25. Sindet-Pedersen S, Enemark H (1985) Comparative study of secondary and late secondary bone-grafting in patients with residual cleft defects. Short-term evaluation. Int J Oral Surg 14:389–98.
26. Lundberg J, Levring Jäghagen E, Sjöström M (2021) Outcome after secondary alveolar bone grafting among patients with cleft lip and palate at 16 years of age: a retrospective study. Oral Surg Oral Med Oral Pathol Oral Radiol 132:281–7.

Tables

Table 1. Gender, impacted canine and age group among patients which underwent bone grafts from mandibular symphysis and iliac crest.

		N (%)		p value
		Mandibular symphysis	Iliac Crest	
Gender	Male	36 (70.6%)	33 (64.7%)	0.5255*
	Female	15 (29.4%)	18 (35.3%)	
Impacted canine	Absent	41 (80.4%)	41 (80.4%)	1.0000*
	Present	10 (19.6%)	10 (19.6%)	
Age group	7 years old	2 (4.0%)	0 (0.0%)	0.2756**
	8 years old	13 (26.0%)	8 (15.7%)	
	9 years old	17 (34.0%)	18 (35.3%)	
	10 years old	8 (16.0%)	15 (29.4%)	
	11 years old	4 (8.0%)	6 (11.8%)	
	12 years old	6 (12.0%)	4 (7.8%)	
Radiographic intervals (months)	0 – 17.14	5 (9.8%)	2 (3.9%)	0.0450*
	17.14 – 34.29	11 (21.6%)	8 (15.7%)	
	34.29 – 51.43	16 (31.4%)	14 (27.5%)	
	51.43 – 68.57	10 (19.6%)	18 (35.3%)	
	68.57 – 85.71	8 (15.7%)	9 (17.6%)	
	85.71 – 102.86	1 (2.0%)	0 (0.0%)	
	102.86 – 120.00	0 (0.0%)	0 (0.0%)	

* p value for Chi-square test comparing proportion between type of boné grafts.

** p value for Mann-Whitney-Wicoxon test for para comparações de medianas

Underlined value indicated significant differences between groups.

Table 2. Comparison between T1 e T2 according to patients undergone bone graft from mandibular symphysis and iliac crest.

	Mandibular symphysis			Iliac rest			p value
	T1	T2	P value	T1	T2	P value	
Type I	47 (92.2%)	36 (70.6%)	0.0164*	48 (94.1%)	37 (72.5%)	0.0121*	0.9950*
Type II	4 (7.8%)	13 (25.5%)		3 (5.9%)	12 (23.5%)		
Type III	0 (0.0%)	2 (3.9%)		0 (0.0%)	2 (3.9%)		
Type IV	0 (0.0%)	0 (0.0%)		0 (0.0%)	0 (0.0%)		

* p value for Chi-square test.

Table 3. Clinical comparison between T1 e T2 according to patients which underwent bone graft from mandibular symphysis and iliac crest.

	Mandibular symphysis			Iliac crest		
	T1	T2	P value*	T1	T2	p value*
Success	51 (100.0%)	49 (96.1%)	0.1532	51 (100.0%)	49 (96.1%)	0.1532
Failure	0 (0.0%)	2 (3.9%)		0 (0.0%)	2 (3.9%)	

* p value for Chi-Square test.

Figures

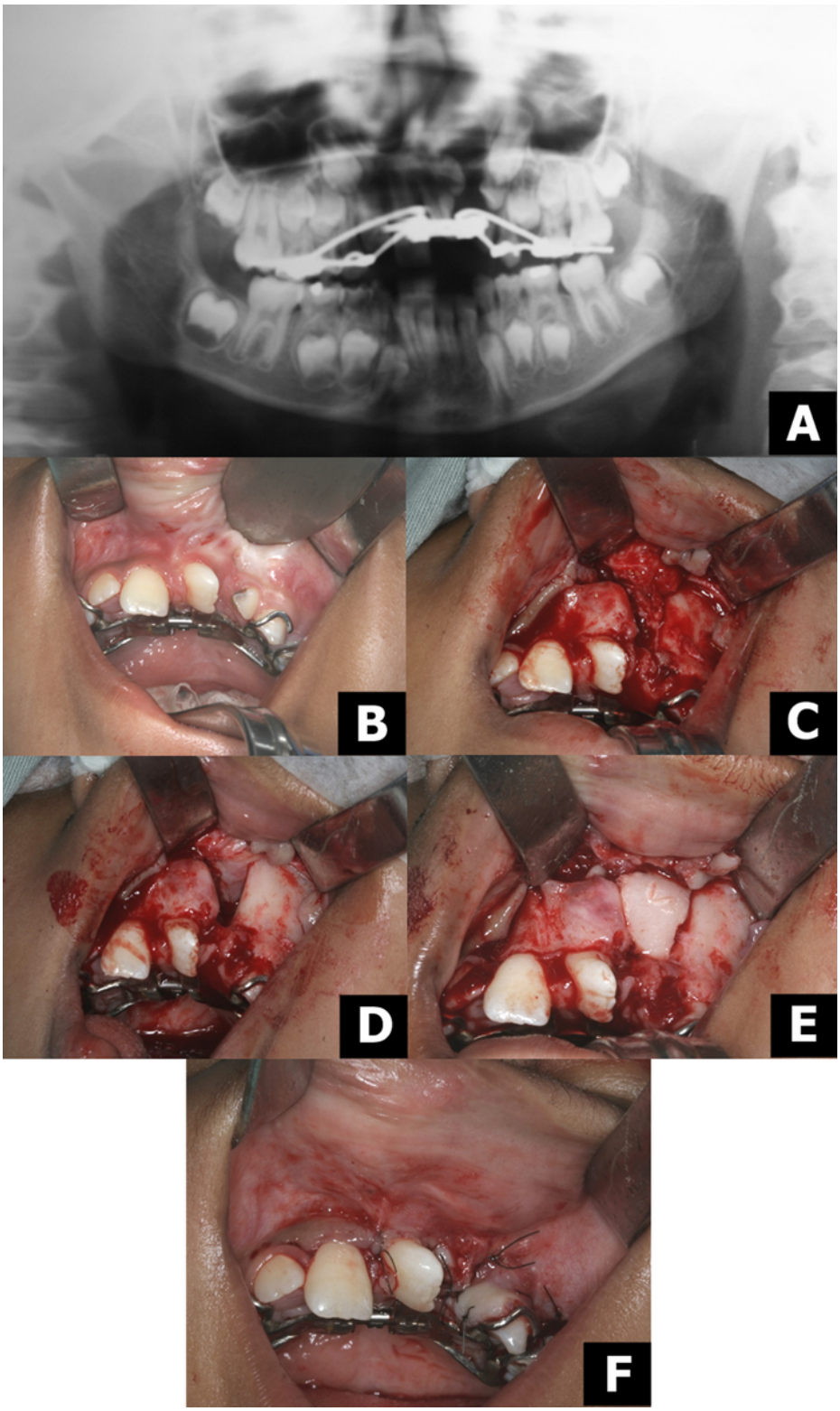

Figure 1

(A) Radiographic image showing an unilateral alveolar cleft to the left. (B) Intra-oral clinical appearence of the cleft. (C) Incision and subperiosteal detachment exposing bone surface in alveolar cleft. (D) Nasal cavity isolated by using nasal mucosa sutures. (E) Bone graft was fixed. (F) Suture for repositioning mucoperiosteal approach.

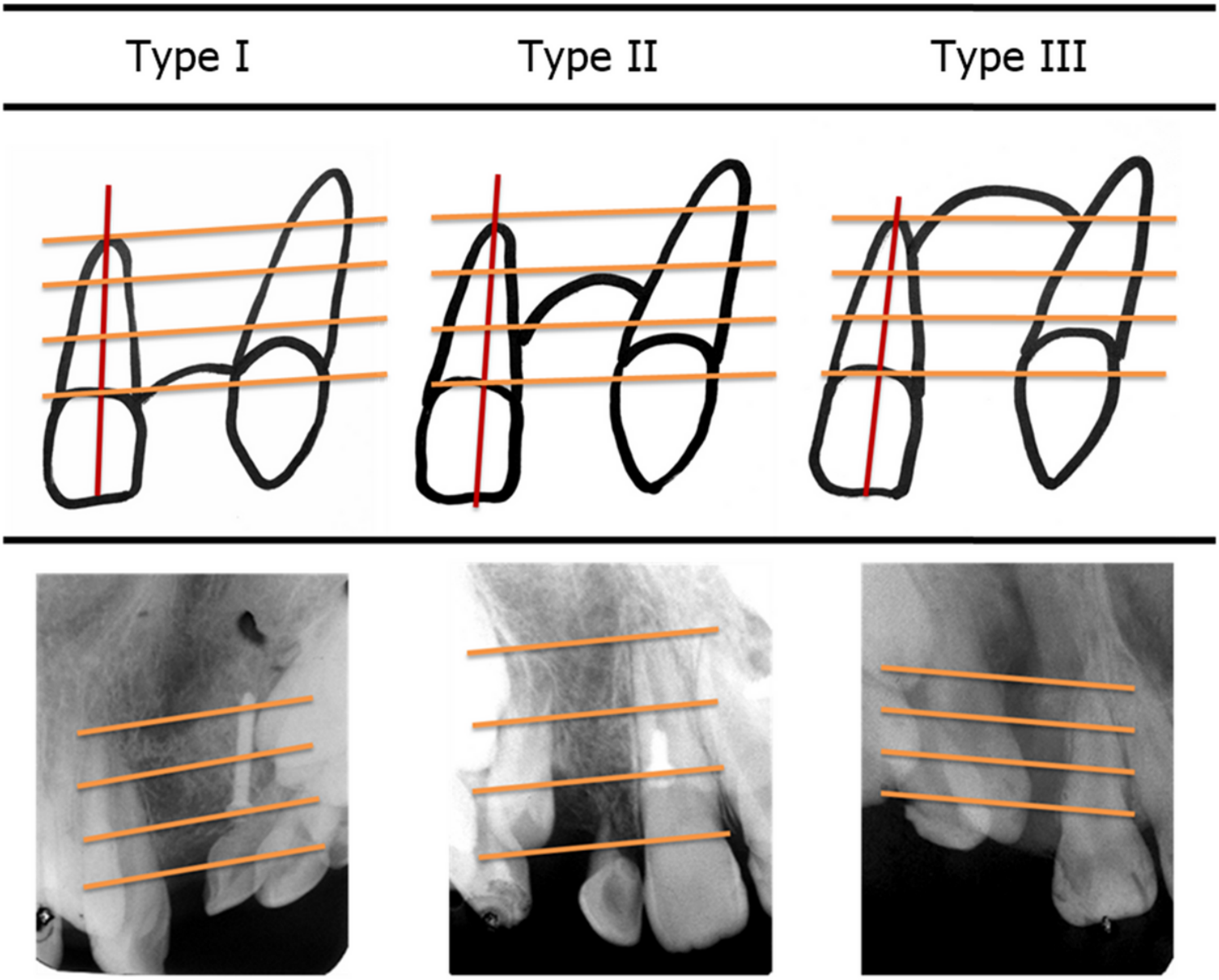

Figure 2

Radiographic images showing mandibular symphysis and iliac crest bone graft used for reconstructing alveolar cleft to be classified according to Berglan, Semb e Abyholm Scale [14].