Ileocecal duplication in children: A single-center experience of 115 cases

Jiayu Yan
Capital Medical University
Waiun Lei
Capital Medical University
Jun Yan
Capital Medical University
Cailin Ding
Capital Medical University
Tingting Liu
Capital Medical University
Yajun Chen (chenyajunmd@126.com)
Capital Medical University

Research Article

Keywords: Children, Ileocecal duplication, Location, Surgical procedure, Ileocecal resection, Prognosis

Posted Date: April 13th, 2022

DOI: https://doi.org/10.21203/rs.3.rs-1541546/v1

Abstract

Purpose To evaluate the clinical features, surgical management, and prognosis of ileocecal duplication in children.

Methods A total of 115 patients diagnosed with ileocecal duplication at Beijing Children's Hospital between January 2010 and June 2021 were retrospectively reviewed. Ileocecal duplications were divided into ileal extraluminal (n = 24), ileal intraluminal (n = 41), ileocecal valve (n = 11), cecal extraluminal (n = 3), and cecal intraluminal (n = 18) types according to their locations.

Results Mean age at diagnosis was 9.5 (0.1-169.2) months. Intussusception was only observed preoperatively in patients with the ileal intraluminal (8/41), ileocecal valve (4/11), and cecal intraluminal (7/18) types (P=0.004). Ileocecal resection and ileocolostomy, and cyst excision were performed in 41 (35.7%) and 74 (64.3%) patients, respectively. The proportions of cyst excision performed in patients with different types were 91.7% (22/24), 78.0% (32/41), 27.3% (3/11), 100.0% (3/3), and 27.8% (5/18) (P<0.001). Mean time of oral intake and hospital stay after surgery were significantly shorter in patients undergoing cyst excision (P=0.003; P<0.001). There were no significant differences in the complications, growth, and stool frequency (older than 4 years) between patients undergoing different surgical procedures. Regarding the stool consistency (older than 4 years), there was a lower proportion of dry stool in patients undergoing cyst excision (P=0.008).

Conclusions Ileocecal duplications at specific locations are prone to intussusception and can influence the surgical procedure choice. At mid-term follow-up, the children's growth and defecation patterns do not seem to be affected by ileocecal resection.

What Is Known

- How to address ileocecal duplication has always been challenging in clinical management.
- Children who have an ileocecal resection can develop some early postoperative complications.

What is New:

- Ileocecal duplications at specific locations are prone to intussusception and can influence the surgical procedure choice.
- Children's mid-term growth and defecation patterns are not affected by ileocecal resection.

Introduction

Enteric duplication, an uncommon congenital malformation with an incidence of 1/10,000 to 1/4,500 live births, has various clinical presentations according to the location and appearance of the lesion that requires surgical resection [1–3]. Duplication lesions may occur at any level of the gastrointestinal tract but most commonly in the small intestine [4]. Ileocecal duplication accounts for approximately 1/5 of patients with an enteric duplication [5].

Ileocecal duplications are almost cysts located in the ileocecal region near the ileocecal valve, and these patients can develop severe complications such as intestinal obstruction and intussusception [6–8]. Due to the complex structure of the ileocecal region and the importance of the ileocecal valve, how to address ileocecal duplication has always been challenging in clinical management. Cyst excision without ileocecal resection has been gradually considered a feasible surgical procedure, first reported by Catalano et al. in 2014 [6, 9]. However, no studies have

focused on the specific location of the lesions in ileocecal duplications and their impact on the choice of surgical procedures. In addition, the existing retrospective studies on ileocecal duplication could not definitively determine the effect of ileocecal resection on children's growth and defecation because of the small sample size and lack of control groups.

Therefore, we performed this retrospective study of 115 cases to analyze the characteristics of ileocecal duplications in different locations, compare the outcomes between patients undergoing different surgical procedures, and provide evidence for clinical management.

Materials And Methods

Patients

After being approved by the Ethics Committee of Beijing Children's Hospital (Approval number: 2021-E-246-R), we conducted a retrospective study of all patients diagnosed with enteric duplication who underwent surgery in our center, Beijing Children's Hospital, Children's National Medical Center, China, from January 2010 to June 2021. Patients who had a duplication cyst at the ileocecal region and ultimately underwent surgery were included in this study. Patients who underwent surgery at other hospitals before admission were excluded. All diagnoses were confirmed by postoperative histopathology with well-defined muscular and mucosal layers.

Study Design

Two pediatric surgeons reviewed the electronic medical records (Jiayu Yan and Waiun Lei). The preoperative patient characteristics, surgical details, pathological data, perioperative clinical data, and postoperative outcomes were analyzed. The preoperative patient characteristics included age, sex, the prenatal diagnosis, accompanying malformations, presenting symptoms, abdominal complications, the preoperative examination findings, and the preoperative diagnosis. The surgical details and pathological data were extracted by reading the surgical records and postoperative pathological results, including the specific location of the lesion, surgical procedure, and lesion characteristics.

The ileocecal duplications were divided into ileal extraluminal, ileal intraluminal, ileocecal valve, cecal extraluminal, and cecal intraluminal types according to their specific locations of the lesion by reading the surgical records (Fig. 1). We divided the patients into two groups according to the surgical procedures, including one group of patients who underwent ileocecal resection and ileocolostomy and another group who underwent cyst excision without ileocecal resection. The perioperative clinical data and postoperative outcomes were compared between the two groups.

The perioperative clinical data included the operation time, blood loss, time of defecation, oral intake, and hospital stay after surgery. Telephone interviews were performed in January 2022 (more than 6 months after surgery) to ask the patients' parents about the child's postoperative complications, height and weight; additionally, the defecation patterns were assessed, including the stool frequency and stool consistency when the patients were older than 4 years old. Regarding their growth, the patients were divided into two categories according to their height-for-age or BMI in normal children of the same age and sex [10]. For the height-for-age, ≥ 90% indicated normal growth, and <90% indicated malnutrition. For the BMI, ≥-1SD indicated normal growth, and <-1SD indicated malnutrition. The stool consistency in each patient was evaluated by the parents using modified Bristol Stool Form Scale [11].

Data Analysis

Categorical variables were analyzed with the $\chi 2$ test, Fisher's exact test or Spearman correlation analysis. Continuous variables with a normal distribution are presented as the means ± standard deviations (SDs) and were analyzed with Student's t test. Continuous variables with nonnormal distribution are presented as the medians and ranges and were analyzed with the Mann-Whitney test or Kruskal-Wallis test. $P < 0.05$ (2-sided) was considered significant. The statistical calculations were performed using a software program (IBM SPSS Package, version 26; IBM Corporation).

Results

Study population

According to the inclusion criteria, 115 patients were included in this study, with a median age of 9.5 (0.1-169.2) months during our hospital visit (Table 1). In 72.2% of the patients, ileocecal duplication was diagnosed before 2 years of age (Fig. 2). Associated congenital malformations were found in 7 (6.1%) patients, including 2 patients with cardiac anomalies, 2 patients with indirect inguinal hernias, 1 patient with hypospadias, 1 patient with Meckel's diverticulum, and 1 patient with Klinefelter syndrome.

Table 1
Clinical characteristics of the study population

Features	N = 115
Age (months) [median (range)]	9.5 (0.1-169.2)
Sex [n (%)]	60 (52.2)
Male	55 (47.8)
Female	
Prenatal diagnosis [n (%)]	27 (23.5)
Gestational age (weeks) [mean ± SD]	25.4 ± 5.8
Accompanying malformations [n (%)]	7 (6.1)
Admission [n (%)]	69 (60.0)
Outpatient	46 (40.0)
Emergency	
Presenting symptoms [n (%)]	59 (51.3)
Vomiting	48 (41.7)
Abdominal pain (including intermittent crying)	36 (31.3)
Abdominal distension	24 (20.9)
Abdominal mass	23 (20.0)
Bloody stool	19 (16.5)
Constipation	11 (9.6)
Diarrhea	5 (4.3)
Fever	2 (1.7)
Incidental finding	
Abdominal complications [n (%)]	24 (20.9)
Intussusception	22 (19.1)
Intestinal obstruction	
Preoperative diagnostic tests [n (%)]	115 (100.0)
Ultrasound	29 (25.2)
Abdominal X-ray	2 (1.7)
Computed tomography	1 (0.9)
Barium enema	1 (0.9)
Magnetic Resonance Imaging	

Features	N = 115
Preoperative diagnosis [n (%)]	107 (93.0)
Enteric duplication	4 (3.4)
Intussusception	2 (1.7)
Appendicitis	1 (0.9)
Intestinal obstruction	1 (0.9)
Enteric cyst	

Patients with different types of ileocecal duplication

Table 2 describes the characteristics of 97 patients with different types of ileocecal duplication, including 24 with the ileal extraluminal type, 41 with the ileal intraluminal type, 11 with the ileocecal valve type, 3 with the cecal extraluminal type, and 18 with the cecal intraluminal type, while in the remaining 18 patients, the exact location of the lesions could not be determined by the surgical records. Intussusception was only observed preoperatively in the ileal intraluminal (8/41), ileocecal valve (4/11), and cecal intraluminal (7/18) types (P = 0.004). At the same time, intestinal obstruction was mainly observed preoperatively in the ileal intraluminal (6/41) and cecal intraluminal (7/18) types (P = 0.176).

Table 2
Characteristics of patients with different types of ileocecal duplication

	Ileal extraluminal (n = 24)	Ileal intraluminal (n = 41)	Ileocecal valve (n = 11)	Cecal extraluminal (n = 3)	Cecal intraluminal (n = 18)	P value	Total (N = 115)*
Abdominal complications [n (%)]	0 (0.0)	8 (19.5)	4 (36.4)	0 (0.0)	7 (38.9)	0.004	24 (20.9)
Intussusception	3 (12.5)	6 (14.6)	1 (9.1)	0 (0.0)	7 (38.9)	0.176	22 (19.1)
Intestinal obstruction							
Surgical procedures [n (%)]	2 (8.3)	9 (22.0)	8 (72.7)	0 (0.0)	13 (72.2)	<0.001	41 (35.7)
Ileocecal resection + ileocolostomy	22 (91.7)	32 (78.0)	3 (27.3)	3 (100.0)	5 (27.8)		74 (64.3)
Cyst excision							
Duplication characteristics							
Length of the cyst (cm) [median (range)]	3.0 (1.0–5.0)	3.0 (0.5-7.0)	3.0 (2.0–7.0)	3.0 (1.5–3.5)	3.3 (2.0–6.0)	0.415	3.0 (0.5-7.0)
Connection with the native lumen [n (%)]	1 (4.2)	0 (0.0)	3 (27.3)	0 (0.0)	1 (5.6)	0.017	6 (5.2)
Ectopic gastrointestinal mucosa [n (%)]	5 (20.8)	15 (36.6)	4 (36.4)	1 (33.3)**	3 (16.7)	0.427	30 (26.1)

*The specific types of 18 patients could not be determined by operative recordings and postoperative pathological results

**Duodenal mucosa

The proportions of cyst excision without ileocecal resection performed in patients with different types were 91.7% (22/24), 78.0% (32/41), 27.3% (3/11), 100.0% (3/3), and 27.8% (5/18), respectively (P<0.001). There was no significant difference in the length of the excised cyst or the proportion of ectopic mucosa among the patients with the different types (P = 0.415; P = 0.427). Ileocecal duplication adjacent to the ileocecal valve had a higher probability of communicating with the native lumen (P = 0.017).

Patients undergoing different surgical procedures

Ileocecal resection and ileocolostomy, and cyst excision without cecal resection were performed in 41 (35.7%) and 74 (64.3%) patients, respectively (Table 3). After comparing the perioperative clinical data between the patients undergoing the two different surgical procedures, we found that the mean age of the patients undergoing ileocecal resection and ileocolostomy was younger than that of the patients undergoing cyst excision (P<0.001). The mean

operative time, blood loss during surgery, and mean time of defecation after surgery did not significantly differ between the 2 groups (P = 0.599; P = 0.859; P = 0.879). The mean times of oral intake and hospital stay after surgery were significantly shorter in the patients undergoing cyst excision (P = 0.003; P<0.001).

Table 3
Perioperative clinical data of the patients according to the procedure types

Characteristics [median (range)]	**Ileocecal resection + ileocolostomy (n = 41)**	**Cyst excision (n = 74)**	**P value**
Age at the time of surgical procedure (months)	5.4 (0.1-147.4)	13.9 (0.2-169.2)	<0.001
Operation time (min)	110 (60–315)	105 (45–200)	0.599
Blood loss (mL)	2 (1–10)	2 (0–10)	0.859
Defecation (days)	3 (1–6)	2 (1–6)	0.879
Oral intake time (days)	5 (2–9)	4 (1–9)	0.003
Hospital stay (days)	8 (5–18)	7 (3–19)	<0.001

Regarding the postoperative outcomes, among those who were followed up, the results showed no significant difference in the postoperative complications and growth development between the 2 groups (Table 4). The postoperative complications included 2 patients with adhesive intestinal obstructions and 1 patient with septicemia in the group undergoing ileocecal resection and ileocolostomy, and 1 patient with anastomotic leakage in the group undergoing cyst excision without cecal resection. The defecation patterns were assessed in 27 (90.0%) patients undergoing ileocecal resection and ileocolostomy and in 45 (71.4%) patients undergoing cyst excision without cecal resection. No significant difference between the 2 groups was noted in terms of stool frequency (P>0.999), while there was a lower proportion of patients with dry stool in the patients undergoing cyst excision without cecal resection (P = 0.003).

Table 4
Postoperative outcomes of the patients according to the procedure types

Characteristics	Ileocecal resection + ileocolostomy (n = 30)	Cyst excision (n = 63)	P value
Mean follow-up age (years)	9.4 (1.3–20.6)	7.1 (1.0-24.1)	0.004
Mean follow-up time (years)	8.4 (0.6–10.8)	3.9 (0.7–11.6)	<0.001
Complications [n (%)]	3 (10.0)	1 (1.6)	0.097
Growth [n (%)]	27 (90.0)	57 (90.5)	——
Height-for-age [n (%)]			>0.999
(I) Normal (≥ 90%)	27 (100.0)	56 (98.2)	
(II) Malnutrition (<90%)	0 (0.0)	1 (1.8)	
BMI [n (%)]			>0.999
(I) Normal (≥-1SD)	26 (96.3)	54 (94.7)	
(II) Malnutrition (<-1SD)	1 (3.7)	3 (5.3)	
Defecation* [n (%)]	27 (90.0)	45 (71.4)	——
Mean follow-up age (years)	9.6 (5.4–20.6)	8.2 (4.0-24.1)	0.054
Stool frequency [n (%)]			
(I) Every other day to twice a day	24 (88.9)	39 (86.7)	>0.999
(II) More often	0 (0.0)	0 (0.0)	
(III) Less often	3 (11.1)	6 (13.3)	
Stool consistency** [n (%)]			
(I) 1–2	14 (51.9)	9 (20.0)	0.008
(II) 3	13 (48.1)	36 (80.0)	
(III) 4–5	0 (0.0)	0 (0.0)	

*The defecation patterns were evaluated in patients who aged older than 4 years

**Stool consistency was evaluated by modified Bristol Stool Form Scale

Discussion

We provided a more specific classification of ileocecal duplications and found that ileocecal duplications at specific locations were prone to intussusception and influenced the choice of surgical procedure. Moreover, our findings also demonstrate that ileocecal resection did not seem to affect children's growth and defecation patterns at mid-term follow-up.

Ileocecal duplication is a particular entity, a highly rare enteric duplication that usually presents symptoms or complications in infancy and childhood [12, 13]. Ileocecal duplication was considered more common than cecal duplication, which shared a common blood supply and wall with the ileum for a few centimeters from the ileocecal valve and compressed the cecum [6]. However, we believe that ileocecal duplication could be distinguished from ileum duplication and includes cecal duplication and cases of duplication at the ileocecal junction because all of these cases are located in the ileocecal region, have the same blood supply (the ileocolic artery) and can present with the same symptoms and complications [14]. Some previous studies on other diseases have demonstrated that resection of the ileocecal region has adverse effects [15, 16]. However, the available literature on ileocecal duplication is sparse, and the literature mainly consists of case reports. No controlled study about the different surgical procedures for ileocecal duplication has been reported.

A review of our data shows that similar to other types of enteric duplication, except for the prenatal ultrasonography findings, vomiting, abdominal pain, and abdominal distension were the main symptoms in ileocecal duplication; however, the rates of complications in ileocecal duplication, including intussusception and intestinal obstruction, were significantly higher than the rate in the other types [2, 5, 14]. Moreover, we noted that intussusception occurred only in ileocecal duplications at specific locations, including ileal intraluminal, ileocecal valve, and cecal intraluminal types. Two possible ways can explain this phenomenon. First, according to the classification diagram (Fig. 1, A, C, D), the lesion in the above three types can act as a pathologic lead point for intussusception [17, 18]. In contrast, the other two types cannot. Second, in the ileocecal valve and cecal intraluminal types, bowel thickening may also show the typical target signs of intussusception on ultrasound, which is not a true intussusception [13, 19]. For intestinal obstructions, space-occupying cystic lesions and the compression effects resulting from mucus secretion and accumulation may be the basic pathogenesis, which will affect the normal process of food passing through the ileocecal valve [20]. Similar to a previous study, abdominal ultrasound was performed for all of the patients in our study and had high accuracy for a preoperative diagnosis [9, 21]. Whenever there is a cystic lesion in the right lower abdomen on ultrasound in a case of intussusception or intestinal obstruction in a child, the first differential diagnosis should be enteric duplication, including ileum duplication, which is the most common, or ileocecal duplication [22, 23].

Notably, the location of the cystic lesions in ileocecal duplication will affect the choice of the surgical procedure; the proportions of patients who had cyst excision without ileocecal resection performed in the ileal extraluminal, ileal intraluminal, and cecal extraluminal types were 91.7%, 78.0%, and 100.0%, respectively, which were significantly higher than those in the patients with the ileocecal valve and cecal intraluminal types. In addition, the choice of surgical procedure also depends on the surgeon’s experience and any complications that develop, such as intestinal necrosis [24]. In our study, 40% of the patients were admitted to our center as an emergency, suggesting that the condition of these children was severe, and the patients needed to have surgery performed as soon as possible. When the children’s conditions are complicated with intussusception for a long time, intestinal necrosis may occur, further leading to shock or even death [25]. Some surgeons preferred to choose the relatively simple ileocecal resection and ileocolostomy to prevent complications, such as delayed intestinal perforation [26].

With the improvement in the perioperative management and surgical techniques, especially when considering that ileocecal duplication is a benign congenital malformation, an increasing number of studies have described excision of duplication cysts in order to preserve the ileocecal region with laparoscopy or laparoscopic assistance [6, 9, 27]. Comparing the perioperative clinical data between the patients undergoing the two different surgical procedures in our center in the past 12 years, we noted that although repair of the bowel or ileocecal valve was

sometimes needed during the cyst excision, compared with the traditional ileocecal resection and ileocolostomy procedures, these procedures did not significantly increase the operative time or blood loss. Furthermore, these patients recovered more quickly after surgery, manifested by an earlier oral intake and a shorter hospital stay. This technique retains the important function of the ileocecal valve in childhood and is consistent with the concept of enhanced recovery after surgery [28]. We also observed that the mean age of the patients undergoing ileocecal resection and ileocolostomy was significantly younger than those undergoing cyst excision. This observation implies that younger children with ileocecal duplication tend to have more severe symptoms and complications, such as dehydration, and the surgical procedures for these patients tend to be more conservative, even including an ileostomy [8, 23]. Therefore, cyst excision without cecal resection is a safe and feasible option for ileocecal duplication, and ileocecal resection and ileocolostomy are recommended for patients with severe complications, including dehydration, intestinal perforation, and a prolonged intussusception.

Furthermore, in our study, ileocecal resection did not increase the incidence of postoperative complications or affect the growth of children with ileocecal duplication. At the same time, in contrast to previous literature, a high proportion of the patients did not have postoperative diarrhea [29]. The patients undergoing ileocecal resection and ileocolostomy had a higher incidence of dry stool with a mean follow-up time of 8.4 (0.6–10.8) years. This finding might be related to the fact that ileocecal resection without an extensive ileal resection did not affect bile acid absorption [15, 30]. Moreover, we hypothesized that an ileocecal valve resection could lead to colon bacterial overgrowth and colonization of the ileum, thereby increasing the ability of the digestive tract to absorb water, resulting in dry stool at mid-term follow-up [16, 31].

This study was a retrospective analysis of a single institution and still had limitations. The primary limitation was the retrospective nature of the design. The short-term postoperative defecation patterns in the patients undergoing cecal resection and ileocolostomy could not be acquired and compared with other studies. In addition, our study did not compare the follow-up results with normal children, so it was impossible to know whether cecal resection affects the patients' long-term postoperative defecation, which is the focus of our future study. Finally, we will test the intestinal flora of the patients enrolled in our study to confirm our hypothesis.

Authors' contributions JY and YC conception and design of the work. JY and WL conducted data collection and performed data analysis. JY, WL, JY, CD, and TL contributed to data interpretation. JY, WL, and YC assisted in drafting the manuscript. All authors critically revised the manuscript and read and approved the final manuscript for submission.

Declarations

Authors' contributions JY and YC conception and design of the work. JY and WL conducted data collection and performed data analysis. JY, WL, JY, CD, and TL contributed to data interpretation. JY, WL, and YC assisted in drafting the manuscript. All authors critically revised the manuscript and read and approved the final manuscript for submission.

Funding The authors declare that no funds, grants, or other support were received during the preparation of this manuscript.

Data availability Not applicable.

Code availability Not applicable.

Ethics approval The study received approval by the Ethics Committee of Beijing Children's Hospital (Approval number: 2021-E-246-R).

Consent to participate N/A.

Consent for publication N/A.

Conflict of interest The authors declare no competing interests.

References

1. Mayer JP, Bettolli M (2014) Alimentary tract duplications in newborns and children: Diagnostic aspects and the role of laparoscopic treatment. World J Gastroenterol 20:14263–14271. https://doi.org/10.3748/wjg.v20.i39.14263
2. Kim SH, Cho YH, Kim HY (2020) Alimentary tract duplication in pediatric patients: its distinct clinical features and managements. Pediatr Gastroenterol Hepatol Nutr 23:423–429. https://doi.org/10.5223/pghn.2020.23.5.423
3. Jeziorczak PM, Warner BW (2018) Enteric Duplication. Clin Colon Rectal Surg 31:127–131. https://doi.org/10.1055/s-0037-1609028
4. Stringer MD, Spitz L, Abel R, Kiely E, Drake DP, Agrawal M, Stark Y, Brereton RJ (1995) Management of alimentary tract duplication in children. Br J Surg 82:74–78. https://doi.org/10.1002/bjs.1800820126
5. Sujka JA, Sobrino J, Benedict LA, Alemayehu H, Peter SS, Hendrickson R (2018) Enteric duplication in children. Pediatr Surg Int 34:1329–1332. https://doi.org/10.1007/s00383-018-4362-x
6. Catalano P, Di Pace MR, Caruso AM, De Grazia E, Cimador M (2014) Ileocecal duplication cysts: is the loss of the valve always necessary?. J Pediatr Surg 49:1049–1051. https://doi.org/10.1016/j.jpedsurg.2013.12.026
7. Radhakrishna V, Rijhwani A, Jadhav B (2018) Cecal duplication: A mimicker of intussusception: A case report and review. Ann Med Surg (Lond) 31:17–19. https://doi.org/10.1016/j.amsu.2018.05.010
8. Pai NG, Prabhu S, Prabhakar P, Kumar V (2020) Duplication cyst with midgut volvulus in a neonate: an unusual presentation. BMJ Case Rep 13:e235526. https://doi.org/10.1136/bcr-2020-235526
9. Chen J, Wang J, Gu Z, Huang S, Zhu J, Wu B, Zhu Z, Cai P, Sun C (2020) Laparoscopic resection of ileocaecal duplication in children (report of 15 cases). J Minim Access Surg 16:372–375. https://doi.org/10.4103/jmas.JMAS_120_19
10. WHO Child Growth Standards and the Identification of Severe Acute Malnutrition in Infants and Children: A Joint Statement by the World Health Organization and the United Nations Children's Fund. Geneva: World Health Organization; 2009.
11. Wegh CAM, Hermes GDA, Schoterman MHC, Vaughan EE, Smidt H, Belzer C, Benninga MA (2021) The Modified Bristol Stool Form Scale: A reliable and valid tool to score stool consistency in Dutch (Non) toilet-trained toddlers. J Pediatr Gastroenterol Nutr 73:210–216. https://doi.org/10.1097/MPG.0000000000003186
12. Keum SW, Hwang MW, Na JI, Yu ST, Oh YK (2009) Intestinal obstruction caused by a duplication cyst of the cecum in a neonate. Korean J Pediatri 270:527–533. https://doi.org/10.3345/kjp.2009.52.2.261
13. Verma S, Bawa M, Rao KL, Sodhi KS (2013) Caecal duplication cyst mimicking intussusception. BMJ Case Rep 2013:bcr2012008056. https://doi.org/10.1136/bcr-2012-008056

14. Stern LE, Warner BW (2000) Gastrointestinal duplications. Semin Pediatr Surg 9:135–140. https://doi.org/10.1053/spsu.2000.7565
15. Diederen K, de Ridder L, van Rheenen P, Wolters VM, Mearin ML, de Meij TG, van Wering H, Oomen MW, de Jong JR, Sloots CE, Benninga MA, Kindermann A (2019) Quality of life and colorectal function in Crohn's disease patients that underwent ileocecal resection during childhood. Eur J Pediatr 178:1413–1421. https://doi.org/10.1007/s00431-019-03427-3
16. Shafik AA, Ahmed IA, Shafik A, Wahdan M, Asaad S, El Neizamy E (2011) Ileocecal junction: anatomic, histologic, radiologic and endoscopic studies with special reference to its antireflux mechanism. Surg Radiol Anat 33:249–256. https://doi.org/10.1007/s00276-010-0762-x
17. Lai M, Coakley BA, Webber EM, Goldman RD (2018) Intussusception with cecal cyst as lead point in a child. Pediatr Emerg Care 34:e134-135. https://doi.org/10.1097/PEC.0000000000000893
18. Al-Shaibi MA, Raniga SB, Asghar ANM, Al Tubi IS (2019) Caecal duplication cyst leading to intussusception in an adult. BMJ Case Rep 12:e230567. https://doi.org/10.1136/bcr-2019-230567
19. Karakus SC, Ozokutan BH, Ceylan H (2014) Diseases mimicking intussusception: diagnostic dilemma. Pediatr Int 56:768–771. https://doi.org/10.1136/bcr-2019-230567
20. Yan J, Yan J, Ding C, Guo J, Peng Y, Chen Y (2021) Clinical features of colorectal duplication in children: A study of 25 cases. J Pediatr Surg 2021:S0022-3468(21)00657-6. https://doi.org/10.1136/bcr-2019-230567
21. Pracros JP, Tran-Minh VA, Wright C (1985) Ultrasound in diagnosis of intussusception. Lancet 28:733–734. https://doi.org/10.1136/bcr-2019-230567
22. Renu Kumar T, Satya Srinivas B (2014) Cecal duplication cyst presenting as a recurrent intestinal obstruction. Indian J Pediatr 81:516–518. https://doi.org/10.1136/bcr-2019-230567
23. Tawil KA, Crankson S, Emam S, Eldemerdash A, Sabbagh F, Laimoun BA (2005) Cecal duplication cyst: a cause of intestinal obstruction in a newborn infant. Am J Perinatol 22:49–52. https://doi.org/10.1136/bcr-2019-230567
24. Temiz A, Oğuzkurt P, Ezer SS, İnce E, Gezer HÖ, Hiçsönmez A (2013) Different clinical presentations, diagnostic difficulties, and management of cecal duplication. J Pediatr Surg 48:550–554. https://doi.org/10.1136/bcr-2019-230567
25. Bogdanović M, Blagojević M, Kuzmanović J, Ječmenica D, Alempijević Đ (2019) Fatal intussusception in infancy: forensic implications. Forensic Sci Med Pathol 15:284–287. https://doi.org/10.1136/bcr-2019-230567
26. Fisher JG, Sparks EA, Turner CG, Klein JD, Pennington E, Khan FA, Zurakowski D, Durkin ET, Fauza DO, Modi BP (2015) Operative indications in recurrent ileocolic intussusception. J Pediatr Surg 50:126–130. https://doi.org/10.1016/j.jpedsurg.2014.10.012
27. Górecki W, Bogusz B, Zając A, Sołtysiak P (2015) Laparoscopic and laparoscopy-assisted resection of enteric duplication cysts in children. J Laparoendosc Adv Surg Tech A 25:838–840. https://doi.org/10.1089/lap.2015.0103
28. Ljungqvist O, Scott M, Fearon KC (2017) Enhanced Recovery After Surgery: A Review. JAMA Surg 152:292–298. https://doi.org/10.1001/jamasurg.2016.4952
29. Iwanaka T, Hashizume K, Kawarasaki H, Tanaka K, Kanamori Y, Utsuki T, Obana K, Uno K, Sugiyama M, Tsuchida Y (1993) Ileocecal resection in neonates and infants: a follow-up study. J Pediatr Surg 28:110–112. https://doi.org/10.1016/s0022-3468(05)80367-7

30. Ho KJ, Bondi JL (1977) Cholesterol metabolism in patients with resection of ileum and proximal colon. Am J Clin Nutr 30:151–159. https://doi.org/10.1093/ajcn/30.2.151
31. Malbert CH (2005) The ileocolonic sphincter. Neurogastroenterol Motil 17:41–49. https://doi.org/10.1111/j.1365-2982.2005.00657.x

Figures

Figure 1

Schematic diagram of specific classification of ileocecal duplication. (A) Ileal intraluminal type. (B) Ileal extraluminal type. (C) Ileocecal valve type. (D) Cecal intraluminal type. (E) Cecal extraluminal type

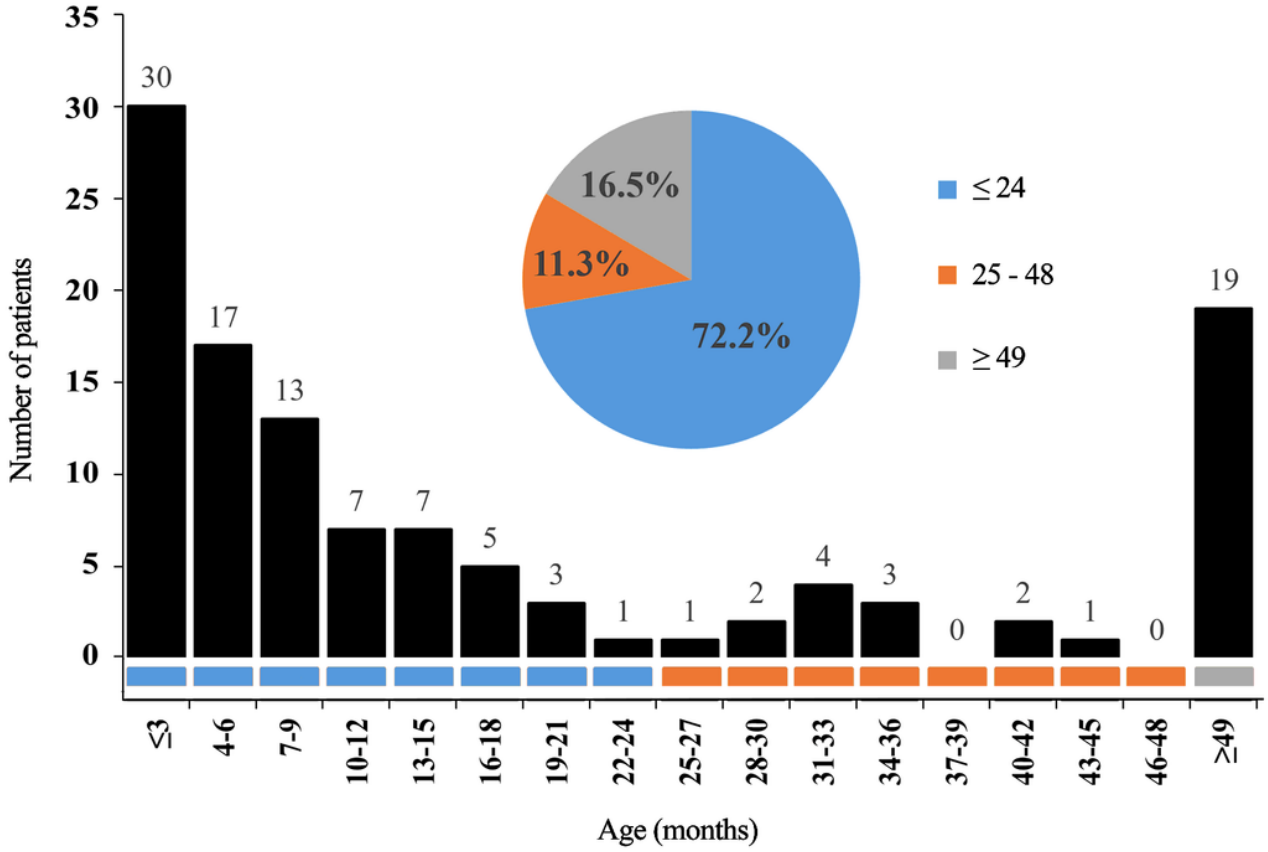

Figure 2

Age distribution of patients diagnosed with ileocecal duplication