Magnetic resonance imaging of congenital talipes equinovarus treated with the Ponseti method: a short-term outcome study

Jiangchao Zhang
Capital Institute of Pediatrics
Ningqing Wang
Capital Institute of Pediatrics
Haixiang Lv
Capital Institute of Pediatrics
Zhenjiang Liu (lzjsdd@163.com)
Capital Institute of Pediatrics

Research Article

Keywords: Congenital talipes equinovarus, Clubfoot, Ponseti method, Magnetic resonance imaging

Posted Date: April 14th, 2022

DOI: https://doi.org/10.21203/rs.3.rs-1541618/v1

Abstract

Background

To quantitatively evaluate the effectiveness of the Ponseti method for the correction of clubfoot, we decided to use Magnetic resonance imaging(MRI) to evaluate changes in the tarsal bones relationship.

Methods

This is a retrospective study of 12 children with clubfoot treated with Ponseti method. MRI studies were obtained using a 3.0T machine(GE, America). T1-weighted and T2-weighted images were acquired in the standard anatomic sagittal, transverse, and coronal planes. For the measurement, the best slice that clearly demonstrated the anatomy was chosen. Sagittal talocalcaneal angle, sagittal tibiocalcaneal angle, coronal tibiocalcaneal angle, transverse talar neck angle, transverse talonavicular angle and transverse talocalcaneal angle were measured. The 15 corrected clubfoot were compared with the 9 unilateral normal feet at clinical and radiological levels using a Pirani scoring system and MRI, respectively.

Results

12 patients (10 boys, 2 girls) with clubfoot were examined by using MRI. 9 cases had unilateral and 3 had bilateral involvement(8 left clubfoot, 7 right clubfoot), giving a total of 15 clubfoot compared with 9 normal feet. The mean age of patients at examination was 47.7months (8-96 months). The recovery of the corrected clubfoot in these patients met the goals of Ponseti treatment(functional, normal looking, pain-free, plantigrade foot). Before Ponseti treatment, the mean Pirani score of clubfoot was 5.5(5-6). During this follow-up, the Pirani score was 0.07(0-0.05). The results of MRI indicated that only the transverse talonavicular angle showed significant difference between the treated clubfoot and the normal feet($P < 0.001$). 1 of 15 of the corrected clubfoot had dorsal talonavicular subluxation in sagittal plane and 1 had lateral subluxation of the navicular in transverse plane, which have never been reported in previous studies.

Conclusions

Although the appearance and function of clubfoot recovered well after the Ponseti method, the results of MRI indicated that Ponseti method successfully corrected the varus, cavus, and equinus deformities and incompletely corrected the adduction deformity regarding transverse talonavicular angle. At the same time, the Ponseti method may cause dorsal talonavicular subluxation in sagittal plane and lateral subluxation of the navicular in transverse plane on MRI.

Introduction

Congenital talipes equinovarus, commonly known as clubfoot, is a well-known common pediatric foot deformity, with an incidence of 1 to 2 per 1,000. Affected individuals present unilateral or bilateral clubfoot and involvement of both feet occurs in approximately 50% of cases. It affects males more than females, where the males to female ratio of clubfoot is 2:1. Forefoot adducts, midfoot cavus, hindfoot varus, and ankle equinus are all characteristics of this deformity[1]. The traditional treatment is early postnatal non-surgical therapy, such as the Ponseti method, which has been accepted as the gold standard treatment of clubfoot in many

countries. Ponseti suggested that if the patient had a functional, plantigrade foot with adequate mobility, the result of treatment should be considered successful[2]. Derzsi suggested that Ponseti method in the treatment of clubfoot resulted in satisfactory clinical results, however, there were still abnormal differences in imaging studies[3].

A number of X-ray, CT, arthrography and ultrasound studies on clubfoot have been performed in recent years[4, 5, 6, 7, 8, 9, 10]. Due to tarsal bones of infants are not completely ossified and are primarily cartilaginous, it has been difficult to assess the morphology and alignment of tarsal bones using X-ray and CT. Arthrography has been recommended for better visualization of tarsal bones including cartilage, but this is an invasive procedure[10]. We can see various elements of the deformity by using ultrasound, but no quantitative evaluations can be made[8]. With MRI, we have a unique opportunity to photograph the chondroosseous components and soft tissue anomalies of clubfoot in multiple planes. The purpose of our study is using MRI to quantitatively evaluate changes in tarsal bones relationship of corrected clubfoot so as to objectively describe the effectiveness of Ponseti method.

Patients And Methods

12 patients with clubfoot after the Ponseti method were examined by using MRI. 10 patients were boys and 2 were girls. 9 cases had unilateral and 3 had bilateral involvement(8 left clubfoot, 7 right clubfoot), giving a total of 15 clubfoot compared with 9 normal feet. The mean age at examination was 47.7months (8–96 months). After institutional review board approval and written informed consent was obtained from their parents. Patients arrived at the MRI scanner sleep-deprived and were sedated by oral administration of 0.5mg/kg of chloral hydrate. Magnetic resonance imaging(MRI) was performed on their both feet. We used a 3.0T MRI scanner(GE, America) with foot and ankle coil that generating both T1-weighted and T2-weighted images with slices thickness of 3-4mm. Each study was assessed with standard sagittal, coronal and transverse planes. In general, we chose the best slice that clearly demonstrates the anatomy of the foot. At the same time, we used the Pirani scoring system to document the severity of clubfoot deformities(before and after Ponseti treatment).

Six major measurement parameters were evaluated: sagittal talocalcaneal angle, sagittal tibiocalcaneal angle, coronal tibiocalcaneal angle, transverse talonavicular angle, transverse talar neck angle and transverse talocalcaneal angle. Two senior pediatric orthopedic surgeons measured these angles separately to reduce interobserver error. In our investigation, results were discarded if the discrepancy between the measured angles was greater than 3°. The real value was then calculated as the average of the angles measured by two observers.

(1) The sagittal talocalcaneal angle was measured by drawing lines through the long axis of the entire ossified and cartilaginous talus and calcaneus bones[Fig. 1]; (2)The sagittal tibiocalcaneal angle was measured as the angle formed by the long axis of the tibial and calcaneus bones[Fig. 2]; (3)The coronal tibiocalcaneal angle was defined as the angle formed by the the long tibial axis and the line connecting dorsolateral and plantolateral corners of calcaneus[Fig. 3]; (4)At the transverse plane, the transmalleolar axis was defined as a line bisecting the lateral and medial malleoli, previously described by Jakob[23]. A line perpendicular to the transmalleolar axis was accepted as the longitudinal axis of the talar body[Fig. 7]. The axis of talar neck was defined by a line passing through the midpoint of the talar head and talar neck. (4)The transverse talar neck

angle was considered by drawing lines through the long axis of the talus body and talus head[Fig. 4]; (5)The transverse talonavicular angle was measured by drawing perpendicular lines to the navicular base line and to the transmalleolar axis[Fig. 5]; ; (6)The transverse talocalcaneal angle was measured by drawing lines through the long axis of the calcaneus and the talar body[Fig. 6]. These angles were measured by maintaining a superimposing image.

Continuous data were presented with mean and standard deviation (SD). All statistical analyses were performed using SPSS version 26.0 (IBM, Armonk, New York, USA). Differences between normal feet and treated clubfoot were analyzed using independent sampled Student t test or Mann–Whitney U test, as appropriate. $P < 0.05$ was considered statistically significant.

Results

Before the Ponseti treatment, the mean Pirani score of clubfoot was 5.5(5–6). The Pirani score at this follow-up period for the corrected clubfoot was 0.07(range, 0-0.05). Pirani scores showed a statistically significant improvement before starting and after the Ponseti method. Among these major measurement parameters[see Table 1], sagittal talocalcaneal angle, sagittal tibiocalcaneal angle, coronal tibiocalcaneal angle, transverse talar neck angle and transverse talocalcaneal angle showed no significant difference between treated clubfoot and normal feet($P > 0.05$). The transverse talonavicular angle showed significant difference between two groups($P < 0.001$). We found one patient had dorsal talonavicular subluxation by MRI[Fig. 8]. One patient had lateral subluxation of the navicular in transverse plan on MRI[Fig. 9], which has never been described.

Table 1
Six measurement parameters between clubfoot and normal feet

	sagittal tibiocalcaneal angle	sagittal talocalcaneal angle	coronal tibiocalcaneal angle	transverse talonavicular angle	transverse talar neck angle	transverse talocalcaneal angle
clubfoot	72.4 ± 6.2	29.9 ± 7.8	13.1 ± 5.6	43.2 ± 13.6	33.2 ± 7.2	11.9 ± 4.0
Normal	68.7 ± 7.9	27.4 ± 8.5	12.2 ± 2.3	22.2 ± 12.7	28.8 ± 13.0	9.8 ± 4.6
P-value	0.219	0.469	0.605	0.001	0.296	0.259
Data presentation: mean ± standard deviation(SD)						

Discussion

Congenital talipes equinovarus is a three-dimensional malformation of leg, ankle and foot immediately visible at birth. It is characterized by forefoot adducts, midfoot cavus, hindfoot varus and equinus of ankle. To assess the severity of the abnormalities, several pediatric orthopedists used clinical-functional scores (such as the Pirani scores or the Dimeligo scores) as well as radiological data. Despite the widespread use of analytical radiography in clubfoot, Surendra et al concluded that radiographic assessment of clubfoot was not a trustworthy tool due to significant intraobserver and interobserver variability[11]. Conventional radiographs were radioactive, unreliable, not easily reproducible, and imprecise in assessing and classifying the severity of

clubfoot. Meanwhile, because the tarsal bones of these patients are not totally ossified and are primarily cartilaginous, we can't utilize X-ray to assess the relationship between the tarsal bones.

Clubfoot with good cosmetic and functional healing, according to Blakeslee, may have several covert tarsal joint impingements, dislocations, or subluxations that are not apparent on clinical examination or radiographs[12]. Furthermore, X-ray has not made visualization of the talonavicular relationships possible. With the long-term follow-up of Ponseti-treated clubfoot cases, the investigators found an increase in the recurrence rate of clubfoot, which ranged from 1.9–45%[13]. Ponseti suggested that the recurrence of clubfoot may be due to inadequate repositioning of the tarsal bones alignment, which was not diagnosed with clinical or radiological examinations in early childhood. The level of correction can be seen clearly on MRI, which can also reveal complications and relapses before skeletal maturity. Although there have been several reports on MRI findings of tarsal bone abnormalities of clubfoot, MRI studies on the level of correction after the Ponseti method are scarce and have not been reported in China[14, 15, 16, 17, 18, 19, 20]. Therefore, we decided to objectively evaluate the effectiveness of the Ponseti method for the correction of clubfoot using MRI.

To describe the equinus deformity of clubfoot, the sagittal talocalcaneal angle and sagittal tibiocalcaneal angle were measured in this study. Before Ponseti treatment, the sagittal talocalcaneal angle was reported to be 28 ± 6° in normal foot and 5 ± 9° in clubfoot on MRI by Downey($P < 0.05$)[14]. The mean sagittal talocalcaneal angle in our study was 29.9° in treated clubfoot and 27.4° in normal foot($P > 0.05$). The mean sagittal tibiocalcaneal angle was 68.7° in corrected clubfoot and 72.4° in normal foot($P > 0.05$). The results of our MRI revealed that the Ponseti method was successful enough in correction of equinus deformity of clubfoot. Pekindil reported the mean sagittal talocalcaneal angle 36.0° in normal foot and 31.4° in treated side($P > 0.05$)[15]. Amhad also reported the mean sagittal tibiocalcaneal angle 80.2° in normal side and 91.6° in corrected side($P > 0.05$)[18]. These measurements were consistent with the findings of our study. An MRI protocol was devised to illustrate the tarsal bones changes that occur with the Ponseti method of the treatment by Pirani, though these changes were qualitative rather than quantitative[17]. They discovered that Ponseti method corrected not only the aberrant relationships of the tarsal bones, but also the abnormal shapes of the individual tarsal osteochondral anlages.

The coronal tibiocalcaneal angle was used to assess the varus deformity of the clubfoot. Satio found that the coronal tibiocalcaneal angle was 0 ± 13.8° in the clubfoot before treatment and14 ± 4.6° in the normal foot($P < 0.001$)[19]. Our results of coronal tibiocalcaneal angle were for normal and corrected foot were statistically insignificant. We believed that Ponseti method successfully corrected the varus deformity of clubfoot. Pirani et al also observed that the abnormal relationship between the calcaneus and tibia of clubfoot had returned to normal in the coronal plane during the third cast fixation phase .

When compared to normal children, the onset of navicular ossification was found to be delayed in children with clubfoot, and the navicular bone was not apparent on radiographs until they were 3–5 years old[21]. However, it was easy to see the navicular cartilage in the sagittal plane of MRI. If a substantial cavus deformity cannot be treated by stretching the plantar fascia, Carroll believed that extrusion of the dorsolateral navicular bone will occur, leading to talonavicular subluxation[22]. In our study, 1 of 15 (6.7%) of the corrected clubfoot had dorsal talonavicular subluxation. Its rate has been reported as 25% by Ahmad[18]. In the MRI transverse plane, we found that 1 corrected clubfoot had lateral talonavicular subluxation, which has never been repored in previous

studies. We speculated that the navicular bone had developed from medial displacement to lateral subluxation due to overcorrection of the Ponseti method and cast fixation. MRI can identify these insidious complications much earlier than X-ray.

Adducts deformity of clubfoot related measurements were transverse talonavicular angle, transverse talar neck angle and transverse talocalcaneal angle. To our knowledge, it was difficult to identify the longitudinal axis of the talar body in the transverse plane of MRI. The longitudinal axis of the talar body was defined as a line perpendicular to the transmalleolar line passing through the center of the medial and lateral malleoli[23]. Before treatment, Downey reported that the mean transverse talar neck angle was 44.0° for clubfoot and 30.8° for normal foot ($P < 0.01$)[14]. And the mean transverse talocalcaneal angle was 22.8° in clubfoot versus 10.1° in normal foot($P < 0.05$). These findings were consistent with the adducts deformity of clubfoot described by Ponseti et al. In our study, only transverse talonavicular angle of these three measurements for normal foot and corrected clubfoot were statistically significant. Kamegaya performed plaster fixation on children with clubfoot, they reported 21.0 ± 9.5° for normal foot and 44.2 ± 15.9° for treated clubfoot regarding the transverse talonavicular angle($P < 0.05$)[20]. We believed that the navicular bone still has a medial displacement despite of the satisfactory appearance and functional activity of the clubfoot after Ponseti method. The transverse talonavicular angle showed that the adducts deformity of clubfoot has not been completely corrected.

Ponseti noticed that the clubfoot had a strong tendency to relapse regardless of the approach used to obtain correction. Among the relapsed deformities, the most common is the recurrence of equinus deformity of ankle, followed by adducts deformity. The recurrence of clubfoot, according to Ponseti, was caused by non-compliance with braces, which might result in an abnormal relationship between the tarsal bones.[2]. In our study, even though the clinical correction and the motion of the foot and ankle are satisfactory, the talonavicular angle on transverse images of MRI showed statistical differences, suggesting that the adducts deformity may be incompletely corrected and therefore additional follow-up is required to rule out the possibility of adducts deformity recurrence. At the same time, residual deformity is present in up to 20% of clubfoot treated by the Ponseti method[24]. We speculated that the reason may be aberrant articular morphology. With MRI, we can detect these small variations in time so as to take targeted treatment and avoid residual abnormalities.

Several limitations of our study should be mentioned. First, the sample size was small. Second, long term follow-up with a larger number of cases will be needed to exclude the possibility of recurrence of clubfoot. Third, the cost of MRI examination is too expensive and using them in the neonatal period is challenging because the infant must be sedated. At last, because the thickness of the MRI scan is 3–4 mm, it will cause errors in the measurement results when selecting slices.

Conclusion

To our knowledge, although the appearance and function of clubfoot recovered well after Ponseti method, the transverse talonavicular angle still shows statistical differences on MRI. MRI can help us to better characterize clubfoot deformity and objectively assess the effectiveness of the Ponseti method. It may reveal recurrence and complications of clubfoot earlier than X-ray. The results of MRI showed that Ponseti method successfully corrected cavus, varus and equinus deformities and incompletely corrected the adduction deformity of

clubfoot. Ponseti method may cause dorsal talonavicular subluxation in sagittal plane and lateral dislocation of the navicular bone in transverse plane on MRI.

Abbreviations

MRI: Magnetic resonance imaging

Declarations

Availability of data and materials

Please contact corresponding author for data requests.

Acknowledgements

None

Funding

This study was not supported by any funding organization.

Contributions

ZJL designed the study. JCZ collected the data and images and wrote the manuscript. HXL and NQW measured the six major parameters and performed the statistical analysis.ZJL, NQW and HXL reviewed and revised the manuscript. All authors read and approved the final manuscript.

Ethics declarations

This study was approved by life ethics committee of the Capital Institute of Pediatrics and was performed in accordance with the ethical standards laid down in an appropriate version of the 1964 Declaration of Helsinki.

Consent for publication

Consent for publication was included with the informed consent forms.

Competing interests

The authors declare that they have no competing interests.

References

1. Rieger MA, Dobbs MB. Clubfoot. Clin Podiatr Med Surg. 2022;39(1):1-14. doi:10.1016/j.cpm.2021.08.006.
2. Ponseti IV. The treatment of congenital clubfoot. J Orthop Sports Phys Ther. 1994;20(1):1. doi:10.2519/jospt.1994.20.1.1.
3. Derzsi Z, Gozar H, Gurzu S, et al. Congenital clubfoot in children after walking age: management and evaluation of 41 feet with the dimeglio score. J Clin Diagn Res. 2013;7(12):2841-2843.

doi:10.7860/JCDR/2013/7361.3772.

4. Addosooki A, Tammam H, Morsy AF, et al. Correlation of radiographic parameters with clinical correction in idiopathic congenital talipes equinovarus undergoing Ponseti treatment. Int Orthop. 2021;45(12):3139-3146. doi:10.1007/s00264-021-05138-7.
5. Segev E, Yavor A, Ezra E,et al. Growth and development of tarsal and metatarsal bones in successfully treated congenital idiopathic clubfoot: early radiographic study. J Pediatr Orthop B. 2009;18(1):17-21. doi:10.1097/BPB.0b013e3283196118.
6. Fahrenbach GJ, Kuehn DN, Tachdjian MO. Occult subluxation of the subtalar joint in clubfoot (using computerized tomography). J Pediatr Orthop. 1986;6(3):334-339. doi:10.1097/01241398-198605000-00014.
7. Johnston CE 2nd, Hobatho MC, Baker KJ, et al. Three-dimensional analysis of clubfoot deformity by computed tomography. J Pediatr Orthop B. 1995;4(1):39-48. doi:10.1097/01202412-199504010-00006.
8. Josse A, Fraisse B, Marleix S, et al. Correlations between physical and ultrasound findings in congenital clubfoot at birth. Orthop Traumatol Surg Res. 2018;104(5):651-655. doi:10.1016/j.otsr.2018.02.019.
9. Simons GW. A standardized method for the radiographic evaluation of clubfeet[J]. Clin Orthop Relat Res. 1978;(135):107-118.doi:10.1097/00003086-197809000-00025.
10. Mary P, Damsin JP, Carlioz H. Correction of equinus in clubfoot: the contribution of arthrography. J Pediatr Orthop. 2004;24(3):312-316.
11. Kamath SU, Austine J. Radiological assessment of congenital talipes equinovarus (clubfoot): Is it worthwhile?. Foot (Edinb). 2018;37:91-94.DOI:10.1016/j.foot.2018.06.001.
12. Blakeslee TJ. Comparative radiographic analysis of congenital idiopathic talipes equinovarus (clubfoot) in infancy: a retrospective study. J Foot Surg. 1988;27(3):188-205.doi:10.1111/j.1574-6968.2009.01743.x.
13. Siapkara A, Duncan R. Congenital talipes equinovarus: a review of current management. J Bone Joint Surg Br. 2007;89(8):995-1000. doi:10.1302/0301-620X.89B8.19008.
14. Downey DJ, Drennan JC, Garcia JF. Magnetic resonance image findings in congenital talipes equinovarus. J Pediatr Orthop. 1992;12(2):224-228. doi:10.1097/01241398-199203000-00013.
15. Pekindil G, Aktas S, Saridogan K,et al. Magnetic resonance imaging in follow-up of treated clubfoot during childhood. Eur J Radiol. 2001;37(2):123-129. doi:10.1016/s0720-048x(00)00275-8.
16. Kamegaya M, Shinohara Y, Kokuji Y, et al. Evaluation of pathologic abnormalities of clubfoot by magnetic resonance imaging. Clin Orthop Relat Res. 2000;(379):218-223. doi:10.1097/00003086-200010000-00025.
17. Pirani S, Zeznik L, Hodges D. Magnetic resonance imaging study of the congenital clubfoot treated with the Ponseti method. J Pediatr Orthop. 2001;21(6):719-726.
18. Ahmad AA, Ghanem AF, Hamaida JM, et al. Magnetic resonance imaging of severe idiopathic club foot treated with one-week accelerated Ponseti (OWAP) technique. Foot Ankle Surg. 2021;S1268-7731(21)00091-6. doi:10.1016/j.fas.2021.04.012.
19. Saito S, Hatori M, Kokubun S, et al. Evaluation of calcaneal malposition by magnetic resonance imaging in the infantile clubfoot. J Pediatr Orthop B. 2004;13(2):99-102. doi:10.1097/00009957-200403000-00007.
20. Kamegaya M, Shinohara Y, Kuniyoshi K, et al. MRI study of talonavicular alignment in club foot. J Bone Joint Surg Br. 2001;83(5):726-730. doi:10.1302/0301-620x.83b5.10936.

21. Miyagi N, Iisaka H, Yasuda K, et al Onset of ossification of the tarsal bones in congenital clubfoot. J Pediatr Orthop. 1997;17(1):36-40.
22. Carroll NC. Clubfoot: what have we learned in the last quarter century?. J Pediatr Orthop. 1997;17(1):1-2. doi: 1097/01241398-199701000-00001.
23. Jakob RP, Haertel M, Stüssi E. Tibial torsion calculated by computerised tomography and compared to other methods of measurement. J Bone Joint Surg Br. 1980;62-B(2):238-242. doi:10.1302/0301-620X.62B2.7364840.
24. Mitchell J, Bishop A, Feng Y, et al. Residual Equinus After the Ponseti Method: An MRI-based 3-Dimensional Analysis. J Pediatr Orthop. 2018;38(5):e271-e277. doi:10.1097/BPO.0000000000001147.

Figures

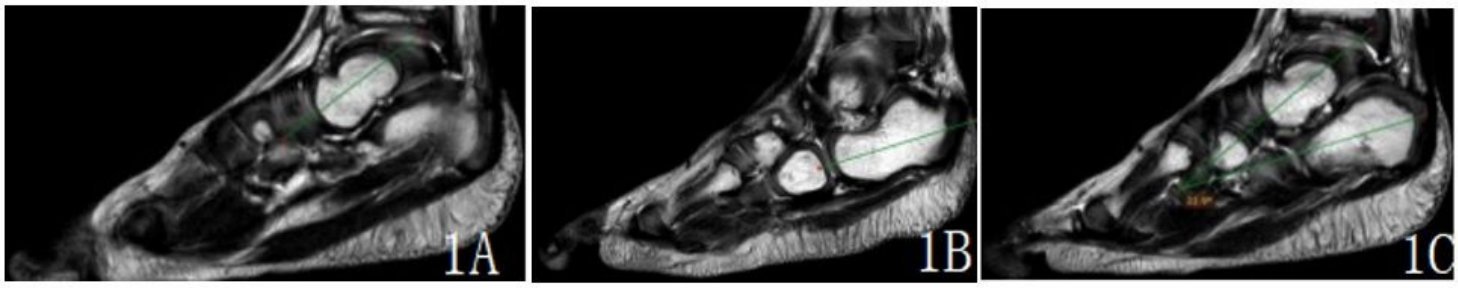

Figure 1

1A: the long axis of talus; 1B: the long axis of calcaneus; 1C: sagittal talocalcaneal angle.

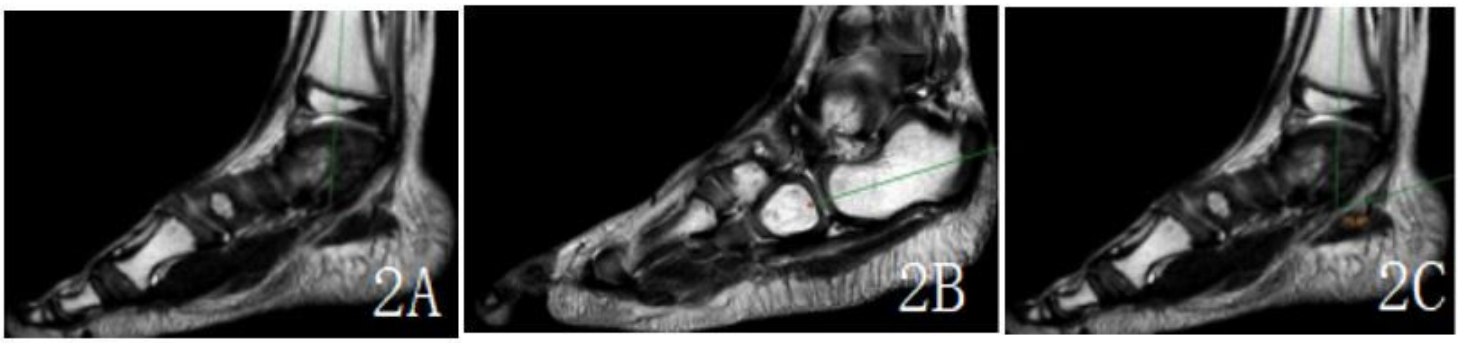

Figure 2

2A: the long axis of tibia; 2B: the long axis of calcaneus; 2C: sagittal tibiocalcaneal angle.

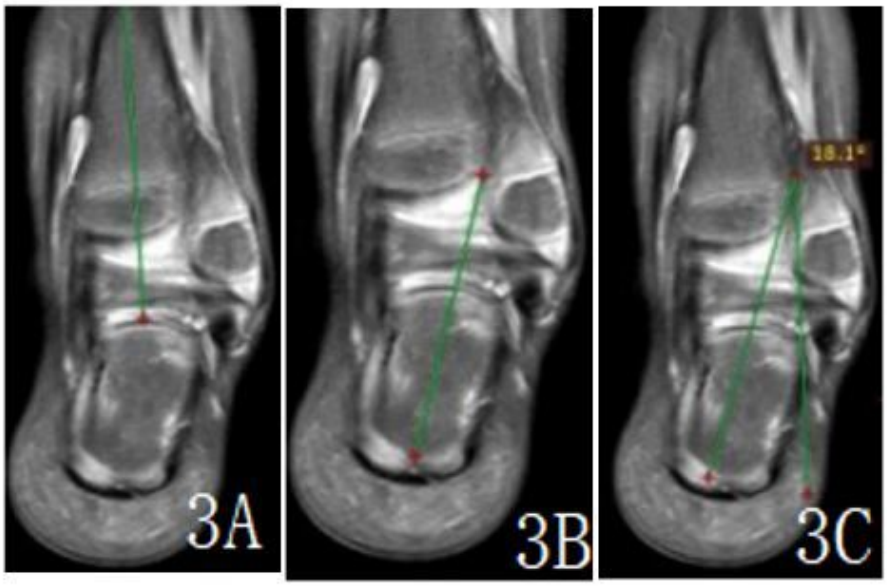

Figure 3

3A: the long axis of tibia; 3B: the long axis of calcaneus; 3C: coronal tibiocalcaneal angle.

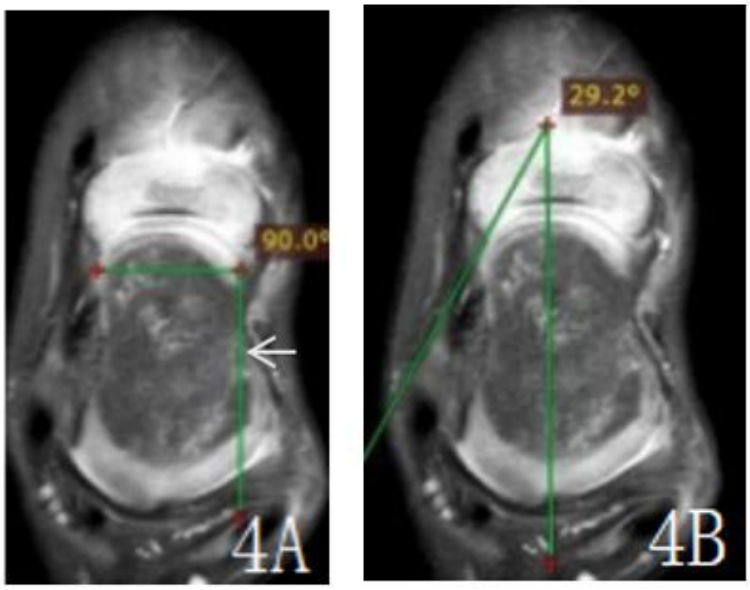

Figure 4

4A: the long axis of talar neck(arrow); 4B: transverse talar neck angle.

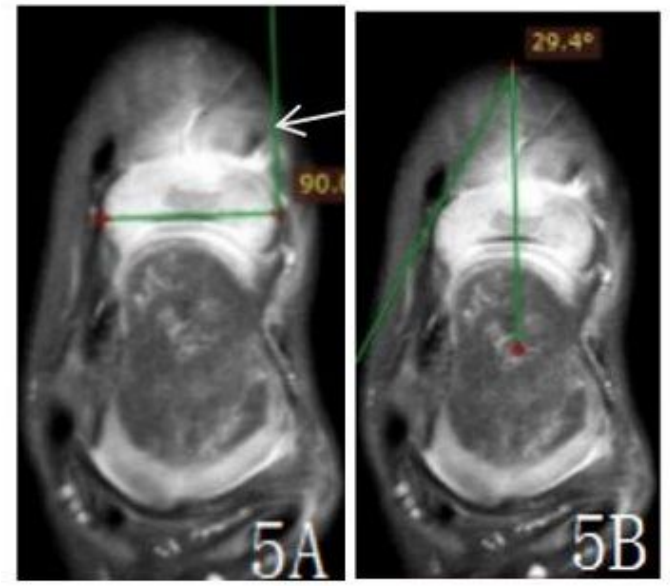

Figure 5

5A: the long axis of navicular(arrow); 5B: transverse talonavicular angle.

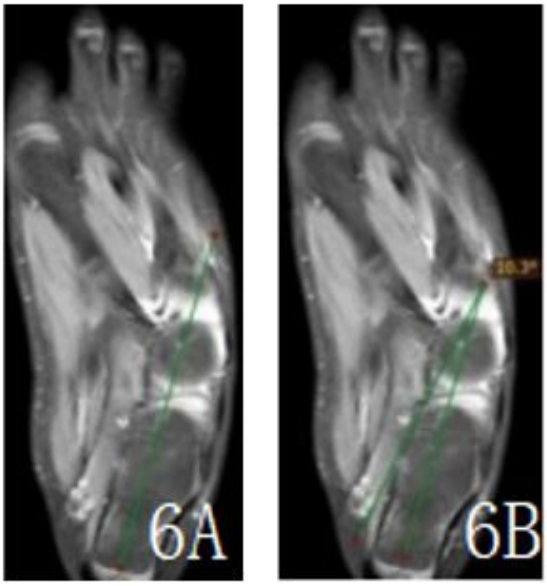

Figure 6

6A: the long axis of calcaneus; 6B: transverse talocalcaneal angle.

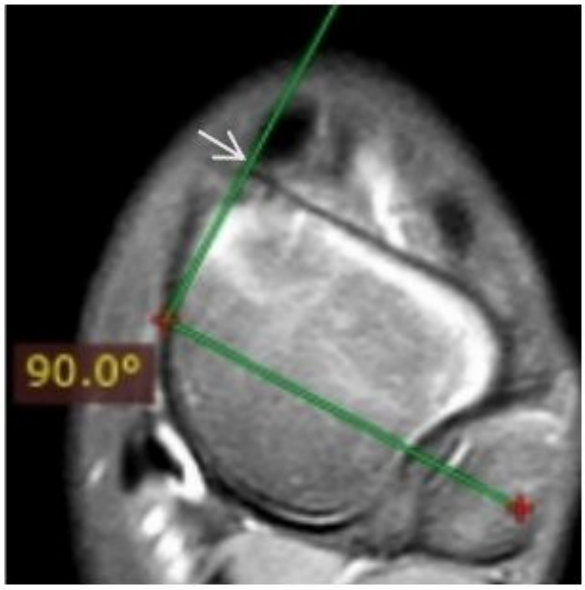

Figure 7

the long axis of talar body(arrow).

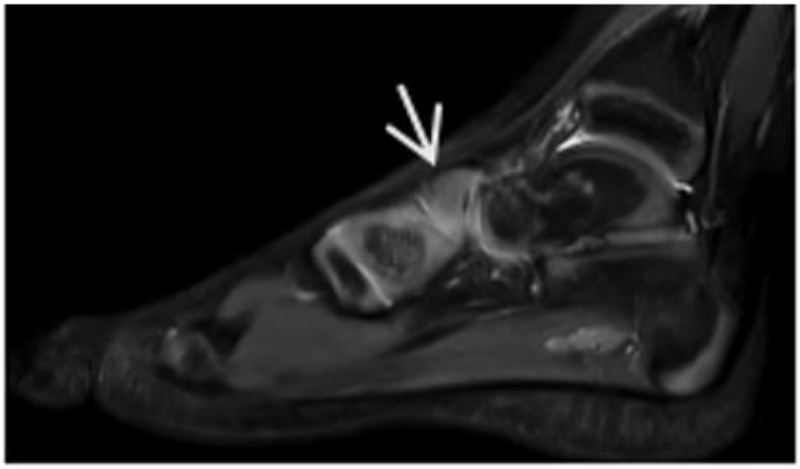

Figure 8

dorsal talonavicular subluxation in the sagittal plane of MRI(arrow).

Figure 9

lateral talonavicular subluxation in the transverse plane of MRI(arrow).