The techniques, short and long term outcomes of laparoscopic transverse colectomy comparing to laparoscopic hemicolectomy in mid-transverse colon cancer.

Rui Sun
Chinese Academy of Medical Sciences & Peking Union Medical College
Guannan Zhang
Chinese Academy of Medical Sciences & Peking Union Medical College
Xiyu Sun
Chinese Academy of Medical Sciences & Peking Union Medical College
Beizhan Niu
Chinese Academy of Medical Sciences & Peking Union Medical College
Jiaolin Zhou
Chinese Academy of Medical Sciences & Peking Union Medical College
Lin Cong
Chinese Academy of Medical Sciences & Peking Union Medical College
Huizhong Qiu
Chinese Academy of Medical Sciences & Peking Union Medical College
Guole Lin
Chinese Academy of Medical Sciences & Peking Union Medical College
Bin Wu
Chinese Academy of Medical Sciences & Peking Union Medical College
Yi Xiao (Xiaoy@pumch.cn)
Chinese Academy of Medical Sciences & Peking Union Medical College

---

Research Article

Keywords: Mid-transverse colon cancer, laparoscopic transverse colectomy, laparoscopic right hemicolectomy, laparoscopic left hemicolectomy, functional outcomes

Posted Date: April 20th, 2022

DOI: https://doi.org/10.21203/rs.3.rs-1541751/v1

Abstract

Purpose: Our study was aimed to depict and summarize the technique, short and long term outcomes of laparoscopic transverse colectomy in one single clinical center and compare with laparoscopic hemicolectomy.

Methods: This was a retrospective cohort study of patients with mid-transverse colon cancer in one single clinical center from February 2012 to October 2020. The enrolled patients were divided into two groups undergoing laparoscopic transverse colectomy and laparoscopic hemicolectomy, respectively. The intraoperative, postoperative complications, oncological outcomes and functional outcomes were compared between the two groups. The primary endpoint was disease free survival (DFS).

Results: The study enrolled 70 patients with 40 patients undergoing laparoscopic transverse colectomy and 30 patients undergoing hemicolectomy. The intraoperative accidental hemorrhage and multiple organ resection occurred similarly in the two groups. In transverse colectomy, caudal-to-cephalic approach was likely to harvest more lymph nodes although require more operation time than cephalic-to-caudal approach (23.1(14.3) versus 13.4(5.4) lymph nodes, P=0.004; 184.3(37.1)min versus 146.3(44.4)min, P=0.012). The laparoscopic transverse colectomy was marginally associated with lower incidence of overall postoperative complications and shorter postoperative hospital stay although without statistical significance (8(20.0%) versus 12(40.0%), P=0.067; 7(5-12) VS 7(5-18), P=0.060). The 3-year DFS showed no significant difference (3-year DFS 89.7% in transverse colectomy versus 89.9% in hemicolectomy, P=0.688) between the two groups. The alternating consistency of defecation occurred significantly less after transverse colectomy (15(51.7%) VS 20(80.0%), P=0.030).

Conclusions: The laparoscopic transverse colectomy is technically, oncologically and functionally feasible for mid-transverse colon cancer. Performing the caudal-to-cephalic approach might be more advantageous in lymphadenectomy.

Introduction

Transverse colon cancer was excluded by large randomized controlled trials (RCTs) which was aimed to compare the outcomes of laparoscopic colectomy versus open surgery because of its relative low prevalence in colon cancer from all sites and variability of its surgical approaches[1–4]. Compared with those tumors located closely to hepatic or splenic flexure, the mid-transverse colon cancer showed more special features. Usually situated between the left and right branch of the middle colic artery (MCA), the surgical option of mid-transverse colon cancer can shift from hemicolectomy to transverse colectomy. Currently, the more advantageous surgical approach for mid-transverse colon cancer remains under debate. In several retrospective studies[5–7], the transverse colectomy showed equivalent long-term outcomes with hemicolectomy and did not alter the recurrence pattern. But from the perspective of the amount of surgery, the hemicolectomy is still the mainstream to treat mid-transverse colon cancer[5, 8]. A national retrospective study from Italy even found that transverse colectomy was associated with higher

incidence of anastomotic leak and compromising oncological outcomes[8]. The actual performing of the transverse colectomy involves flexible and reasonable decision-making which depends on the experience of the surgeon. For examples, surgeons should estimate which colonic flexure or both flexures to mobilize, how to accomplish the tension-free anastomosis and the extension of lymphadenectomy. Due to the standardized procedure of laparoscopic transverse colectomy was undefined, our study tried to introduce the specific laparoscopic transverse colectomy procedure in our institution and compare the surgical and oncological outcomes of this surgical approach with laparoscopic hemicolectomy.

Through the literature, the injury or resection of the autonomic nerve plexus and also the extension of the resected bowel can theoretically act as main factors to affect the risk of diarrhea or bowel function after laparoscopic right hemicolectomy[9–11]. Transverse colectomy has advantages in preserving the terminal ileum, ascending colon and ileocecal valve and may imply lower risk of injury to the autonomic nerve plexus. Whether transverse colectomy could result in more optimal function outcomes was rarely investigated in previous studies. Therefore, our study also tried to discovery whether there was some difference in functional outcomes between laparoscopic transverse colectomy and hemicolectomy.

Methods

Patients

This retrospective cohort study of single-center was approved by the Research Ethics Committee at Peking Union Medical College Hospital. The recruitment criteria were: consecutive patients who were diagnosed with mid-transverse colon adenocarcinoma without distant metastasis and resected by laparoscopic radical surgery from February 2012 to October 2020. The mid-transverse colon cancer was referred to colon cancer located in the middle one-third of the transverse colon. Among these patients, patients with other malignant diseases, distant metastasis, multiple primary colorectal cancer and patients undergoing palliative surgery, total and subtotal colorectal resection were excluded.

Surgical procedure

The enrolled patients underwent laparoscopic transverse colectomy or laparoscopic hemicolectomy in the discretion of the surgeon in charge. The laparoscopic surgery was all performed under 3D imaging system. The camera port site was located between the pubic symphysis and umbilicus using a 10mm trocar. The main operating port site was located in left upper abdomen when doing transverse colectomy and right or extended right colectomy (Figure 1a) while in right upper abdomen when doing left colectomy (Figure 1b) using a 12mm trocar.

Laparoscopic transverse colectomy

The laparoscopic transverse colectomy was defined as a surgery ligating the MCA at the root but preserving the ileocolic artery (ICA) and left colic artery (LCA). This surgery involved removal of 10 cm of normal bowel surrounding the lesion and was all D3 lymph nodes dissection which referred to the

removal of lymph nodes up to main lymph nodes at the origin of MCA (223, which is named by Japanese Society for Cancer of the Colon and Rectum[12]). The surgery was performed by either caudal-to-cranial or cranial-to caudal approach. Caudal-to-cranial approach started by pulling the transverse colon and the attached greater omentum towards upper abdomen to adequately expose the base of transverse mesocolon. Then the surgeons found the projection of MCA at the conjunction of the base of transverse mesocolon, ascending mesocolon and Treitz's ligament. The MCA and middle colic vein (MCV) was then ligated and the main lymph nodes (223) was removed. The subsequent lymphadenectomy was performed from the lower border of pancreas and along the the embryological plane. The lymphatic adipose tissue between the lower border of pancreatic head and transverse mesocolon was cautiously removed in this approach. Cranial-to-caudal approach started by dissecting the greater omentum and entering the lesser omentum sac to separate the transverse mesocolon. Then the transverse mesocolon was dissected at the lower border of the pancreas. The MCA and MCV were detached and divided and lymphadenectomy at the origin of main trunk artery was performed. The gastrocolic trunk (GCT) and right colic artery (RCA) were not separated considering the location of the tumor.

Mobilization of hepatic and/or splenic flexure was done to ensure the tension-free anastomosis. The anastomosis was performed either intracorporeally or extracorporeally. The intracorporeal anastomosis was all done by side-to-side configuration while the extracorporeal anastomosis was done by either side-to-side or side-to-end configuration.

Laparoscopic hemicolectomy

The laparoscopic right hemicolectomy involved the ligation of ICA and right branch of MCA. The laparoscopic extended right hemicolectomy involved the ligation of ICA and the root of MCA. Similarly, the laparoscopic left hemicolectomy involved the ligation of LCA and the left branch of MCA while the laparoscopic extended left hemicolectomy involved the ligation of LCA and the root of MCA. The bowel was resected from terminal ileum or the conjunction of descending colon and sigmoid colon to 10cm distal or proximal to the tumor site. The decision to ligate only one branch of MCA or the root of MCA depended on the relative positional relationship between the tumor and the feeding artery basically according to the Japanese Classification of Colorectal, Appendiceal and Anal Carcinoma[13]. When doing hemicolectomy, it was required to do sharp dissection following the anatomical plane and the extension of lymphadenectomy might be D2 or D3 according to different tumor stage or patient status. No matter D2 or D3 surgery was performed, the main lymph nodes at the root of MCA (223) were always dissected. The anastomosis technique was either extracorporeal or intracorporeal. Both side-to-side and side-to-end configuration were used.

Postoperative treatment

The postoperative complications were defined as adverse events happened during 30 day after the surgery, which included anastomotic leak, anastomotic hemorrhage, intra-abdominal hemorrhage, chylous leak, diarrhea, intestinal obstruction, pneumonia, urinary infection, wound infection,

cardiovascular accident and thrombotic disease. The postoperative complications were classified according to Clavien-Dindo grading[14]. The discharge criteria included the absence of complications and tolerance of liquid food. The administration of adjuvant therapy and strategy of follow-up was depicted in our previous published article[15]. The disease-free survival (DFS) is defined as the surgery to the time of recurrence or metastasis confirmed by objective examination or else death for any cause. The overall survival (OS) is defined as the surgery to the time of death for any cause. The DFS was set as our primary outcome.

Questionnaire investigation

The functional outcomes of enrolled patients were investigated through comprehensive online questionnaire or by telephone. The questionnaire was composed of Bristol stool scale score and many specific questions focusing on the impact of defecation on quality of life. The questionnaire and associated questions were applied in previous functional studies[9, 16].

Data analysis

The clinical data was collected in the prospectively established database in our division. The complications occurred after discharge was identified and registered supplementarily by administrators. These clinical data including baseline characteristics, operation information, recovery data, complications and pathological parameters other than functional data of enrolled patients was retrospectively extracted and confirmed through electronic medical records. Categorical parameters were compared using Chi-square or Fisher's exact test and continuous parameters were compared using Students's *t* test. The Kaplan-Meier method and log-rank test was used to compare DFS and OS. A P value of <0.05 was regarded as of statistical significance. Data analyses were conducted using R (version 4.0.3, R Foundation for Statistical Computing, Vienna, Austria, 2020, https://www.R-project.org).

Results

A total of 70 patients fulfilling the recruitment criteria were included in the study (Fig. 1). Among them, 40 patients underwent laparoscopic transverse colectomy while 20 patients and 10 patients underwent laparoscopic extended/right hemicolectomy and laparoscopic extended/left hemicolectomy, respectively. The clinical and pathological baseline characteristics of patients undergoing laparoscopic transverse colectomy with patients undergoing laparoscopic hemicolectomy were comparable (Table 1).

Table 1
Baseline characteristics

Item	Laparoscopic transverse colectomy (n = 40)	Laparoscopic hemicolectomy (n = 30)	P value
Age, y	58.5 ± 12.5	61.9 ± 12.3	0.264
Male, n(%)	15(37.5)	17(56.7)	0.111
BMI, kg/m^2	24.2 ± 2.9	24.9 ± 2.6	0.264
ASA, n(%)			0.584
I	4(10.0)	5(16.7)	
II	24(60.0)	15(50.0)	
III	12(30.0)	10(33.3)	
pT, n(%)			0.499
T_{is}	1(2.5)	0(0.0)	
T1	1(2.5)	0(0.0)	
T2	4(10.0)	2(6.7)	
T3	30(75.0)	21(70.0)	
T4	4(10.0)	7(23.3)	
pN, n(%)			0.652
N0	23(57.5)	20(66.7)	
N1	10(25.0)	7(23.3)	
N2	7(17.5)	3(10.0)	
AJCC stage, n(%)			0.769
TisN0	1	0	
I	3	2	
II	19	18	
III	17	10	
Differentiation degree, n(%)			0.181
Well and moderate	27(67.5)	25(83.3)	
Poor	6(15.0)	4(13.3)	

Item	Laparoscopic transverse colectomy (n = 40)	Laparoscopic hemicolectomy (n = 30)	P value
Mucinous adenocarcinoma	7(17.5)	1(3.3)	
Vascular or lymphatic invasion, n(%)			0.819
Present	11(27.5)	9(30.0)	
Absent	29(72.5)	21(70.0)	
Perineural invasion, n(%)			1.000
Present	3(7.5)	3(10.0)	
Absent	37(92.5)	27(90.0)	

The operative details of the two groups are shown in Table 2. Among transverse colectomy, mobilization of colic splenic or/and hepatic flexure were demanded for 33 cases (82.5%). The extraperitoneal anastomosis was applied in all but two case either by stapled anastomosis or by hand-sewing in laparoscopic transverse colectomy. Among hemicolectomy, the extended hemicolectomy was required in 19 cases (63.3%). All of the surgery were done to completely dissect the main lymph nodes at the root of MCA (223) no matter the overall lymphadenectomy was D2 or D3. The mean operation time of the two groups did not differ significantly (P = 0.463) as well as the mean estimated blood loss (P = 0.527). The mean number of harvested lymph nodes was significantly lower in transverse colectomy group than in hemicolectomy group (19.7 (12.3) versus 27.4 (15.3), P = 0.025).

Table 2
Operative details and postoperative short-term outcomes.

Item		Laparoscopic transverse colectomy (n = 40)	Laparoscopic hemicolectomy (n = 30)	P value
Operation time, min		171.0 ± 43.3	163.0 ± 40.9	0.436
Estimated blood loss, ml		53.0 ± 50.8	61.2 ± 56.1	0.527
Mobilization of colonic flexures, n(%)				-
Hepatic flexure		19(47.5)	-	
Splenic flexure		8(20.0)	-	
Both flexures		6(15.0)	-	
Neither flexures		7(17.5)	-	
Intraoperative complications, n(%)				
Multiple organ resection		3(7.5)	1(3.3)	0.630
Vascular injury		1(2.5)	0(0.0)	1.000
Conversion to open surgery, n(%)		0(0.0)	1(3.3)	0.429
Conversion to hemicolectomy, n(%)		-	3	-
Number of lymph nodes harvested		19.7 ± 12.8	27.4 ± 15.3	0.025
Ambulation time, days*		1(1–4)	1(1–2)	0.383
Time to first flatus, days*		2(1–4)	2(1–4)	0.669
Time to fluid diet, days*		5(4–7)	5(3–12)	0.715
Postoperative hospital stay, days*		7(5–12)	7(5–18)	0.060
Postoperative complications, n(%)†		8(20.0)	12(40.0)	0.067
Clavein-Dindo Grade I	Diarrhea	1	1	
	Chylous leak	1	1	

*Data was shown by median with range.

†Patients could have more than one kind of complication. This parameter was referred to the number of patients who were affected by complications. The detailed complications below were referred to number of events diagnosed.

Item		Laparoscopic transverse colectomy (n = 40)	Laparoscopic hemicolectomy (n = 30)	P value
	Wound infection	1	1	
Clavein-Dindo Grade II	Pneumonia	1	1	
	Pulmonary embolism	1	0	
	Abdominal infection	0	1	
	Urinary infection	1	1	
	Diarrhea	1	2	
	Intestinal obstruction	0	4	
	Chylous leak	0	1	
Clavein-Dindo Grade III	Anastomotic leak	0	1	
	Intestinal obstruction	1	1	
	Wound infection	1	0	
*Data was shown by median with range.				
†Patients could have more than one kind of complication. This parameter was referred to the number of patients who were affected by complications. The detailed complications below were referred to number of events diagnosed.				

There were 26 (65.0%) cases undergoing caudal-to-cephalic approach in transverse colectomy while 14 (35.0%) cases undergoing cephalic-to-caudal approach. The mean operation time was significantly longer but the mean number of harvested lymph nodes was also significantly more in caudal-to-cephalic approach (operation time: 184.3(37.1) versus 146.3(44.4), P = 0.012; total harvested lymph nodes: 23.1(14.3) versus 13.4(5.4), P = 0.004)(Table 3).

Table 3
Comparison of different approaches of laparoscopic transverse colectomy.

Item	Caudal approach(n = 26)	Cephalic approach(n = 14)	P value
Operative time, min	184.3 ± 37.1	146.3 ± 44.4	0.012
Estimated blood loss, ml	48.7 ± 42.0	61.1 ± 65.0	0.526
Number of lymph nodes harvested	23.1 ± 14.3	13.4 ± 5.4	0.004

Table 4
The incidences of bowel dysfunction in the laparoscopic transverse colectomy and hemicolectomy.

Outcome	Laparoscopic transverse colectomy (n = 29)	Laparoscopic hemicolectomy (n = 25)	P value
Bristol stool scale score 6–7, n(%)	1(3.4)	3(12.0)	0.326
Four or more bowel movements daily, n(%)	2(6.9)	2(8.0)	1.000
Bowel function impact on QoL, n(%)	13(44.8)	6(24.0)	0.113
Alternating consistency, n(%)	15(51.7)	20(80.0)	0.030
More than 5min per attempt to defecate†, n(%)	13(44.8)	7(28.0)	0.202
Urgency*, n(%)	3(10.3)	2(8.0)	1.000
Unproductive call to defecate*, n(%)	6(20.7)	1(4.0)	0.108
Strain to defecate, n(%)	4(13.8)	2(8.0)	0.675
Obstructive sensation*, n(%)	0(0.0)	1(4.0)	0.463
Incomplete evacuation*, n(%)	3(10.3)	3(12.0)	1.000
Clustering*, n(%)	2(6.9)	5(2.0)	0.229
Nocturnal bowel movement*, n(%)	1(3.4)	2(8.0)	0.591
Flatulence*, n(%)	5(17.2)	1(4.0)	0.200
Ability to defer defecation for more than 15min, n(%)	22(75.9)	19(76.0)	0.991
Incontinence flatus*, n(%)	2(6.9)	1(4.0)	1.000
Incontinence liquid*, n(%)	0(0.0)	1(4.0)	0.463
Incontinence solid*, n(%)	3(10.3)	1(4.0)	0.615
Use of pads*, n(%)	0(0.0)	1(4.0)	0.463
Soiling*, n(%)	0(0.0)	0(0.0)	1.000

*Symptoms occuring at least once a week

†The symptom/treatment being present or used.

Outcome	Laparoscopic transverse colectomy (n = 29)	Laparoscopic hemicolectomy (n = 25)	P value
Antidiarrheal agents†, n(%)	3(10.3)	4(16.0)	0.692
*Symptoms occuring at least once a week			
†The symptom/treatment being present or used.			

The incidence of overall postoperative complications was marginally lower in laparoscopic transverse colectomy without statistical significance (8/40(20.0%) versus 12/40(40.0%), P = 0.067). But the CD-III complications did not differ in the two groups. Two patients suffered from complications requiring reoperation in laparoscopic transverse colectomy group. One underwent reoperation to release the intestinal internal hernia. Another underwent debridement due to severe wound infection. One patient in laparoscopic hemicolectomy group had anastomotic leak and underwent ostomy. The postoperative complications in detail were shown in Table 2. The ambulation time, time to first flatus and fluid diet after surgery were comparable in the two groups. The postoperative hospital stay was marginally shorter in laparoscopic transverse colectomy group without statistical significance (7(5–12) VS 7(5–18), P = 0.060) (Table 2).

The median follow-up period was 3.5 years(interquartile range 2–5 years). One patient in laparoscopic transverse colectomy lost to follow-up. The 3-year disease free survival in laparoscopic transverse colectomy group and hemicolectomy group was 89.7% (95%CI 80.7%-99.8%) and 89.9% (95% CI 79.6%-100.0%), respectively (Fig. 2). The difference between the two groups did not constitute statistical significance (P = 0.688).The 5-year overall survival was 89.4%(95%CI 80.1%-99.8%) in laparoscopic transverse colectomy versus 82.9%(95%CI 68.3%-100.0%) (P = 0.726) (Fig. 2).

To investigate the functional outcomes, the questionnaire was despatched for all 70 patients and 29 (72.5%) patients in laparoscopic transverse colectomy and 25 (83.3%) patients in hemicolectomy group finished the questionnaire survey (P = 0.285) (Fig. 1). The mean time from surgery to questionnaire was 4.7 ± 2.0 years. The results showed alternating consistency in defecation occurred significantly more frequently in laparoscopic hemicolectomy (P = 0.030). Compared with laparoscopic hemicolectomy, transverse colectomy did not show significance difference in Bristol stool score of 6–7 and 4 or more bowel movements daily. The impact on quality of life (QoL) of bowel function appeared equivalent in transverse colectomy and hemicolectomy. Other symptoms on questionnaire also occurred similarly in the two groups.

Discussion

Our study found laparoscopic transverse colectomy D3 surgery was a feasible surgical approach with similar risk of intraoperative and postoperative complications compared with laparoscopic

hemicolectomy. Moreover laparoscopic transverse colectomy was associated with comparable oncological and functional outcomes to laparoscopic hemicolectomy for mid-transverse colon cancer.

In a previous study, researchers found the number of transverse colectomy saw a decrease in the past decade[5]. On the one hand, surgeons hesitated to performing laparoscopic transverse colectomy because the surgery was not so familiar for them to get in the targeted embryological plane to accomplish sharp dissection as standard laparoscopic hemicolectomy. On the other hand, whether the oncological outcomes of laparoscopic transverse colectomy could be a surrogate was debatable. In our cohort study, the mean operation time, estimated blood loss and intraoperative complications of transverse colectomy were shown to be comparable to hemicolectomy, which indicated the surgery was feasible in experienced hands. Accomplishing complete mesocolic excision (CME) is of upmost importance in transverse colectomy to ensure the oncological outcomes. In our opinion, the transverse mesenteric lymph nodes are concealed partly in the fold below the pancreas. This part of lymph nodes are more likely to be completely removed when the transverse mesocolon is retracted cephalically and the cutting line is from the dorsal side of the mesocolon. The pancreas serves as important landmark to completely dissociate transverse mesocolon in this approach. While in cephalic-to-caudal approach the cutting line is difficult to cross over the pancreas and turn around to dissociate the remaining transverse mesocolon folded in the angle to the inferior and posterior of pancreas. Our results showed more operation time was required but more lymph nodes were harvested in caudal approach than cephalic approach in laparoscopic transverse colectomy. This result was of expectation. The cutting line was predetermined to be longer in caudal-to-cephalic approach so the more operation time was required. Although the sample size was limited so the oncological outcomes of this two approaches were difficult to be compared, the more lymph nodes in caudal approach implied advanced lymphadenectomy which might lead to better therapeutic effect.

The resected bowel length was not measured in fresh specimen in our study. The proximal and distal margin was much accounted of in colectomy because the 10cm bowel resection was regarded as a basic principle to remove enough pericolic lymph nodes[17]. In our study the transverse colectomy also conformed to this basic principle and we found the resection margin can be guaranteed if the bowel was sufficiently mobilized. But the mobilization of the transverse colon as well as both flexures was technically challenging and should be performed meticulously to avoid the accidentally damage of the blood supply. In our cohort, two cases were determined to perform transverse colectomy but converted to right colectomy because of the poor blood perfusion of proximal bowel.

In the term of short-term outcomes, the transverse colectomy appeared to marginally decrease the risk of complications and length of hospital stay although there was no statistical significance. To investigate the complications in detail, the diarrhea and intestinal obstruction suspected of being associated with clostridium difficile infection occurred in six cases in hemicoletomy group, while there was one corresponding case in transverse colectomy group. Overall, the CD grading distribution of complications seems equivalent in both groups and the risk of CD-III complications was similar in the two groups. In most previous studies and meta-analysis, the incidence of postoperative complications did not differ in the two groups[17]. But in a previous study, Italian researchers found transverse colectomy was

associated with significant higher incidence of anastomotic leak, anemia as well as wound infection[8]. In this study the proportion of laparoscopic surgery came out to be significantly lower in transverse colectomy group, which can influence the interpretation of the results. From another perspective, the laparoscopic transverse colectomy grows to technological maturity in recent years. We think on this background the moderate dissection range in transverse colectomy might be beneficial to patients in terms of short-term outcomes, but this benefit should be cautiously considered based on a comparable oncological outcomes.

In the light of well-balanced demographic and pathological characteristics, we found that the oncological outcomes no matter DFS or OS was comparable in the two groups. Although in a relative small sample size the endpoint events were limited in our study, our study found the oncological outcomes were not compromising in the transverse colectomy group. In recent studies, researchers added emphasis on the pattern of lymph nodes metastasis of mid-transverse colon cancer. Park et al did not find lymph nodes metastasis along side the ICA and LCA in mid-transverse colon cancer[20], which indicated the lymphadenectomy of these lymph nodes might be redundant and simply in order to meet the rules of standard hemicolectomy. Fukuoka et al also found the invasion and metastasis of mid-transverse colon cancer mainly ran through MCA[20]. But researchers also found lymph nodes metastasis along side the RCA, which could be missed when doing transverse colectomy[20]. This may be related to the relative location between tumor lesion and RCA. In the study of Fukuoka, the lymph nodes metastasis surrounding RCA tended to occur in right-side of transverse colon[20]. Therefore, the reasonable patients selection when doing transverse colectomy would be important. Two retrospective studies found the UICC stage was significantly earlier and unfavorable pathological characteristics were less in transverse colectomy group[5, 6]. This reflected one trend for experts to choose surgical approach. No matter which surgical approach surgeons will choose, the dissection of lymph nodes along side the MCA, especially the dissection of 223 lymph nodes is crucial to treat the disease.

There was few studies discussing the long-term functional outcomes of transverse colectomy versus hemicolectomy. Our study found the long-term functional outcomes of the two groups were basically satisfactory. Some theories suggest laparoscopic right hemicolectomy was associated with chronic diarrhea because of the resection of ileocecal valve and terminal ileum[5, 6]. But in our study no matter the Bristol stool score and the bowel movements per day were equivalent in the two groups. Although we found the alternating consistency of defecation occurred more frequently after laparoscopic hemicolectomy, it was believed that as the time went on after the surgery, the impact on bowel function was gradually faded.

The limitations of our study existed mainly below: firstly, this is a retrospective study with limited sample size hence the statistical power of some results may be not strong enough to draw conclusions; secondly, the surgical choice was made according to the experience of different surgeons and there was no uniform standard to follow, which might lead to potential unbalance of the baseline characteristics

although these were not found by statistics; thirdly, there was a lack of baseline functional characteristics which influence the interpretation of the functional results.

In conclusions, the laparoscopic transverse colectomy is technically feasible, oncologically safe and functionally satisfactory for treating mid-transverse colon cancer. To ensure the oncological outcomes, the mid-transverse colon cancer with earlier clinical stage can be recommended to perform laparoscopic transverse colectomy. The caudal-to-cephalic approach might be more advantageous to accomplish complete lymphadenectomy.

Declarations

Funding Declaration: The manuscript has been not supported by any funding.

Authors Contributions: Rui Sun make conceptions of statistical part and wrote the main manuscript. Guannan Zhang completed the statistical part and prepared related tables.Xiyu Sun, Beizhan Niu, Jiaolin Zhou, Lin Cong, Guole Lin, Huizhong Qiu, and Bin Wu provided the data of the enrolled patients and revised the manuscript. Yi Xiao provided the scheme and design of the study and also revised the manuscript.

Conflict of interests: I declare that the authors have no conflict of interests to influence the results and/or discussion reported in this paper.

References

1. Lacy A M, García-Valdecasas J C, Delgado S, et al. Laparoscopy-assisted colectomy versus open colectomy for treatment of non-metastatic colon cancer: a randomised trial[J]. Lancet, 2002,359(9325):2224–2229.
2. Nelson H, Sargent D J, Wieand H S, et al. A comparison of laparoscopically assisted and open colectomy for colon cancer[J]. N Engl J Med, 2004,350(20):2050–2059.
3. Veldkamp R, Kuhry E, Hop W C, et al. Laparoscopic surgery versus open surgery for colon cancer: short-term outcomes of a randomised trial[J]. Lancet Oncol, 2005,6(7):477–484.
4. Guillou P J, Quirke P, Thorpe H, et al. Short-term endpoints of conventional versus laparoscopic-assisted surgery in patients with colorectal cancer (MRC CLASICC trial): multicentre, randomised controlled trial[J]. Lancet, 2005,365(9472):1718–1726.
5. Chong C S, Huh J W, Oh B Y, et al. Operative Method for Transverse Colon Carcinoma: Transverse Colectomy Versus Extended Colectomy[J]. Dis Colon Rectum, 2016,59(7):630–639.
6. Fukuoka H, Fukunaga Y, Nagasaki T, et al. Lymph Node Mapping in Transverse Colon Cancer Treated Using Laparoscopic Colectomy With D3 Lymph Node Dissection[J]. Dis Colon Rectum, 2022,65(3):340–352.

7. Matsuda T, Sumi Y, Yamashita K, et al. Optimal Surgery for Mid-Transverse Colon Cancer: Laparoscopic Extended Right Hemicolectomy Versus Laparoscopic Transverse Colectomy[J]. World J Surg, 2018,42(10):3398–3404.
8. Milone M, Degiuli M, Allaix M E, et al. Mid-transverse colon cancer and extended versus transverse colectomy: Results of the Italian society of surgical oncology colorectal cancer network (SICO CCN) multicenter collaborative study[J]. Eur J Surg Oncol, 2020,46(9):1683–1688.
9. Bertelsen C A, Larsen H M, Neuenschwander A U, et al. Long-term Functional Outcome After Right-Sided Complete Mesocolic Excision Compared With Conventional Colon Cancer Surgery: A Population-Based Questionnaire Study[J]. Dis Colon Rectum, 2018,61(9):1063–1072.
10. Thorsen Y, Stimec B, Andersen S N, et al. Bowel function and quality of life after superior mesenteric nerve plexus transection in right colectomy with D3 extended mesenterectomy[J]. Tech Coloproctol, 2016,20(7):445–453.
11. Lee K M, Baek S J, Kwak J M, et al. Bowel function and quality of life after minimally invasive colectomy with D3 lymphadenectomy for right-sided colon adenocarcinoma[J]. World J Gastroenterol, 2020,26(33):4972–4982.
12. Hashiguchi Y, Muro K, Saito Y, et al. Japanese Society for Cancer of the Colon and Rectum (JSCCR) guidelines 2019 for the treatment of colorectal cancer[J]. Int J Clin Oncol, 2020,25(1):1–42.
13. Japanese Classification of Colorectal, Appendiceal, and Anal Carcinoma: the 3d English Edition [Secondary Publication][J]. J Anus Rectum Colon, 2019,3(4):175–195.
14. Dindo D, Demartines N, Clavien P A. Classification of surgical complications: a new proposal with evaluation in a cohort of 6336 patients and results of a survey[J]. Ann Surg, 2004,240(2):205–213.
15. Lu J Y, Xu L, Xue H D, et al. The Radical Extent of lymphadenectomy - D2 dissection versus complete mesocolic excision of LAparoscopic Right Colectomy for right-sided colon cancer (RELARC) trial: study protocol for a randomized controlled trial[J]. Trials, 2016,17(1):582.
16. Emmertsen K J, Laurberg S. Impact of bowel dysfunction on quality of life after sphincter-preserving resection for rectal cancer[J]. Br J Surg, 2013,100(10):1377–1387.
17. Hashiguchi Y, Muro K, Saito Y, et al. Japanese Society for Cancer of the Colon and Rectum (JSCCR) guidelines 2019 for the treatment of colorectal cancer[J]. Int J Clin Oncol, 2020,25(1):1–42.
18. Leijssen L, Dinaux A M, Amri R, et al. A Transverse Colectomy is as Safe as an Extended Right or Left Colectomy for Mid-Transverse Colon Cancer[J]. World J Surg, 2018,42(10):3381–3389.
19. Milone M, Manigrasso M, Elmore U, et al. Short- and long-term outcomes after transverse versus extended colectomy for transverse colon cancer. A systematic review and meta-analysis[J]. International Journal of Colorectal Disease, 2019,34(2):201–207.
20. Park H M, Lee J, Lee S Y, et al. Distribution of lymph node metastasis and oncological outcomes of mid-transverse colon cancer: extended versus transverse colectomy[J]. Colorectal Dis, 2021,23(8):2007–2013.
21. Gracie D J, Kane J S, Mumtaz S, et al. Prevalence of, and predictors of, bile acid malabsorption in outpatients with chronic diarrhea[J]. Neurogastroenterol Motil, 2012,24(11):538–983.

22. Phillips F, Muls A C, Lalji A, et al. Are bile acid malabsorption and bile acid diarrhoea important causes of loose stool complicating cancer therapy?[J]. Colorectal Dis, 2015,17(8):730–734.

Figures

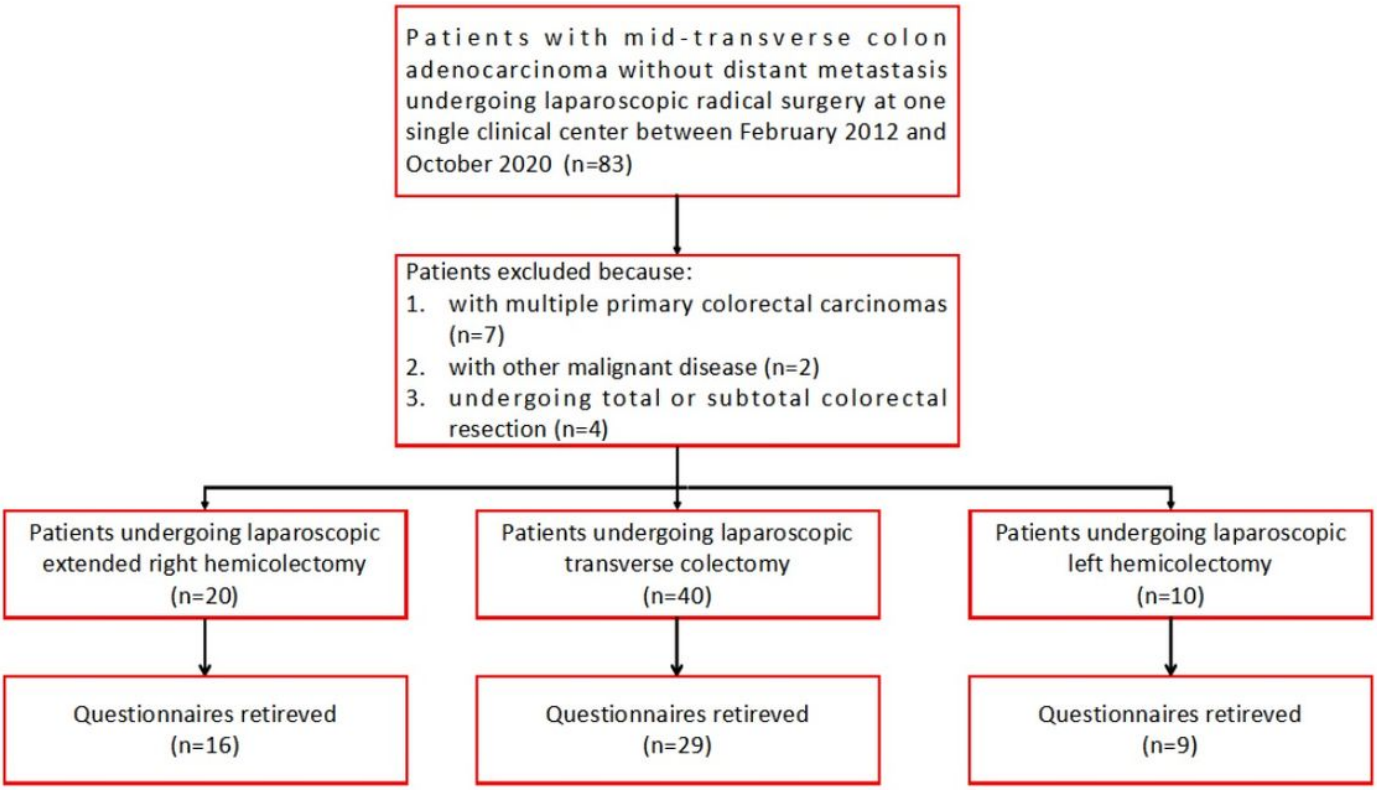

Figure 1

Flow chart of the study

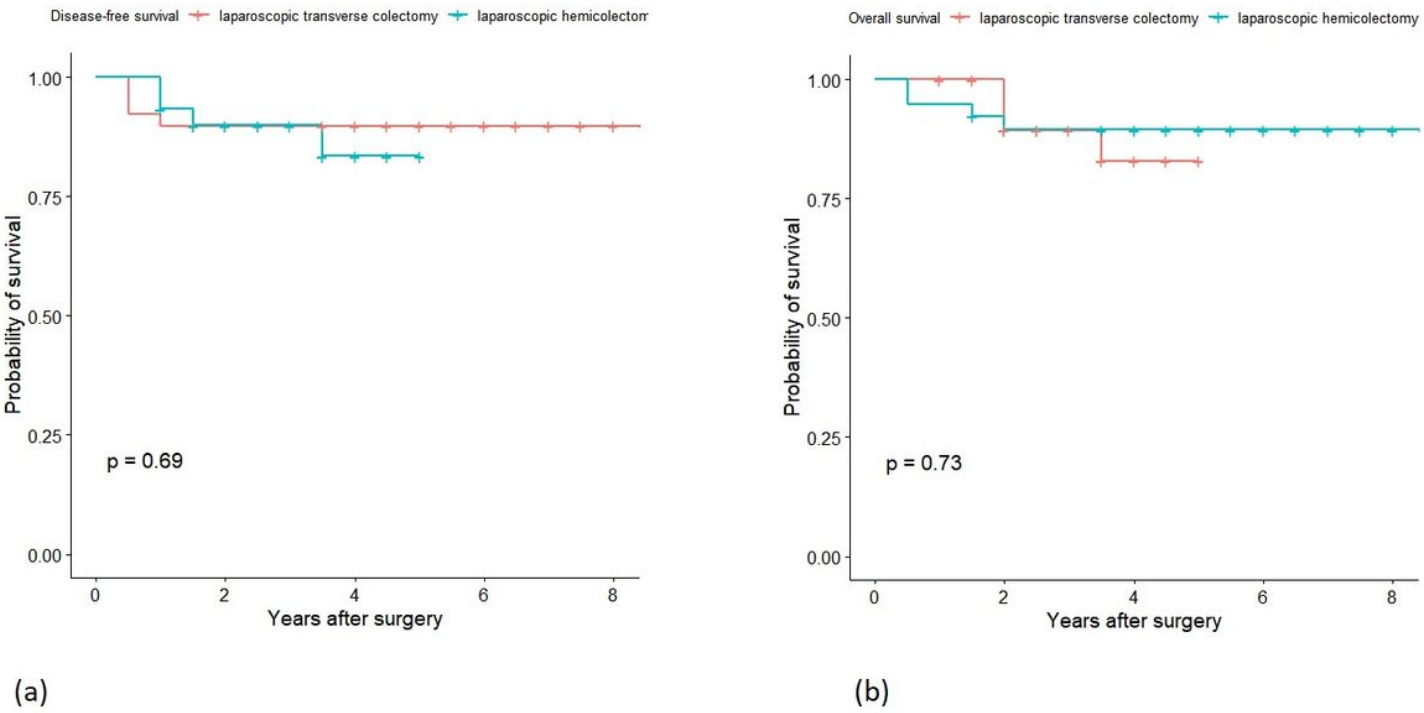

Figure 2

Survival for laparoscopic transverse colectomy and laparoscopic hemicolectomy