Iodine-125 interstitial brachytherapy after tumor excision: an alternative eye-sparing surgery for lacrimal gland carcinoma

Yang-jun Li (liyjun1969@126.com)
Air Force Military Medical University

Ping Wang
Air Force Military Medical University

Shao-bo Zhang
Air Force Military Medical University

Xiao-na Ning
Air Force Military Medical University

Chen-jun Guo
Air Force Military Medical University

Qiong Zhang
Air Force Military Medical University

Qi-lin Cheng
Air Force Military Medical University

Research Article

Keywords: lacrimal gland carcinoma, iodine 125 seeds, brachytherapy

Posted Date: February 10th, 2021

DOI: https://doi.org/10.21203/rs.3.rs-154192/v1

Iodine-125 interstitial brachytherapy after tumor excision: an alternative eye-sparing surgery for lacrimal gland carcinoma

Ping Wang[1], Shao-bo Zhang[1], Xiao-na Ning [1], Chen-jun Guo[1], Qiong Zhang[1], Qi-lin Cheng[1], Yang-jun Li [1]*

[1]Department of Ophthalmology, Tangdu Hospital, Air Force Military Medical University, Xi'an, Shaanxi

***Corresponding author:** Yang-jun Li, PhD, Email: liyjun1969@126.com

Coauthors: Ping Wang, MS, Email: wangping_xq@126.com

Shao-bo Zhang, Mr, Email: Zhangshaobo0911@126.com

Xiao-na Ning, PhD, Email: ningxiaona0223@163.com

Chen-jun Guo, PhD, Email: gchengjun@126.com

Qiong Zhang MS, Email: zhangqiong55555@163.com

Qi-lin Cheng, MS, Email: qilinkuaile@163.com

Ping Wang and Shao-bo Zhang are co-first authors, as they contributed equally to this research.

Conflict of Interest: No conflicting relationship exists for any author.

Running Title: Iodine-125 for lacrimal gland carcinoma

Address: Department of Ophthalmology, Tangdu Hospital, Air Force Military Medical University, No. 1, Xinsi Road, Xi'an, China.

Postal code: 710038

Abstract

Background: To describe the preliminary suppressive effects of iodine-125 brachytherapy for malignant lacrimal gland tumors after excision.

Methods: The study recruit 9 patients with lacrimal gland carcinoma from May 2017 to December 2020. All patients underwent eye-sparing surgical tumor resection first and then received iodine-125 interstitial brachytherapy to prevent tumor recurrence. We look over whether tumor recurred or metastasized by detecting the visual function and CT/MRI/PET-MRI of every patient.

Results： 1 patient was lost visit. The median follow-up period was 29 months of other 8 patients (range, 7-43 months). One patient experienced recurrence two years later but was free from local disease after iodine-125 seeds were implanted one more time. The vision of one female patient was lost due to the seeds moving to the optic nerve. In the remaining 6 patients, the vision was no changed, and CT/MRI showed no tumor was recurrenced.

Conclusions: Permanent iodine-125 strip implantation in the orbit can be used as an alternative eye-sparing surgery for malignant lacrimal gland tumors after tumor excision. It can control tumor recurrence and maintenance of vision and good cosmesis.

Keywords: lacrimal gland carcinoma, iodine-125 seeds, brachytherapy

Background

Primary lacrimal gland carcinoma are rare, including adenoid cystic carcinoma (ACC), pleomorphic adenocarcinoma, and denovo adenocarcinoma (ACA), ACC accounts for 60% of lacrimal gland malignant tumors. Its malignant degree is high, and it is easy to relapse, bony invasion, late metastasis and even death after operation [1-3]. Regardless of the any topical treatment, the estimated 5-year mortality rate is 50% [2,4].

About 80% of the patients have varying degrees of bone invasion [5], Orbital exenteration is the traditional surgical treatment, sometimes with removal of the involved bony walls if necessary [6], and followed by radiotherapy after operation. More recently, the application of various new techniques have changed the mode of diagnosis and treatment of adenoid cystic carcinoma of the lacrimal gland. Eye-sparing surgery combined with adjuvant radiation therapy or chemotherapy have been more and more popular in treatment of malignant lacrimal gland tumors.

Various types of radiation therapy are recommended, including external-beam radiation therapy, brachytherapy and proton therapy [6,8]. Interstitial brachytherapy is widely used in prostate cancer, meningioma, pancreas and some orbital tumors [8-11]. Include ciliochoroidal melanoma, retinoblastoma, malignant lacrimal sac tumours and so on [12,13]. But only one article has reported the effects of iodine-125 (I-125) plaque brachytherapy in the treatment of ACC [14]. In this study, 9 patients underwent tumor excision, and all were treated with radioactive I-125 seed implantation 1 month later. Visual function (eg. fundus photography, fluorescein

angiography, optical coherence tomography), local recurrence, distant metastases, and survival were assessed to evaluate the effects of I-125 seed treatment of lacrimal gland carcinoma.

Patients and methods

Patients

9 patients with malignant lacrimal gland tumor who had undergone eye sparing surgery first and then received I-125 seeds brachytherapy between May 2017 to May 2020 at the Tangdu Hospital of the Air Force Military Medical University were retrospectively reviewed. 5 were male and 4 were female. The age of the patients ranged from 33.0 to 72.0 years, with a median of 54.3 years. This study adhered to the tenets of the Declaration of Helsinki and was approved by the Air Force Military Medical University research ethics committee. (Xi'an, China) (No. 20170806). Informed consents and photographs in verbal form was obtained from all patients at the follow-up visit.

Materials

The I-125 radioactive particles were obtained from Tianjin Saide Medicine Co. Ltd. (Tianjin, China). The parameters of the I-125 seeds: a sealed source for radionuclides, cylinder, activity was 0.6–0.8 mCi; volume was 4.5 mm × ⌀ 0.8 mm; energy was 27–35 keV γ source; half-value layer 0.025 mm lead; tissue penetration 1.7 cm; half-life 59.6 days; and source radiation activity 11.1–37.0 MBq. Titanium alloy covered all seeds surface.

Surgical treatments

Hematologic examination was underwent for all patients, orbital computed tomography (CT) and magnetic resonance imaging (MRI) were performed before the first operation. Ultrasonography of abdominal and neck lymph nodes ruled out multiple organ involvement (kidneys, pancreas, retroperitoneum). Eye-sparing surgery was performed with standard general anesthesia. The tumor and invaded bone were resected carefully and completely during the operation.

After the pathology was confirmed, the 4 earliest patients were assessed, and the seeds were inserted into the orbital tissue directly. In the other patients, the I-125 strips were implanted in the subperiosteum near the tumor. I-125 seeds were loaded in PICC tubes (PICC: peripherally inserted central catheter) as radioactive treatment strip. I-125 strips need processing to prevent particles from falling out. That makes easier to remove the implant in the future, if necessary.

The activity and numbers of the I-125 particles intended to be implanted depend on tumor size. It was calculated using the following formula in our early article [9]: seed number = (tumor length + width + height)/3 × 5/a mCi (a=0.6~0.8). All patients in this study didn't received any other treatment after the operation.

The classification for LGACC was according to the 8th AJCC stage. Follow up patients for eye examinations (vision, fundus photography, OCT FFA). Local recurrence and distant metastasis were confirmed by MRI ,CT scanning and ultrasonography during the following time. The follow-up period range was 7-43 months (average, 29 months).

Results

Patient characteristics

The histologic subtypes of tumors in all patients was assessed. The histologic diagnoses were as follows: 5 patients had ACC, and 4 patients had de novo ACA. The clinical information of patients is summarized in Table 1.

Case No.	Age (years)/Gender/ Affected side	Path	8th AJCC stage	Corrected vision	PNI	Number of I-125 seeds	Strength (mCi)	TTF from implant (month)	Current corrected vision	Outcome
1	72/M/L	ACA	T2bNxMx	0.2	-	20	0.6	43	Lost visit	
2	54/F/R	ACC	T2cN0 M0	0.6	+	20	0.6	41	0.6	LR,AWD
3	63/F/L	ACC	T2cN0 M0	NLP	+	20	0.6	39	NLP	NED
4	33/F/L	ACC	T3cN0 M0	1.2	-	30	0.7	37	NLP	NED
5	59/M/R	ACA	T2aN0 M0	1.0	-	18	0.7	35	0.9	NED
6	48/F/R	ACA	T2cN0 M0	1.2	-	24	0.7	23	1.0	NED
7	48/F/L	ACC	T3cN0 M0	1.0	+	32	0.7	21	1.0	NED
8	56/M/L	ACC	T3cN0 M0	0.6	-	39	0.8	15	0.6	NED
9	65/M/R	ACA	T3bN0 M0	0.5	+	24	0.8	7	0.5	NED

Table 1. Clinical information of patients

ACC adenoid cystic carcinoma, ACA adenocarcinoma, F female, M male, PNI perineural invasion, TTF time to follow-up, LR local recurrence, Met distant metastases, LN lymph node, AWD alive with metastatic disease, NED no evidence of disease,

Visual function

Except for the earliest patient, one patient was lost to follow-up. All other patients were followed for 29 months medially. The vision of the fourth patient was lost intermittently 1 year later and finally lost. The vision, FFA, OCT and fundus photography results of all other patients did not change (Fig. 1). No radiation cataracts, glaucoma or diplopia occurred. All patients had slight xerophthalmia and recovered with artificial tears. They all had good cosmesis.

Tumor

At 1, 3, 6, and 12 months after the operation, CT/MRI/PET-MRI of the operated

orbit was performed and then every 6 months thereafter. The tumor of the second patient recurred in the subcutaneous tissue of the orbit 2 years later, but without distant metastases. Then, surgery and I-125 seeds implantation were performed in the orbit once more. External radiotherapy (ER) for the subcutaneous tumor lasted 20 days, and the target dose was 30 Gy. MRI showed no recurrence sign until now, and vision was still 60/100 (Fig. 2). All CT/MRI scans of the other 6 patients did not show local tumor recurrence. The lymph nodes in the neck did not show swelling on ultrasonography.

Discussion

Despite active local treatment, ACC is invasive and the prognosis is poor, partly due to early perineural spread (approximately 75% of cases) and bony involvement. [14,15]. The rates of local and regional recurrences and late distant metastases in patients with ACC are high, and 50% of patients die of the disease even with modern treatments [16,17]. For lacrimal gland carcinoma, the expectation of treatment is to locally control regeneration and prevent distant metastasis. Tumor tissue can often infiltrate the orbital soft tissue because the tumor lacks a true capsule [14]. Orbital exenteration has been the most common method for the treatment of lacrimal gland malignant tumors. If bone is involved, it should be removed at the same time. However, Woo KI et al. showed that extensive surgery does not decrease the risk of distant metastasis and does not seem to improve survival [4]. Many patients are young and have good vision in the ipsilateral eye. Therefore, eye-sparing surgery for lacrimal gland malignant tumors has been advocated. Radiation therapy after surgery

may be a reasonable option.

Radiation therapy includes external-beam radiation therapy, proton therapy, and brachytherapy. ER may produce several side-effects on ocular and periocular structures, like substantial visual loss, including glaucoma, dry eyes, cataracts, radiation retinopathy, and so on [18,19,20]. Proton therapy is too expensive for patients in developing countries. Therefore, brachytherapy is a better option and was chosen in our treatment.

I-125 is a common radioactive therapy used in some kinds of unresectable solid tumors. At the same time, I-125 plaques was also used in some ocular tumors and orbital rhabdomyosarcoma. We also reported articles for the treatment of lacrimal sac malignant tumors [9]. However, there is only one article about the role of interstitial brachytherapy in the treatment of LGACC. Shields et al. used I-125 plaques with a target dose of 50 Gy for brachytherapy on 4 patients with microscopic residual tumors after excision. Treatment effect display tumor was well controlled in 3 of 4 patients, while one patient needs further surgery to remove recurring tissue [14]. In contrast to impermanent I-125 plaque radiotherapy, we put the I-125 seeds into the PICC tubes as radioactive treatment strip and implanted them under the orbital periosteum permanently. On the one hand, it ensured that all residual tumor cells were treated. On the other hand, the seeds were away from the eyeball and ensured that vision was stable.

In the process of exploring the method of seed implantation, the seeds were implanted into the orbital tissue directly in the 4 earliest patients. The fourth

patient’s vision was lost intermittently because the seeds moved to the optic nerve and thus caused vision loss 1 year later. Therefore, I-125 seed strips under the periosteum were used in the subsequent 5 patients, and vision was stable in these patients (Fig. 3). After 6 months, the seed strips could be whether took out or implanted again according the patient's condition.

The ACC tumor of the second patient recurred in and out of the orbit 2 years later, which was related to the smaller seed number and activity in the first operation. The patient received tumor excision and I-125 seed implantation once more. The out of orbit tumor was treated with ER. The vision was kept at 60/100, and the tumor had no recurrence during the follow-up time.

Pain is often suggestive of malignant lacrimal gland lesions, including ACC and ACA, and may be secondary to bone or orbital nerve involvement [21]. All patients had no pain after the operation, which may be related to subperiosteal implantation of the I-125 seeds. In this study, 6 (65%) patients had xerophthalmia in the ipsilateral eye. It is possible that radiotherapy have some effects on the eyes. All of them recovered with artificial tears.

In recruited patients with lacrimal gland carcinoma, the use of I-125 seeds radiotherapy combined with eye-sparing surgery has a good control of the tumor, while maintaining visual function, and the radiation-induced ocular toxicity is minimal. Early diagnosis and safer and more effective treatment have greatly improved the prognosis, but long-term follow-up is especially necessary for patients with lacrimal gland carcinoma. Therefore, although this new radiotherapy for

lacrimal gland carcinoma (such as adjuvant or primary therapy) have many advantages, long-term follow-up is still required to determine late recurrence, distant metastasis and survival rates.

Conclusions

Malignant tumors of the lacrimal gland are rare and not sensitive to radiotherapy and chemotherapy. Local radiotherapy after eye-sparing surgery can prevent tumor recurrence. I-125 interstitial brachytherapy can provide good visual acuity and cosmesis for patients, it may be a new eye-sparing method for lacrimal gland carcinomas after tumor excision.

Abbreviations

ACC: adenoid cystic carcinoma ; ACA: adenocarcinoma; CT: Computed tomography; MRI: Magnetic resonance imaging; ER:external radiotherapy, PET-MRI: positron emission tomography-MRI

Ethics approval and consent to participate

This study was approved by the Institutiona Ethics Committee for National Durg Clinical Trials, Tangdu Hospita, Fourth Military Medical Uniersity (NO. 20170806) . Written informed consent was obtained from all patients.

Consent for publication

Written informed consent was obtained from all patients for publication of this artical and any accompanying images. A copy of the written consent form is available for review from the Editor of this journal.

Availability of data and materials

The data of this study can be obtained from the corresponding author upon reasonable request.

Competing interests

The authors declare that they have no competing interests.

Funding

No funding was obtained for this article

Authors' contributions

PW and SBZ drafted the manuscript; YJL was responsible for acquisition of the clinical information and reviewing the manuscript; and NXN, CJG，ZQ,CQL prepared figures 1-3. All authors reviewed the manuscript

Acknowledgements

We thank the Department of Pathology and Department of Radiology at Tangdu Hospital of Air Force Military Medical University, Xi'an, Shaanxi Province, China.

Authors' information

[1]Department of Ophthalmology, Tangdu Hospital, Air Force Military Medical University, Xi'an, Shaanxi

References

1.Shields JA, Shields CL, Epstein JA, Scartozzi R, Eagle Jr RC. Review: primary epithelial malignancies of the lacrimal gland: the 2003 Ramon L. Font lecture. Ophthalmic Plast Reconstr Surg 2004, 20(1):10-21.

2.Woo KI,Yeom A,Esmaeli B. Management of Lacrimal Gland Carcinoma: Lessons From the Literature in the Past 40 Years, Ophthalmic Plast Reconstr Surg,. Jan-Feb 2016;32(1):1-10.

3.Bernardini FP, Devoto MH, Croxatto JO. Epithelial tumors of the lacrimal gland: an update. Curr Opin Ophthalmol,2008,19(5):409-413.

4.Woo KI, Kim YD, Sa HS, Esmaeli B, Current treatment oF lzcrimaal gland carcinoma.Curr Opin Ophthalmol .2016;27(5):449-56.

5. Rootman J, White VA, Changes in the 7 th edition of the AJCC TNM classification and recommendations for pathologicanalysis of lacrimal gland tumors. Arch Pathol Lab Med 2009,133(8):1268-1271.

6.Esmaeli B, Golio D, Kies M, DeMonte F. Surgical management of locally advanced adenoid cystic carcinoma of the lacrimal gland. Ophthal Plast Reconstr Surg 2006; 22:366-370.

7.Tse DT, Kossler AL, Feuer WJ, Benedetto PW. Long-term outcomes of neoadjuvant intra-arterial cytoreductive chemotherapy for lacrimal gland adenoid cystic carcinoma. Ophthalmology 2013; 120:1313-23.

8. Kumar PP, Good RR, Patil AA, Leibrock LG. Permanent high activity iodine-125 in the management of petroclival menin giomas: case reports. Neurosurgery. 1989;25:436–41. Discussion 441–442.

9. Marcu L, Quach K. The role of post-implant dosimetry in the quality assessment of prostate implants. The RAH experience. Australas Phys Eng Sci Med. 2006;29:310–4.

10. Peretz T, Nori D, Hilaris B, Manolatos S, Linares L, Harrison L, et al. Treatment of primary unresectable carcinoma of the pancreas with I-125 implantation. Int J Radiat Oncol Biol Phys. 1989;17: 931–5.

11. Stannard C, Sauerwein W, Maree G, Lecuona K. Radiotherapy for ocular tumours. Eye. 2013;27:119–27

12. Spraul CW, Lim JI, Lambert SR, Grossniklaus HE. Retinoblastoma recurrence after iodine 125 plaque application. Retina. 1996;16:135–8.

13.Ping Wang, Nan Ma, Shaobo Zhang, Xiaona Ning, Chenjun Guo, Qiong Zhang, Qilin Cheng, Yangjun Li, Iodine-125 interstitial brachytherapy for malignant lacrimal sac tumours: an innovative technique. Eye(Lond), 2020.Jun 16. doi:10.1038/s41433-020-1098-3.

14.Shields JA, Shields CL, Freire JE, Brady LW, Komarnicky L. Plaque radiotherapy for selected orbital malignancies: preliminary observations: the 2002 Montgomery Lecture, part 2. Ophthal Plast Reconstr Surg. 2003; 19:91-5.

15. Klufas MA, Wolden SL, Bohle GC, Wexler LH, Abramson DH. Exenteration and custom implant brachytherapy as a treatment for recurrent primary extraskeletal orbital ewing sarcoma. Ophthalmic Plast Reconstr Surg. 2015;31:e89-91.

16. Amoaku WM, Archer DB. Fluorescein angiographic features, natural course and treatment of radiation retinopathy. Eye. 1990;4 (Part 5):657-67.

17. Brown GC, Shields JA, Sanborn G, Augsburger JJ, Savino PJ, Schatz NJ. Radiation retinopathy. Ophthalmology. 1982;89:1494-501.

18. Grange JD. Radiation-induced retinopathy. J Fr Ophtalmol. 2001; 24:993-1003.

19. Krema H, Xu W, Payne D, Vasquez LM, Pavlin CJ, Simpson R. Factors predictive of radiation retinopathy post (125)Iodine brachytherapy for uveal melanoma. Can J Ophthalmol. 2011;46:158-63.

20. Lumbroso L, Dendale R, Fourquet A, Desjardins L. Radiation induced retinopathy. Cancer Radiother. 2002;6:289-95.

21. Gündüz AK, Yeşiltaş YS, Shields CL , Overview of benign and malignant lacrimal gland tumors ,Curr Opin Ophthalmol, 2018;29(5):458-68.

Figure Legends

Figure 1

MRI showed high intensity on T1-weighted of LGACC in July 2017 before left eye-sparing surgery (a, axial). MRI showed no tumor recurrence after I-125 seed implantation 37 months later (b, axial; c, coronal). The vision and FFA were normal (d).

Figure 2

MRI of Case 2 (July 2017), who had adenoid cystic carcinoma of the lacrimal gland in the right eye before surgical resection, showed high intensity (a,b). MRI of Case 2 after seed implantation. Coronal CT (c) scans showed that the I-125 seeds were stable, and MRI (d) showed no tumor recurrence 1 year later. (September 2018). CT and MRI showed that the ACC recurred after 2 years (e,f). The tumor was resected, and I-125 stirps were implanted once more in July 2019. MRI scan showed the tumor was inactive and stable until now (August 2020) (g, h).

Figure 3

Two methods of I-125 seed implantation. The seeds were implanted into the orbital tissue directly, but the seeds moved to the optic nerve and thus caused vision loss 1 year later (a, b: arrow: the I-125 seeds). I-125 seed strips were stable under the periosteum of the orbit, and vision was not changed (c, d: arrow: the I-125 seed strips).

Figures

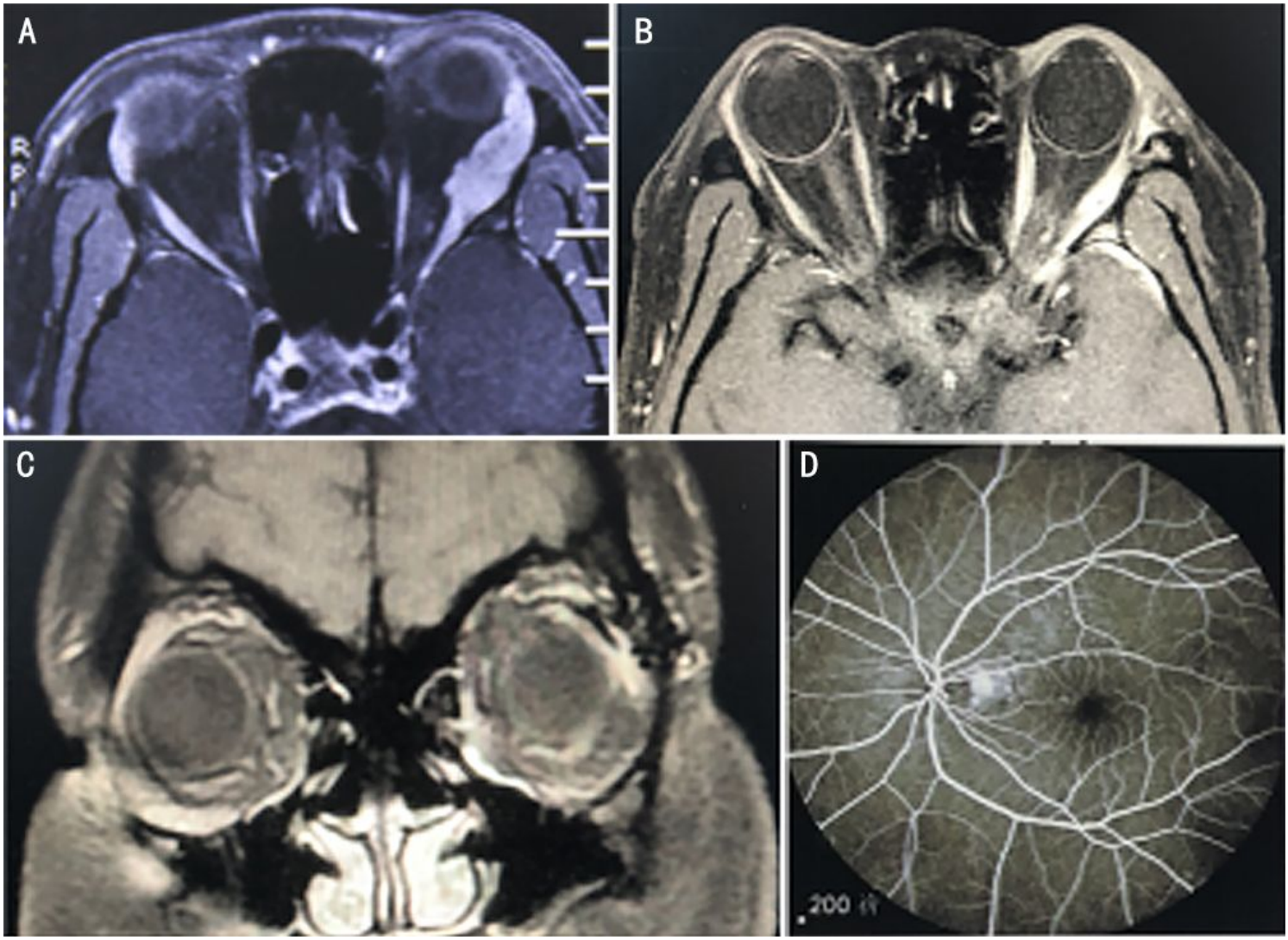

Figure 1

MRI showed high intensity on T1 weighted of LGACC in July 2017 before left eye sparing surgery (a, axial). MRI showed no tumor recurrence after I 125 seed implantation 37 months later (b, ax ial; c, coronal). The vision and FFA were normal (d).

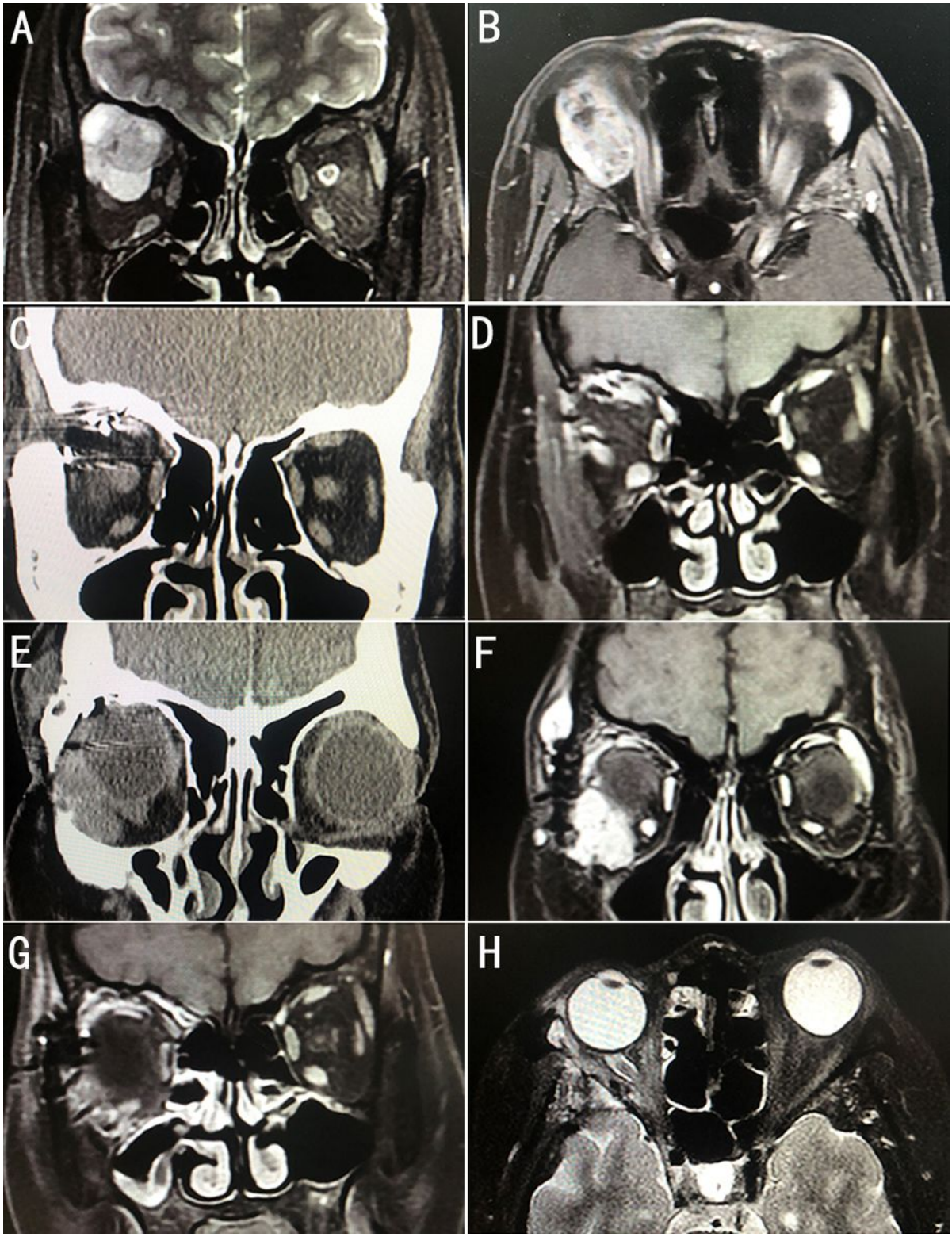

Figure 2

MRI of Case 2 (July 2017), who had adenoid cystic carcinoma of the lacrimal gland in the right eye before surgical resection, showed high intensity (a,b). MRI of Case 2 after seed implantation Coronal CT (c) scans showed that the I 125 seeds were stable, and MRI (d) showed no tumor recurrence 1 year later. (September 2018). CT and MRI showed that the ACC recurred after 2 years (e,f). The tumor was resected

and I 125 stirps were implanted once more in July 20 19 . MRI scan showed t he tumor was inactive and stable until now (August 2020) g, h).

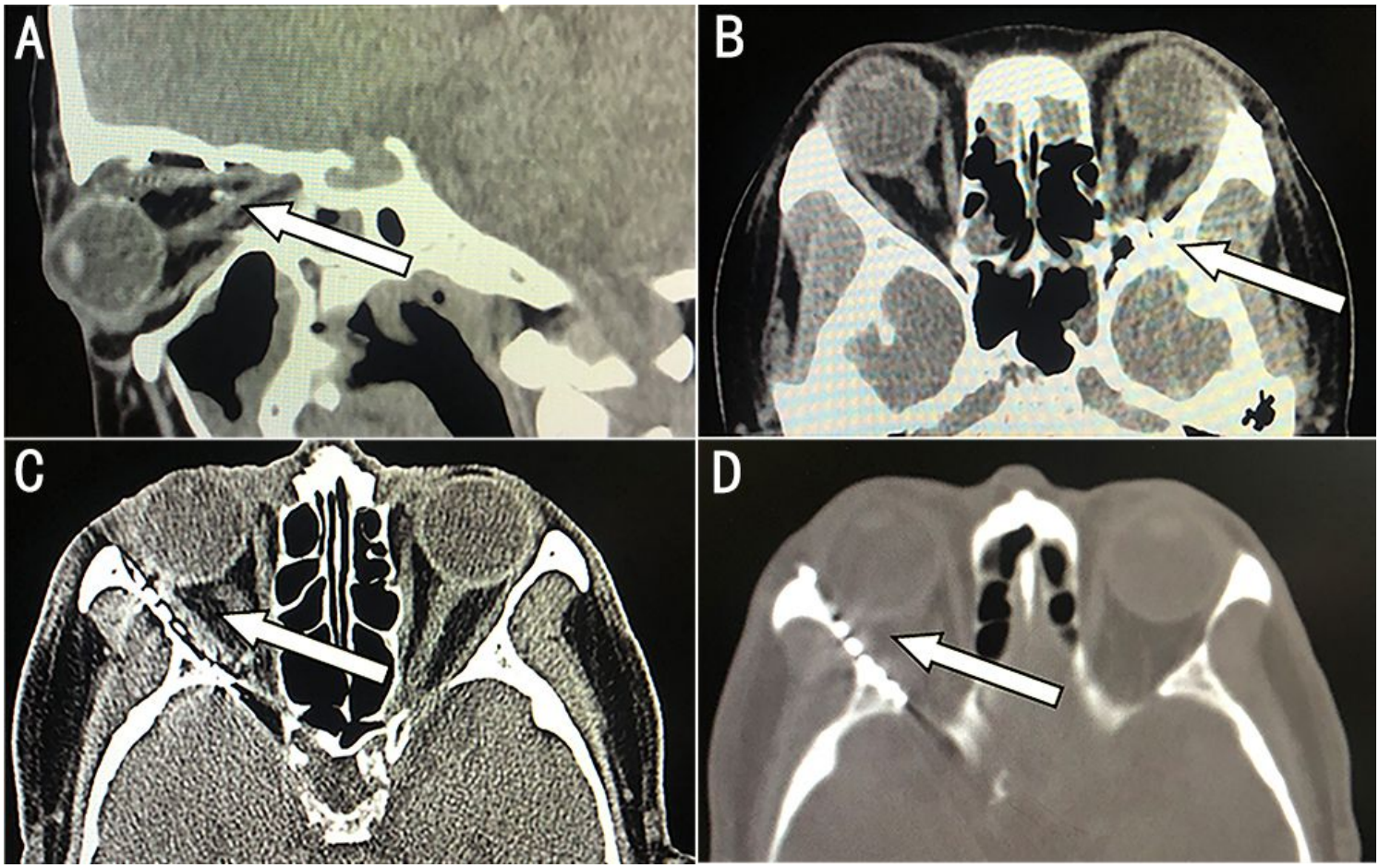

Figure 3

Two methods of I 125 seed implantation. The seeds were implanted into the orbital tissue directly, but the seeds moved to the optic nerve and thus caused vision loss 1 year later (a, b: arrow: the I 125 seeds). I 125 seed strips were stable under the periosteum of the orbit, and vision was not changed (c, d: arrow: the I 125 seed strips).