Amphistomiasis due to Explanatum explanatum (Digenea) in native cattle of Kerman Province, Iran

Mehdi Borhani Zarandi (m.borhani1363@yahoo.com)

State Key Laboratory for Zoonotic Diseases, Key Laboratory of Zoonosis Research, Ministry of Education, Institute of Zoonosis, College of Veterinary Medicine, Jilin University, Changchun 130062, China

Ashkan Faridi

Research Center for Hydatid Disease in Iran, Kerman University of Medical Sciences, Kerman, Iran.

Ali Halajian

Department of Biodiversity, University of Limpopo, Sovenga, South Africa.

Elham Moghaddas

Department of Parasitology and Mycology, Faculty of Medicine, Mashhad University of Medical Sciences, Mashhad, Iran.

Amin Ahmadi

Department of Basic Sciences, Faculty of Veterinary Medicine, Ardakan University, P.O. Box 184, Ardakan, Iran.

Research Article

Keywords: Amphistomiasis, Explanatum Explanatum, Iran, Kerman Province, Scanning Electron Microscopy, SEM

Posted Date: April 15th, 2022

DOI: https://doi.org/10.21203/rs.3.rs-1543069/v1

Abstract

Amphistomiasis is caused by different species of trematodes in the family paramphistomatidae and is one of the neglected parasitic diseases of livestock. Amphistomiasis has a wide geographic distribution, especially in subtropical and tropical regions. Although adult stage of most of the amphistomes are seen in the rumen and reticulum of ruminants, but sometimes can be seen in bile ducts too. A few parasites were collected from the bile ducts of a native cattle from the Kerman slaughterhouse, Kerman Province, southeastern Iran, and samples were studied by histomorphological as well as, Scanning Electron Microscopy. The worms were identified as *Explanatum explanatum* using identification keys and SEM. This trematode has been identified in livestock from only two other provinces of Iran but this is the first report of it in Kerman Province. Specific epidemiological studies with exact slaughter inspections are needed to recognize the extent of the parasite prevalence in native animals of Iran.

Introduction

Amphistomiasis is caused by different species of the family paramphistomatidae (Trematoda: Paramphistomidae).It is one of the neglected parasitic disease of domestic and wild ruminants, which has a wide geographic distribution, especially in subtropical and tropical regions (Arias et al., 2011; Monrad et al., 2005). Generally, adult stage is nonpathogenic for host, but immature stages and their migration in anterior small intestinal mucosa can cause severe pathogenesis. Symptoms such as enteritis, haemorrhage, anorexia, polydipsia, unthriftiness, severe diarrhea, and even mortality (Horak, 1971; Pfukenyi and Mukaratirwa, 2018). In addition weight loss and reduction in animal production and subsequent economic loss have been observed due to amphistomiasis, but in general the importance of these parasites has been neglected (Lotfy et al., 2010). Although adult stage of most of the amphistomes are seen in the rumen and reticulum of wild and domestic ruminants, but in some cases such as *Explanatum explanatum* the adult stage exists in bile ducts (Smith and Sherman, 2009). This species has been reported in different parts of the world (Smith and Sherman, 2009). Although infection with *Explanatum* has been reported from neighboring countries, i.e. Iraq and Afghanistan (Kadhim et al., 1970; Kotrlá et al., 1976) but there is not much information about its epidemiology in Iran.

Different amphistomids have been reported in Iran, including *Paramphistomum, Calicophoron, Gastrothylax, Cotylophoron, Carmyerius* and *Orthocoelium. E. explanatum* has only been reported in buffalo in southern part of Iran (Khuzestan Province) (Otto and Eslami, 1980), cattle and sheep of central Iran (Shiraz) (Rajabloo et al. 2014) and cattle of Zabol, southeast Iran (Arfaa, 1962; Bagheri, 1962; Coskun et al., 2012; Khedri et al., 2015; Mazahery et al., 1994) however limited data are available on this species from other parts of the country. The purpose of the present study was to investigate the presence of this parasite in Kerman province, southern Iran.

In different studies Scanning Electron Microscope (SEM) has been used to study the surface topography of tegument of a number of species in the family paramphistomatidae (Anuracpreeda et al., 2015, 2012; Lenis et al., 2018; Panyarachun et al., 2010; Sanger et al., 2017). However, there is not such study on the

genus *Explanatum* so we decided to use a few of the collected samples for gross microscopic, histomorphological evaluation as well as, and SEM.

Materials And Methods

The parasites were collected from the bile ducts of a native cattle from the Kerman slaughterhouse, Kerman Province, southeastern Iran (30.2907°N 57.0679°E). Recovered amphistomes were rinsed in saline, fixed and preserved in 70% ethanol. Later specimens were transferred to the Research Center for Hydatid Disease (Kerman University of Medical Sciences, Kerman, Iran). Some of the worms were used for morphological study and the rest for SEM study. For morphology, specimens were stained with Carmine and mounted in Canada balsam. Measurements of morphological features were made with an optical microscope using a calibrated ocular micrometer (OLYMPUS CX31). For SEM study, samples were fixed in a 2. 5% glutaraldehyde in a 0.1 M sodium cacodylate buffer. Then, they were fixed in a 2.5% glutaraldehyde solution and 0.1 M phosphate buffer solution (pH 7.2) that was prepared from NaH2PO4 H2O and Na2HPO4 (anhydrous) salts for 24 h (Bozzola and Russell, 1999). After washing with phosphate buffer solution (PBS 0.1 M), the trematodes were dehydrated in a graded ethanol series, dried in a critical-point dryer (SANDRI-780A), and coated with gold for 10 min in an ionizer (Ion Sputter JFC-1100, Jeol, Fine Coat). Coated worms were observed under the SEM (TESCAN MIRA3 LM, Czech Republic) to check for the surface morphology at an accelerating voltage of 10 kV. For histomorphological study, the specimens were fixed in formalin %10, then paraffin blocks were made and were serially sectioned at 2 µm in thickness using microtome (AUTOTECHNICON MONO, MOD. 2A &MICROTEC). These slides were stained by haematoxylin and eosin, and finally slides were examined and photographed by light microscope (OLYMPUS CX41).

Results

During veterinary inspection of cattle in Kerman municipal abattoir, 15 white ventrally curved helminths were found in the bile ducts of a native cattle. The helminths were attached to epithelia by mean of their acetabulum and there was some gross damage on attachment site. Gross microscopic studies showed characters like absence of an oral sucker, acetabulum enormous and subterminal and ventral 4-4.3 mm in external diameter in dorso-ventral direction, large body, pyriform to conical, tapering anteriorly, broad and rounded posteriorly, curved ventrally, 8.7–12 mm long; and net weight was 0.4–0.6 gr (Fig. 1), and thus based on these characters, the amphistomes were associated with Paramphistominae subfamily.

Further confirmation was provided by cross section of the sample as shown in Fig. 3. In the section, observations were as well-developed pharynx, testis position, absence of esophageal bulb and sphincter, vitelline follicles in lateral sides, absence of genital sucker, ventral genital pore in midline, all confirming the identification as *E. explanatum*.

In search for the potential intermediate hosts (IH) for this parasite, we found the shells of snails Family Planorbidae and Lymnaeidae in Kerman (Fig. 4).

Discussion

In the present study, we identified the amphistomes collected from native cattle in Kerman slaughterhouse, Iran. Further analysis proved that all these parasites were *E. explanatum*. *Explanatum* species have acetabulum, pharynx and ventral genitalium, body has 7.86–14.30 mm long and acetabulum 3.50–4.82 mm in external diameter (Eduardo, 1984). The measurements of our samples were consistent with the records in mentioned reference.

Family Paramphistomidae Fischoeder, 1901 has 19 genera and 70 species (Jones et al., 2005), one of these is *Explanatum*. This parasite is mostly found in the bile ducts and intrahepatic ducts and can cause granulomatous reactions together with fibrosis and thickening of the bile ducts that is capable of imposing direct and indirect economic damages. Although it is a common parasite in buffaloes in India, Africa, Asia, and the Caribbeans (Haque et al., 2011), but little information is available in terms of its epidemiology and extent of economic importance. The life cycle of this parasite is not much clear, specifically in Iran. Although we know freshwater snails of the family Lymnaeidae and Planorbidae are proposed as IH of the paramphistomatidae (Paiva, 1994; Santos et al., 1986), but which exactly is involved in distribution of parasite in Iran is unclear. Although we accidentally found the snail shells of two mentioned families during this study and this can introduce them as potential intermediate hosts, but proving this needs an extensive sampling and in vitro tests to find the intermediate stages. Previous studies report the Planorbidae and Lymnaeidae snails in Kerman (GenBank accession numbers: KT267211.1, KT280457.1, KT365877.1, KT280430.1, KT280429.1), but unfortunately, there are no more epidemiological studies in this area.

Although *E. explanatum* was first reported in Iran in 1980, but they were collected from cattle imported from Afghanistan, Pakistan or India (Otto and Eslami, 1980). In the later stage this parasite was reported in indigenous buffaloes in southwest Iran (Mazahery et al., 1994), sheep and cattle with unknown origin in Shiraz slaughterhouse (Rajabloo et al., 2014) and cattle with unknown origin in Zabol, southeast Iran (Khedri et al., 2015). As livestock is imported to Iran from different sources, if *E. explanatum* is really part of Iran fauna or the reports are with abroad (alien) origin needs further works, specially looking at intermediate hosts and checking the source of slaughtered animals more carefully. As this parasite has never been reported in Kerman Province and there is a possibility of introduction of this parasite through imported cattle, precise inspections of slaughtered animals and awareness of related authorities are required for clarifications. It should be noted that the unlawful transfer of livestock from Iran's neighboring countries may have played a role in this occurrence. However, a comprehensive study of native cattle and potential intermediate hosts may provide more insight into the occurrence of this parasite and potential life cycle of it. Such information may help the veterinarians for better control of this parasite.

Declarations

Acknowledgement: We would like to thank the Research Center for Hydatid Disease in Iran for supporting the study.

Funding:

None

Conflicts of interest:

The authors of the present work declare no conflict of interest.

Ethical approval:

Not required

References

1. Anuracpreeda, P., Panyarachun, B., Ngamniyom, A., Tinikul, Y., Chotwiwatthanakun, C., Poljaroen, J., Sobhon, P., 2012. Fischoederius cobboldi: A scanning electron microscopy investigation of surface morphology of adult rumen fluke. Exp. Parasitol. 130, 400–407. https://doi.org/10.1016/j.exppara.2012.02.001
2. Anuracpreeda, P., Phutong, S., Ngamniyom, A., Panyarachun, B., Sobhon, P., 2015. Surface topography and ultrastructural architecture of the tegument of adult Carmyerius spatiosus Brandes, 1898. Acta Trop. 143, 18–28. https://doi.org/10.1016/j.actatropica.2014.12.003
3. Arfaa, F., 1962. A study of Paramphistomum microbothrium in Khuzistan S.-W. Iran. Ann. Parasitol. Hum. Comp. 37, 549–555.
4. Arias, M., Lomba, C., Dacal, V., Vázquez, L., Pedreira, J., Francisco, I., Piñeiro, P., Cazapal-Monteiro, C., Suárez, J.L., Díez-Baños, P., 2011. Prevalence of mixed trematode infections in an abattoir receiving cattle from northern Portugal and north-west Spain. Vet. Rec. vetrecd85. https://doi.org/10.1136/vr.d85
5. Bagheri, H.A., 1962. Study on the species of paramphistomumes of cattle in slaughterhouse of Tehran. DVM Diss. Fac. Vet. Med. Univ. Tehran 1–45.
6. Bozzola, J.J., Russell, L.D., 1999. Electron microscopy: principles and techniques for biologists. Jones & Bartlett Learning.
7. Coskun, S.Z., Eslami, A., Halajian, A., Nikpey, A., 2012. Amphistome species in cattle in South coast of Caspian Sea. Iran. J. Parasitol. 7, 32–35.
8. Eduardo, S.L., 1984. The taxonomy of the family Paramphistomidae Fischoeder, 1901 with special reference to the morphology of species occurring in ruminants IV. Revision of the genusGigantocotyle Näsmark, 1937 and elevation of the subgenusExplanatum Fukui, 1929 to full generi. Syst. Parasitol. 6, 3–32. https://doi.org/10.1007/BF00010983

9. Haque, M., Mohan, C., Ahmad, I., 2011. Natural trematode infection in liver of water buffalo (Bubalus bubalis): histopathological investigation. J. Parasit. Dis. 35, 50–53. https://doi.org/10.1007/s12639-011-0022-y
10. Horak, I.G., 1971. Paramphistomiasis of domestic ruminants, in: Advances in Parasitology. Elsevier, pp. 33–72. https://doi.org/10.1016/s0065-308x(08)60159-1
11. Jones, A., Jones, A., Bray, R.A., Gibson, D.I., 2005. Superfamily Paramphistomoidea Fischoeder, 1901. https://doi.org/10.1079/9780851995878.0221
12. Kadhim, J.K., Altaif, K.I., Hawa, N.J., 1970. The occurrence of paramphistomes in ruminants in Iraq, with a description of Gigantocotyle explanatum in cattle and buffaloes. Bull. Endem. Dis. (Baghdad). 12, 109–111.
13. Khedri, J., Radfar, M.H., Borji, H., Mirzaei, M., 2015. Prevalence and intensity of Paramphistomum spp. in cattle from South-Eastern Iran. Iran. J. Parasitol. 10, 268–272.
14. Kotrlá, B., Blazek, K., Amin, A., 1976. Trematodes of domestic ruminants of Afghanistan and their role in pathology. Folia Parasitol. (Praha). 23, 217–220.
15. Lenis, C., Galiano, A., Vélez, I., Vélez, I.D., Muskus, C., Marcilla, A., 2018. Morphological and molecular characterization of Paragonimus caliensis Little, 1968 (Trematoda: Paragonimidae) from Medellin and Pichinde, Colombia. Acta Trop. 183, 95–102. https://doi.org/10.1016/j.actatropica.2018.03.024
16. Lotfy, W.M., Brant, S. V, Ashmawy, K.I., Devkota, R., Mkoji, G.M., Loker, E.S., 2010. A molecular approach for identification of paramphistomes from Africa and Asia. Vet. Parasitol. 174, 234–240. https://doi.org/10.1016/j.vetpar.2010.08.027
17. Mazahery, Y., Razmyar, J., Hoghooghi-Rad, N., 1994. Explanatum explanatum (Creplin, 1847) Fukui, 1929, in buffaloes in the Ahwaz area, southwest Iran. Vet. Parasitol. 55, 149–153. https://doi.org/10.1016/0304-4017(94)90066-3
18. Monrad, J., Mukaratirwa, S., Pfukenyi, D.M., Willingham, A.L., 2005. Epidemiological studies of amphistome infections in cattle in the highveld and lowveld communal grazing areas of Zimbabwe. Onderstepoort J. Vet. Res. 72, 67–86.
19. Otto, S., Eslami, A., 1980. Review of amphistomes (Trematoda, paramphistomata) of Iranian domestic ruminants. Parasitol. Hung 14, 61–65.
20. Paiva, N., 1994. Epidemiología y control de Paramphistomum en Uruguay. Enfermedades Parasit. Importancia Económica en Bov. Hemisferio Sur, Montevideo Uruguay 257–264.
21. Panyarachun, B., Sobhon, P., Tinikul, Y., Chotwiwatthanakun, C., Anupunpisit, V., Anuracpreeda, P., 2010. Paramphistomum cervi: surface topography of the tegument of adult fluke. Exp. Parasitol. 125, 95–99. https://doi.org/10.1016/j.exppara.2009.12.020
22. Pfukenyi, D.M., Mukaratirwa, S., 2018. Amphistome infections in domestic and wild ruminants in East and Southern Africa: A review. Onderstepoort J. Vet. Res. 85, 1–13. https://doi.org/10.4102/ojvr.v85i1.1584
23. Rajabloo, M., Namazi, F., Shayegh, H., Alavi, A.M., 2014. Explanatum explanatum: an emerging liver fluke in cattle and sheep. Online J. Vet. Res. 18, 675–679.

24. Sanger, B., Swarnakar, G., Roat, K., 2017. Ultrastructural observations of rumen immature and mature Paramphistomum cervi (Trematoda: Digenea) in domestic buffalo of Udaipur district, Rajasthan. Int. J. Zool. Stud. 2, 63–69.
25. Santos, I.C.S., Laranja, R.J., Martins, J.R., Cereser, V.H., 1986. Intermediate host of Paramphistomum (Fischoeder, 1901) Biomphalaria Tenagophila (Orbigny, 1935), Guaiba, Rio Grande do Sul, Brazil. Bol. do Inst. Pesqui. Vet. Desiderio Finamor.
26. Smith, M.C., Sherman, D.C., 2009. Goat medicine, Waverly Company, Philadelphia. John Wiley \& Sons.

Figures

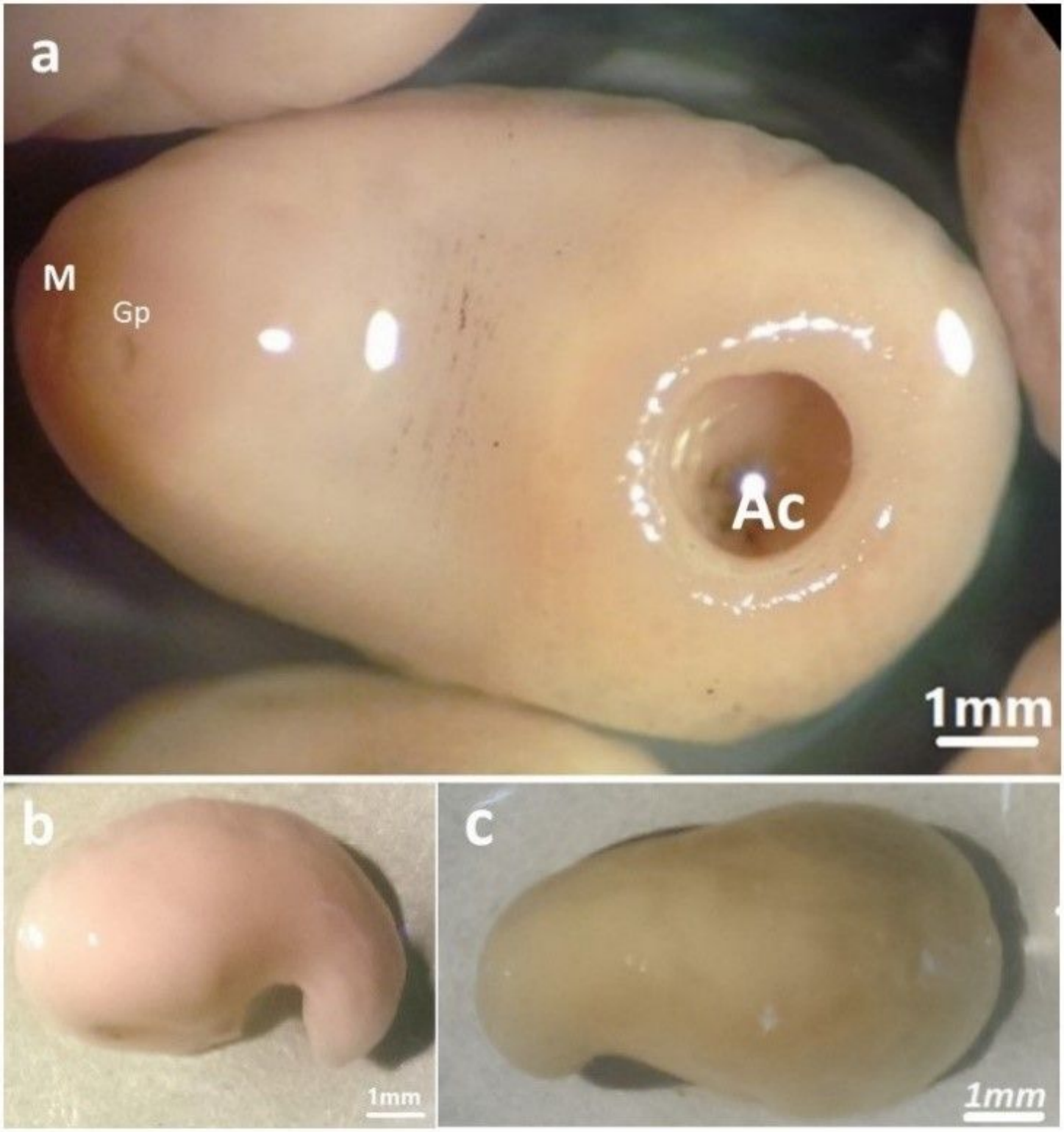

Figure 1

Gross view of *E. explanatum* under stereomicroscope. a) ventral view of whole-body shape, M: Mouth, Gp: Gonopore, ac: Acetabulum, b) lateral view of whole-body, c) dorsal view of whole-body

In SEM images (Fig 2), no body spines and armature were seen, but frequent and prominent tegumental papillae were noticed that are characters of the genus *Explanatum*.

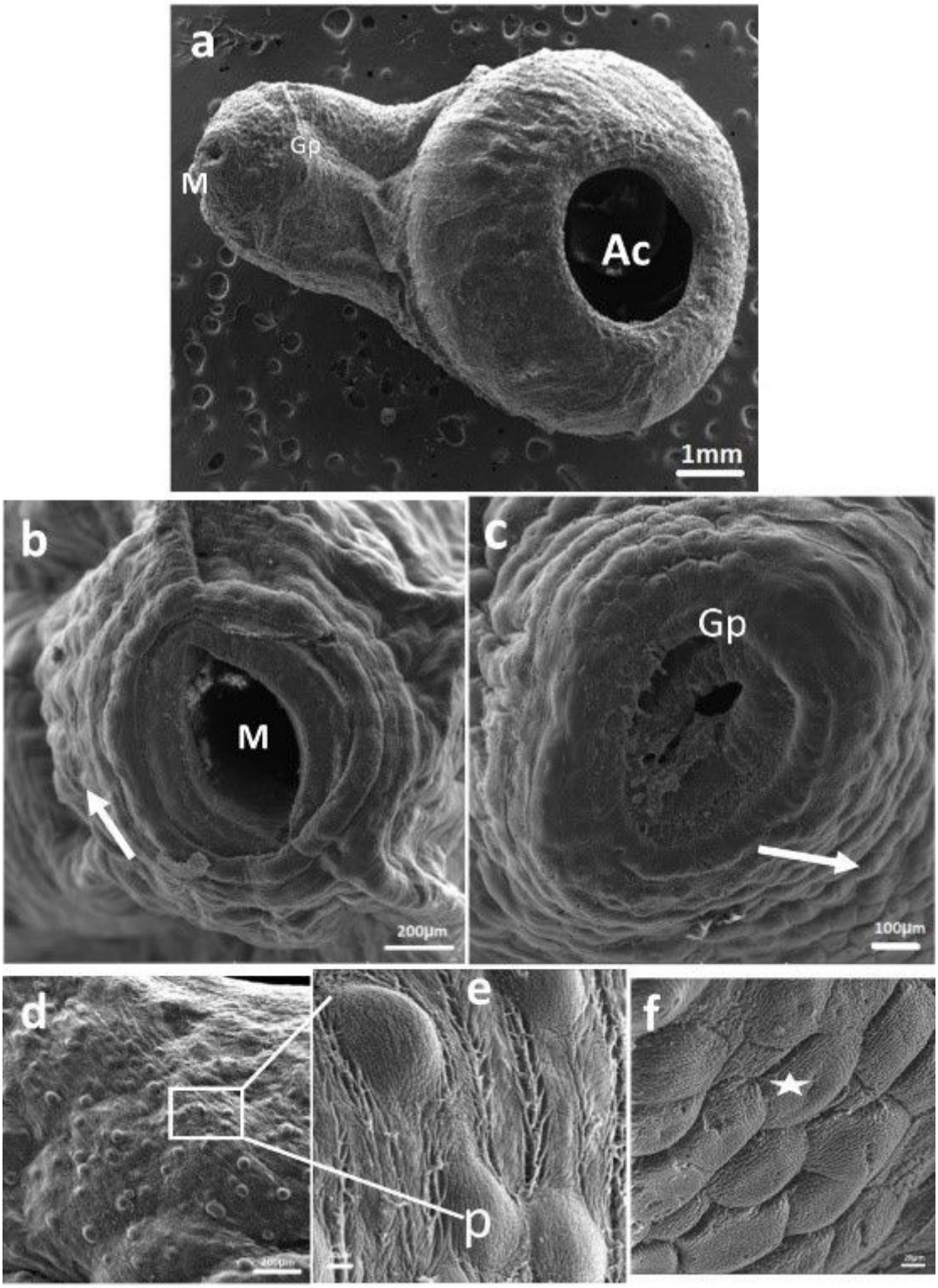

Figure 2

Scanning electron micrograph of *E. explanatum*. a) Ventral view of whole-body, M: Mouth, Gp: Gonopore, Ac: Acetabulum, b) M: Mouth, arrow shows the dome shaped papillae, c) Gp: Gonopore, arrow shows the dome shaped papillae, d & e) p: Dome shaped papillae, f) Star: tegument ridges and furrows.

Figure 3

Cross sections of *Explanatum*. a: acetabulum, o: ovary, p: pharynx, u: uterus, t: testis, c: caeca, Gp: Genital pore, v: Vitelline follicles.



Figure 4

Potential intermediate hosts for *E. explanatum* in the region. a) Shell without operculum, discoid belongs to Family Planorbidae. b) Shell coiled shape, conical, dextral (aperture to right) belongs to Family: Lymnaeidae