In vitro testing of a funnel-tip catheter model to decrease clot migration and to evaluate clot effects in mechanical thrombectomy

Emily S. Payne
University Medical Center of the Johannes Gutenberg University Mainz, Department of Neuroradiology, Langenbeckstrasse 1, 55131 Mainz

Samantha Krost-Reuhl
University Medical Center of the Johannes Gutenberg University Mainz, Department of Neuroradiology, Langenbeckstrasse 1, 55131 Mainz

Axel Heimann
University Medical Center Mainz, Institute for Neurosurgical Pathophysiology, Langenbeckstrasse 1, 55131 Mainz

Oliver Kempski
University Medical Center Mainz, Institute for Neurosurgical Pathophysiology, Langenbeckstrasse 1, 55131 Mainz

Naureen Keric
University Medical Center Mainz, Department of Neurosurgery, Langenbeckstrasse 1, 55131 Mainz

Julia Masomi-Bornwasser
University Medical Center Mainz, Department of Neurosurgery, Langenbeckstrasse 1, 55131 Mainz

Tiemo Gerber
University Medical Center Mainz, Tissue Bank, Institute of Pathology, Langenbeckstrasse 1, 55131 Mainz

Larissa Seidmann
University Medical Center Mainz, Institute of Pathology, Langenbeckstrasse 1, 55131 Mainz

Doris Leithner
Medical University of Vienna, Department of Biomedical Imaging and Image-guided Therapy, 1090 Vienna

Roman Kloeckner
University Medical Center Mainz, Department of Diagnostic and Interventional Radiology, Langenbeckstrasse 1, 55131 Mainz

Felix Hahn
University Medical Center Mainz, Department of Diagnostic and Interventional Radiology, Langenbeckstrasse 1, 55131 Mainz

Lukas Müller

University Medical Center Mainz, Department of Diagnostic and Interventional Radiology, Langenbeckstrasse 1, 55131 Mainz

Timo A. Auer

University Medical Center-Charité, Department of Radiology, Berlin

Stefanie Kirschner

University Medical Center Mannheim, Medical Faculty Mannheim, Heidelberg University, Department of Radiation Oncology, 68167, Mannheim

Marc A. Brockmann (brockmann@gmx.de)

University Medical Center of the Johannes Gutenberg University Mainz, Department of Neuroradiology, Langenbeckstrasse 1, 55131 Mainz

Yasemin Tanyildizi

University Medical Center of the Johannes Gutenberg University Mainz, Department of Neuroradiology, Langenbeckstrasse 1, 55131 Mainz

---

Research Article

Keywords: mechanical thrombectomy, mechanical thrombectomy (MT), clot retrieval

Posted Date: February 18th, 2021

DOI: https://doi.org/10.21203/rs.3.rs-154431/v1

Abstract

Clot-retrieval failure and embolism in new territories (ENT) are complications reducing the efficacy of mechanical thrombectomy (MT). Reasons for these problems are clot abruption during stent retriever retraction into the cylindrical tip of a standard distal access catheter (DAC), and antegrade blood flow during retrieval. To overcome these complications, a funnel-shaped tip catheter model was developed and tested. Using an experimental in vitro setup, this study compared the efficacy of a funnel-shaped tip with a standard cylindrical tip in combination with different clot compositions. Mechanical thrombectomy was performed 80 times for each tip, using two stent retrievers (Trevo XP ProVue 3/20 mm and 4/20 mm) and four different clot types (mechanical vs. static preparation, 0-24h vs. 72h clot aging times). Significantly higher first-pass recanalization rates were observed for the funnel-shaped tip, which reached 70.0% vs. 30.0% for the standard tip (absolute difference, 32; relative difference 20.0%, $P < 0.05$), regardless of the clot type and stent retriever. Recanalization could be increased using fibrin-rich mechanical clots vs. clots prepared under static conditions, as well as 0-24h vs. 72h aged clots, respectively. The extended in vitro-experiments verified the usability of the recently patented funnel-shaped DAC, hereby implementing next-level in vivo-experiments.

Introduction

Mechanical thrombectomy (MT) is a recommended treatment for acute ischemic stroke (AIS) patients with large vessel occlusion (LVO), within 24 hours of symptom onset [1]. A pooled meta-analysis (HERMES collaboration) from the so-called “big five” multicenter randomized controlled trials reported a successful recanalization rate of 71% (mTICI Scores $\geq$2b): ranging from a minimum of 58.7% (MR CLEAN) to a maximum of 88.0% (SWIFT PRIME), and improved functional outcome of 46% (mRS score ≤ 2 after 90 days) for mechanical thrombectomy in LVO of the anterior circulation (M1, M2 and ICA). Despite high recanalization rates, embolism in new territories (ENT) rates of 1 to 8.6% have been reported for most randomized controlled trials [2–5]. Although the use of proximal balloon occlusion during thrombectomy has been suggested to significantly reduce this problem, clot migration into distal territories still remains unresolved. This might be caused by clot abruption at the wall of the cylindrical tip during stent retriever retraction into standard distal access catheters (DAC) [2]. Due to an overlap of thrombus material during retraction into the narrow opening tip, the thrombus is compressed and elongated, increasing the risk of fragmentation [6,7].

A funnel-shaped tip catheter model was tested to decrease the risk of clot migration and to increase the rate of first pass TICI 2b/3 results. We compared the funnel-shaped tip featuring a larger inner-opening diameter (d = 2.5mm) to a standard tip (d = 1.5mm) model, in terms of functionality and efficacy for mechanical thrombectomy in an in vitro setup. In our first in vitro study, we observed higher recanalization rates of up to 90% using the modified funnel-shaped tip compared to 50 to 60% for the standard tip [2]. Consequently, the proof-of-concept for a newly designed funnel-shaped tip was deemed viable for continuing further in vitro experiments, this time including a greater case number (N = 160) and

employing different clot types. As other recent studies [6,8,9] have indicated, thrombus-vessel and thrombus-device interaction are influenced by the viscosity and composition of clot types. Successful MT is associated with reduced friction and adhesion during retraction. Certain clot types may be more prone to fragmentation and may increase the risk of ENT [6,8]. Therefore, the effects of four different clot types on MT were evaluated by comparing the funnel-shaped tip catheter model with a standard cylindrical tip catheter model [2].

Materials And Methods

For standardization, the experimental setup was comparable to the one used in our preliminary study [2].

Catheter Model Setup

Two introducer sheaths were modified to create the funnel tip and standard tip catheter models (4 French (F) Radifocus® Introducer II Standard Kit; TERUMO International Systems, Leuven, Belgium). For this purpose, the tapered tip of each introducer was removed. To develop the funnel-shaped tip, one introducer was manually dilated to a diameter of 2.5 mm. For the standard tip, the other introducer was cut to a diameter of 1.5 mm, comparable with commercially available DACs. The experiments were performed using a catheter model; the actual funnel-shaped DAC prototype was just recently developed and patented by our research team.

MCA Model

MT was performed in vitro using a Middle Cerebral Artery (MCA) vasculature model of the M1-segment (inner tube diameter 3.0 mm, length 16 cm). The MCA model was constructed from an IV line blood transfusion kit (CODAN, Medizinische Geräte GmbH & Co KG, Lensahn, Germany) and attached to the shortened 3 cm end of a 9 French introducer sheath for gaining access. Prior to each MT experiment, the model was flushed with 40% aqua-glycerol solution (Glycerin 85%; Caesar & Lorenz GmbH, Hilden, Germany) to simulate blood-like viscosity.

Generating Thrombi

Blood from five pigs was used to generate thrombi for the MT experiments and histopathological analyses. Research was conducted in accordance with all applicable international, national and/or institutional guidelines for the care and use of animals. A statement confirming the study was carried out in compliance with the ARRIVE guidelines. Specifically, the research project was examined by an ethical committee and approved (reference number 23 177-07/G 14-1-094) by the responsible local government authority (Landesuntersuchungsamt Rheinland-Pfalz, Germany), in accordance with the German Animal Welfare Act (Tierschutzgesetz).

Venous whole blood was extracted before sacrificing the pigs, in accordance with the above mentioned animal welfare regulations and procedures. Polyvinyl chloride (PVC) tubes (clear PVC tubing, inner

diameter 8.0 mm, outer diameter 12.0 mm; Thermo Scientific Fischer, Waltham, Massachusetts, USA) were half filled with blood, and the ends of the tubes were connected using a silicone cuff [2].

Two methods were employed for generating thrombi: (I) mechanical preparation using a Chandler loop device (Chandler loop System, Neuffen, Germany), and (II) clot preparation under static conditions. The Chandler loop simulated physiological blood circulation under dynamic conditions in a standardized setting. For this purpose, a temperature-controlled water basin was preheated to 38.5°C. The PVC tubes containing porcine blood were placed in the loop cradle and rotated at 15 rpm. The “moving column of blood” [10,11] coagulated after 20 to 30 minutes. Simultaneously, the thrombi processed under static conditions were prepared by hanging the PVC tubes vertically from a rod for 20 to 30 minutes at room temperature.

After blood coagulation within the PVC tubes, the clots from both preparation methods were removed from the tubes and refrigerated in saline solution at 10°C. MT was performed either 0 to 24 hours or 72 hours after preparation of thrombi. Prior to each experiment, the thrombi were cut equally into 20 mm long segments.

Mechanical Thrombectomy Procedure

A thrombus segment was placed into the MCA model under aspiration for each MT experiment. Then, one of the catheter models (funnel-shaped tip; standard tip) was positioned at the proximal end of the thrombus. After inserting the stent retriever (Trevo XP Pro Vue 3/20 mm; Trevo XP Pro Vue 4/20 mm; Stryker, Kalamazoo, Michigan, USA) into the MCA model, it was released over the thrombus for 3 minutes. The thrombus was retracted into the catheter model under aspiration, using a vacuum pressure syringe (60 ml, VacLok, Vacuum pressure syringes; Merit Medical System) set in advance to a negative pressure at a volume of 40 ml. MT was conducted using the primary combined approach (PCA), for both aspiration and stent retriever devices. Experiments were performed under visual control using fluoroscopy and video monitoring.

Histopathological Analyses

Histopathological analyses of fresh (0h) and matured (72h) thrombi, prepared with and without the use of a Chandler loop system, were performed after fixation of thrombi in 4% buffered formalin (Formaldehyde solution 4% buffered (PH 6.9); Merck KGaA, Darmstadt, Germany). The thrombi were cut at 3 mm intervals, sliced by a microtome in 2 µm thick sections onto microscopic slides, and stained with masson trichrome. For enhanced visualization, the microscopic slides were scanned with Nanozoomer 2.0 HT (Hamamatsu), magnified 200-fold, and exported as TIFF files. To differentiate the exact fibrin distribution, pixel-by-pixel analysis was performed using Trainable Weka Segmentation Fiji plugin v3.2.27. Each of the different clot types was graduated according to three different categories: fibrin pattern, distribution and outer fibrin rim.

The category “fibrin pattern” was further specified as insular, reticular or no pattern. The distribution of fibrin was classified as peripheral, central, both peripheral and central (regular), or irregular distribution, depending on the localization. The outer rim of fibrin (defined as circumferential layer of fibrin surrounding the thrombus) was divided into the subcategories total circumference of fibrine, focal or no rim.

Statistical Analyses

For the MT experimental series, statistical analyses were performed with GraphPad Prism 9.2 (GraphPad Software, Inc., San Diego, CA). The Pearson chi-square-test (X^2-test) was used to determine the statistical significance of categorial variables (MT success; failure) involving an independent pair sample (funnel-shaped tip; standard tip). The failure causes for the different clot types were assessed using two-way analysis of variance (ANOVA). For histopathological analyses, SPSS Software. ((23.0) IBM; New York, USA) was utilized for statistical analyses. Multinomial logistic regression was used to assess the effect of independent variables (thrombus preparation and aging time) and their prediction of nominal outcome parameters (fibrin pattern, distribution and outer circumference). The p value threshold was set to $p < 0.05$ for all analyses.

Results

MT was conducted 80 times per catheter type (funnel-shaped; standard tip) using two stent retrievers (Trevo XP ProVue 3/20 mm; 4/20 mm) and four clot types (Chandler loop 0-24h; Chandler loop 72h; static 0-24h; static 72h), resulting in 10 procedures for each combination, respectively. (Fig. 1) The effects of the two thrombus preparation methods on MT were evaluated (Chandler loop vs. static), resulting in 80 experiments per preparation method. A total of 160 MTs were carried out. Results from the preliminary study Tanyildizi et al.[2] were included in the Chandler loop group. Please refer to the flowchart (Fig. 1) for further distinction.

MT Results

The funnel-shaped catheter achieved successful first-pass recanalization in 56/80 MTs (70.0%), compared to the standard catheter with only 24/80 MTs (30.0%) at first pass (absolute difference, 32; relative difference 57.1%; $P < .001$) regardless of the clot type and stent retriever.

Table 1
Summary of mechanical thrombectomy (MT) results. Comparing two catheter models (funnel-shaped tip; standard tip); two thrombi aging times (0–24 hours versus 72 hours) and two thrombi preparation methods (mechanical = Chandler loop; static preparation) individually with the corresponding p values.

	Type of catheter tip		**Thrombus age**		**Method of thrombus preparation**	
MT success rate	Funnel-shaped tip	Standard tip	0-24h	72h	Chandler loop	Static
N (success) / N (total = 80)	56/80	24/80	47/80	33/80	46/80	34/80
P value	P *< .001*		*P = .03*		*P = .06*	

Failure Causes For The Funnel-shaped Tip

During stent retriever retraction, thrombus loss was responsible for 11/24 MT failures (45.8%), prior to reaching the wall of the funnel-shaped tip. Clot abruption at the wall of the tip caused 13/24 failures (54.2%). Failure causes for both tips are depicted in Fig. 2.

Failure Causes For The Standard Tip

Clot abruption along the standard tip wall led to 45/56 MT failures (80.4%). The remaining 11/56 failures (19.6%) occurred after the stent retriever failed to grip the thrombus during retraction, before reaching the tip. (Fig. 2)

MT Results For The Preparation Methods

MT performed with Chandler loop-generated thrombi was successful in 31/40 (77.5%) cases for the funnel-shaped tip and 15/40 cases (37.5%) for the standard tip (absolute difference, 16; relative difference, 51.6%; $P < 0.05$). (Table 2) Thrombi prepared under static conditions registered 25/40 (62.5%) successful MTs for the funnel-shaped model, and 9/40 (22.5%) successful MTs for the standard model (absolute difference, 16; relative difference, 64.0%; $P < 0.05$). (Table 3) Regardless of the catheter tip, MT was successful in 46/80 cases (57.5%) for the entire Chandler loop thrombi and 34/80 cases (42.5%) for thrombi generated under static conditions (absolute difference 13; relative difference 28.3%; $p = 0.06$). (Table 1) The recanalization rates for all clot types are shown in Fig. 3.

Table 2
Mechanical thrombectomy results for both catheter models (funnel-shaped tip; standard tip) using mechanical thrombi (Chandler loop) at different aging times (0–24 hours versus 72 hours).

Chandler loop preparation N (success) / N (total)	**Funnel-shaped tip**	**Standard tip**	**Funnel-shaped tip + Standard tip**	***P value***
0-24h	18/20	11/20	29/40	*P = .10*
72h	13/20	4/20	17/40	*P < .001*
0-24h + 72h	31/40	15/40		*P = .01*
Chandler loop preparation total N (success) / N (total) = 46/80				

Table 3
Mechanical thrombectomy results for both catheter models (funnel-shaped tip; standard tip) using thrombi prepared under static conditions at different aging times (0–24 hours versus 72 hours).

Static preparation N (success) / N (total)	**Funnel-shaped tip**	**Standard tip**	**Funnel-shaped tip + Standard tip**	**P value**
0-24h	13/20	5/20	18/40	*P = .03*
72h	12/20	4/20	16/40	*P* < .001
0-24h + 72h	25/40	9/40		*P* = .03
Static preparation total N (success) / N (total) = 34/80				

MT results for different stent retriever types and thrombus aging times are shown in Tables 4 and 5, respectively.

Table 4
Mechanical thrombectomy results for both catheter models (funnel-shaped tip; standard tip) using two stent retrievers (Trevo XP ProVue Retriever 3 x 20 mm; Trevo XP ProVue Retriever 4 x 20 mm).

Stent retrievers **N (success) / N (total = 40)**	**Funnel-shaped tip**	**Standard tip**	***P value***
Trevo XP ProVue Retriever 3 x 20 mm (Stryker)	30/40	12/40	*P < .001*
Trevo XP ProVue Retriever 4 x 20 mm (Stryker)	26/40	12/40	*P < .01*
P value for both stent retrievers	*P = .33*	*P = 1.00*	P = .53

Table 5
Mechanical thrombectomy results for both catheter models (funnel-shaped tip; standard tip) for two thrombi aging times (0–24 hours versus 72 hours).

Thrombus aging times **N (success) / N (total = 40)**	**Funnel-shaped tip**	**Standard tip**	***P value***
0-24h	31/40	16/40	P = .02
72h	25/40	8/40	P < *.001*
P value for both aging times	*P = .14*	*P = .05*	P = .03

Results For The Histopathological Analyses

A total of 280 thrombi sections were included in the histopathological analyses. The Chandler loop thrombi displayed a higher proportion and regular distribution of fibrin than the static thrombi, (distribution: 56/107 vs. 20/173, respectively; odds ratio (OR), 8.4; 95% CI, 4.606 to 15.320; P < .001), and a reticular or insular fibrin pattern (pattern: 83/107 vs. 32/173, respectively; odds ratio, 15.24; 95% CI, 8.4 to 27.6; P < .001). (Fig. 4) Comparing both aging times, an outer fibrin circumference was observed more frequently in the 72h aged thrombi than the 0h thrombi (circumference: 74/155 versus 21/125, respectively; odds ratio, 4.524; 95% CI, 2.572 to 7.960; P < .001). For further histopathological graduation, see supplementary information.

Discussion

MT in combination with IVT is the standard treatment for acute large vessel occlusion [1]. Despite high recanalization rates and improved techniques, endovascular treatment still faces limitations, reporting

ENT incidences of up to 10% for aspiration devices [12–14]. ENT can be caused by clot abruption and stripping along the wall of conventional DACs, due to elongation and compression of thrombus material through the narrow opening [6,7]. Aiming to solve this problem, a modified model featuring a funnel-shaped tip was tested in this study. The larger opening (d = 2.5 mm compared to approx. for 1.7 mm for actual 068-distal access catheters) of the funnel-shaped tip relates to the anatomical diameter of the M1-MCA segment, which is reported to be 2.7 ± 0.23 mm (mean ± 1 SD) [15,16], hereby reducing unwanted effects like striping of the thrombus at the catheter tip using a 4.0 mm stent retriever. The proof-of-concept of this study was validated by achieving significantly higher recanalization rates for the wider, funnel-shaped tip, with 56/80 successful MTs (70.0%) at first pass compared to 24/80 (30.0%) for the standard tip, regardless of the stent retriever and clot type.

The funnel-shaped tip aims to facilitate MT in three ways: 1) by inducing local flow arrest during retraction into the catheter tip model, turbulence and reverse flow may be reduced around the catheter model, mitigating the risk of clot fragmentation and migration; 2) by decreasing the pressure gradient during aspiration due to the larger opening, aspiration forces may be applied across the entire catheter-thrombus contact area; 3) the funnel-shaped tip may decrease the resistance and shear forces, which the self-expanding stent retriever has to overcome during retraction. One problem affecting the standard tip is the disproportionally larger size of the self-expanding stent retriever in relation to the smaller opening of the standard tip during retraction. However, the larger opening of the funnel-shaped tip may guide the stent retriever into the catheter model, enabling a better retraction or interlock during aspiration [6].

Evaluating the causes of MT failure is one advantage of an in vitro setting. An abruption of clot material at the wall of the tip was the main cause of failure for the standard tip. In contrast, half of the failures for the funnel-shaped tip occurred before reaching the wall of the tip when the stent retriever failed to grip the clot.

Recent literature indicates that other funnel-shaped catheters, such as the Lazarus Device (Lazarus Effect, Campbell, California, USA) [17] and the Advanced Thrombectomy System (ANCD; R&D, Anaconda Biomed, Barcelona, Sant Cugat del Vallès, Spain) [7] have been independently developed to our project. The Lazarus Device uses a different mechanism with a funnel-shaped nitinol mesh to enclose the stent retriever without inducing local flow arrest. The ANCD bares technical resemblance to our funnel-shaped tip, in addition to similarly initiating local flow arrest during procedure [17,18]. Both studies also reported promising results for funnel-shaped models, with recanalization rates of 94% and 80% for the ANCD and Lazarus Device, respectively [7,17,18].

Evaluating the effect of clot compositions, Chandler loop thrombi showed a tendency towards improved recanalization compared to thrombi prepared under static conditions. Recent publications have investigated the effect of clot composition on MT. Fibrin determines the structural integrity of blood clots forming a three-dimensional scaffold. Mechanical forces as well as thrombolysis may cause fibrin fibers to break when certain threshold levels are exceeded. Consequently, the structural integrity of the blood

clot is impacted. Physical defects and cracks within the blood clots make the thrombus more susceptible to rupturing. Thus, clot composition and geometry play a pivotal role in the pathogenesis of ENT [20].

According to Duffy et al. [19], clots processed under static conditions, similar to one group of clots from this study, displayed an erythrocyte-dominant (RBC-dominant) and low fibrin content. Chandler loop clots, showed a fibrin-predominant pattern and were characterized by their firmness and elasticity [19]. In correlation to the histopathological findings of this study, clots prepared under static conditions were distinguished by lower levels of fibrin, absence of a fibrin pattern, as well as irregular fibrin distribution. Due to the coagulation of blood under static conditions, erythrocytes were unevenly distributed and more densely concentrated. Controversially, some studies classify Chandler loop clots as erythrocyte-rich [21]. In this study, Chandler loop clots are classified as fibrin-rich because they contain lower amounts of erythrocytes and higher amounts of fibrin relative to clots developed under static conditions. Research literature states that white fibrin-rich thrombi are associated with reduced recanalization rates, in which the stent retriever is unable to grip the clot. The high fibrin content could account for an increased adhesion and resistance along the vessel wall, thereby impeding MT [6–8]. However, this study registered higher recanalization rates for the Chandler loop clots (fibrin-rich) than for the “static” clots. An explanation for this is provided by Madjidyar et al. [21], stating that MT success not only depends on the “right” clot type, but also on the “correct” technique [21–24]. Clot removal for fibrin-rich clots could be improved by applying distal aspiration, as performed in our study. Moreover, the Direct Aspiration First Pass Technique (ADAPT) was considered more effective using RBC-rich clots, whilst stent retrievers and balloon-guided catheters (BGC) were more successful with fibrin-rich clots [21]. Since our research project relied on PCA, using aspiration in combination with stent retrieval, different MT techniques should be included in future studies to evaluate the efficacy of our modified prototype. Numerous studies indicated that RBC-rich thrombi were related to higher recanalization rates, but showed a higher tendency towards fragmentation [6–8]. Accordingly, “static” thrombi from this study (RBC-rich) were found to be more susceptible to fragmentation, resulting in higher rates of clot abruption at the wall of the tip. This can be explained by a lack of structural integrity due to the absence of a fibrin pattern. Furthermore, the disparity of recanalization rates between the Chandler loop 0-24h and 72h thrombi was found to be greater than between the “static” 0-24h and 72h clots. Since fibrin may dissolve over time and become lytic, the fibrin-rich Chandler loop thrombi may be affected more by the aging time.

Evaluating how the clot aging times may affect MT, 0-24h aged clots achieved higher recanalization than 72h clots [25]. Histopathologically, the difference between aging times could be explained by an outer fibrin rim (predominant in the 72h aged thrombi group), which may cause increased friction during retraction. Aged thrombus material may restructure and degrade, becoming more condensed due to fluid loss. Additionally, the higher density could increase friction during retraction and impede stent retrieval [8,25–27].

The simplified experimental setup of this study can be considered a limiting factor. In addition, the MCA-model did not take the tortuosity of the MCA-vasculature into account. Also, a simplified modified tip model was used. The actual funnel-shaped prototype, which was still being developed at the time of the

experiments, was recently patented. It features a self-expanding flexible structure optimized to induce local flow arrest. Because it is unclear how the funnel-shaped tip could affect the vessel endothelium, further in vitro and in vivo research is required. Testing homogenous clots under standardized laboratory conditions is another limitation of this study, since clinical clots have irregular heterogeneous compositions that are still difficult to determine [27]. Additional studies should consider examining the impact of fibrinolytic agents on MT procedure and clot structure. A performance bias in this study cannot be excluded, since the interventionalist could not be blinded during MT procedure.

Conclusion

The underlying study demonstrates significantly higher first-pass recanalization rates for the modified funnel-shaped tip versus the standard tip model, regardless of the clot type and aging time. Clot abruption at the wall of the tip was the leading cause of failure for the standard tip. Furthermore, results indicate that MT success rates were affected by different clot types and compositions. Higher recanalization rates were achieved using mechanically-prepared fibrin-rich Chandler loop clots, instead of erythrocyte-rich prepared clots under static conditions. In addition, 0-24h aged thrombi achieved higher recanalization rates than 72h aged thrombi. This follow-up study underscores the feasibility of the modified tip for further developing the funnel-shaped DAC prototype.

Declarations

Data availability

Supplementary information is available for this paper at https://doi.org/10.1038/s41598-019-57315-9

Author information

Affiliations

Emily S. Payne[1]*, Samantha Krost-Reuhl[1], Axel Heimann[2], Oliver Kempski[2], Naureen Keric[3], Julia Masomi-Bornwasser[3], Tiemo Gerber[4], Larissa Seidman[5], Doris Leithner[6], Roman Kloeckner[7], Felix Hahn[7], Lukas Müller[7], Timo A. Auer[8], Stefanie Kirschner[9], Marc A. Brockmann[1]**, Yasemin Tanyildizi[1]

[1] University Medical Center Mainz of the Johannes Gutenberg University Mainz, Department of Neuroradiology, Langenbeckstrasse 1, 55131 Mainz, Germany

[2] University Medical Center Mainz, Institute for Neurosurgical Pathophysiology, Langenbeckstrasse 1, 55131 Mainz, Germany

[3] University Medical Center Mainz, Department of Neurosurgery, Langenbeckstrasse 1, 55131 Mainz, Germany

[4] University Medical Center Mainz, Tissue Bank, Institute of Pathology, Langenbeckstrasse 1, 55131 Mainz, Germany

[5] University Medical Center Mainz, Institute of Pathology, Langenbeckstrasse 1, 55131 Mainz, Germany

[6] Medical University of Vienna, Department of Biomedical Imaging and Image-guided Therapy, 1090 Vienna, Austria

[7] University Medical Center Mainz, Department of Diagnostic and Interventional Radiology, Langenbeckstrasse 1, 55131 Mainz, Germany

[8] University Medical Center-Charité, Department of Radiology, Berlin, Germany

[9] University Medical Center Mannheim, Medical Faculty Mannheim, Heidelberg University, Department of Radiation Oncology, 68167, Mannheim, Germany

* doctoral candidate, part of Emily S. Payne's doctoral thesis

Corresponding author:

** Univ.-Prof. Dr. med. Marc A. Brockmann, email: brockmann@gmx.de; telephone: +49 (0) 6131 17 7139.

Author contributions

All authors reviewed the manuscript and have approved the submitted version. Design and conception of the study: E.S.P.; S.K.; M.A.B.; Y.T.; Data acquisition: E.S.P.; S.K.-R.; A.H.; O.K.; N.K.; J.M.-B.; T.G.; L.S.; S.K.; Y.T.; Analysis and interpretation of data: E.S.P.; T.G.; L.S.; D.L.; R.K.; F.H.; L.M.; T.A.A.; S.K.; M.A.B.; Y.T.; Wrote the manuscript: E.S.P.; Prepared Figures 1-3: E.S.P.; Prepared Figure 4: T.G.; L.S.; Prepared Tables 1-5: E.S.P.; Prepared Supplements: E.S.P.; Revised and Edited the manuscript: T.G.; S.K.; M.A.B.; Y.T.

Competing interests

Prof. Dr. med. Marc A. Brockmann's and Dr. med. Yasemin Tanyildizi's research work has been funded by the German Federal Ministry for Economic Affairs and Energy (Bundesministerium für Wirtschaft und Energie) under its WIPANO (Wissens- und Technologietransfer durch Patente und Normen) sponsoring program (WIPANO grant number: 03THW13K02), primarily for developing and patenting the funnel-shaped prototype DAC. Prof. Dr. Marc A. Brockmann and Dr. med. Yasemin Tanyildizi declare no potential conflict of interest from funding or any other activities. All other contributing authors, Emily S. Payne, Samantha Krost-Reuhl, Axel Heimann, Oliver Kempski, Naureen Keric, Julia Masomi-Bornwasser, Tiemo Gerber, Larissa Seidman, Doris Leithner, Roman Kloeckner, Felix Hahn, Lukas Müller, Timo A. Auer, Stefanie Kirschner, have not received any funding and declare no potential conflict of interest.

Contact funding/sponsoring details

Office for Social Services, Mainz, Rhineland-Palatinate, Germany

Fr. Anna-Lena Krost

Email: Anna-Lena.Krost@stadt.mainz.de

Telephone: +49 (0) 6131 12-2719

Address: Postfach 3620, 55026 Mainz, Germany

References

1. Fiehler, J. New ESO/ESMINT Thrombectomy Guidelines: after Guideline Writing is before Guideline Writing. *Clinical Neuroradiology* **29**, 189–190 (2019).
2. Tanyildizi, Y. *et al.* In vitro testing of a funnel-shaped tip catheter model to decrease clot migration during mechanical thrombectomy. *Scientific Reports* **10**, 633 (2020).
3. Goyal, M. *et al.* Endovascular thrombectomy after large-vessel ischaemic stroke: a meta-analysis of individual patient data from five randomised trials. *Lancet* **387**, 1723–1731 (2016).
4. Goyal, M. *et al.* Randomized assessment of rapid endovascular treatment of ischemic stroke. *N Engl J Med* **372**, 1019–1030 (2015).
5. Balami, J. S., White, P. M., McMeekin, P. J., Ford, G. A. & Buchan, A. M. Complications of endovascular treatment for acute ischemic stroke: Prevention and management. *Int J Stroke* **13**, 348–361 (2018).
6. Yoo, A. J. & Andersson, T. Thrombectomy in Acute Ischemic Stroke: Challenges to Procedural Success. *J Stroke* **19**, 121–130 (2017).
7. Sanchez, S. *et al.* ANCD thrombectomy device: in vitro evaluation. *J Neurointerv Surg* **12**, 77–81 (2020).
8. Gunning, G. M. *et al.* Clot friction variation with fibrin content; implications for resistance to thrombectomy. *J Neurointerv Surg* **10**, 34–38 (2018).
9. Kang, D. H. & Hwang, Y. H. Frontline Contact Aspiration Treatment for Emergent Large Vessel Occlusion: A Review Focused on Practical Techniques. *J Stroke* **21**, 10–22 (2019).
10. Mousa, S. A. In Vitro and Ex Vivo Tests of Coagulation and Platelet Function. in *Drug Discovery and Evaluation: Pharmacological Assays* (ed. Hock, F. J.) 1–27 (Springer Berlin Heidelberg, 2014). doi:10.1007/978-3-642-27728-3_11-1.
11. Chandler, A. B. In vitro thrombotic coagulation of the blood; a method for producing a thrombus. *Lab Invest* **7**, 110–114 (1958).
12. Pierot, L., Gawlitza, M. & Soize, S. Techniques for endovascular treatment of acute ischemic stroke. *Rev Neurol (Paris)* **173**, 594–599 (2017).
13. Turk, A. S. *et al.* ADAPT FAST study: a direct aspiration first pass technique for acute stroke thrombectomy. *J Neurointerv Surg* **6**, 260–264 (2014).

14. Turk 3rd, A. S. *et al.* Aspiration thrombectomy versus stent retriever thrombectomy as first-line approach for large vessel occlusion (COMPASS): a multicentre, randomised, open label, blinded outcome, non-inferiority trial. *Lancet* **393**, 998–1008 (2019).
15. Schreiber, S. J., Gottschalk, S., Weih, M., Villringer, A. & Valdueza, J. M. Assessment of blood flow velocity and diameter of the middle cerebral artery during the acetazolamide provocation test by use of transcranial Doppler sonography and MR imaging. *AJNR Am J Neuroradiol* **21**, 1207–1211 (2000).
16. Rai, A. T., Hogg, J. P., Cline, B. & Hobbs, G. Cerebrovascular geometry in the anterior circulation: an analysis of diameter, length and the vessel taper. *J Neurointerv Surg* **5**, 371–375 (2013).
17. Fargen, K. M., Mocco, J. & Gobin, Y. P. The Lazarus Funnel: a blinded prospective randomized in vitro trial of a novel CE-marked thrombectomy assist device. *J Neurointerv Surg* **8**, 66–68 (2016).
18. Mokin, M., Setlur Nagesh, S. v, Ionita, C. N., Mocco, J. & Siddiqui, A. H. Stent retriever thrombectomy with the Cover accessory device versus proximal protection with a balloon guide catheter: in vitro stroke model comparison. *J Neurointerv Surg* **8**, 413–417 (2016).
19. Duffy, S. *et al.* Novel methodology to replicate clot analogs with diverse composition in acute ischemic stroke. *J Neurointerv Surg* **9**, 486–491 (2017).
20. Tutwiler, V. *et al.* Rupture of blood clots: Mechanics and pathophysiology. *Science Advances* **6**, eabc0496 (2020).
21. Madjidyar, J., Pineda Vidal, L., Larsen, N. & Jansen, O. Influence of Thrombus Composition on Thrombectomy: ADAPT vs. Balloon Guide Catheter and Stent Retriever in a Flow Model. *Rofo* **192**, 257–263 (2020).
22. Madjidyar, J., Hermes, J., Freitag-Wolf, S. & Jansen, O. Stent-thrombus interaction and the influence of aspiration on mechanical thrombectomy: evaluation of different stent retrievers in a circulation model. *Neuroradiology* **57**, 791–797 (2015).
23. Chueh, J. Y., Puri, A. S., Wakhloo, A. K. & Gounis, M. J. Risk of distal embolization with stent retriever thrombectomy and ADAPT. *J Neurointerv Surg* **8**, 197–202 (2016).
24. Machi, P. *et al.* Experimental evaluation of stent retrievers' mechanical properties and effectiveness. *J Neurointerv Surg* **9**, 257–263 (2017).
25. Nogueira, R. G. *et al.* Thrombectomy 6 to 24 Hours after Stroke with a Mismatch between Deficit and Infarct. *N Engl J Med* **378**, 11–21 (2018).
26. Nouh, A., Mehta, T., Hussain, M., Song, X. & Ollenschleger, M. Clot composition of embolic strokes of undetermined source: a feasibility study. *BMC Neurology* **20**, 383 (2020).
27. Heo, J. H. *et al.* Pathophysiologic and Therapeutic Perspectives Based on Thrombus Histology in Stroke. *J Stroke* **22**, 64–75 (2020).

Figures

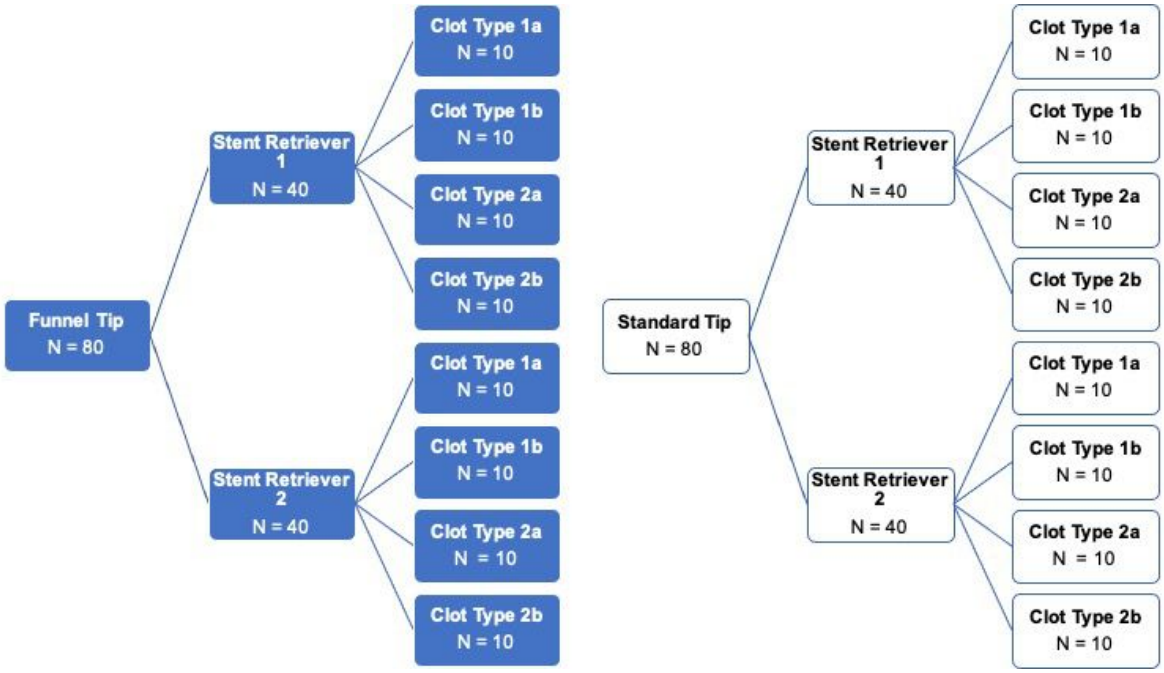

Figure 1

Flowchart of MT experimental series. Stent Retriever 1, Trevo XP ProVue Retriever 3 x 20 mm (Stryker); Stent Retriever 2, (Trevo XP ProVue Retriever 4 x 20 mm (Stryker); Clot Type 1a, Chandler loop 0-24h; Clot Type 1b, Chandler loop 72h; Clot Type 2a, Static 0-24h; Clot type 2b, Static 72h.

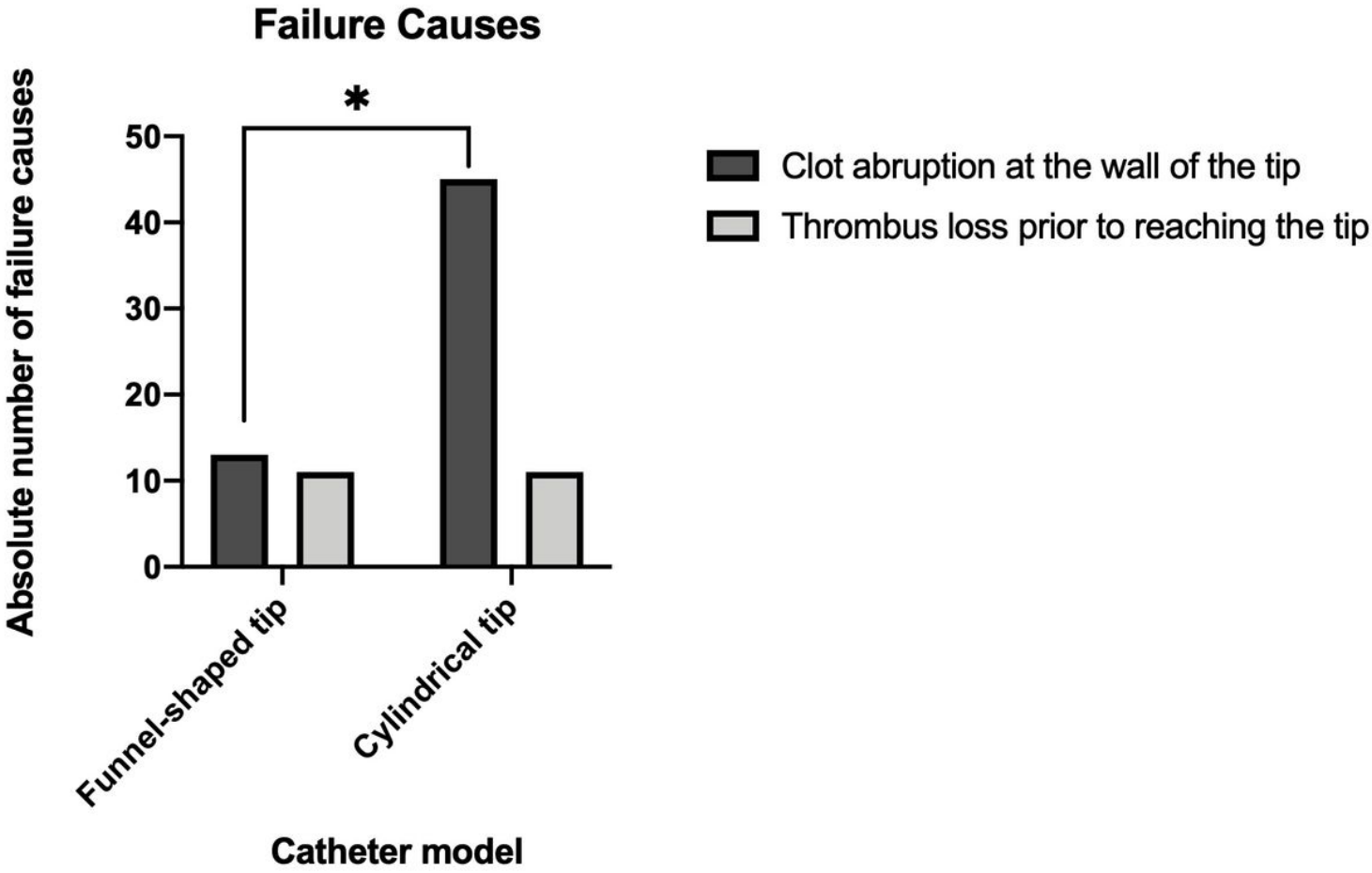

Figure 2

Causes for MT failure for both catheter models (funnel-shaped tip vs. standard tip). The asterix symbols represent the level of significance. (* P < 0.05; ** P < 0.01)

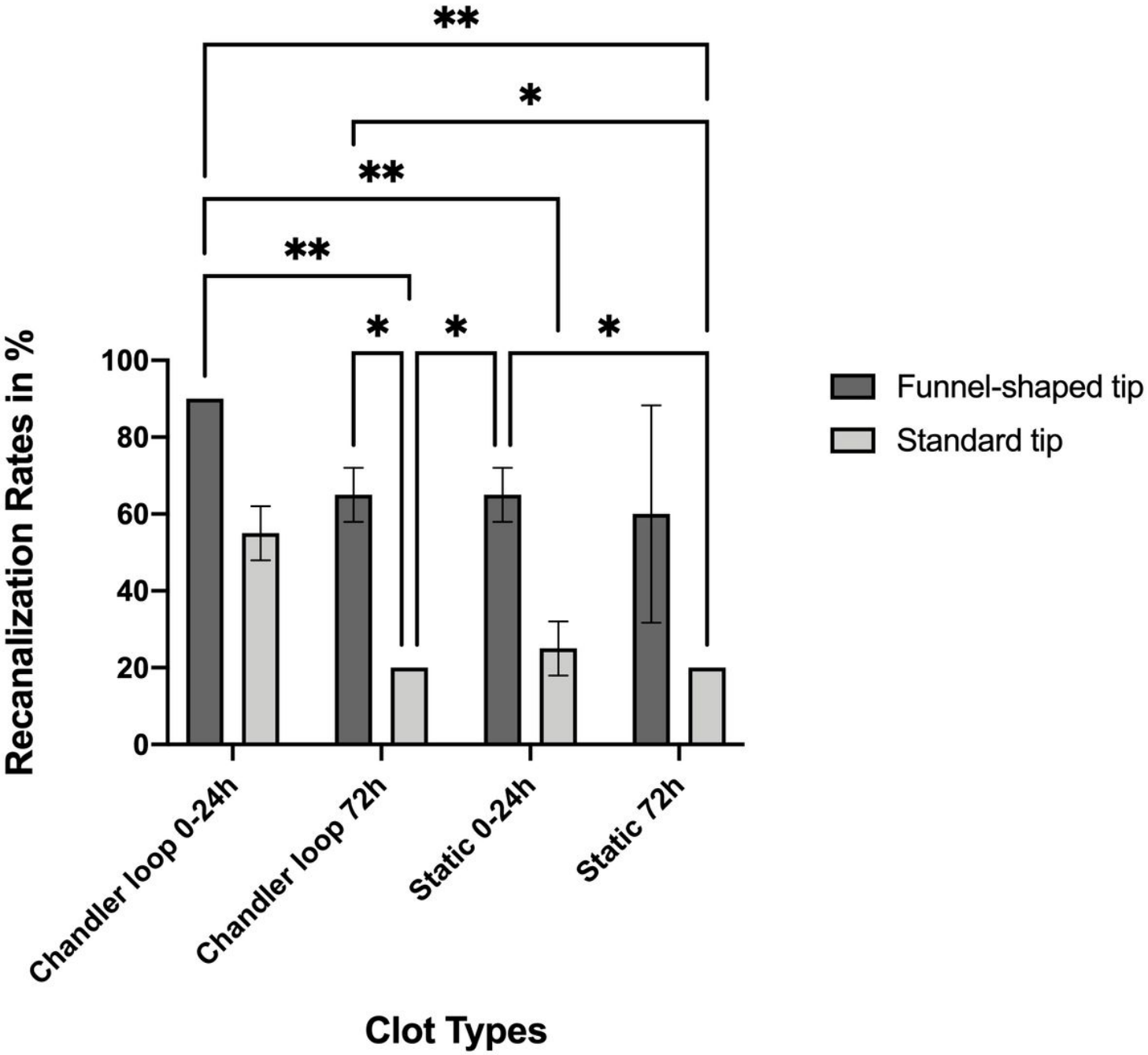

Figure 3

Recanalization rates for four different clot types (Chandler loop 0-24h; Chandler loop 72h; Static 0-24h; Static 72h), (* P < 0.05).

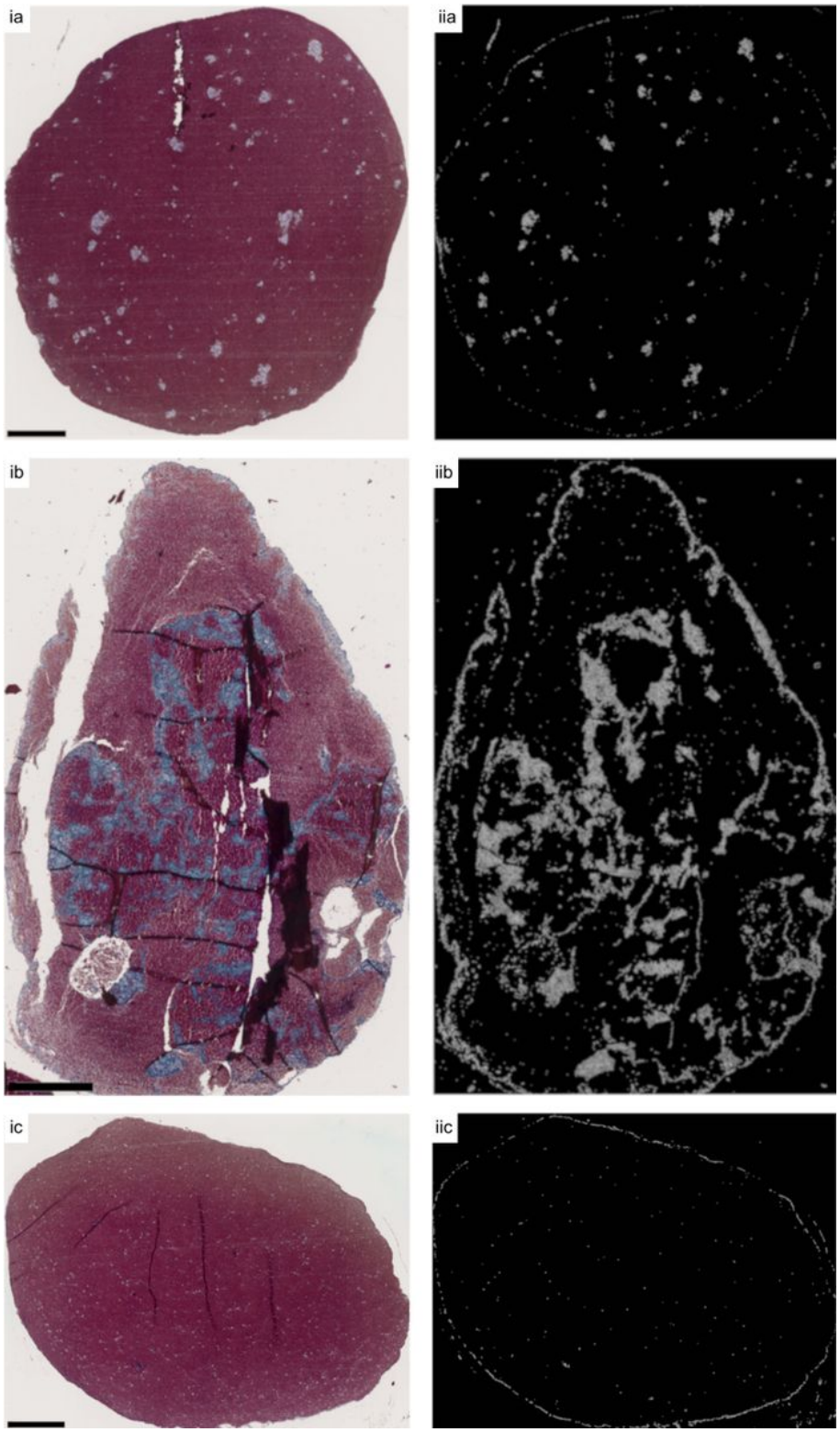

Figure 4

Thrombus before (i) and after (ii) segmentation calculation, grayscale image (ia, ib, ic. Masson-Goldner staining). All scale bars are set to 0.5 mm. a) An example of a Chandler loop 0h thrombus with an insular pattern (i, ii), a peripheral and central distribution of fibrin, and a total circumference of fibrin is demonstrated. b) An example of a Chandler loop 72h thrombus with a reticulated pattern (i, ii), a peripheral and central distribution of fibrin, and a total circumference of fibrin is demonstrated. c) An

example of a 0h thrombus prepared under static conditions with the absence of a fibrin pattern (i, ii) is demonstrated. A total fibrin circumference is lacking. This thrombus type was predominant for the thrombi prepared under static conditions.

Supplementary Files

This is a list of supplementary files associated with this preprint. Click to download.

- Funneltipstatic72hclot1096.mov
- StandardtipChandlerloop72hclot1060.mov
- Supplements.docx