Modified MCL Indentation Technique in Total Knee Arthroplasty With Severe Type II Valgus Deformity

Feng Li
Peking University Third Hospital
Cheng Wang
Peking University Third Hospital
Minwei Zhao
Peking University Third Hospital
Xiao Geng
Peking University Third Hospital
Junyang Li
City University of Hong Kong Shenzhen Research Institute
Ge Zhou
Peking University Third Hospital
Dong Sun
City University of Hong Kong Shenzhen Research Institute
Hua Tian (tianhua@bjmu.edu.cn)
Peking University Third Hospital https://orcid.org/0000-0001-7139-3372

Research article

Keywords: arthroplasty, medial indentation, valgus, constrained condylar knee

Posted Date: January 29th, 2021

DOI: https://doi.org/10.21203/rs.3.rs-154471/v1

Modified MCL indentationtechnique in total knee arthroplasty with severe type II valgus deformity

Feng Li[1#], Cheng Wang[1#], Minwei Zhao[1], Xiao Geng[1], Yangjun Li[2], Ge Zhou[1], Dong Sun[2], Hua Tian[1]*

[1] Peking University Third Hospital, Department of Orthopaedics, No. 49 North Garden Road, Beijing, 100191, China

[2] Centre for Robotics and Automation, Shenzhen Research Institute of City University of Hong Kong, Shenzhen 518057, China

***Corresponding author contact information**

Hua Tian M.D.

Peking University Third Hospital, Department of Orthopaedics

No.49 North Garden Road, Beijing, 100191, China

Office: 86-10-82267010

Email: tianhua@bjmu.edu.cn

Fax: 86-10-82267368

Acknowledgements

Study approval was obtained from the ClinicalTrials and Biomedical Ethics Committee of Hospital, and all participantssigned informed consents for the surgery. F.L. and C.W. contributed equally to this work and should be considered as equal firstauthors.

Conflict of interest

All authors declare that they have no conflict ofinterest or personal relationships with other people or organizationsthat might inappropriately influence this study.

Abstract

Purpose

A modified technique, medial indentation of the medial collateral ligament(MCL),was usedin total kneearthroplastywith severe type II valgus deformity. The study compared the clinical outcomes of the technique relative to conventional release group.

Methods

Consecutive patients with a Krackow type II valgus deformity of >20° who underwent a primary unilateral TKA between May 2008 and June 2017 were retrospectively studied.Modified MCL indentation technique was performed in 20 patients (group A), while the remaining 23 patients (group B) received routine release technique.Radiological parameters, such as the valgus angle (VA), and functional outcomes including the use of constraint implants, Knee Society Score(KSS), Knee Society function score(KSF), and height of the polyethylene insert, were compared between the two groups.

Results

43 consecutive patients had a minimum 2-year follow-up. The preoperative VA was comparable between group A (23.5° ± 5.8°) and group B (21.3° ± 3.2°, P=0.134), so was the postoperative VA (1.1° ± 2.1° and 2.5° ± 3.0°,P=0.084 in groups A and B,

respectively).The postoperative KSS and KSF showedmarked improvement. While no statistically significant difference in preoperative or postoperative functional scores was found between two groups, group A hadthinner PE insert (9.5 ± 1.1 mm vs. 12.9 ± 1.5 mm) and less use of constrained condylar inserts(15% vs. 69.6%).

Conclusion

Modified MCL indentation technique can achieve good outcomes inTKA withtype II valgus deformity of >20°.

Key words: arthroplasty; medial indentation; valgus; constrained condylar knee

Introduction

Approximately 10% of patients with end-stage arthropathy who have undergone total knee arthroplasty have valgusdeformitiesof various degrees[1, 2]. The valgus deformityis often accompanied by structural abnormalities of the bones and soft tissues, including contracture of the posterolateral joint capsule and lateral collateral ligament, relaxation of the medial collateral ligament (MCL), bone defect or dysplasia of the lateral femoral condyle, and bone defect ofthe tibial plateau. Krackow classifiedvalgus into three types, among which type II valgusis defined as combined with medial soft tissue laxity, so the deformities cannot be completely corrected[3]. Treatment of patients with type II valgus is exceptionally challenging. The valgus further aggravates the relaxation of the medial ligaments, especially in patients with severe valgus deformitywith a valgus angle of >20°. Several reconstructive options can be used to address the soft tissue imbalance in patients with severe valgus deformitiestreated with TKA.

The first method is relatively simple and involves extensive release of the lateral structuresto match the medial side. If the medial-lateral balance cannot be achieved, constrained prostheses must be used[4]. The literature reports that although the mid-term clinical outcomes are satisfactory, the incidence rates of prosthesis loosening and instability increase[5]. In addition, comprehensive release of the lateral soft tissue resulted in utilizing thicker polyethylene insert, which would lead to the joint line changing and increase the possibility of common peroneal nerve injury.

Constrained prosthesis would not only increase cost, but make the possible future revision more difficult as well.The second method is the tightened suture of the medial ligament or upward restoration of the MCL tension[6]. However, the knee joint stability after applying this method depends on the healing condition of the MCL itself orits contact surface with bones. Moreover,significant residual valgusalongwith the lower limb's alignment after the operation may aggravate the relaxation of the medial side. Some authors have adopted upward sliding osteotomy of the medial epicondyle. However, the isotonic point of the ligament in flexion-extension gap balancing is not easy to determine during surgery, and the changesin theepicondylar axisof the femur may lead to long-term kinematic changes, so long-term follow-up of outcomes is needed. In addition, the third method is indentationthe insertion point of the MCL *in situ*. Krackow (1990)[7], Whiteside (1993)[8], and Healy (1998)[9] respectively reported this technique. The advantage lies in the indentation of theligament *in situ* without changing the epicondylar axis of the femur, and the lateral release can be reduced.Insert of standard thickness can be used without constrained prostheses, and excellentmid-term clinical outcomes have been achieved in all the cases.However,the cases may be small, with only 6–8 cases, and may have an unstable fixation of the advanced MCL just through making knot，therefore，existing arisk of long-term relaxation of the medial ligament. To optimize the fixation effect, we made some improvements to strengthen the fixation on the medial side.

This study's primary purpose was to investigate the clinical outcomes of the modified technique for medial indentationof the MCL.We hypothesized that for severe type II

valgus deformity, the medial indentationof the MCL with PS arthroplasty would be as effective as routine releasegroup.The modifiedmedial indentation technique can achieve satisfactory mid-termoutcomesand reduce the use of constrained prostheses and thick polyethylene inserts, thus maintaining the normal joint line level.

Materials and Methods

This was a retrospective cohort study.

Eligibility criteria

Patients who had end-stage osteoarthritis of the knee with a Krackow type II valgus deformityof >20°who underwent a primary total knee arthroplasty between May 2008 and June 2017 were considered for enrollment. The type of deformities, that is, the identification of medial laxity, was determined by a physical examination in which a gentle valgus force was manually applied on the knee in 20° flexion. The degree of deformities was measured preoperatively on a standing hip-knee-ankle radiograph. Patients with neuromuscular disorders such as poliomyelitis and those without a minimum 2-year follow-up were excluded as well.

Study items

The baseline demographic information included age, sex, body mass index, diagnosis, and follow-up (Figure 1). Radiographs used in this study included the hip-knee-ankle

anteroposterior (AP) and lateral views, and Merchant patellar view of both knees.Valgus angle (VA) was defined as the angle between the femoral and tibial mechanical axes. The anatomical lateral distal femoral angle（aLDFA） was measured between the femoral anatomical axis and the tangent line of the femoral distal lateral condyle. The anatomical lateral plateau ankle angle（aLTPA） was the angle between the tangent line of the tibial plateau and the tibial anatomical axis[10]. The Insall-Salvati ratio of the knee was defined as described by Meneghini et al., for which a ratio between 0.8 and 1.5 was considered normal[11]. Outcomes were clinically evaluated using the Knee Society score (KSS) and Knee Society functional (KSF) score. Also, the polyethylene insert thickness, constrained implant use, and surgical complications were examined.

Study approval was obtained from the IRB of our hospital (ID:M2017106), and all the participants provided signed informed consent for surgery.

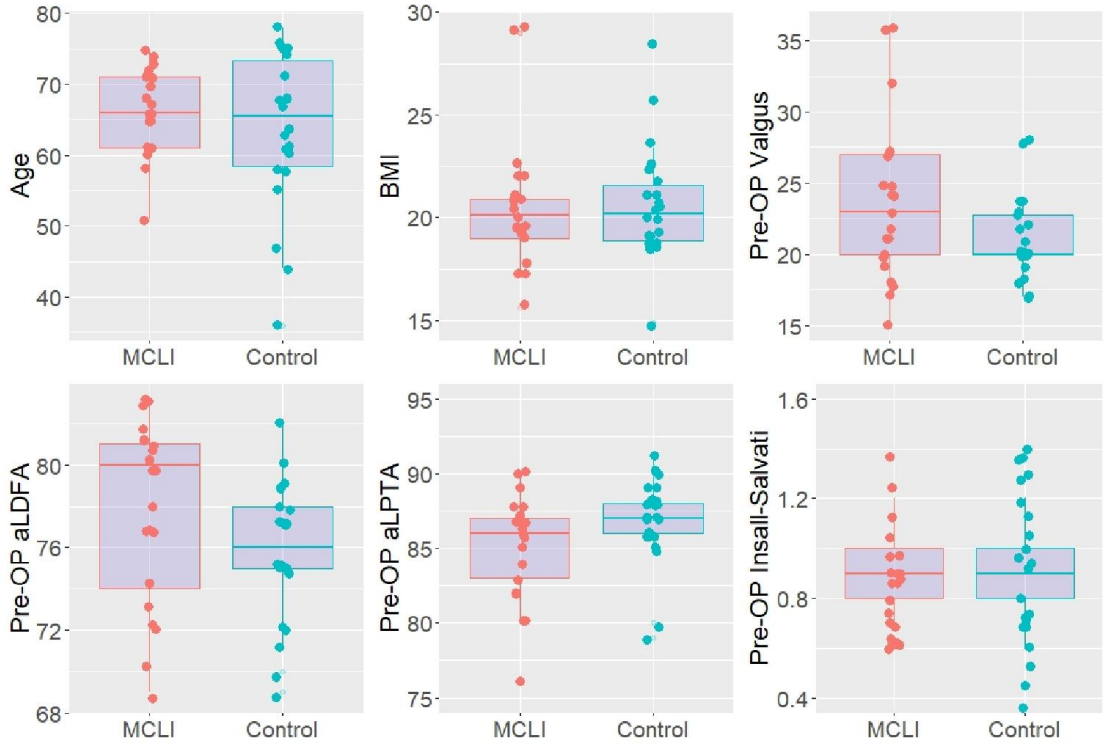

Figure 1 Comparing patient demographics and deformity parameters between patients with and without MCL indentation technique with valgus deformity. The red points represent patients with MCL indentation technique while the light sky blue ones represent those without, both plotted against the boxplot showing the median (the thickened horizontal line) and quartiles of a specific patient characteristic. The difference did not achieve statistical significance.

Patient grouping

The eligible patients were randomly divided into two groups according to the surgical technique used: with (group A) and without (group B) the use of the medial collateral ligament indentation.Two senior surgeons treated the two groupswith similar years of independent practice. For both groups, a posterior stabilized prosthesis was used.

Operative procedure

Through an anterior midline incision, the medial parapatellar approach was used to access the joint space of the knee and remove both the anterior and posterior cruciate ligaments. Bone resections were then performedon the femoral and tibial sides. The tibial surface was cutted using an extramedullary guide with a 3° posterior tibial slope. The distal femoral surface was resected using an intramedullary guide, and the cut was set in the coronal plane, at a valgus angle accordingto the one between the mechanical and anatomical axes of the femur. Excessive osteophytes on the lateral and posterior sides of the femoral condyle were removed. The size of the femoral component was determined by posterior referencing. A 4-in-1 osteotomy was then performed with the rotation being determined by the Whiteside line and epicondylar axis. A spacer was then used to measure the joint gap in knee flexion and extension.

Medial indentation group (group A):

(1) A preliminary limited lateral soft tissue release was performed, including the iliotibial band and posterolateral joint capsule, to the extent that the lateral space could accommodate the thinnest polyethylene insert (Figure 2).

(2) The attachment of the MCL at the medial epicondyle was exposed. After drilling with a Kirschner wire, a miniature pendulum saw was used to open a window (1.2×1.0 cm^2) on the bone at the attachment point of MCL. An embedment device was used to press the cancellous bone inward. A number 5 non-absorbable suture was used for the braided suture of the MCL and then passed through the bone

block with a window opening. A guide needle with wire was used to lead the suture thread out of the lateral epicondyle of the femur. The two needle-withdrawing points were 1 cm apart. The trial component was placed. The knee joint was flexed by 30°, and the suture thread was tightened and tied for fixation (Figure 2)[9].

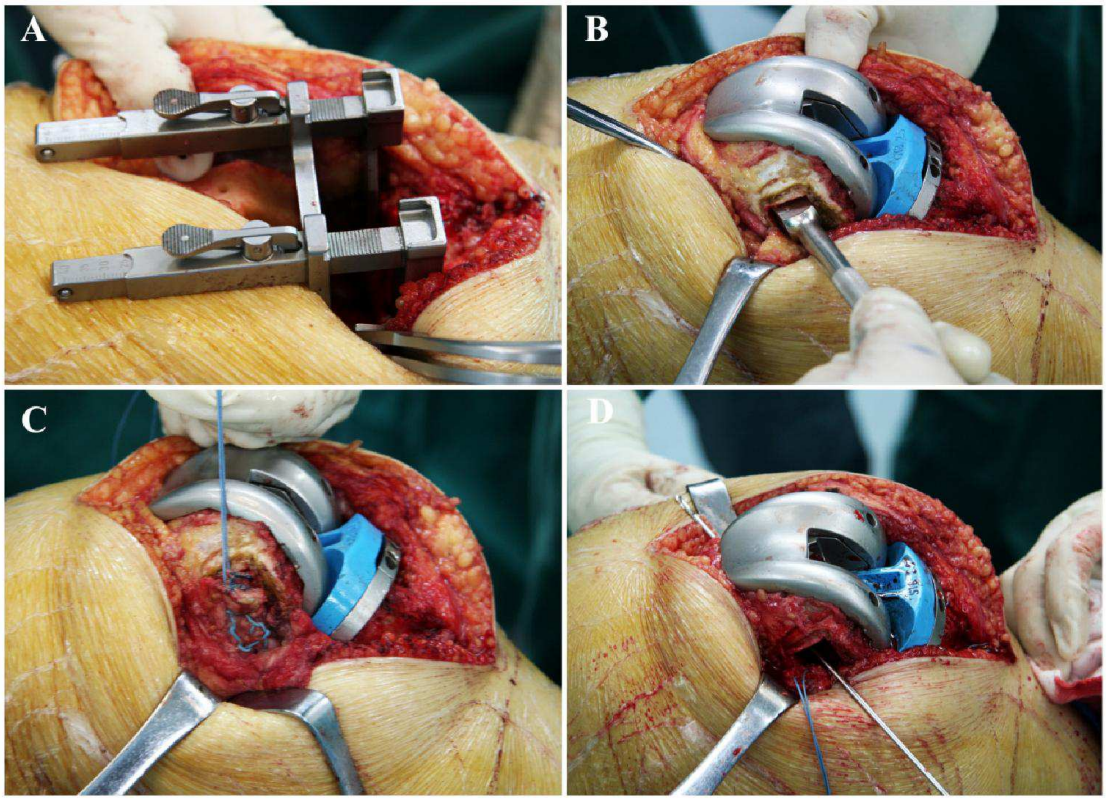

Figure 2 Intra-operative photos were showing the MCL indentation technique. (A) Apparent relaxation of the medial side of the knee after the tensor was stretched. (B) An embedment device was used to press the cancellous bone inward. (C) A number 5 non-absorbable suture was used for the braided suture of the MCL. (D) A guide needle with wire was used to lead the suture thread out of the lateral epicondyle of the femur.

(3) An interference screw (9mm×2.5 cm) was applied to strengthen the fixation at the window opening, a cortical bone screw was drilled into the external epicondyle of the femur, and suture thread was fixed on the bolt at its tail end (Figure 3).

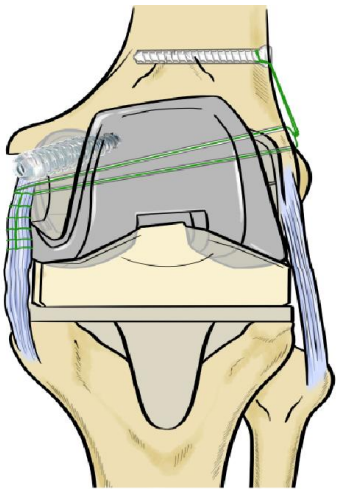

Figure 3. A schematic diagram of MCL indentation technique. Both needle-withdrawing points were 1 cm apart, and also the suture thread was tightened and tied for fixation. A cortical bone screw was drilled right into the outside epicondyle of the femur, and stitch thread was fixed on the bolt at its tail end. An interference screwwas applied to strengthen the fixation at the window opening.

Routine release group (group B):

When the lateral structures were tight in knee extension only, we first released the iliotibial band subperiosteally from Gerdy's tubercle or using the "pie-crusting" technique. For Krackow type II valgus patients, only ITB release or resection was not enough, comprehensive releases of the posterolateral joint capsule,popliteus tendon and LCL were usually needed using the inside-out pie-crusting technique.The stability was evaluated at 0° extension, mid-flexion (30°–40°), and 90° flexion to determine

the type of insert needed.Aconstrained condylar knee (CCK) component was used when the knee was unstable, with a mediolateral gap asymmetry of >3mm,in any of the positions. If the medial and lateral sides reached a balance, PS polyethyleneinsertcould be used.

The residual tibial plateau or femoral condyle bone defects after osteotomy during the operation were repaired using the following method: containedbone defects with a depth of <5 mm were filled with bone cement, or cancellous bone particles prepared from tibial or femoral osteotomy blocks. Cases requiring repair with metal augmentationfor severe bone defects of the lateral femoral condyle were not included in this group. In the case of lateral tilting or subluxation of the patella during the operation, the femoral transepicondylar axis was taken as a reference to increase the femoral external rotation angle for osteotomy and release the lateral retinaculum of the patella. If the patella was severely worn, routine patella replacement was performed. However, if the patient's patella was small and accompanied by bone loss, routine patella replacement would not be performed. Osteophytes around the patella should be removed, the patella cartilage surface should be trimmed with a pendulum saw, and the patella periphery should be thermally ablated, encirclingthe site,for denervation. Then, the patellar track should be detected using the no-thumb test.

Postoperative management

The drainage was withdrawn within 24 hours postoperatively. Low-molecular-weight heparin and foot-pump system were used to prevent deep vein thrombosis. The

patients were immediately instructed to start static quadriceps and flexion-extension exercises. After drainage removal, the patients (Group A) were advised to perform active knee extension and straight-leg raise exercises with caution and then walkwith the toes touch or partial weight-bearingwith a long-leg knee brace removed after six weeks postoperatively.

Outcome evaluation

Surgical outcomes were evaluated clinically andradiologically, and compared between before operation, three months after the operation, 1 year after operation, and then annually thereafter.

Statistical analyses

The SPSS25.0 software was utilized for the statistical analysis. Measurement data conforming to a normal distribution are expressed as mean±standard deviation, a paired-samples*t*-test was used for intergroup comparison, and enumeration dataare expressed as rates. The difference was statistically significant whenthe P-value was <0.05.

Results

Clinical Outcomes

The knees of all the patients in both groups were type II, according to Krackow's classification, indicating a severe valgus deformity. Patients' radiological parameters

preoperatively and at final follow-ups were listed in Table 1.The mean VA in group A was 23.5° ± 5.8°,while the mean VA in group B was 21.3° ± 3.2°(t=1.528, P=0.134). Postoperatively,the mean VAs in groups A and B were 1.1° ± 2.1° and 2.5° ± 3.0°(t=-1.768, P=0.084), respectively.

Table 1 Comparison of several angles by radiography preoperatively and postoperatively

Total patients(no=43)	Group A(no=20) mean±SD	Group B(no=23) mean±SD	*T value*	*P*-value
Valgus Pre-Op(degree)	23.5±5.8	21.3±3.2	1.528	0.134
Valgus Post-Op (degree)	1.1±2.1	2.5±3.0	-1.768	0.084
aLDFA Pre-Op (degree)	78.0±4.5	75.7±3.3	1.931	0.06
aLDFA Post-Op (degree)	85.4±2.0	82.9±2.8	3.252	0.02
aLPTA Pre-Op (degree)	85.4±3.6	86.6±2.9	-1.204	0.236
aLPTA Post-Op (degree)	89.9±3.5	89.0±2.8	0.984	0.331
Insall-Salvati ratio Pre-Op	0.9±0.1	0.9±0.2	0.112	0.911
Insall-Salvati ratio Post-Op	0.9±0.1	0.8±0.1	0.839	0.407
PE(mm)	9.5±1.1	12.9±1.5	-3.028	0.02

aLDFA, anatomical lateral distal femoral angle;aLPTA, anatomical lateral plateau ankle angle; PE,polyethylene

In group A, 20 knees received a PS implant, including Genesis II in 9 cases, A3 Knee (AK Medical, China) in 8 cases, Depuy-PFC in 2 cases, and Aesculap (Germany) in 1 case. The mean polyethylene thickness was9.5 ± 1.1 mm. Constrained condylar inserts were used for three patients (15%).

In group B, all the surgeries used posterior-stabilized prostheses, including GenesisII (Smith & Nephew, Memphis, TN) in 16 cases, Legion (Smith & Nephew, Memphis, TN) in 4 cases, Vanguard (Vanguard, Complete Knee System, Biomet, Inc, Warsaw, IN, USA) in 2 cases, and A3 Knee (AK Medical, China) in 1 case. The mean polyethylene thickness was 12.9±1.5 mm.Constrained condylar inserts were used for 16 cases (69.6%).

The mean follow-up period was 62.4 months. Preoperatively and at the last follow-up, the Knee Society score (KSS), Knee Society function score(KSF) were obtained. The deformity was significantly improved, and the pain was significantly relieved in all the patients. The mean KSS and KSF score in group A were 30.2 ± 4.8 and 38.8 ± 4.8before the operation, respectively, and increased to 91.3 ± 2.6 and 86.5 ± 2.4 at the last follow-up, respectively.The mean KSS and KSF score in group B were respectively 31.5±7.5 and 36.5±7.8 before the operationand92.4±3.5 and88.5±3.6at the last follow-up.However, no statistically significant difference in preoperative or postoperative functional scores was foundbetween the two groups (Figure 4).

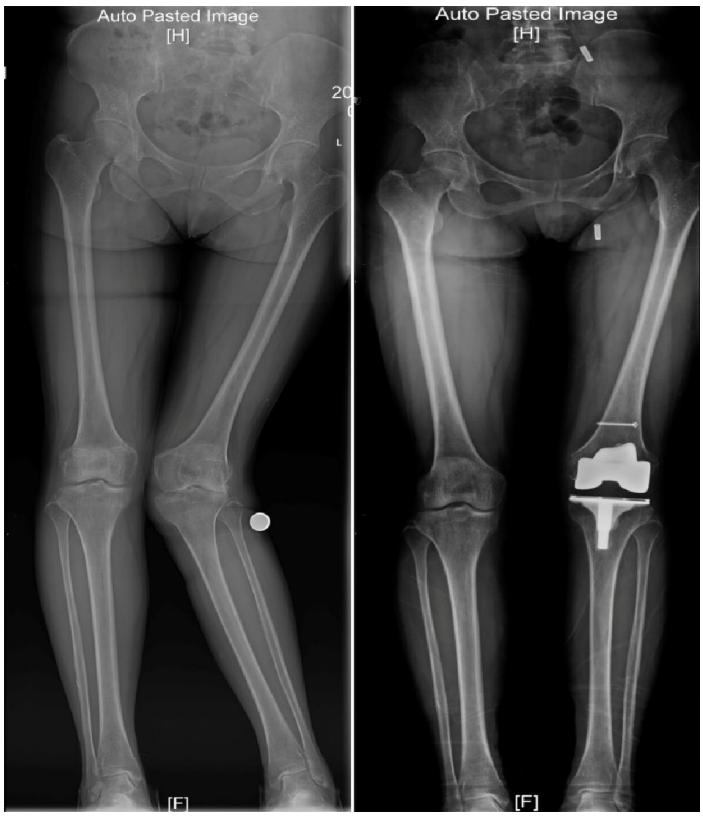

Figure 4. An illustrative case (Case #1). A 51-year-old woman diagnosed with rheumatoid arthritis underwent TKA using the MCL indentation technique. On the radiograph obtained two years postoperatively, the VA was improved from 36 to 3°, and PE thickness was 11mm. According to the clinical notes, she did not have any complications and, at the follow-up, said that she was delighted with surgery.

Complications

The complications of TKA were recorded in detail. One patient in the routine release group had the common peroneal nerve paralysis after the operation, decreased skin sensation on the dorsum pedis, and inability to perform ankle joint dorsiflexion. This might be related to the nerve traction after valgus correction and nerve traction injury caused by seed bone removal during operation. No special treatment was given, and the symptoms disappeared three months after the operation. One patient developed

knee joint dislocation at 30 days after the operation and underwent revision with a thickened polyethylene insert. One patient had a periprosthetic fracture due to trauma one year after the operation and underwentinternal fixation. In the medial indentation group, one patient hadmedial knee joint instability, and the medial laxity exceeded 4mm during the valgus stress test. Considering that the MCL function was weakened, knee braceswere provided for protection, and the symptoms disappeared after three months. No complications such as infections, prosthesis loosening, and pulmonary embolism occurred during the follow-up period.

Discussion

The most important finding of this study is that for type II valgus with severe medial laxity, the MCL indentation technique is a safe and effective treatment method that can achieve satisfactory functions and maintain normal joint line level and reduce the use of CCK prostheses. Compared with the conventional operation group, the medial indentation group showed no statistically significant differences in KSS and KSF scores, with thinner polyethylene inserts, and had no common peroneal nerve paralysis. CCK inserts were used in asmaller proportion of patients in the medial indentation group than inthe conventional operation group(15% vs. 69.6%).

At present, no consensus has been reached on the treatment of type II valgus deformity[12, 13]. Compared with that on the medial side of the knee, the controllability of the release on the lateral side of the knee is imperfect, owing to the lack of soft tissue sleeve. The extensive lateral release may lengthen the lateral

structure, which will increase the risk of common peroneal nerve paralysis. A larger joint space will require thicker polyethylene, and a lower joint line will cause patella baja[14]. If the medial-lateral balance cannot be reached, instability on the medial side will often occur after surgery. If the correction is insufficient, residual valgus may also gradually aggravate the relaxation on the medial side[15]. Some authors believed that constrained condylar prostheses could well avoid this problem. However, the CCK prosthesis is semi-constrained[16, 17]. The interface between the prosthesis and the bone cement bears great stress, and its postoperative loosening rate is high[18]. Pour et al. believed that the use of higher constrained prostheses such as hinged knees is associated with a high revision rate and relatively large bone defects during revision, which makesthe revision surgery difficult[19].

Reconstruction of the relaxed medial side is another option. Some authors considered folding the MCL or moving up its attachment point, but the stability of the knee joint after applying it depends on the healing of the MCL[6]. Moreover, if significantresidual valgusoccurs, it may aggravate the laxityon the medial side. The method of MCL indentation used in our research was first proposed by Krackow[3] andreported by Healy[9]and Whiteside[8]. Whiteside applied the MCL advancement method in 6 cases of valgusof >25°. He believed that more bone in the distal femur would be cut off for the genicular lateral space to accommodate the prosthesis,and relaxation on the medial side will also increase. After theMCL indentation technique was applied, a 6-year follow-up did not show valgus recurrence orligament relaxation. Healy reported the outcomes of 8 cases of type II valgusfor whomMCL reconstruction

was performed, with a mean valgus angle of 22.4°, usinga cruciate retaining prosthesis (CR) in 7 cases and a posterior stabilized prosthesis (PS)in 1 case, all without a constrained prosthesis. After a mean follow-up period of 5.88 years, the valgus angle was corrected to a mean of 5.4°. Despite some residual valgus, all the patients had no residual medial relaxation. None of the patients had a significant change in the patellar position or tibiofemoral joint line, as measured by the Insall-Salvati ratio technique on lateral radiographs. Healy used non-absorbable sutures to fix the MCL during the operation. Based on Healy's method, we added interference screwto the medial femoral condyle, while bolts of cortical bone screws were added tothe lateral femoral condyle at the tail end of the suture. Thereby, the effect of multiple fixations can be achieved while reducing the adverse effects caused by suture breakage.

The advantages of MCL indentation include the unchanged position of the femur's epicondylar axis, limited release of lateral structures, the stabilization of the flexion-extensiongap, and the use of an insert of standard thickness, with which the original joint line can be maintained.If the medial and lateral sides reach a balance, the probability of using CCK will be decreased. The risk of common peroneal nerve injury is correspondingly reduced when the lateral release range is decreased. In this group of cases, nocases of common peroneal nerve paralysis were found, while one occurred in the control group. A bone-to-bone contact surface was attained with good bone healing potential after the medial ligament was tightened. The critical points of this technology are as follows: Carefully dissect theattachmentof the MCL, separate

the bone blocks at the endpoint of the MCL using a miniature electric saw, and separate the two guide pins of the femoral condyle by 1cm to avoid cutting osteoporotic bone by the suture thread. Among the patients, one still had significant medial relaxation at six weeks after the operation and continued wearing brace protection for three months. This experience implies that if the overall lower limb alignment is corrected satisfactorily after the TKA and reached the neutral position, the relaxed medial ligament would gradually contract, and the instability would be improved accordingly.

Although this study is by far the largest cohort reported using this method, it still has some limitations, including the small number of cases and its retrospective nature. If themodified medial indentation technique is used,patients must wear braces for six weeks after surgery so that the recovery rate will slow down. However, for cases with a ruptured MCL or an accidental injury of the lateral collateral ligament during operation, this technique is not suitable, and the constrained prosthesis is still an effective rescuetreatment in such cases[20].

Acknowledgements

Study approval was obtained from the ClinicalTrials and Biomedical Ethics Committee of Hospital, and all participantssigned informed consents for the surgery. F.L. and C.W. contributed equally to this work and should be considered as equal firstauthors.

Authors' contributions

HT designed this study. CW，GZ and HT collected the data. MW Z, DS, JY L and XG analyzed the data. FL and CW was the major contributor in writing the manuscript. All authors read and approved the final manuscript

Funding Statement

This work was supported by grants from the National Natural Science Foundation of China(81572148, 82001481, U20A20194). Beijing Science and Technology Program (D171100003217001, 19L2067). Key Clinical Projects of Peking University Third Hospital (No.BYSYZD2019037). Bethune Charitable Foundation (G-X-2019-1107-8)

Consent for publication

Not applicable.

Competing interests

The authors declare that they have no competing interests.

References

1. Ranawat, A.S., et al., *Total knee arthroplasty for severe valgus deformity.* J Bone Joint Surg Am, 2005. **87 Suppl 1**(Pt 2): p. 271-84.
2. Lange, J. and S.B. Haas, *Correcting severe valgus deformity: taking out the knock.* Bone Joint J, 2017. **99-B**(1 Supple A): p. 60-64.
3. Krackow, K.A., et al., *Primary total knee arthroplasty in patients with fixed valgus deformity.* Clin Orthop Relat Res, 1991(273): p. 9-18.
4. Williot, A., et al., *Total knee arthroplasty in valgus knee.* Orthop Traumatol Surg Res, 2010.
5. Li, F., et al., *Abnormally high dislocation rate following constrained condylar knee arthroplasty for valgus knee: a case-control study.* J Orthop Surg Res, 2019. **14**(1): p. 268.
6. Mou, P., et al., *The Effectiveness of Medial Femoral Epicondyle Up-Sliding Osteotomy to Correct Severe Valgus Deformity in Primary Total Knee Arthroplasty.* J Arthroplasty, 2018. **33**(9): p. 2868-2874.
7. Krackow, K.A., *The technique of total knee arthroplasty.* 1990, St. Louis: C.V. Mosby Co. xi, 440 p.
8. Whiteside, L.A., *Correction of ligament and bone defects in total arthroplasty of the*

severely valgus knee. Clin Orthop Relat Res, 1993(288): p. 234-45.

9. Healy, W.L., R. Iorio, and D.W. Lemos, *Medial reconstruction during total knee arthroplasty for severe valgus deformity.* Clin Orthop Relat Res, 1998(356): p. 161-9.
10. Brinkman, J.M., et al., *Osteotomies around the knee: patient selection, stability of fixation and bone healing in high tibial osteotomies.* J Bone Joint Surg Br, 2008. **90**(12): p. 1548-57.
11. Meneghini, R.M., et al., *The effect of the Insall-Salvati ratio on outcome after total knee arthroplasty.* J Arthroplasty, 2006. **21**(6 Suppl 2): p. 116-20.
12. Li, F., et al., *Lateral femoral sliding osteotomy in total knee arthroplasty with valgus deformity greater than twenty degrees.* Int Orthop, 2019. **43**(11): p. 2511-2517.
13. Matar, H.E., et al., *High Medium-Term Survivorship of Cruciate-Retaining Total Knee Arthroplasties (110 Knees) for Valgus Deformity.* J Knee Surg, 2019.
14. Pang, H.N., et al., *Joint line changes and outcomes in constrained versus unconstrained total knee arthroplasty for the type II valgus knee.* Knee Surg Sports Traumatol Arthrosc, 2013. **21**(10): p. 2363-9.
15. Whiteside, L.A., *Selective ligament release in total knee arthroplasty of the knee in valgus.* Clin Orthop Relat Res, 1999(367): p. 130-40.
16. Ang, C.L., et al., *Unconstrained arthroplasty in type II valgus knees: posterior stabilized or cruciate retaining?* Knee Surg Sports Traumatol Arthrosc, 2014. **22**(3): p. 666-73.
17. Siqueira, M.B.P., et al., *The Varus-Valgus Constrained Knee Implant: Survivorship and Outcomes.* J Knee Surg, 2017. **30**(5): p. 484-492.
18. Easley, M.E., et al., *Primary constrained condylar knee arthroplasty for the arthritic valgus knee.* Clin Orthop Relat Res, 2000(380): p. 58-64.
19. Pour, A.E., et al., *Rotating hinged total knee replacement: use with caution.* J Bone Joint Surg Am, 2007. **89**(8): p. 1735-41.
20. Abdel, M.P. and S.B. Haas, *The unstable knee: wobble and buckle.* Bone Joint J, 2014. **96-B**(11 Supple A): p. 112-4.

Figures

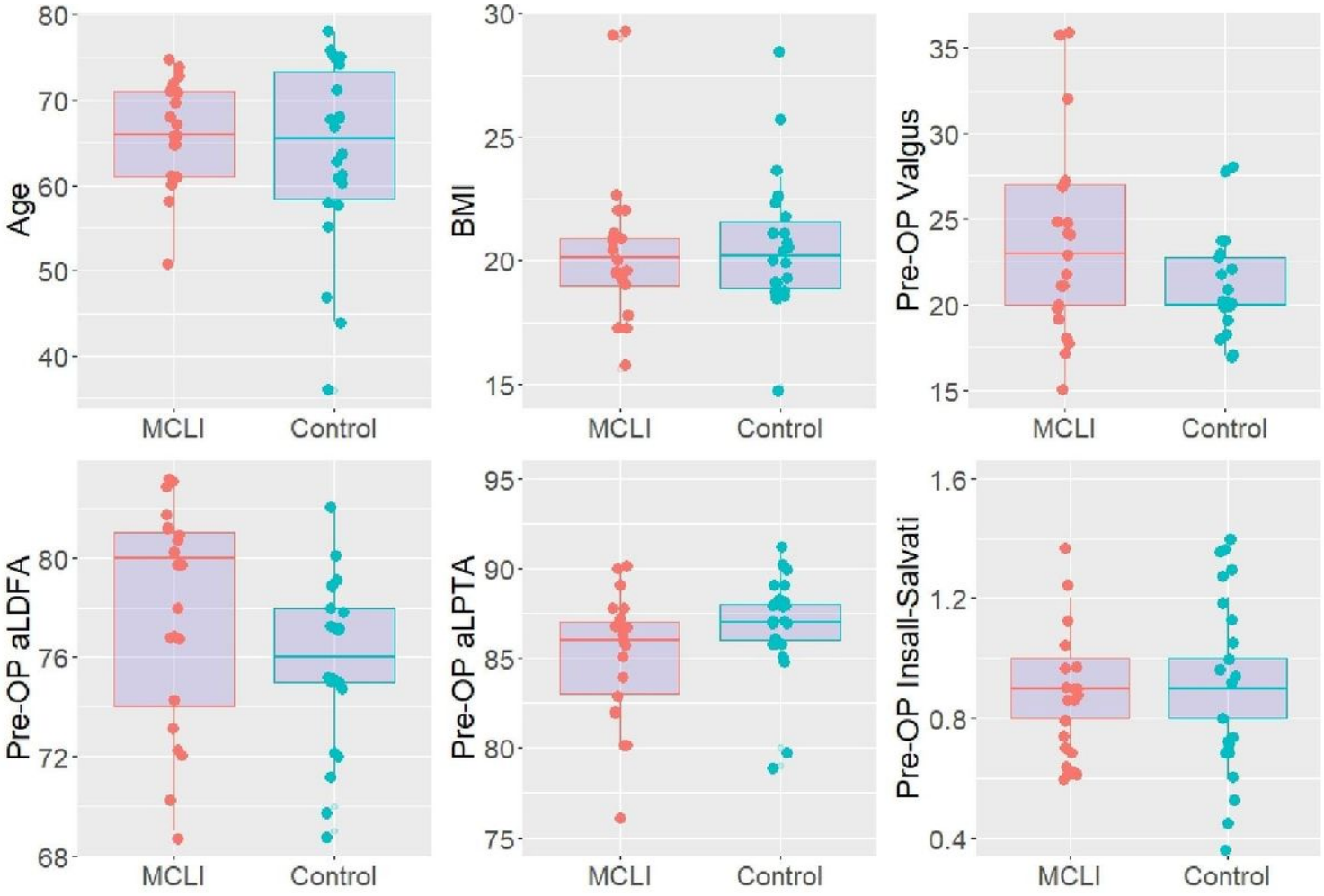

Figure 1

Comparing patient demographics and deformity parameters between patients with and without MCL indentation technique with valgus deformity. The red points represent patients with MCL indentation technique while the light sky blue ones represent those without, both plotted against the boxplot showing the median (the thickened horizontal line) and quartiles of a specific patient characteristic. The difference did not achieve statistical significance.

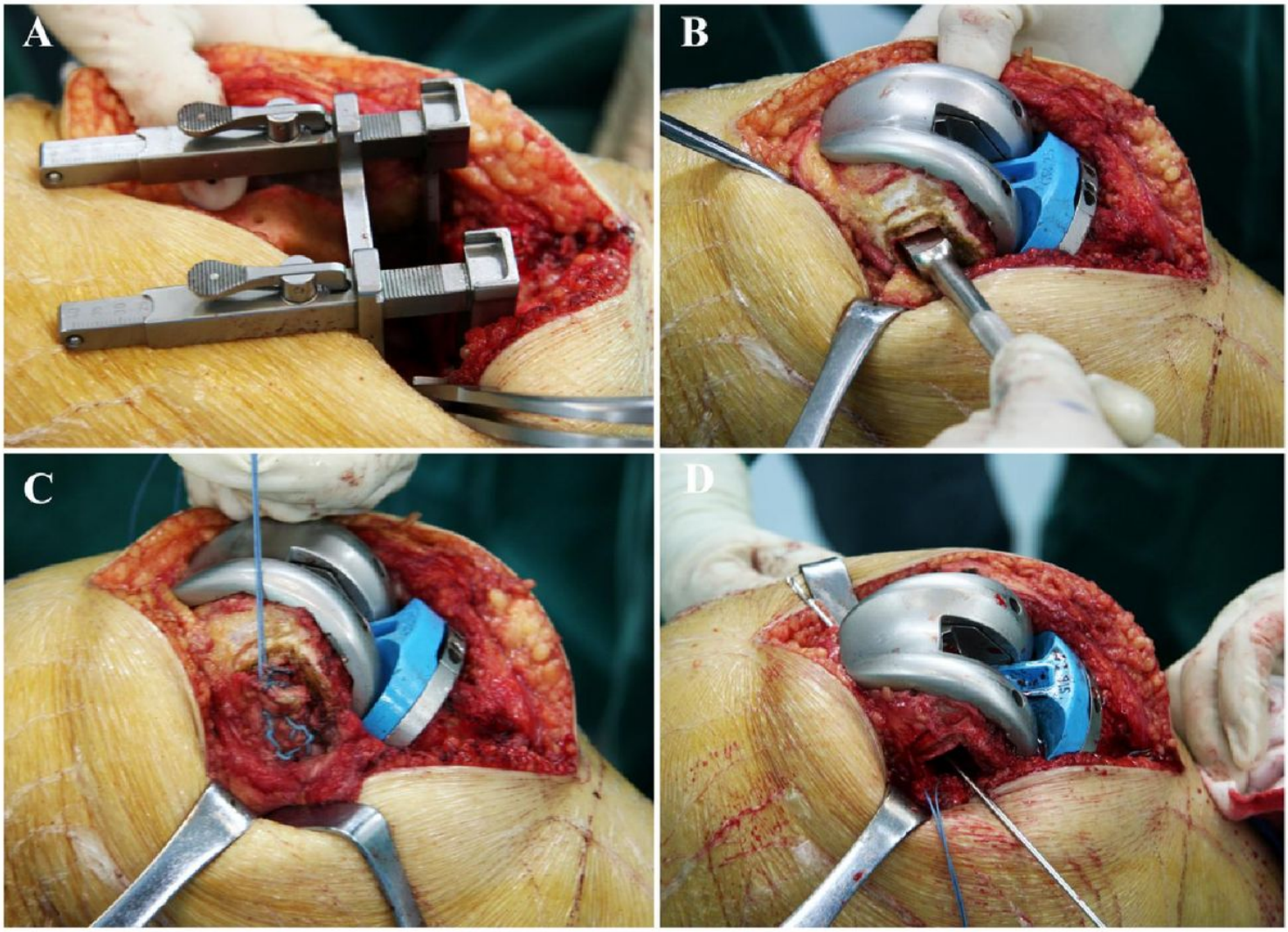

Figure 2

Intra-operative photos were showing the MCL indentation technique. (A) Apparent relaxation of the medial side of the knee after the tensor was stretched. (B) An embedment device was used to press the cancellous bone inward. (C) A number 5 non-absorbable suture was used for the braided suture of the MCL. (D) A guide needle with wire was used to lead the suture thread out of the lateral epicondyle of the femur.

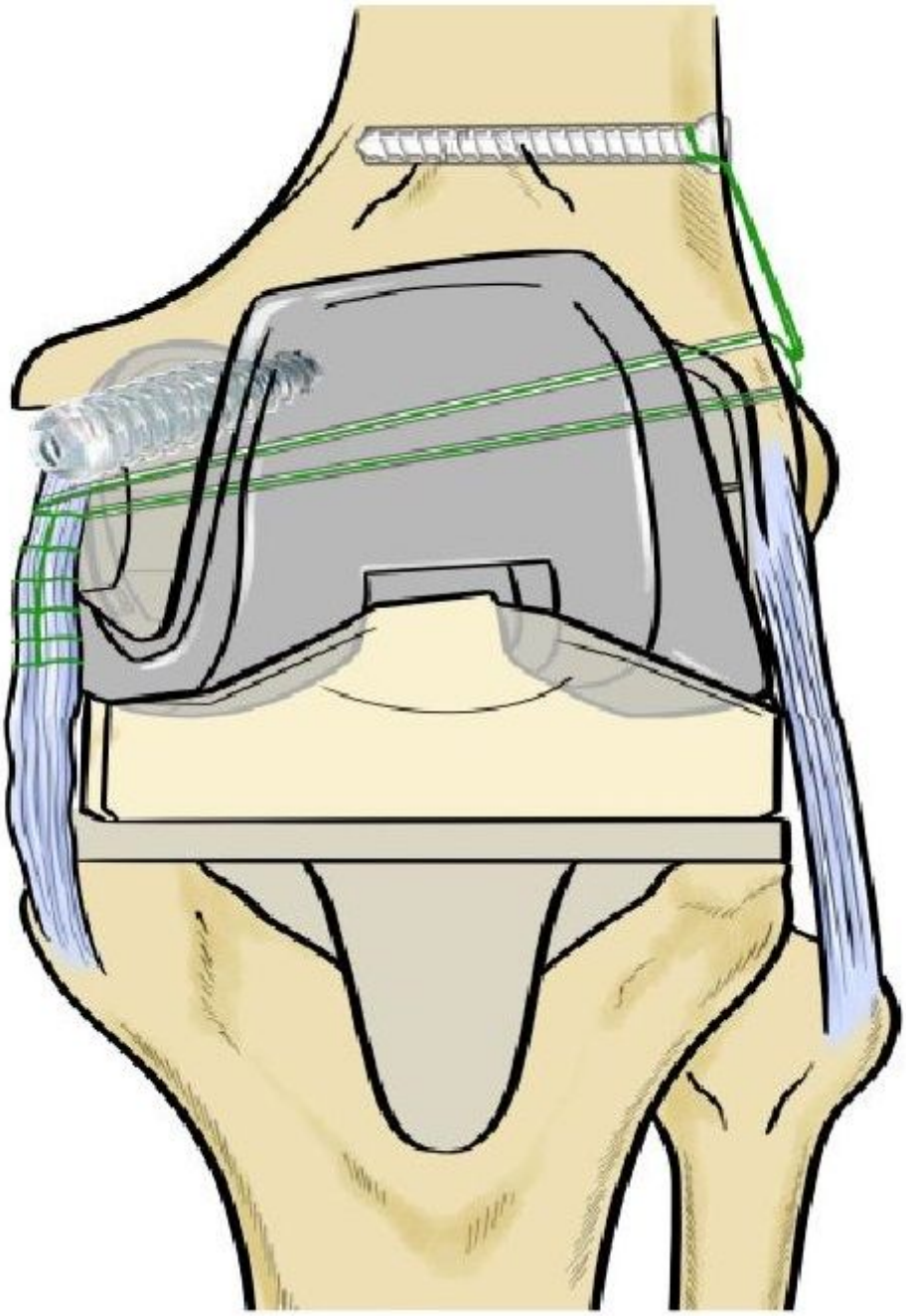

Figure 3

A schematic diagram of MCL indentation technique. Both needle withdrawing points were 1 cm apart, and also the suture thread was tightened and tied for fixation. A cortical bone screw was drilled right into the outside epicondyle of the femur, and stitch thread was fixed on the bolt at its tail end. An interference screw was applied to strengthen the fixation at the window opening.

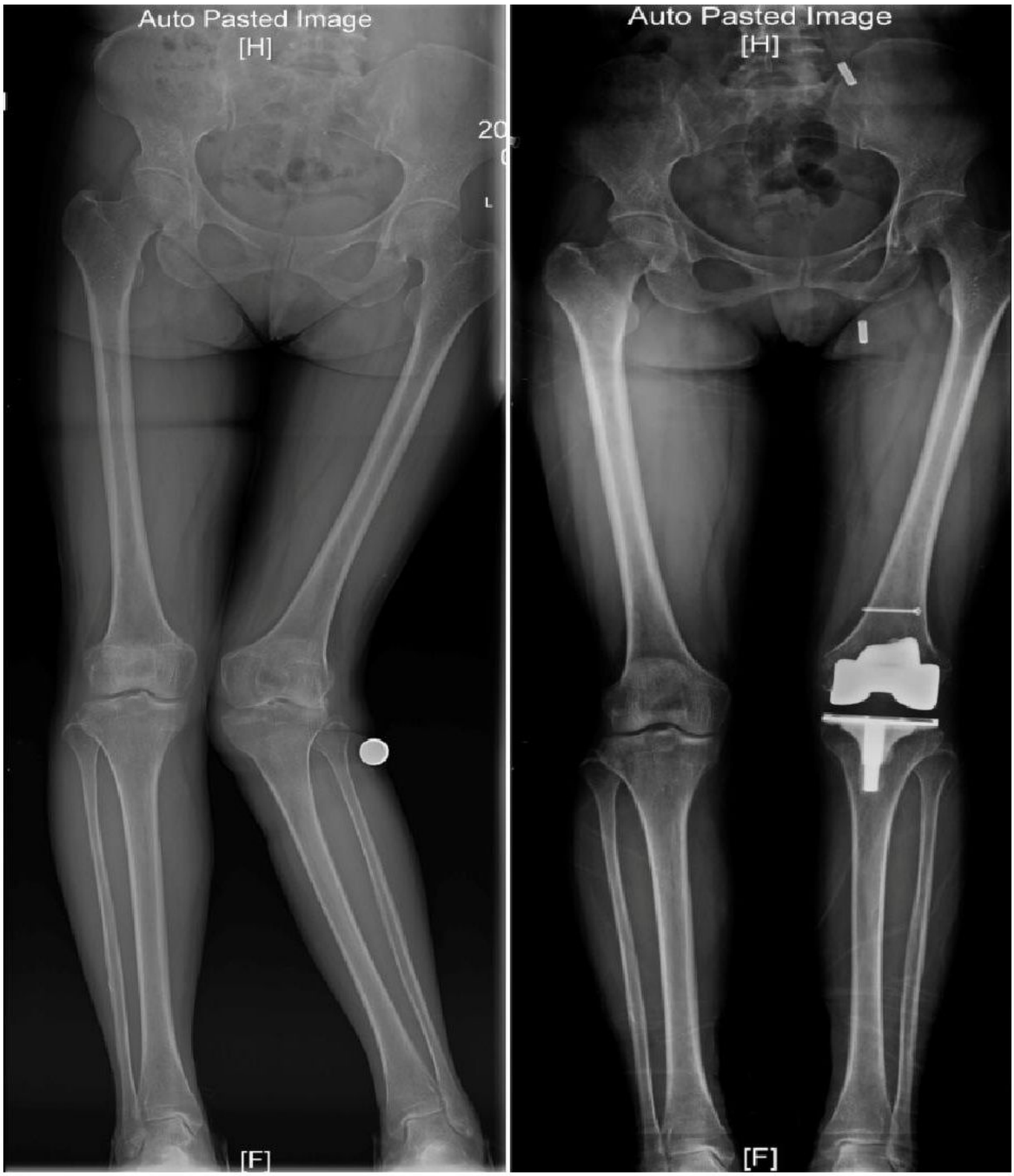

Figure 4

An illustrative case (Case #1). A 51-year-old woman diagnosed with rheumatoid arthritis underwent TKA using the MCL indentation technique. On the radiograph obtained two years postoperatively, the VA was improved from 36 to 3°, and PE thickness was 11mm. According to the clinical notes, she did not have any complications and, at the follow-up, said that she was delighted with surgery.