Clinical application and anatomical study of Arterio-Venolization in Replantation of the Severed Fingers

chen yun
Third Affiliated Hospital of Southern Medical University
li yanbin
Southern Medical University
wang zemin
Loudi Central Hospital
liu chang
Beijing Jishuitan Hospital
sun yongjian
Third Affiliated Hospital of Southern Medical University
cai daozhang
Third Affiliated Hospital of Southern Medical University
yao jinghui (7056452@qq.com)
Third Affiliated Hospital of Southern Medical University

Research Article

Keywords: Severed fingers, Venous anastomosis conditions, Arterio-Venolization, Super microsurgery, Replantation of amputated finger

Posted Date: April 14th, 2022

DOI: https://doi.org/10.21203/rs.3.rs-1548699/v1

Abstract

Objective To investigate the feasibility of arteriovenous operation in the replantation of the severed finger.

Methods 65 patients with distal finger segment disjunction admitted from January 2014 to August 2021 were selected. According to the severity of finger injury, existing blood vessels and soft tissue conditions of the patients, the vascular anastomosis was determined, and they were grouped according to different blood vessel merging methods. Clinical comparison of postoperative effects between group A (12 cases of arterio-venolization replantation fingers) and group B, C and D (25 cases, 9 cases, 19 cases). After 1 to 7 years of follow-up and study. Meanwhile,In January 2022, ten isolated finger specimens were collected.The vascular routes and distribution were analyzed under the microscope, and the relationship between the arteriovenous arch and the body surface location markers was defined. The preferred vascular path of arterio-venolization was confirmed again.

Results There were no significant differences in survival rate, length of hospital stay,the number of vascular crisis and skin necrosis between group A and B ($P > 0.05$). However,the length of hospital stay, the rate of partial skin necrosis and the incidence of vascular crisis in group C and D were higher than those in group A and B, and the survival rate of replantation finger was lower than that in group A and B ($P < 0.05$). In the anatomy process of the finger specimens, it was found that the nail base line was clearly and accurately used as the body surface positioning mark. There were a variety of arterio-venolization surgery options as the blood flow artery and the vein with a better match. The veins with a diameter of about 0.3-0.5mm on the lateral side of the non-dominant lateral nail groove of the proximal finger were preferred as the docking vessels. The distal artery was anastomosed with the proximal vein by super microscopic technique, and the anastomosis with the normal artery-to-artery on the other side formed a closed blood flow loop.

Conclusion With no vein anastomosis, the treatment of distal finger amputation with super micro combined with arterio-venolizationis is convenient, safe and effective.

Introduction

The end of the finger is a special part of the finger, and its function and appearance may be affected after it is broken. It is very essential to carry out the replantation of the finger end in a timely manner[1]. However, replantation of the severed finger at the end of the finger is one of the most difficult operations in hand surgery, and the operation will be more difficult for young children who have not encountered the severed finger without venous anastomosis. In addition, even experienced hand microsurgeons and pediatric orthopedics still cannot solve the problems of difficulty in matching the veins and blood vessels and the high incidence of postoperative venous crises [2]. Therefore, more doctors will choose to abandon the replantation of the severed finger and perform stump trimming or skin flap repair, but this will cause the finger to become shorter and lose part of its function and beauty. In addition, the venous network near the fingertips at the distal end of the fingertip is usually very thin [3]. If the finger is cut off

and close to the methylation or oblique injury occurs, the distal end of the finger lacks good venous anastomosis conditions. Therefore, a simple arterial anastomosis cannot form a closed loop of the replanted finger blood flow. In severe cases, it will cause an arteriovenous crisis and cause avascular necrosis of the replanted finger. In the past, arteriovenous crises were treated with arterial anastomosis plus finger exsanguination and decompression. However, this technology has higher requirements for doctors to operate and the postoperative nursing work is extremely cumbersome [4]. Hu Rong et al. [5] stated that children cry and do not cooperate during postoperative decompression and bloodletting, and parents are under great psychological pressure, which can easily lead to conflicts between doctors and patients.

In microsurgery, an anastomosis of blood vessels with a caliber less than 0.8mm can be called super microsurgery. With the rapid development of super microscopy technology, super microsurgery combined with arterial venation technology can be used to solve the problem of finger tip dissection without venous anastomosis, and to improve the success rate of fingertip replantation [6]. And because of the distal end of the broken finger, the artery is deep and often preserved well. Super microsurgery combined with arterial venous replantation after finger replantation is relatively smooth, without repeated manual intervention, and patient satisfaction is high. In this study, the cadaver study explored the distribution of blood vessels at the end of the finger and the matching conditions of blood vessels. At the same time, the clinical effects of various amputated finger anastomosis methods were compared, and the technical effectiveness and scientificity of arterio-venolization in fingertip amputated finger replantation were analyzed.

1 Materials And Methods

1.1 Clinical research data

65 patients with severed fingertips operated in Loudi Central Hospital from January 2014 to November 2018 and in the Third Affiliated Hospital of Southern Medical University from November 2018 to January 2021 were randomly selected. All of them were included in the group, 36 males and 29 females; the age ranged from 1.5 to 56 years, with an average of (31 ± 2) years old. All of the fingers were severed, 44 cases of right hand and 11 cases of left hand. Injury finger categories: 15 cases of thumb, 26 cases of index finger, 12 cases of middle finger, 5 cases of ring finger, 6 cases of little finger. Causes of injury: 38 cases of sharp cutting injuries, 9 cases of chainsaw injuries, 7 cases of strangulation injuries, 7 cases of crush injuries, and 4 cases of bite injuries. According to the Ishikawa classification standard, the distal finger was classified as: Type I (far from the midpoint of the nail) 15 cases ; Type II (nail root to midpoint of nail) 7 cases; Type III (from the root of the nail to 1/2 of the distal interphalangeal joint) 25 cases; Type Ⅳ (from the root of the nail to the proximal half of the distal interphalangeal joint) 18 cases.

The 12 fingers that were not able to find a suitable vein for anastomosis at the distal end were treated with supermicroscopic technique for arterial venous amputated finger replantation as group A; if an anastomosis condition was available, the anastomosis method of the distal segment of the finger was a

normal artery, Venous end-to-end anastomosis replantation of 25 fingers as group B; due to unconditional anastomosed vein anastomosis, only unilateral artery anastomosis plus postoperative bloodletting therapy for 9 fingers as group C; finger end segmentation without arteriovenous anastomosis conditions, 19 fingers that could only undergo in situ replantation of the fingertips were regarded as the group D.

All the surgical methods could not be predicted before the operation and need to be determined during the operation. The preoperative doctor in charge introduced the possible options of the amputated finger replantation to each group of patients or parents in detail, and obtained a written informed consent signed by each patient and their parents. There was no significant statistical difference between the groups in various indexes before operation.

1.1.1 Surgery and postoperative treatment process

During the surgical procedure, the operation was performed under a microscope (Moller-Wedel GmbH FS 2012), and the magnification was 26–32 times. The patient was treated with brachial plexus anesthesia or general anesthesia. The affected limb was laid flat on a sterile operating table. At the beginning of the operation, the operating room was kept at a constant temperature of 23 degrees. When the blood vessels were ready for anastomosis, the temperature in the operating room was raised to 28 degrees Celsius. The operation was performed by the surgeon and assistant in pairs, and the assistant cooperated on the opposite side.

First, the upper arm pneumatic tourniquet ("Jinjian JS-B27") was used to inflate the bleeding. The severed fingers were routinely cleaned with normal saline, diluted complex iodine, trimmed and incised, dissected the flexor and extensor tendons and digital nerves at both ends, dissociated the bilateral digital proper arteries and dorsal veins and marked. A 0.8–1.5 diameter Kirschner wire was used to fix the severed phalanx, and an oblique Kirschner wire was added if necessary to prevent rotation. If insertion of flexor or extensor tendon was involved, suture or reconstruction was performed to suture the finger proper nerve.

Arterial blood supply vessels for anastomosis: For the arterial blood supply vessels, the ulnar finger artery was generally selected for thumb, index finger and middle finger, while the radial finger artery was selected for little finger and ring finger. With good elasticity and thick blood vessels, the probability of arterial crisis after anastomosis is low, so they are the preferred arterial vessels. The dominant digital artery was anastomosed with the 10 − 0 to 12 − 0 undamaged silk thread, and the tourniquet was loosened to check the bleeding of the other digital artery at the distal end of the severed finger. If the bleeding was unobstructed, it would be used as the distal blood vessel matching arterial venous. Reinflate the tourniquet to stop the bleeding.

In group A, 12 cases of severed finger distal segment replantation arterial venous vascular anastomosis: the finger artery with smooth bleeding on the non-dominant side of the severed finger were selected, and the adventitia of the 1.5 mm end of the vessel was removed. A vein with a diameter of about 0.3–0.5 mm on the outside of the nail groove on the non-dominant side of the proximal finger was selected as the docking vessel. Hydraulic pressure was applied to enlarge the distal artery and proximal vein diameter,

Fig. 1. A 12-0-10-0 non-injury vascular line under a 26–32 times microscope was used to perform an intermittent valgus anastomosis, a strangulation test was performed after the operation to determine the patency of the blood vessel, and check that the fingertips were full and ruddy. If the judgment was not accurate, observed after 10 minutes, there was no dark red blood from the distal end of the acupuncture finger, and the capillary filling test was negative, indicating that the blood supply of the finger was good. Closely monitoring the patient's blood pressure during the operation, and keeping the blood pressure at a systolic pressure greater than 130 mmHg during the anastomosis. After the anastomosis, the skin was loosely sutured to prevent the blood vessels from being compressed, and special care should be taken not to compress the finger artery area when bandaging. The fingertips should be lined to the upper middle of the upper arm with plaster protection to prevent inadvertent movement of the affected limb. Routine anti-tetanus, anti-inflammatory, anti-spasm, and constant temperature treatment were given after the operation.

In group B, 25 cases of finger distal segment replantation surgery were performed with conventional arterial-to-artery and vein-to-vein anastomosis during vascular anastomosis. The other replantation procedures were the same as those in group A. The postoperative related treatment was the same as that of group A.

In group C, 9 cases of finger distal segment replantation surgery did not have proper venous anastomosis and only anastomosed unilateral artery. The other replantation operations were the same as group A. After surgery, they returned to the ward to closely observe the blood supply of the replanted finger and used bloodletting therapy if necessary.. Other related treatments after operation were the same as in group A.

In group D, 19 cases of replanted finger with severed distal segment of the finger had no conditions for anastomosis of the distal artery and proximal vein. Kirschner wires were used to enlarge the medullary cavity, the severed finger was replanted in situ, and hyperbaric oxygen was used after the operation. Hyperbaric oxygen chamber treatment 2 times/d, 2 h/time; other postoperative treatments were the same as group A.

1.1.2 Assess clinical results

(1) The replanted fingers were evaluated. The content of the evaluation included finger capillary filling experiment, the average survival rate of each finger, the length of hospitalization, the number of vascular crises, and partial skin necrosis.

(2) After the operation, the patient was required to return to visit regularly. If the patient had abnormal changes during the recovery at home, he could contact the doctor in time through telephone, WeChat, etc. After 2 years of follow-up, the function of the replanted fingers and the degree of two-point discrimination were determined again, and the patient's satisfaction with this treatment was investigated.

1.1.3 Statistical analysis

SPSS22.0 statistical software package was used for processing. Continuous data were expressed as (± S) and t-test was performed. The count data were described by rate and composition ratio, and χ^2 test was used. The test level was 0.05 on both sides of α value.

1.2 Corpse research materials and methods

In January 2022, 10 isolated hand index books were taken from the Department of human anatomy of Southern Medical University. Among them, there were 5 on the left and 5 on the right.

Autopsy finger dissections were performed by two pediatric orthopedic surgeons (15 years and 5 years experience respectively) with microsurgery skills under the same microscope at 8–32 times magnification, carefully dissecting the index books of 10 isolated hands. According to the methyl line and the distance of the midpoint of the finger thread as the positioning standard, analyze the relationship between the distribution of the terminal arteriovenous blood vessels available for anastomosis and the two positioning marks. To find the matching relationship between the distal finger artery and the proximal vein, so as to determine the conditions of arterial venovenous anastomosis and the optional range of the distal finger. (3) Possible collateral damage, etc.

2 Results

2.1 Clinical results

The 10 patients in the treatment group A were negative in capillary filling experiment of finger tip after replantation. The blood flow of finger tip was good, and the color of finger body was ruddy, but the color was slightly darker after replantation than that of group B, and the capillary filling speed was slightly faster, which returned to the normal color and reaction speed of finger of group B about 7-10 days after replantation. Stitches were removed 14 days after the operation, and 11 fingers were completely alive with normal appearance and plump and ruddy fingers. Vascular crisis occurred in 3 fingers, among which 1 finger vein crisis failed to be saved and necrosis occurred, and the other 1 finger artery crisis. The family members chose to give up rescue and underwent stump repair.

In group B, 20 of the 25 replanted fingers survived, the appearance of the fingers was normal, and the finger belly was full and ruddy. Vascular crisis occurred in 7 cases, of which 2 cases underwent vascular recanalization and returned to normal after the operation, and 5 cases underwent necrotic tissue removal and flap transposition.

Of the 9 replanted fingers in group C, 6 of the fingers were pale after the operation, and gradually changed to brown or light gray 2-5 days after the operation. Among them, 2 cases had partial skin necrosis, which returned to normal after dressing change. In 3 cases, the fingers directly turned to dark black and shriveled, and underwent the second-stage stump trimming flap transposition.

In group D, the replanted fingers of 19 cases were pale after operation, 13 cases were dark gray 5 days after operation, and light red after 14 days. In 6 cases, the fingers directly turned to dark black and shriveled and necrotic, and the stump trimmed flaps were used for transposition.

2.2 Comparison of survival ratio, hospitalization time, number of vascular crises, and partial skin necrosis in each group

There was no significant difference in the survival ratio, hospitalization time, number of vascular crises, and partial skin necrosis in groups A and B (P>0.05). The hospitalization time and partial skin necrosis rate of groups C and D were higher than those of groups A and B, the incidence of vascular crisis was higher than that of group B, and the survival rate of replanted fingers was lower than that of groups A and B (P<0.05). There was no difference in hospitalization time, vascular crisis, and partial skin necrosis rate in groups C and D (P>0.05), but the survival rate of replantation in group D was higher than that in group C (P<0.05), **Table 1**.

2.3 Comparison of two-point resolution, DIPJ activity and patient satisfaction in each group

There were no significant differences in the two-point resolution, DIPJ activity, and patient satisfaction between group A and group B (P>0.05). The two-point resolution and DIPJ activity of groups C and D were higher than those of groups A and B, and the patient satisfaction was lower than that of groups A and B. The difference was statistically significant (P<0.05), **Table 2**.

2.4 Typical cases

In my previous study,Typical case 1 Multi-segment injury of the dorsal vein, severing of the distal segment arterio-venolization surgery. Typical case 2 Distal thumb injury, no veins remaining on the distal dorsal side arterio-venolization surgery.Cases 1 and 2 have been published in World Journal of Clinical under the title Supermicroscopy and arterio-venolization for digit r eplantation in young children after traumatic amputation: Two case reports. [21]

Typical case 3 The index finger, middle finger, and ring finger are severed. Arteries and veins are anastomosed. Treatment of venous crisis. **Figure2**.

Typical case 4 The thumb is severed and the arteries and veins are anastomosed. **Figure3.**

Typical case 5 The index finger is severed, the artery is anastomosed, the vein is not anastomosed. **Figure4**.

Typical case 6 The middle finger is severed, and the arteries and veins are not anastomosed. **Figure5**.

2.5 Anatomical findings

There were clear distal capillary networks in the dissected fingers. The position of the rear edge of the nail and the center point of the fingertip thread did not exactly correspond, and the relationship was not

constant. The thread center point of 4 fingers was in front of the nail root, the thread center point of 4 fingers was behind the nail root, and the thread of 2 fingers was not clear. It is not clear to remember half-moon, 4 without half-moon, and 6 cases with half-moon. Finger veins gradually shrink at the end of the finger, and a vein with a diameter of about 0.3~0.5mm at the outer side of the nail groove 1-2mm and the vein on the palm of the finger were relatively constant. During anatomy, it was found that the terminal nerves were extremely thin and had many bifurcations, making it difficult to suture.

During the operation of the arteriovenous anastomosis, no obvious side injury was seen at the distal end of the finger body.

3 Discussion

Dissection of the distal segment of the finger is common in knife cuts, crush injuries, rush contusions, etc. Due to the different causes of injury and the location of the severed finger is different, the degree of damage from the cross-section varies [7]. Children's fingers are small, and it is extremely difficult to replant the distal segment of the finger after finger injury [8]. At the same time, if the dissection is damaged or the distal dissection is severely contaminated, a long section of debridement is required, which makes it very difficult to control the conditions suitable for vascular anastomosis, especially for veins that are difficult to find a suitable size vessel for anastomosis [9]. However, if the off-section arterial vein cannot be sutured or only the artery is sutured, the blood supply of the replanted finger will be insufficient or the blood supply vessel will be occluded again due to no return channel after the blood supply, so that the distal end of the replanted finger will lose effective blood circulation, which will eventually lead the replanted finger to have a high probability of necrosis due to ischemia [10].

According to the Ishikawa classification, zone I is located far from the midpoint of the nail. When this part of the finger body is broken, the wound will be treated. There is less stock at the distal end of the finger body, and it is basically impossible to find arteriovenous blood vessels that can be anastomosed. In situ replantation is often used. Treatment, if there is a large bone mass, the bone marrow cavity will be opened up, and hyperbaric oxygen treatment will be used after the operation [11]. In the case group, the patients in group D all came from the severed injury in the I area. Zone II is from the midpoint of the nail to the baseline of the nail. In this zone, the dorsal finger veins are missing. It is difficult to find matching veins on the finger side. The palmar veins and finger arteries are often in better condition. Arteriovenous techniques are often used for anastomosis. If the blood vessel is still unconditionally anastomosed, only arterial anastomosis and small distal incision bloodletting therapy will be performed. Finger treatment methods that cannot be anastomosed even with a small amount of arteries are the same as those for finger removal in area I. Zone III is the part from the baseline of the nail to 1/2 of the distal interphalangeal joint. In this area, a small part of the dorsal vein and lateral veins remain, and most of them can be anastomosed from artery to artery, vein to vein, or distal artery to proximal vein (arterial venation). The specific method is determined by the intraoperative exploration of vascular conditions. Decision [12]. The first choice of veins is the lateral vein, followed by the subcutaneous vein at 45° above the digital dorsi, and then the palmar finger vein. Zone IV is the part from the baseline of the nail to the

half of the distal interphalangeal joint. The arteries and veins in this area are usually well preserved, and the first choice is the arterial-to-artery and lateral vein anastomosis to the lateral vein.

Cheng et al. [13] conducted autopsy and found 303 volar veins from 100 fingers, all with a diameter greater than 0.3mm, with the center of the nail root as the 12 o'clock position. The volar veins are mainly distributed in 3–5 and 7–9 o'clock position. Another comparative study showed that fingertip replantation with palm vein anastomosis has a higher success rate, and a lower rate and severity of venous congestion. In this study, when the lateral arteriovenous anastomosis of the finger was performed, the operation time was extended by only 10 minutes. This is because the lateral finger arteries are easy to find, the lateral veins appear relatively constant, and the palmar veins are unstable. At the same time, the blood vessels are thin and it is more difficult to suture. In addition, studies have found that in most cases, the lateral veins and the dorsal finger veins are a venous network and are closely connected. In a few cases, the lateral veins are continuous with the palm veins [14, 15]. However, no matter where the blood vessel is closely connected, the position of the blood vessel on the side of the nail is relatively constant, and the lumen is thick, which is convenient for anatomy and has good ductility.

This study shows that: the proper digital arteries on both sides of the distal segment of the finger migrate to the fingertips at the distal interphalangeal joints and divide into multiple branches. Each branch is anastomosed into a net, and at the tip of the fingertips, it turns to the back of the finger and connects to the back of the finger. The lateral vascular network is connected to form an arteriovenous closed loop characterized by arterioles-arterioles-capillary network-venules-venules. As long as the severed finger can effectively connect one side of the finger artery, it can be effectively perfused into the soft tissue of the distal severed finger through the capillary network to provide nutrition [16, 17]. At the same time, the blood flow can enter the contralateral finger artery along the capillary network and flow out. Therefore, by introducing the backflow blood from the contralateral finger artery into the proximal vein of the injured finger, the blood flow can form a loop, forming a replanted finger and The body constitutes blood circulation, which is conducive to the nutrient supply and survival of the replanted fingers [18, 20]. This study shows that the biggest difference between the groups is that the finger capillary filling experiment time of arteriovenous replantation will be faster, and the color is usually darker or lighter purple. If the finger body is shorter, the color is closer to normal. For example, if the finger body is longer, the color is darker and the recovery time is longer. In addition, the hospitalization time and partial skin necrosis rate of groups C and D were higher than those of groups A and B, the incidence of vascular crisis was higher than that of group B, and the survival rate of replanted fingers was lower than that of groups A and B ($P < 0.05$). It is proved that arterial venation can rebuild blood circulation, anastomosis of the movement and the vein is complete, the plasticity of the broken finger is strong, the survival rate of replantation and the healing rate are clinically effective. The results showed that the two-point resolution of the C and D groups was greater than that of the A and B groups. Considering that the surviving groups of the C and D groups had a higher rate of skin necrosis on the distal fingertips and poor sensory recovery[19]. The difference in DIPJ range of motion between groups C and D between groups A and B is small. The reason is considered to be that the distal segment injuries treated in groups C and D are relatively short and generally do not exceed the methyl line, so the impact on the joints is small.

In summary, in the face of finger amputation without good vein anastomosis, especially in infants, arterial venous therapy with super microscopic technology can effectively improve the success rate of finger preservation, and has the advantages of one-stage wound sealing, reducing the chance of infection, and maximizing the recovery of distal finger function. This method is an effective and safe choice in this special case. It can provide the greatest technical assistance for the replantation of severed terminal fingers and is suitable for promotion. The disadvantage is that this study is based on whether there are lateral veins, oblique lateral veins, arteries and other anastomotic conditions to determine the surgical grouping. At the same time, the grouping is closely related to the severed location and the length of the severed finger, so the research group cannot do it. To be completely unified, and the number of patients is limited, which may have an impact on the results of the study.

Conclusion

Finally, we use super microscopy combined with arterial venalization technology to provide a good surgical method for patients with distal severed fingers, which significantly improves the probability of successful replantation of severed fingers and increases the satisfaction of patients. This technology is highly feasible, safe and effective, and is suitable for wide popularization and application.

List Of Abbreviations

DIPJ
distal interphalangeal joints

Declarations

Corresponding author:

Yao Jinghui,Department of Pediatric Orthopedics,Center for Orthopaedic Surgery, The Third Affiliated Hospital of Southern Medical University, Guangzhou 510630, Guangdong Province,jinghuiyao2020@163.com;Department of Pediatric Orthopedics, Once in Loudi Central Hospital, Loudi 417000,China

Ethics declarations

Ethics approval and consent to participate

Approved by the clinical trial ethics committee of Loudi Central Hospital and The Third Affiliated Hospital of Southern Medical University.

Consent for publication

All authors have read and approved the submitted manuscript.

Availability of data and materials

Study data are available upon request from the principal author.

Competing interests

All authors declared no competing interest.

Funding

This study was funded by Loudi financial enterprise plan Award Number: 2015592 | Recipient: yao jinghui.Loudi financial education plan Award Number: 2018 50 | Recipient: chen yun.Medical Science and Technology Foundation of Guangdong Province Award Number: 2018B090944002 | Recipient: Li yanbin

Author contributions:

Chen Yun,Li Yanbin and Wang Zemin collate the materials and write articles; Yao Jinghui,Cai Daozhang and SUN Yongjian,designed the research study; Yao Jinghui,Wang Zemin and Liu chang completed these operations; Chen Yun,Li Yanbin and Yao Jinghui completed the anatomical stud; All authors have read and approve the final manuscript.Yao JH used to work in the Department of orthopedics of Loudi Central Hospital and was transferred to the Third Affiliated Hospital of Southern Medical University in December 2018.

Acknowledgements

None.

Informed consent statement

All study participants, or their legal guardian, provided informed written consent prior to study enrollment.

Authors' information

Chen Yun, Master of medicine,Department of Pediatric Orthopedics,Center for Orthopaedic Surgery,The Third Affiliated Hospital of Southern Medical University, Guangzhou 510630, Guangdong Province, China

Li Yanbin, doctor of Medicine, Department of human anatomy, Southern Medical University,Guangzhou 510515, Guangdong Province, China

Wang Zemin,Master of medicine, Department of Pediatric Orthopedics, Loudi Central Hospital, Loudi 417000, Hunan Province, China

LIU Chang,doctor of Medicine,Department of hand microsurgery, Jishuitan Hospital, Peking University,Beijing 100035,China

SUN Yongjian, Department of Pediatric Orthopedics,Center for Orthopaedic Surgery, The Third Affiliated Hospital of Southern Medical University, Guangzhou 510630, Guangdong Province, China

Cai Daozhang,doctor of Medicine,Orthopedics,Center for Orthopaedic Surgery,The Third Affiliated Hospital of Southern Medical University, Guangzhou 510630, Guangdong Province, China

Yao Jinghui,Master of medicine,Department of Pediatric Orthopedics,Center for Orthopaedic Surgery,The Third Affiliated Hospital of Southern Medical University, Guangzhou 510630,Guangdong Province,Once in Loudi Central Hospital, Loudi 417000,Hunan Province,China

References

1. Chen S, Wen G, Cheng L, Chai Y. *Mangled finger salvage using cross-finger revascularization[J]*. Journal of Orthopaedic Surgery and Research, 2020, *15*(*1*):104.
2. Jiang Q, Wang Y, Yang L, Jiang Z. *[Clinical application of veno-arteriolization of finger lateral vein for repairing severed finger tips].[J]. Zhonghua zheng xing wai ke za zhi = Zhonghua zhengxing waike zazhi = Chinese* journal of plastic surgery,2014,*30*(*2*):93–5.
3. Wang X, Zhang WK, Yin SM, Wang HB, He T, Gong YQ, Zhu GM, Mao GL, Hu MX, Li J. *[[Fingertip replantation with anastomosis of palm vein and retaining the nail].[J]*. Zhongguo gu shang = China journal of orthopaedics and traumatology, 2013,*26*(*8*): 639–41.
4. Wei J M, Sun J S, Jiao X H, et al. [Replantation of fingertip amputation in lack of availability of intravenous anastomosis].[J]. Zhongguo gu shang = China journal of orthopaedics and traumatology, 2012, 25(8):648.
5. Wapler C, Laronde P, Nedellec G, Aumar A, Sayah N, Fontaine C. *A prospective study of 100 cases of sterile T-RING™ digital tourniquet application.[J]*. Hand Surg Rehabil. 2016, *35*(*4*):271–279.
6. *Van* Handel AC, Pet MA. *Fingertip Replantation: Technique Details and Review of the Evidence. [J]*. Hand Clin. 2021, *37*(*1*):53–65.
7. Kawaiah A, Thakur M, Garg S, Kawasmi SH, Hassan A. *Fingertip Injuries and Amputations: A Review of the Literature*. [J]. Cureus. 2020, *12*(*5*):e8291..
8. Li M, Zeng XC, Xie WG. *[Clinical characteristics of treadmill abrasion in children]*. Zhonghua Shao Shang Za Zhi. 2020, *36*(*10*):966–968.
9. Elzinga K, Chung K C. Non-microsurgical Composite Grafting for Acute Management of Fingertip Amputation[J]. Hand Clin,2021,37(1):43–51.
10. Sindhu K, Defroda S F, Harris A P, et al. Management of partial fingertip amputation in adults: Operative and non operative treatment. [J]. Injury, 2017, 48(12): 2643–2649.
11. Loewenstein S N, Adkinson J M. Pediatric Fingertip Injuries. [J]. Hand Clin,2021,37(1):107–116.
12. Nakanishi A, Omokawa S, Kawamura K, et al. Tamai Zone 1 Fingertip Amputation: Reconstruction Using a Digital Artery Flap Compared With Microsurgical Replantation. [J]. J Hand Surg Am,2019,44(8):655–661.

13. L, Cheng, K, et al. Fingertip replantation at the eponychial level with venous anastomosis: an anatomic study and clinical application. [J]. Journal of Hand Surgery (European Volume), 2013, 38(9):959–963.
14. Omokawa S. Favoured treatments for fingertip defects and finger amputation distal to the distal interphalangeal joint in my unit and in Japan[J]. J Hand Surg Eur Vol,2019,44(10):1101–1102.
15. Van Handel A C, Pet M A. Fingertip Replantation: Technique Details and Review of the Evidence[J]. Hand Clin,2021,37(1):53–65.
16. Lok L W, Chan W L, Lau Y K. Functional Outcomes of Antegrade Homodigital Neurovascular Island Flaps for Fingertip Amputation[J]. J Hand Surg Asian Pac Vol,2017,22(1):39–45.
17. Masaki S, Kawamoto T. Fingertip Amputation Injury of Allen Type III Managed Conservatively with Moist Wound Dressings[J]. Am J Case Rep,2021,22:e928950.
18. Hong M K, Park J H, Koh S H, et al. Microsurgical Free Tissue Options for Fingertip Reconstruction[J]. Hand Clin,2021,37(1):97–106.
19. Ito H, Sasaki K, Morioka K, et al. Fingertip amputation salvage on arterial anastomosis alone: an investigation of its limitations[J]. Ann Plast Surg,2010,65(3):302–305.
20. Li X, Zhai H, Zhao G, Pan X, Yao Q, Hua Y, Yu J, Mi J. *A comparative study of lateral and palmar venous anastomosis in Ishikawa zone â fingertip replantation*. J Orthop Surg (Hong Kong). 2020, *28*(*3*):2309499020962861.
21. Chen Yun; Wang Zhemin; *Yao Jinghui; Supermicroscopy and arterio-venolization for digit r eplantation in young children after traumatic amputation: Two case reports*, *World Journal of Clin ical*, 2020
22. **Corresponding author**:
23. *Yao Jinghui,Department of Pediatric Orthopedics,Center for Orthopaedic Surgery, The Third Affiliated Hospital of Southern Medical University*, *Guangzhou 510630, Guangdong Province,jinghuiyao2020@163.com;Department of Pediatric Orthopedics, Once in Loudi Central Hospital, Loudi 417000,China*
24. **Ethics declarations**

Tables

Table 1 Comparison of related indexes of replantation index in four groups A, B, C, D (%)

groups	n	Hospitalization time (d)	Vascular crisis (finger)	Partial skin necrosis (finger)	Replanting refers to the number of survival (finger)
grouop A	12	15.00±3.12	3（25.00）	2（16.67）	10（83.33）
group B	25	14.80±1.23	7（28.00）	5（20.00）	20（80.00）
group C	9	22.32±5.31	0（0.00）	6（66.67）	2（22.22）
group D	19	20.43±5.69	0（0.00）	9（47.37）	6（31.58）
t/χ^2	-	13.45	9.000	9.604	18.354
P	-	（0.001	0.029	0.022	（0.001

Table 2 Comparison of prognostic indicators between the two groups

groups	n	Two-point resolution (mm)	DIPJ activity (°)	Patient satisfaction [n(%)]
grouop A	12	5.36±0.36	61.46±2.13	11（91.67）
group B	25	5.33±0.25	61.71±2.21	23（92.00）
group C	9	6.50±1.02	69.60±3.69	4（44.44）
group D	19	7.38±1.55	74.38±4.52	14（73.68）
t/χ^2	-	20.14	67.73	10.856
P	-	（0.001	（0.001	0.013

Figures

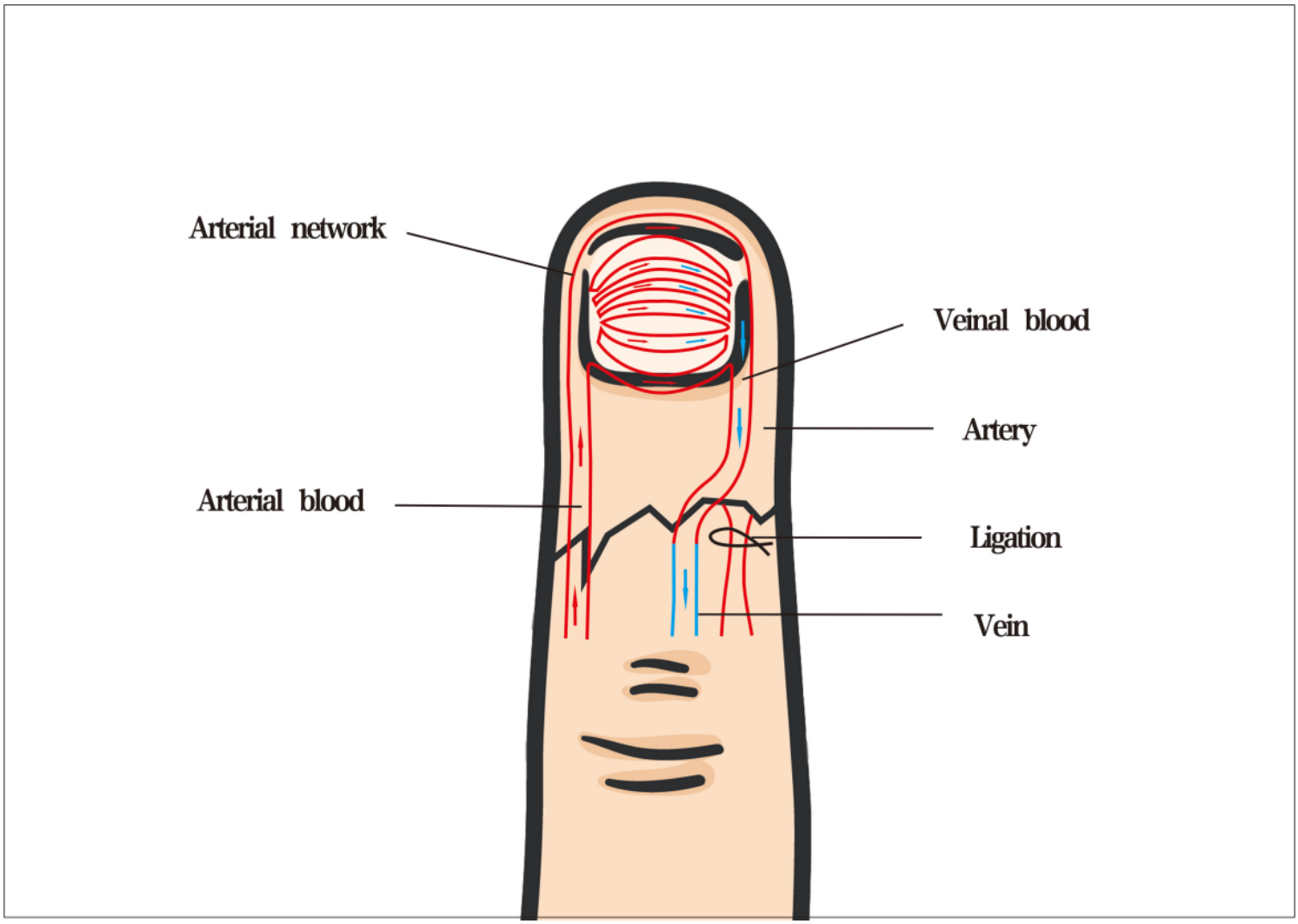

Figure 1

Surgical procedure demonstration

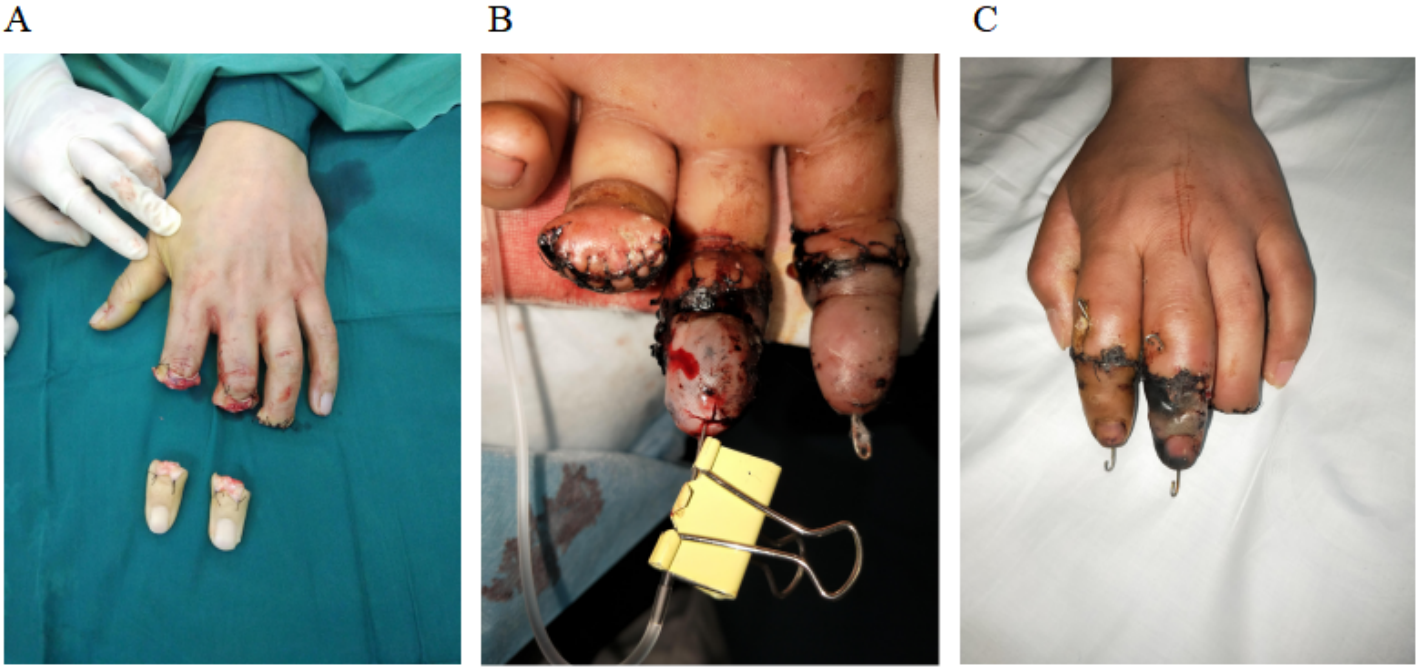

Figure 2

Typical case 3 The index finger, middle finger, and ring finger are severed. Arteries and veins are anastomosed. Treatment of venous crisis

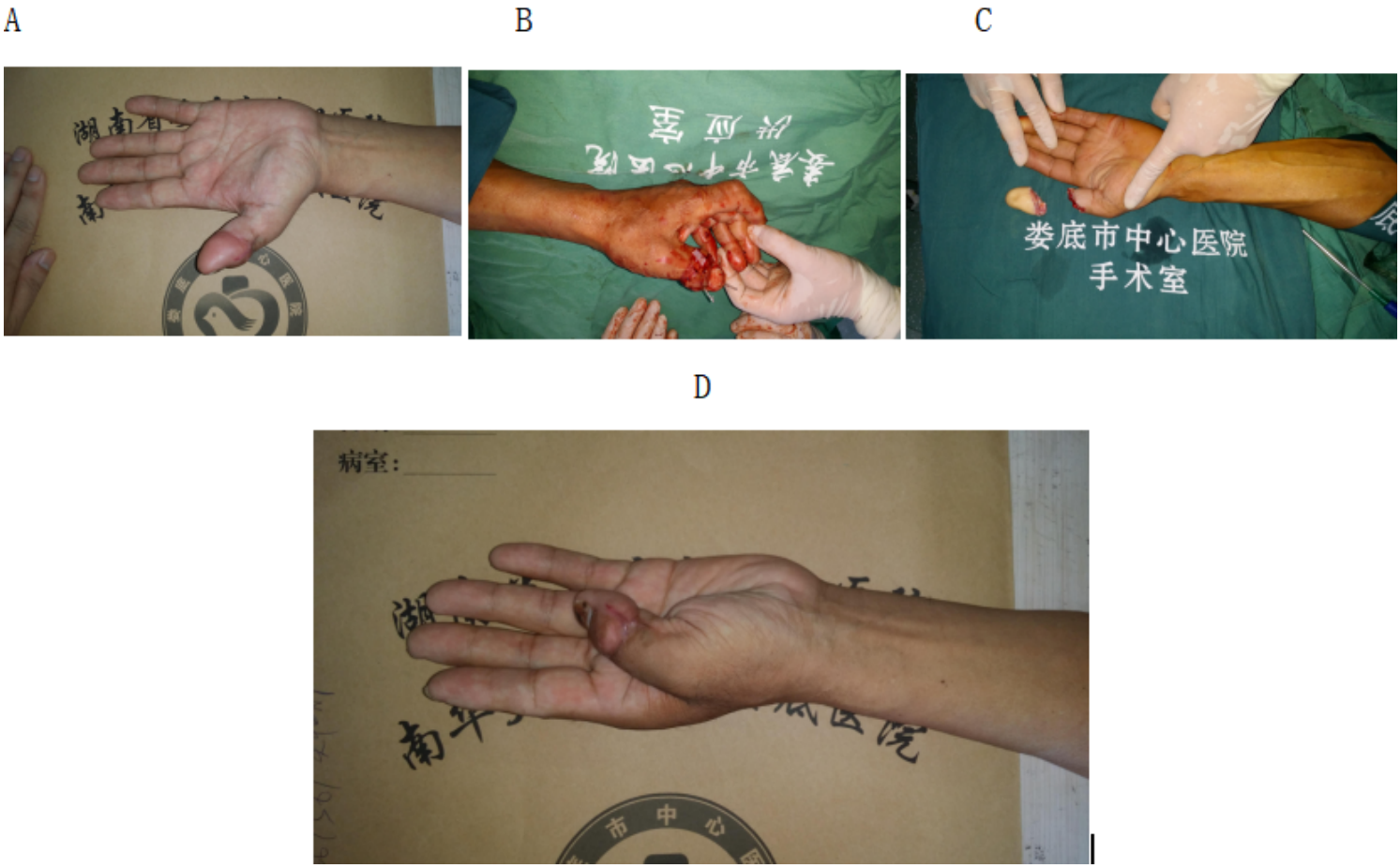

Figure 3

Typical case 4 The thumb is severed and the arteries and veins are anastomosed

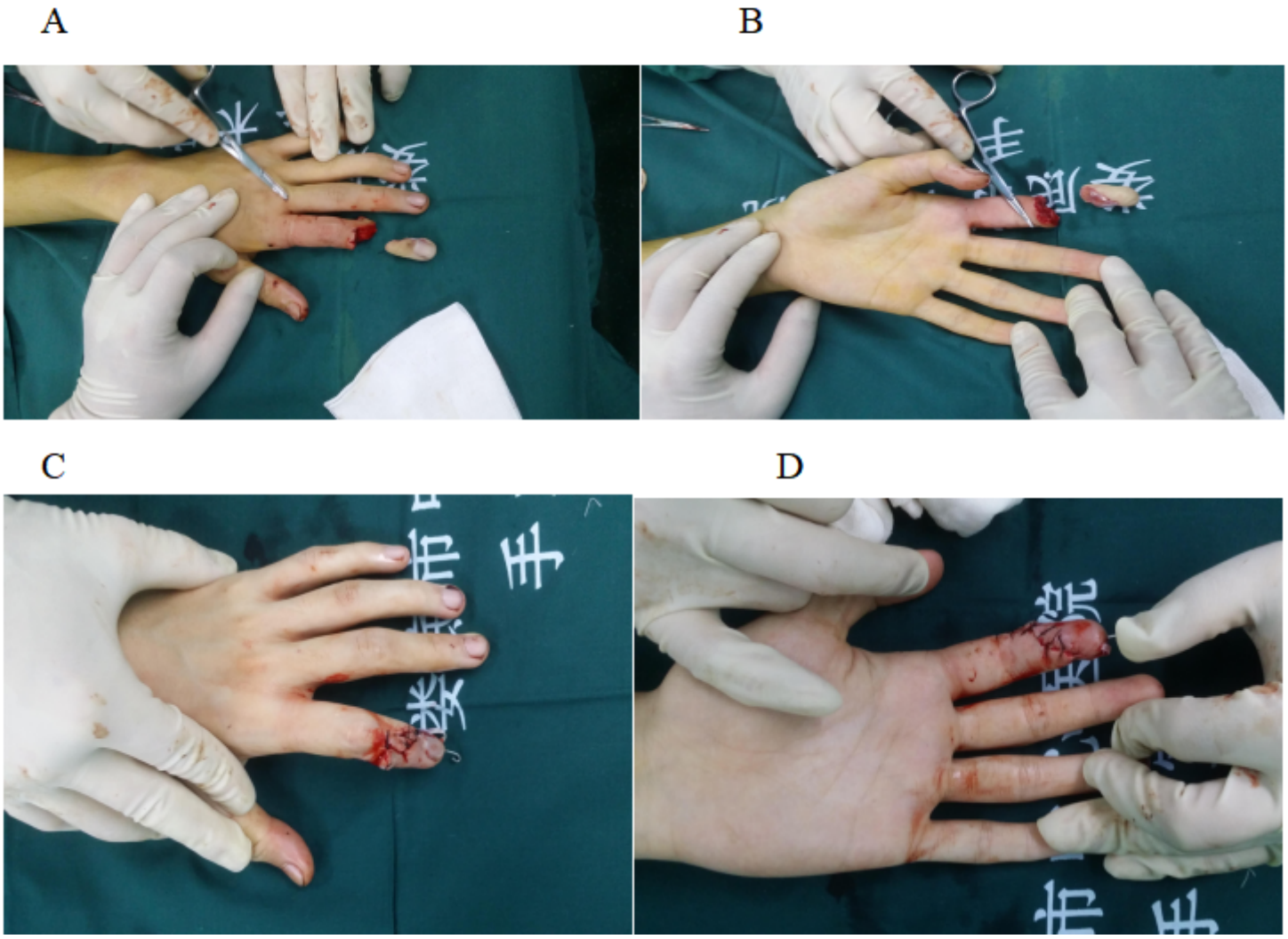

Figure 4

Typical case 5 The index finger is severed, the artery is anastomosed, the vein is not anastomosed

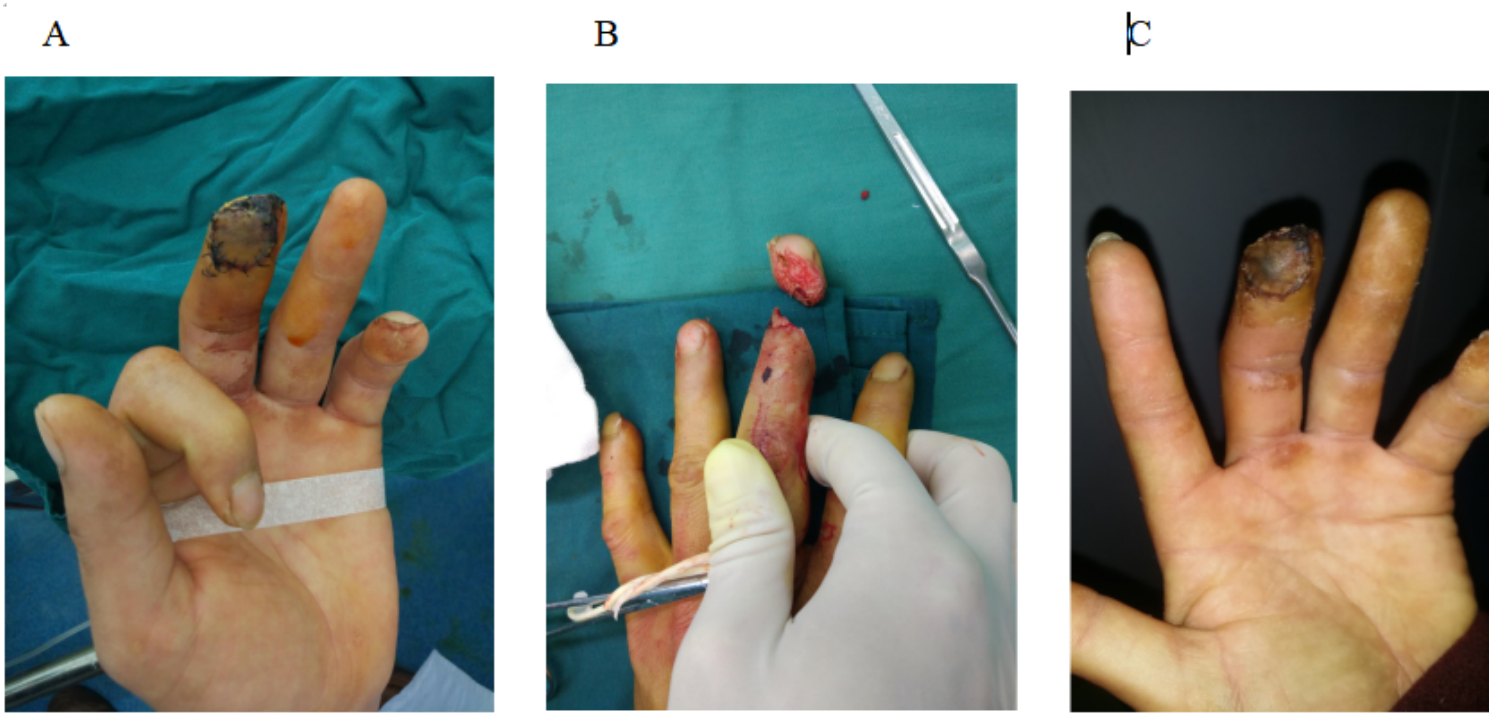

Figure 5

Typical case 6 The middle finger is severed, and the arteries and veins are not anastomosed