The clinical efficacy of periodontally accelerated osteogenic orthodontics in patients with bone fenestration and dehiscence: a retrospective study

Ziling Chen
Xi'an Jiaotong University
Huan Zhou
Xi'an Jiaotong University
Kaili Zhang
Xi'an Jiaotong University
Xu Wang
Xi'an Jiaotong University
Liangqiuyue Zhong
Xi'an Jiaotong University
Yuxia Hou
Xi'an Jiaotong University
Yue Chen (dentistcy@126.com)
Xi'an Jiaotong University

Research Article

Keywords: periodontally accelerated osteogenic orthodontics, bone fenestration and dehiscence, periodontal tissues, guided bone regeneration, gingival recession

Posted Date: April 20th, 2022

DOI: https://doi.org/10.21203/rs.3.rs-1548799/v1

Abstract

Purpose: The objective of the study was to explore the effect of periodontally accelerated osteogenic orthodontics (PAOO) in orthodontic patients with bone dehiscence and fenestration in the anterior alveolar region of the mandible.

Methods: A retrospective study was performed in 42 patients with bone dehiscence and fenestrations in the anterior alveolar region of the mandible underwent the PAOO technique. Bleeding index (BI), probing depth (PD), keratinized gingiva width (KGW), gingival recession depth (GRD), and gingival phenotype were recorded and assessed at baseline, postoperative 6 and 12 months. Cone-beam computerized tomography was utilized for bone volume measurement in term of root length (RL), horizontal bone thickness at different levels and vertical bone height at baseline, 6 months and 12 months after the surgery.

Results: The sample was composed of a total of 42 patients (22 males and 20 females; mean age, aged 25.6 ± 4.8 years) with 81 teeth showing dehiscence/fenestrations and 36 sites presenting with gingival recessions. There was no significant difference in BI, PD, and KGW (between baseline, postoperative 6 and 12 months) based on the clinical evaluations ($P > 0.05$). Gingival recession sites demonstrated a significant reduction in the GRD after surgery ($P < 0.05$). Besides, the proportion of teeth with thick gingival phenotype was increased from 33.61% at baseline to 53.13% at the end of the follow-up. In addition, the bone thickness at mid-root and crestal level was markedly increased compared with the baseline records ($P < 0.05$), although the increase in apical level was not statistically significant ($P > 0.05$). Moreover, alveolar bone height was also remarkably increased at postoperative 6 month compared with the baseline records ($P < 0.05$).

Conclusions: Within the limitations of the study, the obtained results show that PAOO technique is beneficial to periodontal conditions in terms of soft and hard tissue augmentation. PAOO procedure may represent a safe and efficient treatment for orthodontic patients with bone dehiscence and fenestration.

Trial registration: This study was approved by the ethics committee of stomatological hospital affiliated to Xi'an Jiaotong University (xjkqll[2019]NO.016) and registered in Chinese Clinical Trial Registry (ChiCTR2100053092).

1. Background

At present, the number of adult patients demands esthetics-centered, function-oriented and fast-paced orthodontic treatment is increasing, which brings great challenge to the clinical practice [1–3]. Generally, age is not a contraindication to orthodontic treatment, however, the tissue response to orthodontic forces in terms of the cell activity and collagen fiber conversion is markedly slower in adults compared with younger patients (teenagers and children). Additionally, the hyalinized zones are formed easily on the pressure side of the orthodontically moved tooth, which could hinder the tooth from moving into the intended direction [4, 5]. Thus, the average orthodontic treatment time for adults is 18.7 to 31 months,

which considerably longer than that for children and teenagers. And the longer duration for toot movement, to a certain degree, limits the possibility of providing suitable treatment procedure for a high number adults seeking orthodontic treatment.

Under this context, some alternative treatments have been proposed to get over the above limitations of orthodontics. In particular, the introduction of periodontally accelerated osteogenic orthodontics (PAOO) has bring about gospel for adult patients. PAOO distinguishes itself from traditional orthodontics by combining clinical periodontal treatment with orthodontic movement, involving selective surgical corticotomy, bone grafting, and orthodontic forces; which based on the principle of regional accelerated phenomenon (RAP), an increase in bone metabolism and transitory osteopenia allows for accelerated teeth movement [6, 7]. An accumulating body of research indicated that PAOO gain an advantages over traditional orthodontic methods, in terms of accelerated tooth movement up to 3 to 4 times, increased scope of orthodontic therapy, abridged treatment duration, sustainable alveolar bone augmentation, increased range of tooth movement and reduced root resorption [6, 8, 9]. To our knowledge, although the present studies indicated that PAOO is a safe, time-consuming and effective treatment, most of the studies were case reports [10–13], and there is lacking systematic studies to prove whether PAOO is safe or detrimental to the periodontal tissues of adults, especially in patients with bone dehiscence and fenestration.

Bone dehiscence (a defect that extends to the cervical surface of the root, leading to marginal alveolar bone loss) and fenestration (a window that affects the root surface but is still bordered by bone along its coronal aspect) are the commonly manifestations of alveolar bone defect [14–15]. A previous study identified that the Class II and Class III subjects showed high prevalence of bone defects up to 41.11% and 45.02% in the anterior mandible teeth, respectively [16]. These defects usually lead to root exposure, gingival recession and even treatment relapse or failure, which bring challenges to the orthodontic treatment [17, 18]. Therefore, how to shorten the orthodontic time and decrease the severe sequelae is of great significance for orthodontic patients, especially the adults with bone fenestration and dehiscence also concerned time-consuming and esthetics issues. PAOO has been regarded as a promising therapeutic strategy with minimal side effects, in terms of root resorption and bone defect risk [13]. However, it is not clear whether PAOO is still applicable when the orthodontic patients suffer from bone fenestration and dehiscence in themselves, and the clinical effect remains unknown, especially on the periodontal tissues that play a cornerstone role on the overall tooth treatment.

Therefore, the present study was designed to examine the clinical efficacy of PAOO in adult patients with bone fenestration and dehiscence. Periodontal status was evaluated by bleeding index (BI), probing depth (PD), keratinized gingiva width (KGW), gingival recession height (GRH) and gingival phenotype at baseline, postoperative 3, 6 and 12 months. Bone volume was also measured during the follow-up period, with the aim to provide guidance for the clinical application of PAOO therapy.

2. Methods

2.1. Study design

The present single-center, retrospective study included 54 recruited subjects who were prescribed PAOO surgery by the Department of Periodontology, School of Stomatology, Xi'an JiaoTong University, China from December 2017 to June 2019. The inclusion criteria included: (a) patients aged at least 18 years; (b) with alveolar bone fenestration or dehiscence on the labial surface of the mandible before surgery; (c) non-smoker; (d) no uncontrolled systematic diseases such as infectious or metabolic diseases, hypertension, diabetes, cardiovascular disease and immunodeficiency. The exclusion criteria were as follows: (a) subjects who underwent bisphosphonate therapy, chemotherapy or radiotherapy, anticoagulant therapy or reported a history of head/neck radiation that could affect bone metabolism; (b) subjects who were taking medications associated with the occurrence and development of drug-induced gingival enlargement, e.g. calcium channel antagonist; (c) females who were lactating or pregnant; (d) previous orthognathic or orthodontic treatment. The current study was conducted in accordance with the Declaration of Helsinki, and the protocol was reviewed and approved by the ethics committee of School of Stomatology, Xi'an Jiao Tong University (approval number: xjkqll [2019] NO.016). In addition, the study registered in Chinese Clinical Trial Registry (ChiCTR2100053092). All the recruited subjects were explicitly informed of the intent and duration of the study, and the informed consent was received from all the patients.

2.2. Surgical and procedures

2.2.1. Treatment protocol

In accordance with the clinical treatment guidelines, each subject was treated with a mandibular pre-adjusted fixed appliance (“0.022 × 0.028” in size, Integra Brackets, Rocky Mountain Orthodontics Inc, Denver, CO, USA) during the week preceding PAOO surgery, however, the appliance was not activated pre-surgically. Orthodontic tooth movement was started 2 weeks after the periodontal surgical procedure. During orthodontic treatment, nickel-titanium arch wires (0.012", 0.014", 0.016", and 0.018", were aligned and leveled the postoperative arch) and stainless steels arch wires (0.019" × 0.025", to complete the treatment) were used in accordance with routine orthodontic adjustment guidelines [19, 20].

2.2.2. PAOO surgery

All subjects underwent PAOO surgery under local anesthesia, specifically, a full thickness mucoperiosteal flap was raised with the 15# blade at the interdental papillae on the buccal aspect (first premolar to first premolar), two vertical releasing incisions were positioned at one tooth beyond the “bone activation” region, with the aim to fully expose the surgical field and relieve tissue tension. A split-thickness flap (separating the periosteum flap from the overlying mucosal layer) was then carefully elevated apically for 3–4 mm. Two periosteal flap segments in terms of the “coronal” and “apical” region were finally created. After the flap reflection, corticotomy was performed. In specific, in the inter-radicular space, vertical alveolar decortications which extended 2–3 mm below the crest of the alveolar bone were created, and then connected with horizontal grooves (located 2–3 mm beyond the apices of the roots). Afterwards,

deproteinized bovine bone material (Bio-Oss, Geistlich, Wolhuser, Switzerland) was placed on the prepared region with light pressure, besides, the collagen membrane (Geistlich) was utilized to increase the stability of the graft material. Subsequently, flap tissue was coronally advanced and positioned at the cemento-enamel junction (CEJ) level, completely covering the graft material and collagen membrane. The procedure was finally completed by single interrupted suturing with 4 – 0 absorbable polyester, which connected the lingual tissue, the labial flap and the membrane together.

2.2.3. Post-operative management

All patients were provided with cold packs for external application to ameliorate postoperative swelling or edema. Routine antibiotics and nonsteroidal anti-inflammatory drugs were prescribed for use for at least 3 days. Each patient was provided oral hygiene instructions explicitly, and the use of antiseptic mouth wash (0.12% chlorhexidine gluconate solution) for plaque control was recommended. The sutures were removed 1 week after the surgery. All the enrolled subjects were asked to participate in regular follow-up to receive clinical examination and radiographic evaluations.

2.3. Clinical outcomes

2.3.1. clinical examination

The following clinical parameters were measured and recorded during the follow-up period. (1) probing depth (PD): the distance from the gingival margin to the bottom of the gingival sulcus; (2) bleeding index (BI): score from 0–5 according to Mazza's bleeding index [21]; (3) keratinized gingiva width (KGW): the distance from the gingival margin to the mucogingival junction [22];(4) gingival recession height (GRH): the distance from CEJ to the lowest point of the gingival margin;(5) gingival phenotype: based on the transparency of the periodontal probe through the gingival margin while probing the labial sulcus. If the outline of the underlying periodontal probe could be seen through the gingiva, it was categorized as a thin biotype; if not, it was categorized as a thick biotype.

2.3.2. Radiographic measurements

All patients were scanned using a commercially available CBCT scanner (Vatech, Korea) before surgery and postoperative 6 and 12 months. CBCT images were reconstituted using image software Mimics 18.0 (Materialise, Belgium). The following radiographic parameters were measured (Fig. 2) according to Xiao Xu et al. [23]:

(1) root length (RL): the distance from the root apex (dot 0) to the intersection (dot 1) of labial-lingual CEJ line and the long axis; (2) bone thickness at apical level (ABT): a line perpendicular to the long axis was made through the root apex (dot 0). ABT was the distance from dot 0 to the intersection (dot 2) of the labial alveolar bone surface and the line referred above; (3) bone thickness at mid-root level (MBT): a line perpendicular to the long axis was made through the mid-root point of the labial root surface (dot 3). MBT was the distance from dot 3 to the intersection (dot 4) of the labial alveolar bone surface and the line referred above; (4)bone thickness at crestal level (CBT): a line perpendicular to the long axis was

made through the point 2mm below labial CEJ (dot 5), CBT was the distance from dot 5 to the intersection (dot 6) of the labial alveolar bone surface and the line referred above; (5) vertical bone height (VBH): the shorter the distance from labial CEJ (dot 7) to alveolar crest (dot 8), the higher the vertical bone height.

2.4. Statistical analysis

The Statistical Package for Social Sciences (SPSS, version 18.0, Chicago, IL) was utilized for statistical analysis. All the descriptive data were presented as the means ± SD. Then, the data were tested to determine whether they were normally distributed and homogeneity of variance. We found some of them lacked normal distribution. One-way analysis of variance (ANOVA) and Kruskal-Wallis test were used to access the efficacy between before surgery (Baseline), after 6 months and 12 months. The data analysis was performed with SPSS (Version 25.0, Chicago, IL, USA), and a P-value < 0.05 was considered significant.

3. Results

3.1. Sample description

A flowchart of the recruited subjects is presented in Fig. 1. During the follow-up period, two subjects were excluded from the study: one female subject was unable to perform CT due to pregnancy, and one subject could not be contacted because of phone number changes. A total of 42 subjects (20 males and 22 females, aged 43.9 ± 12.8 years) with a total of 244 teeth were included in the study and finally completed the follow-up.

3.2. Clinical outcomes

All the enrolled subjects had no post-operative complications except the mild pain within the surgical area, which recovered largely soon. For periodontal tissues, there was no significant difference in BI and PD at baseline, postoperative 3, 6 and 12 months ($P > 0.05$). At the end of the observation period, KWG was observed to increase by 0.12 mm, although the difference was not significant ($P > 0.05$). As compared with the baseline, there was a significant reduction in the mean GRD (Fig. 4) after surgery ($P < 0.05$). At the end of the observation period, GRD decreased by 2.01mm, (Table 2). However, these differences were not significant during the follow-ups. In the present study, a total of 16 teeth had Miller class Ⅲ gingival recession (the mean GRH was 1.94 mm) at the baseline. GRH decreased by 1.35 mm and 1.38 mm on average at 3 and 6 months after surgery, the differences were statistically significant ($P < 0.05$) (Table 1). the proportion of teeth with thick gingival phenotype increased from 43.6% (82/188) to 63.3% (119/188) at 6 months after surgery.

Table 1
The basic information of patients

Variable	Outcome assessment
No. of patients (sites)	42 (244)
Mean age (range: yr)	30.9 (20.1–43.7)
Sex ratio (male: female)	20:22
Mean follow-up (range: month)	12 (11–13)
Biotype ratio (thin: thick)	103:141

Table 2
The descriptive statistics of clinical measurements

					Multiplecomparison		
	BL	6m	12m	*P*	BL-6m	BL-12m	6m-12m
BI	0.68 ± 0.56	0.60 ± 0.51	0.56 ± 0.52	0.061			
PD	2.21 ± 0.84	2.21 ± 0.85	2.21 ± 0.84	0.827			
KGW	4.76 ± 1.66	5.21 ± 1.69	4.97 ± 1.76	0.420			
GRH	1.25 ± 1.35	0.56 ± 0.86	0.64 ± 0.86	0.000	0.000	0.000	1

Note: Data are presented as mean (95% CI)

12m = 12 months after surgery, 6m = 6 months after surgery, BL = baseline, PD = probing depth, KGW = keratinized gingiva width, GRD = gingival recession height.

Table 3
The descriptive statistics of radiographic measurements

					Multiplecomparison		
	BL	6m	12m	*P*	BL-6m	BL-12m	6m-12m
RL	12.11 ± 1.47	11.99 ± 1.46	11.84 ± 1.44	0.147			
CBT	0.37 ± 0.47	0.68 ± 0.52	0.66 ± 0.50	0.000	0.000	0.000	1
MBT	0.34 ± 0.43	1.82 ± 0.77	1.77 ± 0.76	0.000	0.000	0.000	1
ABT	3.73 ± 1.40	3.91 ± 1.31	3.90 ± 1.29	0.318			
VBH	8.36 ± 3.02	9.48 ± 2.10	9.09 ± 2.03	0.000	0.000	0.154	0.095
Note: Data are presented as mean (95% CI)							
12m = 12 months after surgery, 6m = 6 months after surgery, BL = baseline, RL = root length, CBT = bone thickness at crestal level, MBT = bone thickness at mid-root level, ABT = bone thickness at apical level, VBH = vertical bone height							

3.2. Radiographic evaluations

Base on the obtained data, there was no statistically significant difference on root length at each follow up points ($P > 0.05$). Compared with the baseline, the mean bone thickness at mid-root and crestal level apical level was increased at 6 and 12 months after surgery, and the difference was statistically significant ($P < 0.05$). although the increase in apical level was not statistically significant ($P > 0.05$).

4. Discussion

A great many adult patients with malocclusions show reluctance to the traditional orthodontic procedure due to the drawn out treatment time, which usually increase the probability of suffering from other concomitant diseases including dental caries, decalcification, root resorption, gingival recession and other periodontal diseases. Under this context, PAOO technology has been introduced to satisfy the adult patient demand of shorter treatment time without compromising results. Indeed, Orthodontic tooth movement involves the compression of periodontal ligament, further activating the kinetics of crestal bone resorption and reconstruction, which thereby is considered a “periodontal phenomenon” [24]. Thus, it is prerequisite and of great significance to explore the effect of PAOO procedure on the periodontal status in adult patients; in particular, patients with bone fenestration and dehiscence, which in itself is a periodontal hazard. Based on our current study, PAOO technique were demonstrated to be beneficial to the periodontal tissues in terms of soft and hard tissue augmentation, which may represent a safe and efficient treatment for orthodontic patients with bone fenestration and dehiscence.

As a novel technology to shorten the treatment period without compromising orthodontic results, PAOO carries a big weight in the comprehensive treatment for patients with occlusal and esthetic issues. PAOO was firstly introduced by Wilcko in 2001 based on the RAP theory [7], the author assumed that the

surgical trauma in healthy tissues could cause osteopenia, reduce the bone resistance to tooth movement and further allow for the tooth acceleration movement. More importantly, PAOO procedure was identified to be an effective treatment with minimal root resorption and bone dehiscence when compared with the conventional orthodontic treatment. However, when the orthodontic patients in themselves are involved in bone dehiscence and fenestration, it is not clear whether PAOO is still applicable and beneficial to the periodontal tissues, in view of this, the present study was conducted.

In our current study, there were no significant difference in BI, PD and KGW (between at the baseline, postoperative 3, 6 and 12 months), which was in line with the previous study conducted by Miyamoto T et al, periodontal parameters were identified to remain stable after the implementation of PAOO surgery supplied by deproteinized bovine bone mineral with 10% collagen (DBBM-C) or without [24]. BI and PD are closely related to plaque biofilm and gingival inflammation; keratinized gingiva is of great significance for periodontal tissues to resist external stimulation, and its ability to resist inflammation was identified to be positively related to the KGW [25]. Based on the data obtained from our present study, well-controlled plaque could be achieved with good oral hygiene habits, and PAOO didn't increase the risk of gingival inflammation, for the reduced time within fixed appliance not facilitate the conversion of commensal bacterial biofilms to destructive periodontopathic organisms [26]. In addition, the proportion of teeth with thick gingival phenotype was increased from 43.6% (at baseline) to 63.3% (12 months post-surgery) in the present study, this encouraging results may be the results of GBR procedure, which aimed to periodontal bone regeneration, and the gingival thickness was identified to be positively correlated with the alveolar bone width, then the increase of bone thickness (at mid-root and crestal level) observed in the present study may lead to the increase of thick gingival phenotype [27]. In general, thick gingival phenotype was correlated with a relatively well clinical therapeutic effect, which indicated a relatively promising therapeutic effect of PAOO in patients with bone fenestration and dehiscence. Gingival recession is a commonly complication in orthodontic treatment and it was reported that about 15% of the patients suffer development or aggravation of gingival recession after orthodontic implementation [28]. However, in this particular study, 112 teeth sites without gingival recession before the treatment demonstrated no developing gingival recession 12 months after the operation. On contrary, a significantly reduction in GRD was recognized in the gingival recession sites at the end of observation period. The significant effect on reducing the gingival recession and covering the exposed root may be correlated with the coronally advanced flap technology. Additionally, the improved stability of the periodontium was considered to be a result of managing bone dehiscence and fenestration, which can decrease the possibility of periodontal tissue recession [8]. Collectively, these obtained data indicated that the PAOO procedure does not increase the risk of gingival recession and tissue inflammation in patients with bone fenestration and dehiscence, and to a certain degree, performing PAOO technology may be beneficial to the gingival recession sites.

In addition to the reduced periodontal concerns, PAOO procedure was identified to facilitate the increase of bone volume. A previous study reported that both the alveolar bone height and width was increased significantly after the implementation of PAOO procedure. Also, a recent study conducted by Liu and colleagues demonstrated that PAOO treatment can provide adequate graft stabilization in terms of

superior coronal augmentation and favorable vertical volume [29]. Coscia et al revealed that PAOO can remarkably increase the horizontal ridge thickness (at the mid-root and apex level) of lower anterior teeth, while no statistical change within vertical alveolar bone was identified [30]. In our current study, the bone height and width (at the mid-root and crestal level) were increased markedly compared with the baseline records, although the increase in apical level was not statistically significant. The observed increase in bone thickness and height could be positively related to the bone grafting and the RAP phenomenon [31].

Root resorption is an undesirable sequelae of traditional orthodontic treatment associated with a long treatment duration [32], usually attributed to the hyalinization necrosis of periodontal ligament, and commonly identified in adults. However, significant root resorption was not identified in the current study, which was in accordance with the previous findings [24]. Based on the current understanding, after PAOO surgery performed, cortical incision initiates the RAP phenomenon to reduce the resistance to tooth movement, leading to the decrease of the orthodontic treatment time and reduce of root resorption.

The present study, combined with previously published data show that, as a technology combines corticotomy-facilitated orthodontics, alveolar augmentation, and periodontal treatment, PAOO treatment facilitates the management of pre-existing bone fenestration and dehiscence, further improving the periodontal stability. However, Although the present study demonstrated favorable results based on the outcomes obtained, there still exists some limitations, the long-term clinical efficacy of PAOO in adult patients with bone fenestration and dehiscence remains unknown. Besides, although the quantity of new bone was identified, the quality of the newly formed bone also needs to be measured and analyzed. In the future studies, we will expand the data pool and continue the study along with histologic analysis, to provide more basic theory and clinical basis for the proper use of PAOO.

5. Conclusion

Data obtained from the present study shows that PAOO may represent a safe and promising effective treatment for adults with bone fenestration and dehiscence, which can result in an improvement of periodontal health, and simultaneously facilitate the repair of bone dehiscence and fenestration in the labial aspect of the mandibular anterior area. However, further clinical investigations with long-period should be performed to evaluate the long-term post operatory stability of PAOO procedure.

6. List Of Abbreviations

Periodontally accelerated osteogenic orthodontics (PAOO)

Regional accelerated phenomenon (RAP)

Bleeding index (BI)

Probing depth (PD)

Keratinized gingiva width (KGW)

Gingival recession height (GRH)

Cemento-enamel junction (CEJ)

Root length (RL)

Bone thickness at apical level (ABT)

Bone thickness at mid-root level (MBT)

Bone thickness at crestal level (CBT)

Vertical bone height (VBH)

Declarations

Consent for publication

the authors have no competing interests as defined by BMC, or other interests that might be perceived to influence the results or discussion reported in this paper.

Competing interests

The authors declare that they have no interest conflicts.

Author Contributions

Conceptualization: Ziling Chen, Kaili Zhang,Yue Chen

Formal Analysis: Ziling Chen,Kaili Zhang,Xu Wang

Investigation: Ziling Chen, Xu Wang

Methodology: Ziling Chen, Kaili Zhang, Xu Wang,Liangqiuyue Zhong

Project Administration: Yue Chen,Yuxia Hou

Writing – Original Draft: Ziling Chen,Kaili Zhang,Xu Wang

Writing – Review & Editing: Yue Chen, Huan Zhou,Yuxia Hou

Ethics approval and consent to participate

This study was approved by the ethics committee of stomatological hospital affiliated to Xi'an Jiaotong University (xjkqll[2019]NO.016) and registered in Chinese Clinical Trial Registry (ChiCTR2100053092).

The authors would like to acknowledge for statistical analysis of research reported in this publication which supported by Department of Statistics, School of Public Health, Xi'an Jiaotong University.

Availability of data and materials

All data generated or analyzed during this study are included in this published article.

Funding Information

Medical research project of the 2018 " Science and Technology plus" Action Plan

Number: 201805100YX8SF34□1□

References

1. Hou HY, Li CH, Chen MC, Lin PY, Liu WC, Cathy Tsai YW, Huang RY. A novel 3D-printed computer-assisted piezocision guide for surgically facilitated orthodontics. Am J Orthod Dentofacial Orthop. 2019 Apr;155(4):584–591.
2. Yi J, Xiao J, Li Y, Li X, Zhao Z. Efficacy of piezocision on accelerating orthodontic tooth movement: A systematic review. Angle Orthod. 2017 Jul;87(4):491–498.
3. Johal A, Joury E. What factors predict the uptake of orthodontic treatment among adults? Am J Orthod Dentofacial Orthop. 2015 Jun;147(6):704–10.
4. Amit G, Jps K, Pankaj B, Suchinder S, Parul B. Periodontally accelerated osteogenic orthodontics (PAOO) - a review. J Clin Exp Dent. 2012 Dec 1;4(5):e292-6.
5. Ong MM, Wang HL. Periodontic and orthodontic treatment in adults. Am J Orthod Dentofacial Orthop. 2002 Oct;122(4):420–8.
6. Ferguson DJ, Wilcko MT, Wilcko WM, Makki L: Scope of treatment with periodontally accelerated osteogenic orthodontics therapy. Semin Orthod 21(3): 176e186, 2015
7. Wilcko WM, Wilcko T, Bouquot JE, Ferguson DJ. Rapid orthodontics with alveolar reshaping: two case reports of decrowding. Int J Periodontics Restorative Dent. 2001 Feb;21(1):9–19.
8. Singh S, Jayan B. Comparative Evaluation of Periodontally Accelerated Osteogenic Orthodontics (PAOO) Versus Conventional Orthodontic Tooth Movement in Adult Patients with Bimaxillary Dentoalveolar Protrusion. Int J Periodontics Restorative Dent. 2019 Jul/Aug;39(4):571–577.
9. Farina R, Salinas F, Zurbuchen A, Hinojosa A, Barreda M: Corticotomy-assisted Le ~ Fort I osteotomy: an alternative to segmentation of the maxilla in orthognathic surgery. J Craniofac Surg 26(4): 1316e1320, 2015
10. AlHammadi HA, Wilcko MT, Ferguson DJ. Severe Mandibular Crowding Treated with Nonextraction Periodontally Accelerated Osteogenic Orthodontics. Int J Periodontics Restorative Dent. 2019 Sep/Oct;39(5):e188-e194.

11. Muñoz F, Wilcko T, Acuña S, Gracia B, Sanhueza V, Palacios S, O'Ryan JA. Periodontally Accelerated Osteogenic Orthodontics (PAOO) technique in cleft patients: A complement to orthognathic surgery in dentoalveolar expansion. A case series report. J Craniomaxillofac Surg. 2020 Nov;48(11):1028–1034.
12. Soltani L, Loomer PM, Chaar EE. A Novel Approach in Periodontally Accelerated Osteogenic Orthodontics (PAOO): A Case Report. Clin Adv Periodontics. 2019 Sep;9(3):110–114.
13. Nowzari H, Yorita FK, Chang HC. Periodontally accelerated osteogenic orthodontics combined with autogenous bone grafting. Compend Contin Educ Dent. 2008 May;29(4):200–6; quiz 207, 218.
14. Koke U, Sander C, Heinecke A, Müller HP. A possible influence of gingival dimensions on attachment loss and gingival recession following placement of artificial crowns. Int J Periodontics Restorative Dent. 2003 Oct;23(5):439–45.
15. Leung CC, Palomo L, Griffith R, Hans MG. Accuracy and reliability of cone-beam computed tomography for measuring alveolar bone height and detecting bony dehiscences and fenestrations. Am J Orthod Dentofacial Orthop. 2010 Apr;137(4 Suppl):S109-19.
16. Yagci A, Veli I, Uysal T, Ucar FI, Ozer T, Enhos S. Dehiscence and fenestration in skeletal Class I, II, and III malocclusions assessed with cone-beam computed tomography. Angle Orthod. 2012 Jan;82(1):67–74.
17. Enhos S, Uysal T, Yagci A, Veli İ, Ucar FI, Ozer T. Dehiscence and fenestration in patients with different vertical growth patterns assessed with cone-beam computed tomography. Angle Orthod. 2012 Sep;82(5):868–74.
18. Rothe LE, Bollen AM, Little RM, Herring SW, Chaison JB, Chen CS, Hollender LG. Trabecular and cortical bone as risk factors for orthodontic relapse. Am J Orthod Dentofacial Orthop. 2006 Oct;130(4):476–84.
19. Bahammam MA. Effectiveness of bovine-derived xenograft versus bioactive glass with periodontally accelerated osteogenic orthodontics in adults: a randomized, controlled clinical trial. BMC Oral Health. 2016 Nov 30;16(1):126.
20. Wang B, Shen G, Fang B, Yu H, Wu Y, Sun L. Augmented corticotomy-assisted surgical orthodontics decompensates lower incisors in Class III malocclusion patients. J Oral Maxillofac Surg. 2014 Mar;72(3):596–602.
21. Mazza JE, Newman MG, Sims TN. Clinical and antimicrobial effect of stannous fluoride on periodontitis. J Clin Periodontol. 1981 Jun;8(3):203–12.
22. Alkan Ö, Kaya Y, Tunca M, Keskin S. Changes in the gingival thickness and keratinized gingival width of maxillary and mandibular anterior teeth after orthodontic treatment. Angle Orthod. 2021 Jul 1;91(4):459–467.
23. Xu X, Wu JQ, Jiang JH, Liang C, Wang XE, Jing WD, Xu L. Periodontal Effect of Periodontally Accelerated Osteogenic Orthodontics in Skeletal Angle Class III: A Nonrandomized, Controlled Trial. Int J Periodontics Restorative Dent. 2020 Jul/Aug;40(4):e169-e177.

24. Miyamoto T, Lang M, Khan S, Kumagai K, Nunn ME. The clinical efficacy of deproteinized bovine bone mineral with 10% collagen in conjunction with localized piezosurgical decortication enhanced orthodontics: A prospective observational study. J Periodontol. 2019 Oct;90(10):1106–1115.
25. Wilcko MT, Ferguson DJ, Makki L, Wilcko WM. Keratinized Gingiva Height Increases After Alveolar Corticotomy and Augmentation Bone Grafting. J Periodontol. 2015 Oct;86(10):1107–15.
26. Mattingly JA, Sauer GJ, Yancey JM, Arnold RR. Enhancement of Streptococcus mutans colonization by direct bonded orthodontic appliances. J Dent Res. 1983 Dec;62(12):1209–11.
27. Younes F, Eghbali A, Raes M, De Bruyckere T, Cosyn J, De Bruyn H. Relationship between buccal bone and gingival thickness revisited using non-invasive registration methods. Clin Oral Implants Res. 2016 May;27(5):523–8.
28. Melsen B, Allais D. Factors of importance for the development of dehiscences during labial movement of mandibular incisors: a retrospective study of adult orthodontic patients. Am J Orthod Dentofacial Orthop. 2005 May;127(5):552–61; quiz 625.
29. Liu X, Fan B, Abdelrehem A, Ma Z, Yang C. Membrane fixation for osseous graft stabilization in periodontally accelerated osteogenic orthodontics: a comparative study. BMC Oral Health. 2020 Jan 28;20(1):22.
30. Coscia G, Coscia V, Peluso V, Addabbo F. Augmented corticotomy combined with accelerated orthodontic forces in class III orthognathic patients: morphologic aspects of the mandibular anterior ridge with cone-beam computed tomography. J Oral Maxillofac Surg. 2013 Oct;71(10):1760.e1-9.
31. Bhattacharya P, Bhattacharya H, Anjum A, Bhandari R, Agarwal DK, Gupta A, Ansar J. Assessment of Corticotomy Facilitated Tooth Movement and Changes in Alveolar Bone Thickness - A CT Scan Study. J Clin Diagn Res. 2014 Oct;8(10):ZC26-30.
32. Hatrom AA, Howait MS, Zawawi KH, Al-Turki GA, Alansari RA, Almehayawi NF, Alammari SH, Mohammed RA, Hassan AH. Pulp volume changes after piezocision-assisted tooth movement: a randomized clinical trial. BMC Oral Health. 2021 Jan 13;21(1):28.

Figures

Figure 1

Flowchart

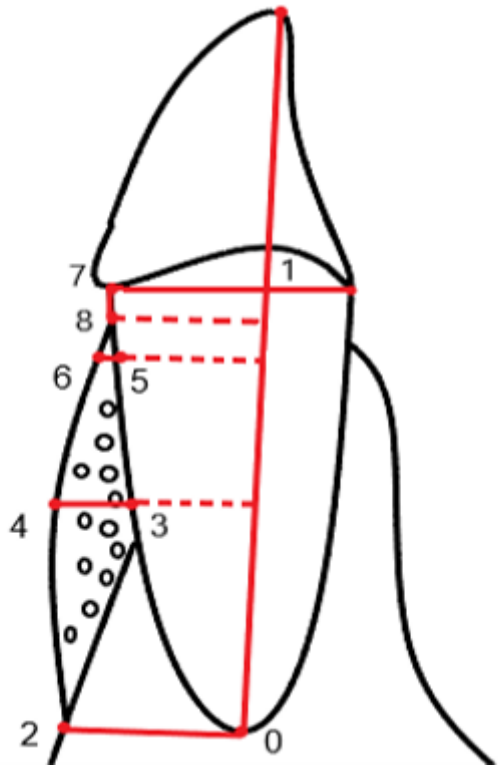

Figure 2

Schematic diagram of radiographic measurements. (0-the root apex; 1- the intersection of labial-lingual CEJ line and the long axis; 2- the intersection of the labial alveolar bone surface and the line perpendicular to the long axis which is through dot 0; 3-the mid-root point of the labial root surface; 4-the intersection of the labial alveolar bone surface and the line perpendicular to the long axis which is through dot 3; 5-the point 2mm below labial CEJ; 6-the intersection of the labial alveolar bone surface and the line perpendicular to the long axis which is through dot 5; 7-labial CEJ; 8-the alveolar crest .)

Figure 3

Surgical procedure of PAOO. (a) Presurgical treatment. (b) Full-thickness flap reflection (yellow dotted lines show bone dehiscence). (c) Performing corticotomies in the interradicular space. (d) Placing grafting materials on the surface of alveolar bone. (e) Collagen membrane covering grafting materials. (f) Interrupted sutures. (g) Six-month retention. (h) Twelve-month retention.

Figure 4

CBCT images of mandibular anterior teeth before and after surgery (6m, 12m)