A Novel Suture Bridge Anchor Fixation Technique to Treat Inferior Pole Fractures of Patella：a Retrospective Clinical Study

Bingqian Chen (kgx2327@suda.edu.cn)
Changshu Hospital Affiliated to Soochow University, First Peoples' Hospital of Changshu City, China

zhengfei wang
Changshu Hospital Affiliated to Soochow University, First Peoples' Hospital of Changshu City, China

xiaohong qu
Changshu Hospital Affiliated to Soochow University, First Peoples' Hospital of Changshu City, China

xiaowen fang
Changshu Hospital Affiliated to Soochow University, First Peoples' Hospital of Changshu City, China

zhi chen
Changshu Hospital Affiliated to Soochow University, First Peoples' Hospital of Changshu City, China

yufeng qian
Changshu Hospital Affiliated to Soochow University, First Peoples' Hospital of Changshu City, China

xuesong wang
Affiliated Hospital of Jiangnan University, Wuxi, Jiangsu, China

Research Article

Keywords: inferior pole fracture of patella, double row anchor, suture bridge

Posted Date: April 22nd, 2022

DOI: https://doi.org/10.21203/rs.3.rs-1550264/v1

Abstract

Background:

The fracture of the lower pole of patella is common and the fracture block is small and mostly comminuted. The traditional surgical methods include steel wire tension band fixation and inferior patellar resection, which have many disadvantages. In order to overcome the disadvantages of traditional surgery, we innovated and improved the double row anchor suture bridge technology to the treat the inferior patellar fracture. This study is to investigate the method, technique and clinical efficacy of double-row anchor suture bridge technique in the treatment of inferior pole fractures of patella.

Methods:

Between January 2019 and March 2021, 36 patients with inferior pole fractures of patella underwent the surgery with the double-row anchor suture bridge technique. The study sample consisted of 19 males and 17 females, aged 31–72 years old. There were 17 cases of right fractures and 19 cases of left fractures, all of which were closed fractures. 28 injury cases were caused by falls while 8 injury cases were from car accidents. All of the patients were ethnic Chinese. The operation time, amount of intraoperative bleeding and complications were recorded. Radiological assessments and Bostman score were performed 1, 3 and 6 months post-operation and at the most recent follow-ups.

Results:

The operation time was 54–76 minutes and the intraoperative blood loss was 28–46 ml. All incisions healed in one stage and stitches were removed after 2 weeks. No complications such as incision infection, flap necrosis and nerve injury occurred. Patients in this group were followed up for 10–18 months, with an average follow-up of 12 months. All fractures healed in 10–20 weeks, with an average healing time of 12 weeks. At the last follow-up, the Bostman score was (27.5 ± 3.3), excellent in 34 cases and good in 2 cases, with an excellent rate of 94.4%. The range of motion of the knee joint was (-2.6 ± 2.0)° when the knee was extended and (120 ± 5.0)° when the knee was bent. The muscle strength of quadriceps femoris was grade 5.

Conclusion:

Double-row anchor suture bridge technique is applied to inferior pole fractures of patella by virtue of its various effects, such as the complete preservation of the inferior pole fragments during the operation, satisfactory fracture reduction, firm fixation, and meeting patients' requirements for early postoperative ambulation. In summary, double-row anchor suture bridge technique is an ideal surgical procedure for the treatment of the inferior pole fracture of patella with safety, reliability and high satisfaction.

Introduction

Inferior pole fracture of patella is clinically difficult to treat due to the inherent weakness of small comminuted distal fragments[1]. Currently, wire tension band fixation and resection of the inferior pole of patella are the preferred surgical treatments for inferior pole fractures of patella. Each treatment has its own advantages and disadvantages therefore provides inconsistent efficacy. Resection of the inferior pole of patella is rarely applied currently for the reason that it changes the bio-mechanical characteristics of the patella, causes weakened quadriceps muscle strength and patellofemoral arthritis, and affects the function of the knee joint[2]. In contrast, Kirschner wire tension band internal fixation is commonly applied. The wire is placed on the tension side of the patella and the tension it is subjected to will change into the compressive stress at the fracture end during knee flexion, consequently promote the fracture healing. In the traditional AO tension band technique, two Kirschner wires are fixed in the center of the bone and the “8”-shaped steel wire is fixed at both ends of the Kirschner wires[3]. It is reported that although the tension band wire fixation method is reliable and achieves satisfactory clinical outcomes, it also has numerous drawbacks[4] such as: not suitable for small and comminuted bones, Kirschner wires can pierce the skin and cause painful infections, a second operation is performed to remove Kirschner wire.

Suture anchor technique has also been applied in the treatment of inferior pole fractures of patella as it continues to develop. It is superior to wire tension band fixation and resection of the inferior pole of patella on account of its advantages of retaining fracture fragments of the inferior pole of patella, which are no need to take out the internal fixation, bone-bone healing superior to tendon-bone healing and no Kirschner wire withdrawal[5][6]. Nevertheless, traditional anchor technique alone is unable to provide sufficient stability for the fractured end and patients often need to be protected by a brace postoperatively. In addition, active knee joint functional exercises can not be performed at early stage and the reduction of comminuted fractures is less than optimal.

To overcome the shortcomings of traditional surgical methods, innovation and improvement have been made on the double-row anchor suture bridge technique in rotator cuff repairs, which is applied to the treatment of inferior pole fractures of patella. Specifically, after the fracture fragments and ligaments are sutured by the internal-row of anchors, the sutures are compressed on the surface of the patella by the external-row of extrusion nails, which is similar to a parachute bag. In consequence, it can enhance the stability of the fracture without the need for secondary removal of internal fixation that has significant advantages. It is indicated by the literature review that there have been few reports of a similar technique in the treatment of inferior pole fractures of patella.

This study has retrospectively analyzed the clinical and radiographic outcomes of performing the double-row anchor suture bridge technique to inferior pole fractures of patella. The specific details are reported as follows:

Materials And Methods

The retrospective study was approved by Institutional Review Board approval. Between January 2019 and March 2021, 36 patients with inferior pole fractures of patella underwent the surgery with the double-row anchor suture bridge technique. These including 19 males and 17 females, aged 31-72 years old, with an average of (52.4±5) years old. Among them, there were 17 cases of right fractures and 19 cases of left fractures, all of which were closed fractures. 28 injury cases were caused by falls while 8 injury cases were from car accidents. All of the patients were ethnic Chinese.

Inclusion criteria: inferior pole fractures of patella, closed fracture.

Exclusion criteria: fractures involving articular surfaces, open fractures and local infectious lesions.

All patients underwent routine X-ray and CT scan for three-dimensional reconstruction. After admission, patients were given ice compress, temporary immobilization of brace, and pain relief. Surgery was performed after completion of the intraoperative examination and 3-4 days after the injury.

1.2 Surgical methods

After satisfactory anesthesia, routine disinfection was performed. An incision was made layer by layer to reveal the inferior pole fractures of patella and the patellar ligament. Subsequently the hematoma and soft tissue of the fractured end were straightened out. At the proximal end of the patella fracture, two suture anchors (one medial and one lateral) were screwed close to the articular surface of the patella, each with two sutures. Kirschner wire was utilized to drill longitudinally at the inferior pole fractures of patella, and the patellar ligament was sutured with transverse mattress suture for several stitches through both ends of the anchor suture line. After reduction and tightening of the fractured end, a total of 4 knots were tied. Consecutively, four knotted tail wires were gathered to cover the bone fragments of the inferior pole of the patella, and then passed through a Johnson & Johnson Versalok extrusion anchor to drive into the bone at the upper end of the patella. Finally, X-ray fluoroscopy confirmed that the fracture was ideally reduced, the knee joint was moved and the fracture was fixed firmly. See Figure 1.

1.3 Postoperative management and follow-up

The patients were given ice compress, pain relief and swelling treatment postoperatively. On the first day after surgery, patients were able to do functional exercises of the knee and ankle and perform functional exercises of the knee on a CPM machine from 45° to 120° three times a day for half an hour each. On the third day, patients were able to move with crutches out of bed. Around three months post surgery, patients resumed their daily activities. X-ray examinations were performed on the patients in January, March, June, and December to observe the fracture healing.

The postoperative incision healing and postoperative complications were recorded together with the knee joint function score. The efficacy evaluation criteria of Bostman patella fracture was utilized to score the

patella fracture in terms of range of motion, duration of motion, pain and atrophy: excellent (28-30 points), good (20-27 points), poor (<20 points).

1.4 Statistical analysis

All data in this study were statistically analyzed by using SPSS 19.0 software. Measurement data were expressed as (x±s), and paired sample T test was used for comparison. The level of significance was set at $P<0.05$. Each examiner was blinded to the results obtained by the other examiner.

Results

The operation time was (54-76) min, with an average of (56±10) min and the intraoperative blood loss was (28-46) ml, with an average of (40±9) ml. All incisions healed in one stage and stitches were removed after 2 weeks. No complications such as incision infection, flap necrosis and nerve injury occurred. Patients in this group were followed up for 10-18 months, with an average follow-up of 12 months. All fractures healed in 10-20 weeks, with an average healing time of 12 weeks. At the last follow-up, the Bostman score was (27.5±3.3), excellent in 34 cases and good in 2 cases, with an excellent rate of 94.4%. The range of motion of the knee joint was (-2.6±2.0)° when the knee was extended and (120±5.0)° when the knee was bent. The muscle strength of quadriceps femoris was grade 5. See table 1

Table 1: Personal information and rates of excellent results

N	Mean age	Mean operation time	Mean bleeding	Rates of excellent results (%)
32	52.4±5	56±10	40±10	94.4

Discussion

3.1 Characteristics of inferior pole fractures of patella and disadvantages of traditional surgical methods

Inferior pole fractures of patella are clinically common, accounting for approximately 9.3%-22.4% of all patella fractures[1]. It has the following characteristics: Firstly, the fracture fragments are small and most of them are comminuted, Secondly, the inferior part of the patella is the insertion point of the patellar tendon, which is subjected to greater tensile stress. For that reason, the fracture is under a certain degree of particularity and difficulty in reduction and fixation[2] [3] [7].

Up to this time, wire tension band fixation and resection of the inferior pole of patella, etc. are the preferred surgical treatments for inferior pole fractures of patella[8] [9]. Resection of the inferior pole of patella is rarely applied at present because it changes the biomechanical characteristics of the patella, causes weakened quadriceps muscle strength and patellofemoral arthritis and affects the function of the knee joint.

In contrast, Kirschner wire tension band internal fixation is widely applied. In this method, the steel wire is placed on the tension side of the patella, and the tension it is subjected to will change into the compressive stress at the fracture end during knee flexion therefore promote the fracture healing[10][11]. In the traditional AO tension band technique, two Kirschner wires are fixed in the center of the bone while the “8”-shaped steel wire is fixed at both ends of the Kirschner wires. It is reported that although the tension band wire fixation method is reliable and achieves satisfactory clinical outcomes, it also has numerous drawbacks[12]. First of all, this technique is not appropriate for small bones. Secondly, the fixation technique for comminuted fracture is not reliable. In addition, Kirschner wire tension band is prone to Kirschner wire withdrawal, which can compress the skin and cause pain, or on occasions pierce the skin. Finally, Kirschner wire tension band must be removed by a second operation, which can contribute to increased patient pain and medical costs[13].

3.2 Advantages and disadvantages of traditional anchor technique

Suture anchor was first applied in the treatment of rotator cuff tears and gradually applied in the treatment of inferior pole fractures of patella with the development of techniques in orthopedic[14][15]. Fixation of comminuted fractures of the inferior pole of the patella with suture anchors can not only restore the integrity of the knee extension device, but also preserve the fracture of the inferior pole of the patella. Concurrently, bone-bone healing is also superior to tendon-bone healing. Ultimately, suture anchor does not need to be removed subsequently a secondary operation is avoided[16]. In summary, this technique has obvious advantages over traditional wire tension band internal fixation and resection of the inferior pole of patella.

The traditional suture anchor method is a single row anchor fixation, which also has many drawbacks[16][17]. First of all, single-row anchors rely only on sutures, which can not provide sufficient stability at the fracture end and prevent early ambulation postoperatively. Moreover, for comminuted fractures, fracture fragments can not be reduced well by wire anchors alone, which may easily cause displacement of fracture fragments.

3.3 Advantages of double-row anchor suture bridge technique

“Double-row anchor suture bridge technique” is a novel technique for arthroscopic repair of rotator cuff tears[18], which was first proposed by Park in 2006[12]. Firstly, the sutures of the internal-row anchors passed through the tendon in a horizontal mattress and were knotted. After passing the suture tail through the external-row pressing screw, the external-row nails were inserted into the greater tubercle of the humerus at the lateral insertion point of the rotator cuff, so as to complete the uniform extrusion of the rotator cuff by the “suture bridge”. This technique is more stable than the traditional anchor fixation technique and has greater anti-pulling strength. Furthermore, due to the extrusion pressure of the “suture bridge” on the rotator cuff, the contact surface between tendon and bone is increased and the tendon and bone healing is promoted. In view of the advantages of suture bridge technique, this technique has gradually been widely applied in shoulder surgery, and its scope of application has also been expanded to be used in the treatment of some fractures. It has been reported in literature[14][15]that some scholars

have applied this technique to the treatment of avulsion fractures of the greater tuberosity of humerus and intercondylar spine avulsion fractures of the tibia, achieving satisfactory clinical results. However, there have been no reports about the application of this technique in the treatment of patellar fractures.

In order to overcome the shortcomings of the traditional suture anchor method, we modified the technique of “double-row anchor suture bridge” in shoulder arthroscopy and applied it to the treatment of the fracture of the inferior pole of patella. Specifically, two internal row anchors were screwed into the proximal end of the patella fracture. Subsequently, the sutures were passed through the inferior pole fracture fragments via the bone tunnel and the patellar ligament was sutured with horizontal pad and knotted. The tail line of the suture was arranged to cover the bone fragments at the lower part of the patella. After passing the tail of the suture through the external extrusion anchor, the external extrusion nail was driven into the upper part of the patella (see Figures A-B). This technology not only strengthens the stability of the fracture, but also gathers the lower pole fragments and maintains the reduction of the fracture. Since the sutures of the anchors wrap around the bone fragments below the patella in the shape of a parachute, it is also known as “parachute technique”.

Although Kim KS[18] reported that the suture bridge anchor technique was used to fix the fracture of the lower pole of the patella, the technique in this study was different from theirs. First of all, their technology need two extrusion anchors, while the technique implemented here only used one, which saved the cost of surgery. Simultaneously, the extrusion anchors were reported to be driven into the both sides of the patella according to Kim KS. However in this study, the extrusion anchors was driven into the bone at the upper end of the patella as this part of the bone is thicker and stronger, which can obtain better fixation strength.

The technique used in this research is to treat the fracture of the lower pole of the patella. Patients were able to exercise the flexion and extension function of the knee joint early after operation. No loosening of internal fixation and re-displacement of the fracture were found. All fractures healed and achieved satisfactory clinical results. It was discovered that comminuted fractures benefited from utilizing this technique, which could not only increase the stability of the fixation, but also close and reduce the fracture block. In this group, All comminuted fractures were healed well without fracture displacement and loss of reduction.

3.4 Points of attention and surgical experience

First of all, the two anchored implant points should be lower than the center of the patella section, close to the subchondral bone and need to be screwed to a sufficient depth in order to achieve the maximum holding force. For patients with relatively loose bones, the screw can be screwed deeper until it approaches or even breaks through the cortical bone at the upper end of the patella to increase the holding force of the anchor. If the anchor is found to be loose when screwed in, it is estimated that sufficient stability can not be obtained therefore it is necessary to replace or assist other internal fixation methods. At the initial stage of the operation, one case was found to have a loose screw anchor during the operation hence other internal fixation methods were implemented in time. In the coronal position, the

two anchors should be positioned equally on either side of the midline of the patella to facilitate fracture reduction and stress distribution. All the patients in this group were operated on according to the above methods. On that account, no loosening of anchor or loss of fracture block reduction was found.

Secondly, after the suture passes through the fracture of the lower pole, one end of the tail line needs to be sewed into the patellar ligament for 2-3 stitches and then tied into the other end for fixation. Direct knotting may result in cutting of bone, especially in comminuted fractures. After all the four wires are knotted, the position of the tail wire should be adjusted and the broken bones of the bottom pole should be covered as much as possible, which is resembling a parachute bag, in order to achieve the optimal fixing outcome. All cases in this group were performed according to the above methods and no tendon cutting or loss of fracture block reduction was found.

Moreover, intraoperative fluoroscopy is required to ensure that the extrusion screw is in the center of the upper pole of the patella when the external extrusion screw is inserted and attention should be paid to the matching perforator to open the bone canal. In case of too small perforator and insufficient bone canal diameter, splitting of the bone canal wall may occur when the extrusion anchors are inserted. In severe cases, iatrogenic fractures may occur. Meanwhile, proper tail line tension needs to be adjusted for driving the extrusion anchors. Too little tension may make it impossible to achieve favorable fixation and too much tension may result in the cutting of the bone tunnel wall with sutures and displacement of the inferior pole fracture.

Finally, after the fracture is fixed, the two patellas are circulated with non-absorbable ETHIBOND suture to strengthen the fixation. Bend and extend the knee joint to confirm that the fractured end is firmly fixed and not separated. If instability is found, a brace is recommended for postoperative protection.

Declarations

We make a statement that all authors have agreed to the submission to the journal and that the manuscript is not currently under submission in any other journals.

-Ethical Approval

The experimental protocol was established according to the ethical guidelines of the Helsinki Declaration and was approved by the Human Ethics Committee of First Peoples' Hospital of Changshu City. Written informed consent was obtained from individual participants or guardians. The Ethics Approval Report :LSS (application) batch No. 12 in 2021.

-Consent to Participate

All data generated or analyzed during this study are included in this published article and its supplementary information files.

-Consent to Publish

Not applicable

-Authors Contributions

Conceived and designed the experiments: Bingqian Chen

Performed the surgeries: Bingqian Chen, Xiaohong Qu Xiaowen Fang

Data acquisition and analysis: Bingqian Chen, zhi Chen Yufeng Qian

Wrote the manuscript: Bingqian Chen, Zhengfei Wang

-Funding

This research received no specific grant from any funding agency in the public, commercial, or not-for-profit sectors.

-Competing Interests

The authors declare no conflicts of interest

-Availability of data and materials

All data generated or analysed during this study are included in this published article .

Acknowledgements:

I would like to show my deepest gratitude to my supervisor, Dr. Qirong Dong, a respectable, responsible and resourceful scholar. I shall extend my thanks to Mrs. Ke for all her kindness and help. Last but not least, I would like to thank all my friends for their encouragement and support.

References

1. Henrichsen JL,Wilhem SK,Siljander MP,et al. ,2018Treatment of patella fractures[J]. Orthopedics , 41(6):e747-e755.
2. Sigvard T,2007Rockwood and green’s fractures in adults. 6th ed[J]. Jbjs ,89:511.
3. Ma Xiangyu, Xiang Liangbi, Liu Bing, Zhou Dapeng,(2020) Progress in the treatment of partial resection of fractures of the lower pole of the patella[J]. Clinical Journal of Medical Officers. 48(04): 478-480.
4. Li Lantao, He Haichao, Li Zhong, et al. , (2014) Modified patella tibial tuberosity cerclage technique for the treatment of the lower pole of the patella[J]. Chinese Journal of Bone and Joint Injury, 29(S1):79.
5. Tian Jian, Xu Yajun, Chen Zheng, etc. , (2017) Effectiveness analysis of limited small incision with simple Krackow suture in treatment of acute closed Achilles tendon rupture[J]. Chinese Journal of

Reconstructive and Reconstructive Surgery, 31(11):1322-1325.

6. Lysholm J, Gillguist J, (1982) Evaluation of knee ligament surgery results with special emphasis on use of ascoring scale[J]. Am J SportsMed, 10(3):150-154.
7. Lu Tianxiang, Yang Hua, Chen Zunrong, etc. , (2016) A case report of repair, reconstruction and rehabilitation of patellar tendon rupture of high-level long jump athletes[J]. Chinese Journal of Sports Medicine, 35(1):71-73.
8. Chen Nong, Li Zhi, Dong Jian, et al. , (2011)Application of suture anchors in the treatment of ankle deltoid ligament injury[J]. Chinese Journal of Bone and Joint Injury, 26(7): 235-236.
9. Khazen GE, Wilson AN, Ashfap S, et al. , (2007) Fixation of calcaneal avulsion fractures using screws with and without suture anchors: a biome-chanical investigation[J]. Foot Ankle Int,28(11):1183-1186.
10. Gu Deshuai, Zhu Ren, Yu Wenjun, Zhang Liwen.,(2018)Clinical application of absorbable net-sliding intertexture with tension band wiring comminuted fracture of inferior patella pole[J]. China Journal of Orthopaedics and Traumatology. 31(10):903-906.
11. Misir, A. , Kizkapan, T. B. , Uzun, E. , Oguzkaya, S. , & Golgelioglu, F. . (2019). Fracture patterns and comminution zones in ota/ao 34c type patellar fractures. Journal of Orthopaedic Trauma, 1.
12. Shi Dufang, Wang Dongmei, et al. , (20l0)Tensile and Viscoelastic Properties of Chinese Patellar Ligaments: Preliminary Comparison between Chinese and Westerns[J]. Journal of Chinese Biomedical Engineering, 4(2): 314-320.
13. Wang Peizhao, Han Xu, Wang Xiao, Yu Jinyang, Yuan Yanhao, Tan Honglue. , (2020)Clincal observation of non-absorbable suture cerclage combined with patella claw fixation for treatment of inferior patella fractures[J]. Chinese Journal of Reconstructive and Reconstructive Surgery,34(10):1243-1247.
14. Zhang Dabao, Mao Bo, and Lai Jinping. , (2019) Krachow method suture combined with patella tibial tension band to treat lower pole fracture of patella[J]. Practical Clinical Journal of Integrated Traditional Chinese and Western Medicine,19(02):78-79.
15. Zhang Liang, Zhao Zandong, Kang Xin, Ren Bo, Zhang Xian, and Zheng Jiang. , (2020)Arthroscopic suture bridge technique for elderly patients with shoulder dislocation combined with supraspinatus avulsion fracture[J]. Orthopedics,11(06):475-479.
16. Li Ji, Li Zhongli, Liao Weixiong, Zhang Hao, Wang Ketao, and Yang Yimeng. , (2017)Clinical research on suture anchor fixation for the treatment of avulsion fracture of tibial intercondylar eminence under arthroscopy[J]. China Journal of Orthopaedics and Traumatology, 30(11):1023-1028.
17. Cho J W, Kim J, Cho W T, et al. , (2017) Comminuted inferior pole fracture of patella can be successfully treated with rim-plate-augmented separate vertical wiring[J]. Archives of Orthopaedic and Trauma Surgery, 138(Suppl 2):1-8.
18. Kim, K. S. , Suh, D. W. , Park, S. E. , Ji, J. H. , & Kim, J. H. . (2020). Suture anchor fixation of comminuted inferior pole patella fracture-novel technique: suture bridge anchor fixation technique. Archives of Orthopaedic and Trauma Surgery, 1-9.

Figures

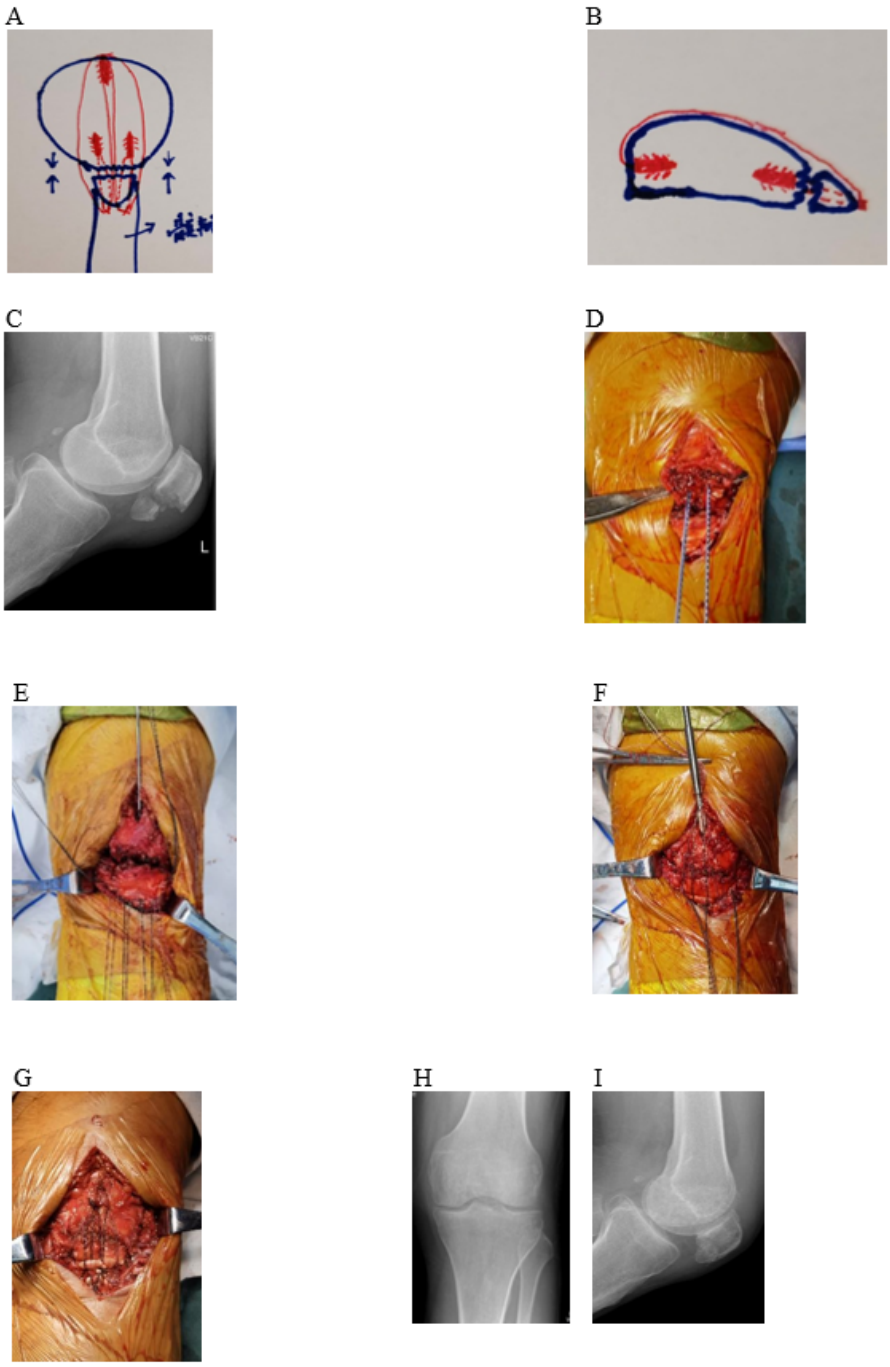

Figure 1

The surgical procedure of this technique and a typical case

Figures A-B. Freehand sketching of double-row anchor suture bridge technique for treatment of inferior pole fractures of patella: two internal-row anchors were driven into the proximal end of the patella fracture and the sutures passed through the inferior pole of the fracture fragments via the bone tunnel. The patellar ligament was sutured in a horizontal mattress and knotted and the tail line of the sutures was arranged to cover the bone fragments at the inferior pole of the patella. After passing the tail of the sutures through the external-row anchors, the external-row anchor was nailed on the top of the patella

Typical case: A 58-year-old male patient was admitted to the hospital due to pain in the left knee joint caused by trauma and limited movement for 1 hour.

Figure C: X-ray shows a fracture of the inferior pole of the left patella with an obvious displacement of the fractured end.

Figures D-G: Open reduction and double-row anchor of inferior patella fracture under epidural anesthesia.

Figure H: Radiographically confirmed ideal reduction of the fracture.

Figure I: One year postoperatively, X-ray radiographs showed good fracture union and no obvious fracture displacement.