Multitrack and multianchor point screw technique combined with the Wiltse approach for lesion debridement in the treatment of lumbar tuberculosis

Yu-fei Yuan
Handan Central Hospital
Zhi-xin Ren
Handan Central Hospital
Yan-bao Li
Handan Central Hospital
Cun Zhang
Handan Central Hospital
Guan-jun Li
Handan Central Hospital
Bing-zhi Liu
Handan Central Hospital
Xiao-dong Li
Handan Central Hospital
Jian-fei Li
Handan Central Hospital
Jie Miao (bumiaojie@163.com)
Handan Central Hospital

Research Article

Keywords: lumbar spine, tuberculosis, debridement, pedicle screw, cortical bone trajectory screw (CBT screw), Wiltse approach

Posted Date: April 20th, 2022

DOI: https://doi.org/10.21203/rs.3.rs-1552799/v1

Abstract

Backgroud: To study the safety and efficacy of the multitrack and anchor point screw technique combined with the Wiltse approach for lesion debridement in the treatment of lumbar tuberculosis.

Methods: We retrospectively enrolled 13 patients with lumbar spinal tuberculosis in our department from October 2014 to January 2021 who underwent unilateral multitrack multianchor screw fixation combined with contralateral Wiltse approach lesion debridement. Preoperative and final follow-up C-reactive protein (CRP), erythrocyte sedimentation rate (ESR), preoperative, 3 months after operation, final follow-up low back pain visual analogue scale (VAS), and Oswestry disability index (ODI) were used for statistical analysis. The American Spinal Injury Association (ASIA) grades were recorded before surgery, 3 months after surgery, and at the final follow-up for all patients to evaluate the clinical effect of the surgery.

Results: The average age of the 13 patients was 60.15±10.31 years old, the average operation time was 150.92±37.32 minutes, and the average blood loss was 415.39±151.91 mL; CRP (3.05±1.82 mg/L) and ESR (5.57±3.70 mm/h) returned to normal, and the difference was statistically significant compared with those before the operation (P<0.01). The VAS score for low back pain in all patients was significantly decreased. The VAS scores for low back pain were 2.23±0.73 and 0.54±0.66 at 3 months after the operation and at the last follow-up, respectively, compared with 7.54±0.97 before the operation, and the difference was statistically significant. (P<0.01). The average preoperative ODI score was 80.31%±3.35% and decreased to 29.08%±1.94% and 19.54%±2.18% at 3 months after the operation and at the last follow-up, respectively, and the difference was statistically significant. (P<0.01). The symptoms of all patients with neurological dysfunction were relieved, and the ASIA grade increased by 1-2 grades at the last follow-up. The mean follow-up time for all patients was 18.23±4.69 months, and the mean bone fusion time was 8.85±2.51 months. There were no internal fixation-related complications, no tuberculosis sinus formation, and no recurrence of lumbar tuberculosis. Two patients were cured of postoperative pneumonia by antibiotic treatment. **Conclusion:** The multitrack multianchor point screw fixation technique combined with contralateral Wiltse approach debridement is an effective and safe method for the treatment of lumbar tuberculosis.

Background

The 2020 Global Tuberculosis Report stated that tuberculosis remains the most common cause of death as a single infectious agent [1, 2]. Spinal tuberculosis was first reported by Pott in 1782, and spinal tuberculosis accounts for approximately 50% of the cases of bone and joint tuberculosis [3]. Lumbar tuberculosis accounts for 42.36% of spinal tuberculosis cases [4]. Spinal tuberculosis lesions often involve the vertebra and intervertebral discs, leading to vertebral destruction and intervertebral space collapse, resulting in intervertebral space abscesses, paravertebral abscesses [5], and angular kyphosis of the spine in severe cases[6]. Patients with lumbar spine tuberculosis may have clinical symptoms such as low back pain and neurological dysfunction, with or without symptoms of tuberculosis toxicity [7]. In cases where medicine fails, surgery should be performed to relieve pain, correct deformity, and improve neurological function [8].

At present, the choice of surgical approach for lumbar tuberculosis remains controversial [9]. The surgical approach is divided into the anterior approach, posterior approach, and anterior-posterior combined approach. Each approach has advantages and disadvantages. The anterior approach can remove tuberculosis lesions and reconstruct the collapsed vertebra under direct vision, but the risk of complications is high due to the complex anatomical structure of vessels and nerves in the anterior lumbar spine [9]. The combined anterior and posterior approach results in a long operation time and substantial intraoperative trauma. The conventional posterior approach requires stripping the paraspinal muscles, removing normal posterior structures such as the lamina to expose and clear tuberculosis lesions, and using the screw rod internal fixation system to reconstruct lumbar lordosis[10, 11].

Tuberculosis patients generally suffer from anaemia, hypoalbuminemia, and nutritional depletion states [12], so the operation should be minimally invasive as much as possible to remove tuberculosis lesions while reducing damage to normal structures and reconstructing the spinal sequence [13]. Based on the above considerations, the author's team tried the posterior unilateral multitrack multianchor screw technique combined with the contralateral Wiltse approach for lesion debridement in the treatment of lumbar tuberculosis.

A 2021 article approved the pedicle screw as one of the top 10 inventions that shaped modern orthopaedics [14]. Pedicle screws were first used in vertebral fusion in 1959 [15], and Roy-Camille first used pedicle screws for spinal fixation in 1963. Through the anterior column, it achieves three-column fixation of the spine, so it has excellent holding force and orthopaedic ability. It needs to be exposed to the isthmus of the lamina. The screw track runs from the medial-caudal to the lateral-cephalic. The screw is driven from the medial side of the lateral edge of the lamina into the posterior part of the superior endplate, and the screw path runs in the cortical bone. There are four cortical bone contact points to hold the screw, so it has a stronger screw holding force, which is especially suitable for patients with osteoporosis, and can be used for the revision of adjacent spondylosis [17] and spinal orthopaedic correction [18].

Materials And Methods

Our research project was approved by the Ethics Committee of Handan Central Hospital. All patients signed informed consent forms.

The clinical data of patients with lumbar tuberculosis treated by unilateral pedicle screw combined with CBT screw fixation + contralateral Wiltse approach for lumbar tuberculosis debridement from October 2014 to January 2021 were retrospectively analysed.

Inclusion criteria: X-ray, CT, MRI, and other imaging examinations of patients showed vertebral and intervertebral space destruction, sequestrum formation, intervertebral and paravertebral cold abscess formation, spinal instability/deformity, etc., which were consistent with the characteristics of spinal tuberculosis; the presence of a caseous substance was consistent with the diagnosis of spinal histopathology tuberculosis; the patient had symptoms such

as night sweats, low fever in the afternoon, and fatigue; and the patient had intractable low back pain, progressive neurological impairment, and other symptoms.

Exclusion criteria: huge abscess anterior to the lumbosacral spine; lumbar infusion abscess.

Preoperative preparation

All patients were absolutely bedridden; high-energy and high-protein diets were given to improve nutritional status; anaemia and hypoproteinemia were corrected before surgery. All patients received standard combinations of 4 drugs for 2–4 weeks (H, isoniazid: 300 mg/day, R, rifampicin: 450 mg/day, E, ethambutol: 750 mg/day, Z, pyrazinamide: 750 mg/day).

Surgical strategy

The patient underwent general anaesthesia and tracheal intubation in the prone position. The target segment was positioned, a midline incision was made in the posterior lumbar spine, the paraspinal muscle was stripped on the opposite side of the lesion; the spinous process, lamina, and facet joints were exposed, and the pedicle was implanted according to the preoperative plan. CBT screws, pre-bent titanium rods, and fixation sutures were used. A wound incision was made on the opposite side, the original muscle space was separated to reach the intervertebral space, the channel was expanded step by step, a quadrant dilator was placed, the facet joint was exposed, and electrocautery was used to stop bleeding and peel the surface soft tissue. Osteotomy removed part of the inferior and superior articular processes and limited cleavage of the lamina was used to expose the spinal canal. Exposure and protection occurred under direct vision, and the dural sac and nerve root were retracted before exposure of the intervertebral space, suction to remove pus, curette of diseased vertebral body and intervertebral space abscess, sequestrum and caseous necrosis with different angle spatulas until the surface of the healthy bone reached a slight oozing. After the lesions were completely removed, the dural sac was carefully checked to ensure that there was no damage, and a large amount of iodophor hydrogen peroxide and normal saline were injected through a syringe to flush the intervertebral space. After washing, 1.0 g of streptomycin was sprinkled into the wound, and the pre-bent titanium rod was fixed and locked; the indwelling negative pressure drainage tube was placed in the deep paraspinal muscle, and the incision was closed.

Postoperative management

The motor and sensory functions of the legs of the patients were closely observed, and the patients were encouraged to perform straight leg raising exercises. When the drainage volume was less than 50 ml in 24 hours, the drainage was removed. Standard H/R/E/Z combinations were administered for at least 6 months and a lumbar brace was worn for at least 12-16 weeks after surgery. It was recommended that the patients perform their daily activities without weight bearing. Routine blood examination, liver and kidney function, C-reactive protein (CRP), and erythrocyte sedimentation rate (ESR) were reviewed monthly according to the situation during the application of anti-tuberculosis drugs. X-rays were reviewed at 1, 3, 6, 9, and 12 months after the operation and every year after, and CT was reviewed every 3 months. Trabecular bone connection between vertebrae was determined as bone fusion.

Data acquisition and factors of interest

Preoperative and last follow-up CRP and ESR were recorded and evaluated; preoperative, 3 months after operation, and last follow-up Oswestry disability index (ODI), American Spinal Injury Association (ASIA) classification, low back pain visual analogue scale (VAS); all patients were followed up for at least one year, and the time of bony fusion was recorded.

Statistical Analysis

Statistical analysis was performed using SPSS 18.0 software (IBM, USA). Continuous variables conforming to a normal distribution were used to indicate ESR and CRP before surgery and last follow-up were compared by paired t test; ODI and VAS before surgery, 3 months after surgery, and last follow-up were analysed by one-way analysis of variance. The LSD test was used for comparisons between two groups; $P<0.05$ was considered statistically significant.

Results

1. General information

A total of 13 patients, male/female: 5:8, average age: 60.15±10.31 years old (Table 1), 4 of whom were complicated with pulmonary tuberculosis; 9 patients had symptoms of tuberculosis toxicity, such as low fever, night sweats, weight loss, and fatigue; all patients had persistent low back pain in the passive position and all had different degrees of lower extremity nerve dysfunction. All patients received laboratory tests (blood routine, CRP, ESR) and imaging tests (X-ray, CT, MRI).

2. Surgical information

The mean operation time was 150.92±37.32 minutes (110-210 minutes), the mean blood loss was 415.39±151.91 ml (200-600 ml), and the mean follow-up time was 18.23±4.69 months (Table 1).

3. Follow-up data

At the last follow-up, the CRP and ESR of all patients decreased to the normal physiological range, and the difference was statistically significant compared with the preoperative values (CRP: $t=17.934$, $P<0.001$; ESR: $t=8.341$, $P<0.001$, Table 1). The average preoperative ODI score was 80.31%±3.35% (86%-74%), and it decreased to 29.08%±1.94% (26%-32%, compared with preoperative $P<0.05$) at the 3-month follow-up after the operation. At the last follow-up, it continued

to decrease to 19.54%±2.18% (16%-24%, P<0.05 compared with preoperative and P<0.05 compared with 3 months after operation) (F=2109.803, P<0.001). The preoperative VAS score was 7.54±0.97 (6-9), which decreased to 2.23±0.73 (1-3; P<0.05 compared with preoperative) 3 months after the operation and decreased to 0.54±0.66 (0-2) at the last follow-up (Compared with preoperative, P<0.05, compared with 3 months after operation, P<0.05) (F=274.176, P<0.001) (Table 2). Two patients with preoperative ASIA grade C improved to grade D and the other to grade E at the last follow-up, and 8 patients with grade D all improved to grade E at the last follow-up.

The mean time to osseous fusion after surgery was 8.85±2.51 months. A retrospective case is shown in Figure 1.

Postoperatively, 2 patients suffered from pneumonia, which was cured by the application of sensitive antibiotics. No patient had vascular injury or nerve injury during the operation, and no implant-related complications occurred. The surgical incision healed well in all patients, with no sinus tract formation and no tuberculosis recurrence.

Discussion

Benefits of the Wiltse approach in the treatment of lumbar tuberculosis

The Wiltse approach is more accurate in removing lumbar tuberculosis lesions, with less intraoperative trauma and faster postoperative recovery [19]. Biomechanical studies have shown that the posterior bone structures of the spine act as anchor points for posterior muscles and ligaments, which can share the stress of internal fixation and increase the stability of the spine. The Wiltse approach has the following advantages: 1. Entering the target lesion through the original muscle space and retaining the attachment of the paraspinal muscle to the spinous process without destroying the integrity of the muscle structure; not easily forming dead space, and reducing the risk of infection; 2. The Quadrant channel is fixed to expose the surgical area, reducing the repeated pulling on the soft tissue, which is beneficial to the recovery of the soft tissue; 3. The operation under the channel can achieve single-person operation and reduce the workload of the assistant; reducing the degree of dorsal branch of spinal nerve root injury does not easily cause paraspinal muscle neuropathic atrophy, which is conducive to enhancing the recovery of patients after surgery.

Reliability of multitrack multianchor screw technology

The combined use of pedicle screws and CBT screws was first applied to patients with degenerative scoliosis by Professor Masaki [20] in 2013. The purpose of surgery for lumbar tuberculosis is to remove the infection foci, protect nerve function, and stabilize the spine. For tuberculosis lesions invading the anterior column and part of the central column of the vertebral body, CBT screws can be placed to avoid lesions and fix the spine through the posterior and central columns. Biomechanical studies have demonstrated that the insertion torque of CBT screws is 1.71 times that of pedicle screws [21], the uniaxial pullout resistance is increased by 30% [16], and the sagittal flexion and extension strength is also better than that of pedicle screws. Otherwise, the pedicle screws have strong resistance to axial rotation and coronal lateral flexion stress [22], so we placed CBT screws in the middle and pedicle screws in the head and tail according to the characteristics of the lesion to achieve fixation of multiple tracks and anchors. In 2015, a study by Matsukawa [23] showed that the biomechanical strength of the same vertebral body with the cross-track technique was better than that of CBT and pedicle screws alone. Related studies have shown that short-term stabilization is provided by an internal fixation system, while long-term stability reconstruction requires bone fusion [24]. In this study, all patients were able to wear a brace to participate in daily activities. Until final follow-up, all patients had bone fusion, no screw pullout, and no screw or rod rupture, so the author speculates that the multitrack multianchor point screw technology has outstanding fixation strength and can provide a stable mechanical environment. However, the biomechanical strength of the fixed structure in this study needs to be further verified by biological models.

Safety and efficacy of multitrack and anchor point fixation combined with the Wiltse approach in the treatment of lumbar tuberculosis

In this study, none of the patients had internal fixation-related neurological injury, and all had partial neurological recovery. At the last follow-up, the neurological function of 8 patients with ASIA grade D recovered to grade E and 1 patient with ASIA grade C recovered to grade E. The ODI score and VAS score were significantly improved at the last follow-up.

Research limitations

undefinedThis study is a retrospective study with a small sample size, lack of a control group, and short follow-up time. We are looking forward to a multicentre prospective randomized controlled study with rich clinical data and a long follow-up time. Due to the narrow operative field of the Wiltse approach under the channel, it is not suitable for cases where extensive debridement should be performed under direct anterior vision, such as large abscesses and infusion abscesses in front of the vertebra. Such cases may have recurrence due to incomplete posterior debridement. Due to the limitation of the surgical field, the surgeon needs to have enough patience to remove the lesion and repeatedly flush the intervertebral space.

Conclusions

Pedicle screw combined with CBT screw + contralateral Wiltse approach is safe and effective in the treatment of lumbar tuberculosis and suitable for the case of heavier lesion on one side and no large or flow abscesses in front of the lumbar spine.

Declarations

Consent for publication

Any individual's data was allowed to publish.

Competing interests

The authors declare that they have no competing interests.

Funding

This project is supported by 2022 Hebei Province Medical Science Research Project Plan(20220014) and 2022 Hebei Province Medical Science Research Project Plan (20220558).

Authors' Contributions

Jie Miao contributed to the conception and design of this study.Yu-fei Yuan wrote the main manuscript text. Zhi-xin Ren and Jian-fei Li prepared figures 1.cun-Zhang followed up the patients and collected the relevant data. Guan-Jun Li performed the statistical analysis. Xiao-dong Li and Bing-zhi Liu prepared Table 1-2. All authors reviewed and approved the final manuscript.

References

1. Kruk ME, Sulis G, Adam P, Nafade V, Gore G, Daniels B, Daftary A, Das J, Gandra S, Pai M: Antibiotic prescription practices in primary care in low- and middle-income countries: A systematic review and meta-analysis. PLoS Med. 2020;17(6):e1003139.
2. Chakaya J, Khan M, Ntoumi F, Aklillu E, Fatima R, Mwaba P, Kapata N, Mfinanga S, Hasnain SE, Katoto PDMC, Bulabula ANH, Sam-Agudu NA, Nachega JB, Tiberi S, McHugh TD, Abubakar I, Zumla A: Global Tuberculosis Report 2020 – Reflections on the Global TB burden, treatment and prevention efforts. Int J Infect Dis. 2021;113(Suppl 1):S7-12.
3. Millet J-P, Moreno A, Fina L, del Baño L, Orcau A, de Olalla PG, Caylà JA: Factors that influence current tuberculosis epidemiology. Eur Spine J. 2012;22(S4):539 – 48.
4. Yang Z, Liu C, Niu N, Tang J, Shi J, Wang Z, Ding H: Selection of the fusion and fixation range in the intervertebral surgery to correct thoracolumbar and lumbar tuberculosis: a retrospective clinical study. BMC Musculoskelet Disord. 2021;22(1):466.
5. Martinez V, Rolland E, Bricaire F, Caumes E: Tuberculous paravertebral abscess. Lancet. 2004;363(9409):615.
6. Long W, Gong L, Cui Y, Qi J, Duan D, Li W: Single posterior debridement, interbody fusion, and fixation on patients with continuous multivertebral lumbar spine tuberculosis (CMLSTB). BMC Musculoskelet Disord. 2020;21(1):606.
7. Varatharajah S, Charles YP, Buy X, Walter A, Steib JP: Update on the surgical management of Pott's disease. Orthop Traumatol Surg Res. 2014;100(2):233–9.
8. Xu Z, Wang X, Liu Z: One-stage posterior debridement and single-segment interbody fusion for treating mono-segmental lumbar and lumbosacral spinal tuberculosis in adults following minimum 5-year follow-up. J Orthop Surg Res. 2020;15(1):473.
9. Hassan K, Elmorshidy E: Anterior versus posterior approach in surgical treatment of tuberculous spondylodiscitis of thoracic and lumbar spine. Eur Spine J. 2016;25(4):1056–63.
10. Ukunda UNF LM: The posterior-only surgical approach in the treatment of tuberculosis of the spine: outcomes using cortical bone allografts. Bone Joint J. 2018;100-B(9):1208–13.
11. Li M, Huang J, Chen J, Liu S, Deng Z, Hu J, Cao Y, Wu T: Unilateral Limited Laminectomy for Debridement to Treat Localized Short-Segment Lumbosacral Spinal Tuberculosis: A Retrospective Case Series. Orthop Surg. 2021;13(4):1170–80.
12. Shah K, Kothari M, Nene A: Role of Frailty Scoring in the Assessment of Perioperative Mortality in Surgical Management of Tuberculous Spondylodiscitis in the Elderly. Global Spine J. 2018;8(7):698–702.
13. Yang X, Luo C, Liu L, Song Y, Li T, Zhou Z, Hu B, Zhou Q, Xiu P: Minimally invasive lateral lumbar intervertebral fusion versus traditional anterior approach for localized lumbar tuberculosis: a matched-pair case control study. Spine J. 2020;20(3):426–34.
14. Baig MN, Kearns SR, Shannon FJ, Devitt A: Ten Inventions That Shaped Modern Orthopedics. Cureus. 2021;13(1):e12819.
15. HH. B: A method of spinal fusion. J Bone Joint Surg Br. 1959;41-B(2):248–59.
16. Santoni BG, Hynes RA, McGilvray KC, Rodriguez-Canessa G, Lyons AS, Henson MAW, Womack WJ, Puttlitz CM: Cortical bone trajectory for lumbar pedicle screws. Spine J. 2009;9(5):366–73.
17. Rodriguez A NM, Liu A, Somasundaram A, Hsu W, Branch CL Jr: Novel placement of cortical bone trajectory screws in previously instrumented pedicles for adjacent-segment lumbar disease using CT image-guided navigation. Neurosurg Focus. 2014;36(3):E9.
18. Ashayeri K, Nasser R, Nakhla J, Yassari R: The use of a pedicle screw–cortical screw hybrid system for the surgical treatment of a patient with congenital multilevel spinal non-segmentation defect and spinal column deformity: a technical note. Eur Spine J. 2016;25(11):3760–4.
19. Foley KT HL, Schwender JD: Minimally invasive lumbar fusion. Spine (Phila Pa 1976). 2003;28(15):s26-35.
20. Ueno M IT, Inoue G, Takaso M.: Posterior corrective fusion using a double-trajectory technique (cortical bone trajectory combined with traditional trajectory) for degenerative lumbar scoliosis with osteoporosis: technical note. J Neurosurg Spine. 2013;19(5):600–7.
21. Matsukawa K, Yato Y, Kato T, Imabayashi H, Asazuma T, Nemoto K: In Vivo Analysis of Insertional Torque During Pedicle Screwing Using Cortical Bone Trajectory Technique. Spine. 2014;39(4):E240-5.
22. Matsukawa K, Yato Y, Imabayashi H, Hosogane N, Asazuma T, Nemoto K: Biomechanical evaluation of the fixation strength of lumbar pedicle screws using cortical bone trajectory: a finite element study. J Neurosurg Spine. 2015;23(4):471–8.

23. Matsukawa K, Yato Y, Imabayashi H, Hosogane N, Asazuma T, Nemoto K: Biomechanical Evaluation of Cross Trajectory Technique for Pedicle Screw Insertion: Combined Use of Traditional Trajectory and Cortical Bone Trajectory. Orthop Surg. 2015;7(4):317–23.
24. Zheng G, Wang C, Wang T, Hu W, Ji Q, Hu F, Li J, Chaudhary SK, Song K, Song D, Zhang Z, Hao Y, Wang Y, Li J, Zheng Q, Zhang X, Wang Y: Relationship between postoperative lordosis distribution index and adjacent segment disease following L4-S1 posterior lumbar interbody fusion. J Orthop Surg Res. 2020;15(1):129.

Tables

Table 1. Baseline information and variables of patients (mean±SD,* P0.001).

Case No.	Gender(M/F)	Age(yr)	Bone fusion time (months)	Operation		Follow-up (months)	CRP(mg/L)		ESR(mm/h)	
				Time(min)	Blood loss(ml)		Preop	Final	Preop	Final
1	M	47	6	211	600	13	103.9	1.0	102	2
2	M	47	12	201	400	24	94.2	3.8	90	4
3	M	72	8	120	200	13	78.5	4.7	34	3.1
4	F	68	6	140	400	11	69	4.2	34.8	4
5	F	50	10	120	300	15	48.9	2.0	51	9
6	F	55	12	110	300	19	99	1.3	65	2.6
7	M	65	9	140	600	24	70	4.8	49	12
8	F	69	6	200	600	18	84	3.3	34	2
9	F	47	8	130	500	16	80	2.4	48	7
10	F	64	12	120	300	20	61	0.5	100	9
11	F	77	6	140	200	24	73	2.0	68	3
12	F	64	8	130	400	16	84	2.6	59	13
13	M	57	12	200	600	24	85	7	59	1.7
	-	60.15±10.31	8.85±2.51	150.92±37.32	415.39±151.91	18.23±4.69	79.27±15.23	3.05±1.82*	61.06±23.58	5.57:

CRP, C-reactive protein; ESR, erythrocyte sedimentation rate;

Table 2. Comparison between pre- and postoperative variables (mean±SD,* P<0.05;△ P<0.05).

Time	VAS	ODI(%)	ASIA				
			A	B	C	D	E
Preop	7.54±0.97	80.31±3.35	0	0	2	8	3
3 months post-operation	2.23±0.73*	29.08±1.94*	0	0	1	1	11
Final follow-up	0.54±0.66*△	19.54±2.18*△	0	0	0	1	12

VAS, visual analogue scale; ODI, Oswestry Disability Index; ASIA, American Spinal Injury Association Classification of Spine Injury; *, P<0.05 compared with pre-operation; △, P<0.05 compared with 3 months after operation

Figures

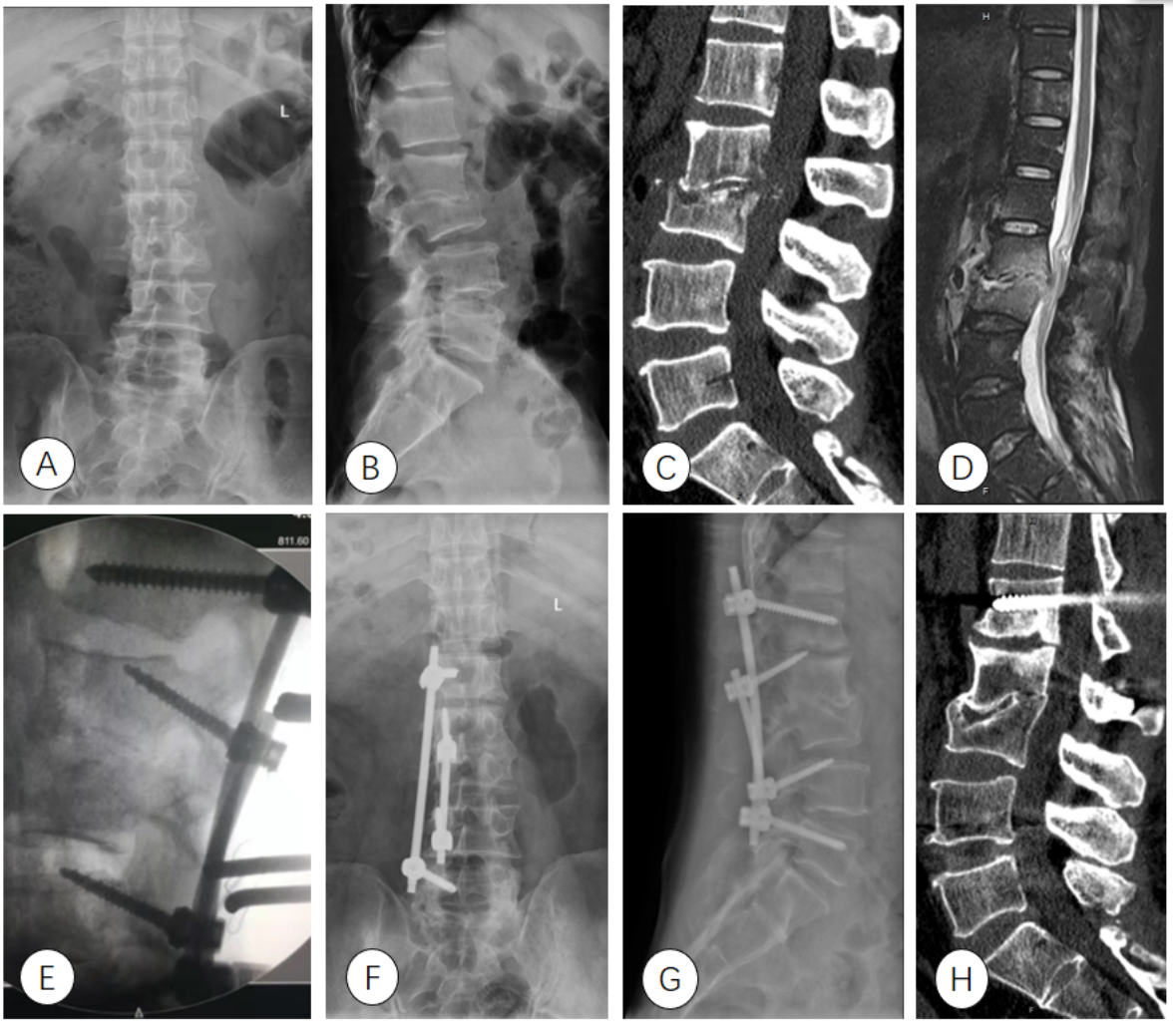

Figure 1

Case review. A 47-year-old male patient presented with low back pain and left leg numbness and weakness. The pathological diagnosis was L2/3 lumbar tuberculosis. The preoperative lumbar spinal X-ray showed L2/3 intervertebral space collapse (**A, B**); the lumbar spinal CT scan showed L2/3 intervertebral space stenosis and vertebral body destruction, and sequestrum could be seen invading the front of the intervertebral space and protruding backwards into the spinal canal (**C**); the fat-suppressed MRI scan of the lumbar vertebrae showed destruction of the L2/3 intervertebral disc, narrowing of the intervertebral space, pus formation in the intervertebral space protruding toward the front and back of the intervertebral space, and compression of the dural sac (**D**); C-arm fluoroscopy during the operation confirmed the pedicle screws and CBT screws were in good positions (**E**); the X-ray of the lumbar spine 1 year after the operation showed L2/3 intervertebral space fusion, normal positioning of the internal fixation device, and the absence of broken screws and rods (**F, G**); the CT scan of the lumbar spine 1 year after the operation showed that the L2/3 vertebral bodies had fused and that tuberculosis lesions had not developed (**H**).