Early Detection and Intervention for Acute perforated Peptic Ulcer after Elective Spine Surgeries: A Review of 13 Cases from 24,026 Patients

Fu-Cheng Kao
Chang Gung Memorial Hospital

Tung-Yi Lin (ross_1222@hotmail.com)
Chang Gung Memorial Hospital

Ping-Yeh Chiu
Chang Gung Memorial Hospital

Tsung-Ting Tsai
Chang Gung Memorial Hospital

Tsai-Sheng Fu
Chang Gung Memorial Hospital

Po-Liang Lai
Chang Gung Memorial Hospital

Research Article

Keywords: perforated peptic ulcer, postoperative, progressive abdominal pain, spine surgery

Posted Date: February 4th, 2021

DOI: https://doi.org/10.21203/rs.3.rs-155910/v1

Abstract

Background:

To determine how perforated peptic ulcers be diagnosed earlier after patients undergoing an elective spine surgery

Methods:

Patients who underwent elective spine surgeries at our hospital between January 2000 and April 2018 and experienced an acute perforated peptic ulcer were included. An age-and gender-matched control group was comprised of 26 patients without a postoperative acute perforated peptic ulcer who received spine surgery during the same period. Medical records and imaging studies were thoroughly reviewed.

Results:

Thirteen patients were enrolled in the study group, including eight females and five males. Three patients, two females and one male, died of uncontrolled peritonitis during the hospital stay. All patients in the study group experienced the sudden onset of abdominal pain, which was continuous and progressive. Patients with elevated serum amylase, a peptic ulcer history and increased intraoperative blood loss had a tendency to develop a postoperative perforated peptic ulcer.

Conclusion:

Spine surgeons should be highly suspicious of a perforated peptic ulcer if a patient with abnormal high serum amylase level, a history of peptic ulcer and nonsteroidal anti-inflammatory druguse experiences, progressive pain in the epigastrium accompanied by abdominal rigidity and absent bowel sounds. Early diagnosis and emergency surgical intervention promote better outcomes.

Introduction

Peptic ulcer perforation is one of the most common indications for emergency gastric surgery. Although the incidence of peptic ulcer perforation is relatively low, the condition is life threatening, with a high mortality rate varying from 10–40% [1, 2]. A perforated ulcer may be complicated by peritonitis, septic shock, renal insufficiency, multiple organ failure, and death. Factors associated with a higher mortality rate include shock at presentation, renal insufficiency, surgery delayed more than 12 hours, increased age (i.e., over the age of 70), liver cirrhosis, an immunocompromised state, and the presence of gastric ulcers[3, 4]. However, diagnosing peptic ulcer perforation is difficult. It requires a high index of suspicion based on a detailed examination of the patient’s medical history and physical examination findings, which may be equivocal with minimal or no signs of peritonitis[5].

The main etiologic factors associated with peptic ulcers include smoking, alcohol use, stress, steroid use, the presence of *Helicobacter pylori*, trauma, neoplasm, foreign body or corrosive ingestion, and iatrogenic

causes [2, 6]. On the other hand, the development of an acute perforated peptic ulcer (PPU) after elective spine surgery is a rare complication. To the best of our knowledge, there have been no published case reports concerning acute perforated peptic ulcers after elective spine surgeries. Patients may complain of abdominal discomfort due to ileus after prolonged anesthesia and excessive blood loss after spine surgery, which might mask a perforated peptic ulcer. Due to the possible need for emergency laparotomy, and the possibility of multiple organ failure and septic shock, spine surgeons should consider the possibility of a perforated peptic ulcer in patients with postoperative abdominal pain. The purpose this study was to determine how perforated peptic ulcers can be diagnosed and treated earlier.

Methods

Thirteen patients who underwent elective spine surgery at our hospital between January 2000 and April 2018, and experienced an acute perforated peptic ulcer were included in this retrospective study. An age- and gender-matched control group was comprised of 26 patients without a postoperative acute perforated peptic ulcer who received spine surgery during the same period. The study was approved by the hospital's Ethics Committee. The consent was waived by the ethics committee as it is retrospective study. We confirm that all methods were performed in accordance with the relevant guidelines and regulations.

Acute perforated peptic ulcers were diagnosed within 8 days after the elective spine surgery in all included patients. Medical records, imaging studies, laboratory data, neurological function data, and functional outcomes were reviewed and analyzed. The definitive diagnosis of peptic ulcer perforation was based on pneumoperitoneum on a standing chest posterior-anterior radiograph, or in the left lateral abdominal decubitus view, and the presence of unexplained intraperitoneal fluid, pneumoperitoneum, bowel wall thickening, mesenteric fat streaking, mesenteric hematoma, and extravasation of contrast on computed tomography (CT) of the abdomen[7]. Operative intervention is almost always indicated in the treatment of perforated peptic ulcers[8]. Patients with hollow organ perforation due to trauma, malignancy, and foreign body or corrosive ingestion were excluded.

Surgical time, intraoperative blood loss, instrumentation level, and complications from spine surgeries were recorded in both groups. Routine postoperative care after elective spine surgery at our institution encourages patients to sit at the bedside and begin oral intake on postoperative day 1, and to ambulate on postoperative day 3. Any symptoms and signs after surgery were analyzed. Laboratory data including white blood cell (WBC) count, C-reactive protein (CRP), amylase, and lipase were checked and recorded before laparotomy in the perforated ulcer group. Abdominal contrast CT and radiography were conducted for definitive diagnosis, and surgical planning before general surgery. General surgeons managed the postoperative care after the abdominal surgery, including fluid resuscitation, nasogastric decompression, acid suppression, and empiric antibiotic therapy.

Statistical analysis

Quantitative variables were expressed as mean ± standard deviation. The study sample was divided into two groups based on the exposure: the perforated ulcer group included patients who experienced an acute perforated peptic ulcer after elective spine surgeries, whereas the control group included patients who did not. The differences between groups were assessed using Mann–Whitney U test for continuous variables and Fisher's exact test for categorical variables. The threshold for statistical significance was set at $p < 0.05$. All statistical calculations were performed using SPSS 12.0 software (SPSS, Chicago, IL)

Results

In total, 24,026 elective spine surgeries were performed at the Spine Section of the Orthopedic Department in our hospital between January 2000 and April 2018. Thirteen patients with a postoperative acute perforated peptic ulcer, eight females and five males, were included as the perforated ulcer group. An age- and gender-matched group of 26 patients without a postoperative acute perforated peptic ulcer who received spine surgery during the same period were used as a control group. Three patients (two females and one male patient) with a perforated peptic ulcer died of severe sepsis and uncontrolled peritonitis during their hospital stay. The remaining 10 patients were followed for at least 24 months.

Three patients in the study group had a history of peptic ulcers treated with medications, compared to only one patient in the control group ($p < 0.05$). Four male patients in the perforated ulcer group had a > 10-year smoking history, as did two patients in the control group. The mean surgical time was 251.7 ± 83.1 minutes in the perforated ulcer group, and 242.4 ± 78.8 minutes in the control group. The mean blood loss during spine surgery of the perforated ulcer group was 855.4 ± 701.3 ml, which was significantly greater than that of the control group (333.1 ± 170.3ml, $p < 0.05$). The demographic and surgical data of both groups were summarized in Table 1. Abdominal CT was required for further confirmation of the diagnosis in seven patients in the perforated ulcer group; the other six patients displayed free air on the standing chest posterior-anterior radiograph or in the left lateral abdominal decubitus view (Fig. 1).

Table 1
Demographic and surgical data

	Perforated ulcer group	Control group	p-value
Sex			
F	8 (62)	16 (62)	1
M	5 (38)	10 (38)	1
Age (y)	71.8 ± 5.4	71.8 ± 5.8	0.988
Index spine surgery			
Surgical time (min)	251.7 ± 83.1	242.4 ± 78.8	0.957
Blood loss (ml)	855.4 ± 701.3	333.1 ± 170.3	< 0.05
Biochemical testing			
Amylase (U/L)	431.9 ± 678.6		
Lipase (U/L)	163 ± 233.1		
White blood cell count (1000/uL)	11 ± 7.5		
Past history			
Peptic ulcer	3 (23)	1 (4)	< 0.05
Steroid use	1 (8)	0 (0)	0.07
Smoking	4 (31)	2(8)	0.11
Postoperative S/S			
Sudden abdominal pain	13 (100)	0 (0)	
Abdominal fullness	6 (46)	4 (15)	
Muscle guarding	6 (46)	0 (0)	
Images for PPU			
Radiography	6 (46)		
Abdominal CT	7 (54)		
POD of PPU diagnosis	3.6 ± 2.3		
≤ 3 days	10 (77)		

Data are presented as mean ± standard deviation or number (percentage).

PPU, perforated peptic ulcer; POD, postoperative day; S/S, symptoms and signs.

	Perforated ulcer group	Control group	p-value
> 3 days	3 (23)		
Site of perforation			
Stomach	7 (54)		
Duodenum	6 (46)		
General surgery			
Gastrorrhaphy or duodenorrhaphy	10 (77)		
Subtotal gastrectomy or antrectomy	3 (23)		
Data are presented as mean ± standard deviation or number (percentage).			
PPU, perforated peptic ulcer; POD, postoperative day; S/S, symptoms and signs.			

Spine surgery

All patients enrolled in this study underwent elective spine operations. In the perforated ulcer group, one patient had cervical spine decompression and posterior instrumentation. Twelve patients underwent thoracolumbar or lumbar spine surgeries: one single-level discectomy, 10 posterior decompressions with instrumentation, and one anterior surgery with instrumentation. Seven patients had instrumentation ≥ 3 levels, and five patients had two level instrumentation. Data from two groups of spine surgeries was summarized in Table 2.

Table 2
Spine surgery data

	Perforated ulcer group	Control group
All patients	13 (100)	26 (100)
Surgical site		
Cervical spine	1 (8)	3 (12)
Thoracolumbar and lumbar spine	12 (92)	23(88)
Surgical levels		
≥ 3	7 (54)	16 (62)
< 3	6 (46)	10 (38)
Surgical methods		
Posterior instrumentation	11 (84)	20 (78)
Anterior surgery with instrumentation	1 (8)	3 (12)
Discectomy	1 (8)	3 (12)
Data presented as number (percentage).		

Symptoms and signs of acute perforated peptic ulcer

Six patients were found to have muscle guarding with rebound pain, and only one patient developed a high fever. All patients in the perforated ulcer group experienced the sudden onset of abdominal or epigastric pain that was continuous and progressive, and not relieved by analgesics. Six patients complained of abdominal fullness and constipation, and had hypoactive bowel sounds. One patient had a delayed diagnosis after presenting with a disturbance of consciousness, and septic shock due to peritonitis. None of the control group patients had postoperative abdomen pain, muscle guarding, or rebound pain. Four patients in the control group complained of abdominal fullness and postoperative constipation, which improved after ambulation and use of laxatives.

Laboratory data and imaging findings of acute perforated peptic ulcer

The mean amylase level was 431.9 ± 678.6 U/L (normal serum level: 40–140 U/L), and the mean lipase level was 163 ± 233.1 U/L (normal serum level: 0–50 U/L) in the group with a perforated ulcer. There were six patients with leukocytosis, and two with leukopenia and a left shift or band cells. The WBC count in five patients was within the normal range, but the differential contained band cells. Abdominal CT was

conducted in seven patients when no obvious free air was detected on radiographs; however, a perforated peptic ulcer was suspected based on the patients' clinical symptoms and signs, physical examination, and laboratory findings.

General surgery for acute perforated peptic ulcer

The mean time between the spine surgery and diagnosis of an acute perforated peptic ulcer was 3.6 ± 2.3 days (range, 1–8 days). Ten patients with a perforated ulcer were diagnosed within 3 days after the spine surgery and the other three patients who presented with delayed peritonitis did not have a history of a peptic ulcer. Ten patients underwent gastrorrhaphy or duodenorrhaphy, and three patients received subtotal gastrectomy or antrectomy with a Billroth II reconstruction. Three patients died of uncontrolled sepsis after abdomen surgeries during the hospital stay.

Discussion

Perforated peptic ulcers are relatively rare, and difficult to diagnose. Classically, there is a three-stage process described for the presentation of a PPU [7]. The abrupt onset of abdominal pain is the initial symptom, occurring within 2 hours of perforation. The pain is progressive, and may become generalized after a short time, with pain originating in the epigastrium. After 2 to 12 hours, the pain becomes more severe and significant during palpation of the hypogastrium. Twelve hours after perforation, the patient may exhibit a fever, signs of hypovolemia, and abdominal distention without abdominal pain. Making the diagnosis of a perforated peptic ulcer as quickly as possible is important. In a patient with an appropriate history, if there is free air on a standing chest radiographor in the left lateral abdominal decubitus view, or on a CT scan, no additional testing is required before treatment[9]. Prognosis is related to the timing of treatment. The prognosis is better if treatment is provided within 6 hours of perforation, and a delay in treatment beyond 12 hours increases both morbidity and mortality[10]. According to Boey, preoperative shock, concurrent medical comorbidities, and perforations that are present for more than 48 hours before treatment were associated with a higher mortality[11]. In our retrospective study, three patients died of uncontrolled septic peritonitis. All of them were diagnosed within 3 days postoperatively, and only one presented with a high fever without a change in consciousness.

Three patients (23%) in the perforated ulcer group had a history of a peptic ulcer, compared to only one patient in the control group (4%, $p < 0.05$). Peptic ulcer disease used to be one of major causes contributing peptic ulcer perforation[12], and *Helicobacter pylori* infection is responsible for more than 90% of duodenal ulcers and in up to 80% of gastric ulcers[13]. Besides, PPI are associated with the use of non-steroidal anti-inflammatory drugs (NSAIDs) and steroids [6, 14]. NSAIDs inhibit the production of prostaglandins in the stomach, which play a critical role in the gastric mucosal defenses against acid- and pepsin-induced injury[15]. Each patient in our study underwent elective spine surgery after at least 6 weeks of conservative treatment, including NSAIDs and rehabilitation. Only one patient received steroids

before the surgery due to underlying diseases. Smoking is another important risk factor that predisposes development of a perforated peptic ulcer[16]. In our series, smoke factor showed no significant difference.

The intraoperative blood loss of the spine surgery was significantly different between the two groups (855.4 ± 701.3 ml in the ulcer group versus 333.1 ± 170.3 ml in the control group, $p < 0.05$). Stress ulcer is induced by hypoperfusion of the mucosa in the upper gastrointestinal tract, and reduced gastric blood flow, mucosal ischemia and reperfusion injury are putative underlying mechanism [17]. Greater intraoperative blood loss plus postoperative close wound drainage caused relative hemodynamic instability during anesthesia and in perioperative period in patients in the perforated ulcer group. This resulted in tissue hypoperfusion and reperfusion injury, similar to that of gastrointestinal mucosa injury.

Elevated serum amylase is a frequent concomitant of PPU. There might be significant correlation between increase in amylase and some of the other factors associated with ulcer perforation[7]. The rise is probably a result of increased gastrointestinal leakage into theperitoneal cavity and subsequent lymphatic absorption[18]. In the present study, mean amylase level of the perforated ulcer group was above three times of upper normal limit. Patients in the perforated ulcer group showed significant elevated serum amylase level after elective spine surgeries, especially in the three who died of severe sepsis and uncontrolled peritonitis during their hospital stay (mean serum amylase level in those three patients: 1253.3 U/L). According to the study of Frank A.[19], the increase of mortality rate seemed to be related to high serum amylase level in the findings of 1000 cases with PPU. Large amounts of gastrointestinal leakage and large perforations cause higher elevated amylase in patients. To avoid delay diagnosis, clinicians should keep alert to determine the patients, who are highly suspected of perforation and with abnormally high serum amylase level, even if free subphrenic air could not be demonstrated.

In this retrospective study, 13 out of the 24,026 patients that underwent elective spine surgeries; thus, the incidence was 0.054%. Some case reports have reported the presence of small bowel perforations after lumbar laminectomy or discectomy [20, 21]. The authors considered that ventral hollow organ perforation was a rather rare complication of lumbar decompression surgery, and laminectomy had a lower incidence than discectomy. According to a study of 30,000 lumbar discectomies, the ventral hollow organ perforation rate was 0.016%[22].

Postoperative abdominal distension, poor appetite, nausea or vomiting, constipation, and bowel hypoactivity are not uncommon for patients after elective spine surgery due to the prolonged absence of oral intake, anesthesia, and postoperative bed rest. It is difficult to distinguish between normal postoperative gastritis, and early symptoms of PPU, especially in elderly and ill patients[23]. Feng et al [24] presented a-13-patients series, those were diagnosed with acute pancreatitis after scoliosis surgery. The low body mass index, low intraoperative mean arterial pressure and long segment of fusion were independent risk factors. A careful examination of a patients' medical history, as well physical examination, can assist in evaluating acute abdominal pain after elective spine surgery. Clinicians should consider the presence of a PPU if abdominal pain is of abrupt onset, progressive, and located in the epigastrium, and is associated with abdominal rigidity and absent bowel sounds[25], especially in

patients with elevated serum amylase level, a history of a peptic ulcer and NSAID use. Due to high mortality rate in the present study (23%), early diagnosis and emergent surgical treatment are necessary to avoid further complication. Each suspicious patient should undergo standing chest posterior-anterior radiography, or a left lateral abdominal decubitus view, or even abdominal CT to check for signs of pneumoperitoneum, free air, and a double-wall sign, and to rule out other conditions in the differential diagnosis, including cholecystitis, appendicitis, acute pancreatitis, diverticulitis, bowel obstruction, and aortic aneurysm[9].

There are several limitations of this study. This was a retrospective and single-center study. As it is a rather rare complication with a low incidence after elective spine surgery, only a small number of cases were included. Training for the evaluation and management of acute abdominal pain is not common in our orthopedic department. Diagnosis and surgical intervention might have been delayed in the opinion of the general surgeons, and some cases were lost because of a missed diagnosis.

Conclusion

A postoperative perforated peptic ulcer is a rare, but devastating complication after elective spine surgeries. Early diagnosis and emergency surgical intervention result in better outcomes. Spine surgeons should be highly suspicious of a perforated peptic ulcer if a patient with abnormal high serum amylase level, a history of a peptic ulcer and NSAID use experiences, progressive abdominal pain in the epigastrium associated with abdominal rigidity and absent bowel sounds after elective spine surgery.

Abbreviations

CT: computed tomography; PPU: perforated peptic ulcer ; WBC : white blood cell; CRP: C-reactive protein ; NSAID: non-steroidal anti-inflammatory drugs

Declarations

Author’s contributions:

T-YL and F-CK drafted the manuscript and designed the study. P-LL provided

most of the patient data and data on treatment methods. P-YC and T-TT participated in data collection. T-SF analyzed and interpreted the data. All authors read and approved the final manuscript.

Ethical approval and consent to participate:

This study was approved by the ethics committee of Chang Gung Medical

Foundation, and the informed consent was waived by the ethics committee as it is a retrospective study. (Protocol No: CGMF IRB No. : 104-7197C)

Availability of data and materials

The data which analyzed during the study are stored in our hospital and are available from the corresponding author on reasonable request.

Competing interests

The authors declare no competing interests.

Funding:

There was no funding receive to the study and no conflict of interests to be declared.

Acknowledgements:

We thank the Statistics Center for Clinical Research, Chang Gung Memorial Hospital, Taoyuan, Taiwan, for allowing us using the database retrospectively and providing statistical analysis support

References

1. Thorsen, K., et al., *Trends in diagnosis and surgical management of patients with perforated peptic ulcer.* J Gastrointest Surg, 2011. **15**(8): p. 1329-35.
2. Svanes, C., *Trends in perforated peptic ulcer: incidence, etiology, treatment, and prognosis.* World J Surg, 2000. **24**(3): p. 277-83.
3. Uccheddu, A., et al., *Surgery for perforated peptic ulcer in the elderly. Evaluation of factors influencing prognosis.* Hepatogastroenterology, 2003. **50**(54): p. 1956-8.
4. Tsugawa, K., et al., *The therapeutic strategies in performing emergency surgery for gastroduodenal ulcer perforation in 130 patients over 70 years of age.* Hepatogastroenterology, 2001. **48**(37): p. 156-62.
5. Fakhry, S.M., et al., *Current diagnostic approaches lack sensitivity in the diagnosis of perforated blunt small bowel injury: analysis from 275,557 trauma admissions from the EAST multi-institutional HVI trial.* J Trauma, 2003. **54**(2): p. 295-306.
6. Lau, J.Y., et al., *Systematic review of the epidemiology of complicated peptic ulcer disease: incidence, recurrence, risk factors and mortality.* Digestion, 2011. **84**(2): p. 102-13.
7. Di Saverio, S., et al., *Diagnosis and treatment of perforated or bleeding peptic ulcers: 2013 WSES position paper.* World J Emerg Surg, 2014. **9**: p. 45.
8. Lee, C.W. and G.A. Sarosi, Jr., *Emergency ulcer surgery.* Surg Clin North Am, 2011. **91**(5): p. 1001-13.

9. Grassi, R., et al., *Gastro-duodenal perforations: conventional plain film, US and CT findings in 166 consecutive patients.* Eur J Radiol, 2004. **50**(1): p. 30-6.
10. Svanes, C., et al., *Adverse effects of delayed treatment for perforated peptic ulcer.* Ann Surg, 1994. **220**(2): p. 168-75.
11. Boey, J., J. Wong, and G.B. Ong, *A prospective study of operative risk factors in perforated duodenal ulcers.* Ann Surg, 1982. **195**(3): p. 265-9.
12. Soreide, K., et al., *Perforated peptic ulcer.* Lancet, 2015. **386**(10000): p. 1288-98.
13. Ahmed, N., *23 years of the discovery of Helicobacter pylori: Is the debate over?* Annals of Clinical Microbiology and Antimicrobials, 2005. **4**(1): p. 17.
14. Gisbert, J.P., et al., *Helicobacter pylori and perforated peptic ulcer prevalence of the infection and role of non-steroidal anti-inflammatory drugs.* Dig Liver Dis, 2004. **36**(2): p. 116-20.
15. Wallace, J.L., *Prostaglandins, NSAIDs, and gastric mucosal protection: why doesn't the stomach digest itself?* Physiol Rev, 2008. **88**(4): p. 1547-65.
16. Malfertheiner, P., F.K.L. Chan, and K.E.L. McColl, *Peptic ulcer disease.* The Lancet. **374**(9699): p. 1449-1461.
17. Spirt, M.J. and S. Stanley, *Update on stress ulcer prophylaxis in critically ill patients.* Crit Care Nurse, 2006. **26**(1): p. 18-20, 22-8; quiz 29.
18. Rogers, F.A., *SERUM AMYLASE IN PEPTIC GASTRODUODENAL PERFORATION—A Study to Determine the Significance of Abnormally High Levels.* Calif Med, 1960. **93**(1): p. 6-10.
19. Rogers, F.A., *Elevated Serum Amylase: A Review and an Analysis of Findings in 1,000 Cases of Perforated Peptic Ulcer.* Ann Surg, 1961. **153**(2): p. 228-40.
20. Kim, D.S., et al., *Small bowel injury as a complication of lumbar microdiscectomy : case report and literature review.* J Korean Neurosurg Soc, 2010. **47**(3): p. 224-7.
21. Krieger, R.H., et al., *Small Bowel Perforation as a Postoperative Complication from a Laminectomy.* Case Rep Surg, 2015. **2015**: p. 378218.
22. Ramirez, L.F. and R. Thisted, *Complications and demographic characteristics of patients undergoing lumbar discectomy in community hospitals.* Neurosurgery, 1989. **25**(2): p. 226-30; discussion 230-1.
23. Huddy, S.P., W.P. Joyce, and J.R. Pepper, *Gastrointestinal complications in 4473 patients who underwent cardiopulmonary bypass surgery.* Br J Surg, 1991. **78**(3): p. 293-6.
24. Feng, F., et al., *Incidence and Risk Factors of Acute Pancreatitis After Scoliosis Surgery: A Prospective Study.* Spine (Phila Pa 1976), 2018. **43**(9): p. 630-636.
25. Lyon, C. and D.C. Clark, *Diagnosis of acute abdominal pain in older patients.* Am Fam Physician, 2006. **74**(9): p. 1537-44.

Figures

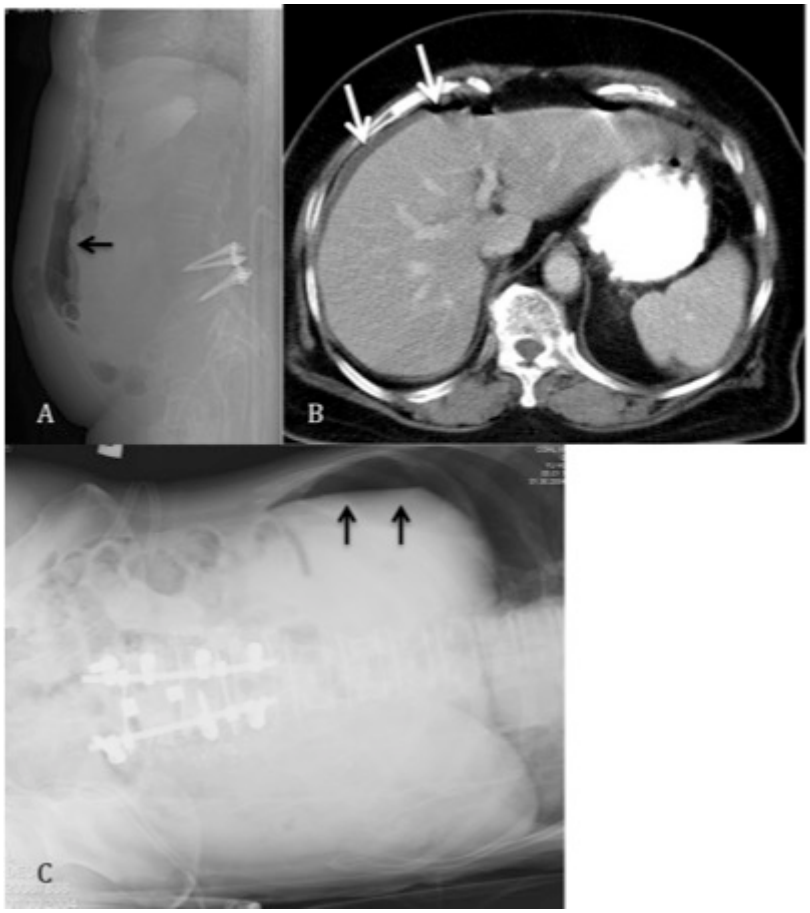

Figure 1

A, B) A 76-year-old female complained of abrupt onset of abdominal pain with progressive muscle guarding, which started on postoperative day 1 after lumbar decompression and posterior instrumentation at L4-5. A)Supine lumbar lateral radiograph showed intra-abdominal free air without disruption upon examining the bowel gas pattern (black arrow). B) Axial computed tomography (CT) revealed intraperitoneal free air and fluid in the right paracolic gutter (white arrow). C) A 70-year-old male experienced sudden abdominal pain with abdomen distension, which started on postoperative day 3 after lumbar decompression and posterior instrumentation of L3-S1 Intra-abdominal free air and an air-fluid level were observed on the left lateral decubitus view (black arrow).