Pediatric patient with Penetrating Brain Injury by a Pickaxe: Case Report and Literature Review

Raíssa Mansilla (raissamansilla@gmail.com)
Alberto Torres State Hospital

Paulo Henrique Reigota Pinguelo
Alberto Torres State Hospital

Bárbara Contarato Pilon
Alberto Torres State Hospital

Luís Gustavo Duarte Amaral
Antonio Pedro University Hospital

Fernando Jorge Monteiro Martins
Alberto Torres State Hospital

Geraldo Luiz Paraguassu Correia da Silva
Alberto Torres State Hospital

Case Report

Keywords: Penetrating Brain Injury, Pickaxe, Non-missile injuries, Case Report, Traumatic Brain Injury

Posted Date: April 25th, 2022

DOI: https://doi.org/10.21203/rs.3.rs-1564845/v1

Abstract

Head trauma due to falls is often seen in children, however Penetrating Brain Injury (PBI) – the most life-threatening condition of Traumatic Brain Injury (TBI) - is exceedingly rare. Herein, we report and discuss the challenges encountered in surgical and post-operative management of a 13-old-child patient with PBI by a pickaxe, admitted in Glasgow Coma Scale (GCS) 3 and that not only survived, but also achieved a Glasgow Outcome Scale (GOS) after one year of postoperative follow-up. To our knowledge, this is the first case of pickaxe-induced brain injury on the American Continent and the youngest survivor of this trauma reported in literature.

Introduction

PBI is the most life-threatening condition of TBI: only 10–30% survive to reach the hospital, half of which ultimately die during initial resuscitation and the other half often suffer significant long-term neurologic sequelae[1–3].

Based on the speed of penetration, PBI is classified into two groups: missile injuries (> 100m/s) or non-missile injuries (< 100m/s). Non-missile injuries represent only 0,4% of overall head trauma[4, 5] and are even more rare in children, being commonly described as result of an accident while playing, assault, suicidal attempts or road traffic accident, but also as a result of domestic violence.

Several materials have been reported as PBI[1, 2, 12–19, 4–11], but little is known about penetrating pickaxe and its surgical management challenges. Herein, we report an PBI by a pickaxe in 13-old-child and discuss the challenges encountered in its surgical extraction and post-operative management.

Case Report

A 13-years-old male patient was found on GCS 3 with a pickaxe (Fig. 1) onto his head owing to paternal violence and conducted to the hospital intubated, with right-sided hemiplegia, mydriatic left pupil and a left frontotemporal PBI. Computerized tomography (CT) showed a metallic object penetrating left frontotemporal skull and brain parenchyma in at a depth of 120mm and left orbit fracture (Fig. 2a).

After initial evaluation, and under general anesthesia, a Becker flap was made around the pickaxe, and the bone fixed under it was removed to prevent unnecessary movement. The pickaxe was slowly pulled out from the skull under direct visualization and hemostasis was performed. Necrosis and hemorrhage surrounding brain tissue was observed, but no major vessel injury was found. Brain relaxation was visualized, and dura mater was closed tightly using autologous and pericranial graft. Then, patient was transferred to intensive care unit and postoperative CT showed residual hematoma with no mass effect.

On the second day, bulging of the surgical wound region was noted and new CT showed Marshall score IV (Fig. 2b). Decompressive craniectomy was performed and patient was extubated in nine days. Initially, expressive aphasia was prominent. He could follow orders with his left side, but the right side was heavily

paretic and ipsilateral amaurosis due to irreversible left optic nerve lesion was confirmed by ophthalmologist.

Three days later, he was transferred to the neurosurgical department and after completing 28-day antibiotic regimen, patient made another CT (Fig. 2c) and was discharged with GOS 3, instructions for homeschooling, physio and speech therapy. After 1 year, patient achieved GOS 5 despite sequelae alterations found in the control CT (Fig. 2d).

Discussion

Since Phineas Gage in 1848[10], PBI have been broadly reported, but is still rare in children. Our case is the first on American continent and the only one in a pediatric patient with a surgical view. An African case was reported[9] and, despite the age difference, both were male patients victims of violence with left frontotemporal injury, consistent with general PBI literature related. The higher incidences in the left side could be explained due to right-handedness of the aggressor[5, 20] and, although the most common entrance site in non-missile PBI is the roof of the orbit, it is followed by the squamous part of the temporal bone due to its thinner wall[4, 6]. Complete comparison of the cases is available on Table 1.

The time trauma to hospital arrival is directly related with in-hospital all-cause mortality and for each 10-minute enlargement in prehospital time the odds of death increases 9%[21]. Fortunately, Brazil has an effective public prehospital trauma care which certainly was the watershed between life and death in this case. Foreign body removal at the scene was not recommended because could reduce pressure on vascular structures inducing hemorrhage[11].

CT scan is, undoubtful, standard imaging for PBI[1] and angiography should be obtained in suspected vascular injuries. In our case, owing to patient gravity, we decided to immediate surgical treatment and no other exams were performed. Timing of surgical intervention is likewise important to avoid secondary injuries and, for that, the door-to-surgery time must be within the first hour[1, 22]. In this case, patient was quickly transferred to hospital but, unfortunately, this target is more achievable in trauma centers, which is not available in all regions of Brazil neither worldwide.

Despite disagreements among neurosurgeons about surgical indication according to admissional GCS, there is a general agreement that once the surgery is proposed, it must be adopted the following precepts: 1) remotion of the foreign body in the operation room; 2) Evacuation of any hematomas or lesions causing mass effect; 3) debridement only around the injury tissue; 4) vigorous hemostasis; 5) Watertight dural and scalp closure [5, 12, 17, 23–26].

Furthermore, is fundamental adequate post-operative care to prevent and treat early (< 1 week) and late (> 1 week) complications following PBI: hemorrhage and infection (most commons)[7, 27], cerebral contusion or edema, ischemic or vascular injury, hydrocephalous, liquor leakage and foreign body migration[2]. In our case, patient suffered an early complication promptly diagnosed and treated,

demonstrating that post-operative imaging and follow-up are crucial to identify complications[5, 8, 14, 23].

Although infection associated with TBI ranges from 5–23%[2, 17, 28], in pediatric PBI reaches over 40% [15]. Prophylaxis with broad-spectrum antibiotics should be done, but its duration is still under discussion[1, 5, 7, 17, 19, 25]. Our patient received 4 weeks of intravenous Ceftriaxone and Metronidazole and no infection was observed. Also, we routinely administer anticonvulsants within 7 days[29]. Afterwards, medication is discontinued and all were followed up for a minimum of 2 years, since 80% of PBI patients have seizure during this time[17, 30].

Prognosis of PBI depends on multiple factors and the first golden hour post-trauma is decisive. In our case, patient survived with good neurologic status not only being promptly operated, but also by the multidisciplinary team post-operative management.

Conclusion

TBI requires remarkable attention and quick action as it may lead to irreversible brain damage and death. Due to its complexity and rarity, this PBI by pickaxe report could contribute with feasible management suggestions and also to show that even in the most serious conditions, we could have hope.

Declarations

Funding

The authors declare that no funds, grants, or other support were received during the preparation of this manuscript.

Conflicts of Interest

The authors confirm that there are no known conflicts of interest with this publication and no relevant financial or non-financial interests to disclose.

Author Contributions

First draft of manuscript, literature review and data analysis: Raíssa Mansilla

Review and editing: Bárbara Contarato Pilon, Geraldo Paraguassu;

Material preparation and data collection: Luís Gustavo Duarte Amaral and Paulo Henrique Reigota Pinguelo

Article's idea: Paulo Henrique Reigota Pinguelo and Fernando Jorge Monteiro Martins

Ethics approval

Ethical approval was waived by the local Ethics Committee of Fluminense Federal University in view of the retrospective nature of the study and all the procedures being performed were part of the routine care

Consent to participate and publish (participant)

Written informed consent was obtained from the legal guardian of the child, including the consent for image publication available in Figure 2a.

Consent to publish (authors)

As corresponding author, I confirm that all authors read and approved the final manuscript.

References

1. Pringle C, Bailey M, Bukhari S, et al (2020) Manchester Arena Attack: management of paediatric penetrating brain injuries. Br J Neurosurg 0:1–9. https://doi.org/10.1080/02688697.2020.1787339
2. Vakil MT, Singh AK (2017) A review of penetrating brain trauma: epidemiology, pathophysiology, imaging assessment, complications, and treatment. Emerg Radiol 24:301–309. https://doi.org/10.1007/s10140-016-1477-z
3. Joseph B, Aziz H, Pandit V, et al (2014) Improving survival rates after civilian gunshot wounds to the brain. J Am Coll Surg 218:58–65. https://doi.org/10.1016/j.jamcollsurg.2013.08.018
4. De Holanda LF, Pereira BJA, Holanda RR, et al (2016) Neurosurgical Management of Nonmissile Penetrating Cranial Lesions. World Neurosurg 90:420–429. https://doi.org/10.1016/j.wneu.2016.03.015
5. Chowdhury FH, Haque MR, Hossain Z, et al (2016) Nonmissile Penetrating Injury to the Head: Experience with 17 Cases. World Neurosurg 94:529–543. https://doi.org/10.1016/j.wneu.2016.06.062
6. Evangelos D, Dimitrios G, Alexandros B, et al (2018) Pediatric Nonmissile Penetrating Head Injury: Case Series and Literature Review. World Neurosurg 110:193–205. https://doi.org/10.1016/j.wneu.2017.11.037
7. Fahde Y, Laghmari M, Skoumi M (2017) Penetrating head trauma: 03 rare cases and literature review. Pan Afr Med J 28:. https://doi.org/10.11604/pamj.2017.28.305.10376
8. Mikhael M, Frost E, Cristancho M (2018) Perioperative Care for Pediatric Patients with Penetrating Brain Injury: A Review. J Neurosurg Anesthesiol 30:290–298. https://doi.org/10.1097/ANA.0000000000000441
9. Mbengono JAM, Ntock FN, Tochie JN, et al (2019) Anesthetic Management of a Rare Penetrating Traumatic Brain Injury Caused by a Pickaxe: A Case Report. Open J Anesthesiol 09:155–165. https://doi.org/10.4236/ojanes.2019.98015
10. Harlow JM (1848) Passage of an iron rod through the head. 1848. Bost Med Surg J 39:389–393

11. Tan MH, Choudhari KA (2003) Penetrating head injury from an electrical plug. Injury 34:950–953. https://doi.org/10.1016/S0020-1383(02)00167-5
12. Chattopadhyay S, Sukul B, Das SK (2009) Fatal transorbital head injury by bicycle brake handle. J Forensic Leg Med 16:352–353. https://doi.org/10.1016/j.jflm.2009.01.010
13. Teixeira Domingues Duarte TSA L, Ângelo Saraiva TSA R (2009) When the Bispectral Index (Bis) can Give False Results. Rev Bras Anestesiol Rev Bras Anestesiol Artig REVISÃO 99:99–109. https://doi.org/10.1590/S0034-70942009000100013
14. Domingo Z, Peter JC, de Villiers JC (1994) Low-velocity penetrating craniocerebral injury in childhood. Pediatr Neurosurg 21:45–49
15. Koestler J, Keshavarz R (2001) Penetrating head injury in children: A case report and review of the literature. J Emerg Med 21:145–150. https://doi.org/10.1016/S0736-4679(01)00363-8
16. Pandey S, Li L, Cui DM, et al (2018) Perforating brain injury by a rusty steel bar. J Craniofac Surg 29:e372–e375. https://doi.org/10.1097/SCS.0000000000004394
17. Kazim SF, Shamim MS, Tahir MZ, et al (2011) Management of penetrating brain injury. J Emergencies, Trauma Shock 4:395. https://doi.org/10.4103/0974-2700.83871
18. Paleologos TS, Wadley JP, Kitchen ND, et al (2000) Clinical utility and cost-effectiveness of interactive image-guided craniotomy: Clinical comparison between conventional and image-guided meningioma surgery. Neurosurgery 47:40–48. https://doi.org/10.1097/00006123-200007000-00010
19. Sweeney JM, Lebovitz JJ, Eller JL, et al (2011) Management of Nonmissile Penetrating Brain Injuries: A Description of Three Cases and Review of the Literature. Skull Base Reports 1:39. https://doi.org/10.1055/S-0031-1275257
20. Van Dallen, JR; Lipschitz R (1978) Stab wounds of the skull. Surg Neurol 10:110–114
21. Gauss T, Ageron FX, Devaud ML, et al (2019) Association of Prehospital Time to In-Hospital Trauma Mortality in a Physician-Staffed Emergency Medicine System. JAMA Surg 154:1117–1124. https://doi.org/10.1001/JAMASURG.2019.3475
22. Eskridge SL, MacEra CA, Galarneau MR, et al (2012) Injuries from combat explosions in Iraq: injury type, location, and severity. Injury 43:1678–1682. https://doi.org/10.1016/J.INJURY.2012.05.027
23. Shi J, Mao Y, Cao J, Dong B (2017) Management of screwdriver-induced penetrating brain injury: A case report. BMC Surg 17:15–18. https://doi.org/10.1186/s12893-016-0195-5
24. Karim T, Topno M (2010) An unusual case of penetrating head injury in a child. J Emergencies, Trauma Shock 3:197–198. https://doi.org/10.4103/0974-2700.62113
25. Esposito DP, Walker JB (2009) Contemporary management of penetrating brain injury. Neurosurg Q 19:249–254. https://doi.org/10.1097/WNQ.0B013E3181BD1D53
26. Pruitt B (2001) Guidelines for the management of penetrating brain injuries. J Trauma 51:S1–S86
27. Aarabi B, Taghipour M, Haghnegahdar A, et al (2000) Prognostic factors in the occurrence of posttraumatic epilepsy after penetrating head injury suffered during military service. Neurosurg Focus 8:1–6. https://doi.org/10.3171/FOC.2000.8.1.155

28. Van Wyck DW, Grant GA, Laskowitz DT Penetrating Traumatic Brain Injury: A Review of Current Evaluation and Management Concepts. https://doi.org/10.4172/2155-9562.1000336
29. Carney N, Totten AM, Ullman JS, et al (2016) Guidelines for the Management of Severe Traumatic Brain Injury 4th Edition
30. Wu R, Ye Y, Liu C, et al (2018) Management of Penetrating Brain Injury Caused by a Nail Gun: Three Case Reports and Literature Review. World Neurosurg 112:143–147. https://doi.org/10.1016/j.wneu.2018.01.127

Table

Table 1
Comparison of the African case of PBI by a pickaxe with the present study.

Trauma Report	Mansilla R et al. (2022)	Mbengono JAM et al (2019)
Country	Brazil	Cameroon
Age	13	34
Gender	Male	Male
Transport to hospital	Advanced Ground Ambulance	Neighbor
Aggression type	Paternal violence	Assault
Time to hospital arrival	30 minutes	Not described
Door-to-surgery time	1 hour	Not described
Penetrating agent	Pickaxe	Pickaxe
Material	Metal	Not described
Entry point	Frontotemporal	Frontotemporal
Side	Left	Left
GCS on admission	3	15
Pupils on admission	Anisocoric (L > R)	Anisocoric (R > L)
Post-operative complication	Yes. Hemorrhage and brain edema	No.
GOS-HD (hospital discharge)	3 (severe disability)	5
GOS-Late (12 months)	5 (good recovery)	5
Antibiotic prophylaxis	28 days (ceftriaxone + metronidazole)	5 days
Tetanus prophylaxis	Yes. 1st hour	Yes.
Inpatient hospital stays	28 days	5 days
Rehabilitation	Physio and speech therapy	Not described

Figures

Figure 1

Old Steel Wood Pickaxe – Weapon Characteristics.

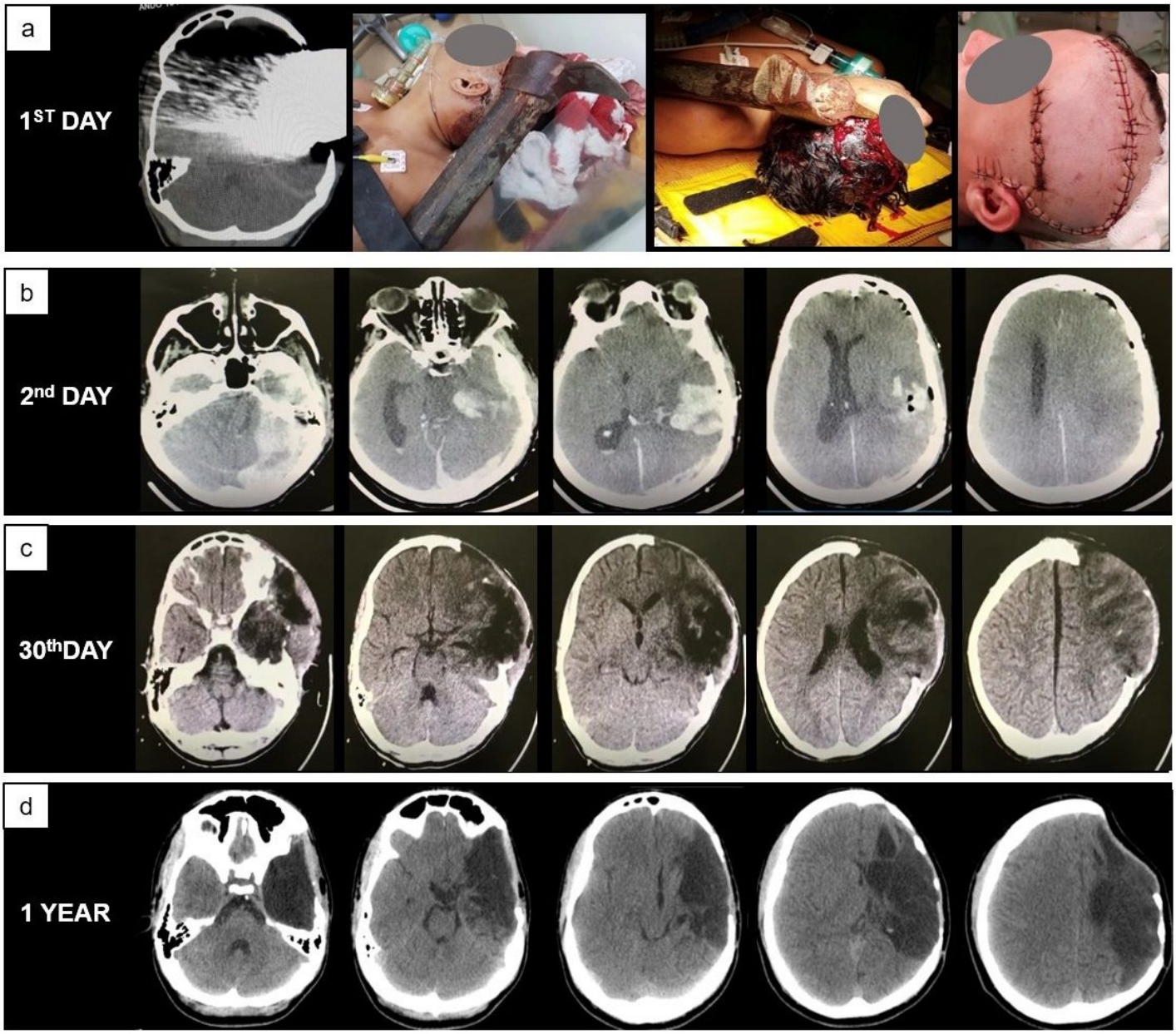

Figure 2

Timeline summarizing major events of the case. a. First day trauma - admissional images of the patient with perforating injury below the left frontotemporal side caused by pickaxe, his admissional CT head and the final aspect of the skin incision post Becker flap. b. Day two pos-operative CT head with large hemorrhage and cerebral edema in the left side with midline shift bigger than 10mm and uncal herniation (Marshal IV). c. One-month post-operative CT with encephalomalacia at the site of prior contusion, brain parenchyma bulging above the inner plate of the skull and wide decompressive craniectomy (12 x 15cm). d. One year post operative CT head showing relaxed brain parenchyma with frontoparietotemporal hypodensity.