Infection with Novel Coronavirus (SARS-CoV-2) Causes Pneumonia in the *Rhesus Macaques*

Chao Shan (shanchao@wh.iov.cn)
Center for Biosafety Mega-Science, Wuhan Institute of Virology, Chinese Academy of Sciences

Yan-Feng Yao
Center for Biosafety Mega-Science, Wuhan Institute of Virology, Chinese Academy of Sciences

Xing-Lou Yang
Center for Biosafety Mega-Science, Wuhan Institute of Virology, Chinese Academy of Sciences

Yi-Wu Zhou
Department of Forensic Medicine, Tongji Medical College of Huazhong University of Science and Technology

Jia Wu
Center for Biosafety Mega-Science, Wuhan Institute of Virology, Chinese Academy of Sciences

Ge Gao
Center for Biosafety Mega-Science, Wuhan Institute of Virology, Chinese Academy of Sciences

Yun Peng
Center for Biosafety Mega-Science, Wuhan Institute of Virology, Chinese Academy of Sciences

Lian Yang
Department of Radiology, Union Hospital, Tongji Medical College, Huazhong University of Science and Technology

Xue Hu
Center for Biosafety Mega-Science, Wuhan Institute of Virology, Chinese Academy of Sciences

Jin Xiong
Center for Biosafety Mega-Science, Wuhan Institute of Virology, Chinese Academy of Sciences

Ren-Di Jiang
Center for Biosafety Mega-Science, Wuhan Institute of Virology, Chinese Academy of Sciences, and University of Chinese Academy of Sciences, Beijing

Hua-Jun Zhang
Center for Biosafety Mega-Science, Wuhan Institute of Virology, Chinese Academy of Sciences

Xiao-Xiao Gao
Center for Biosafety Mega-Science, Wuhan Institute of Virology, Chinese Academy of Sciences

Cheng Peng
Center for Biosafety Mega-Science, Wuhan Institute of Virology, Chinese Academy of Sciences

Juan Min
Center for Biosafety Mega-Science, Wuhan Institute of Virology, Chinese Academy of Sciences

Ying Chen
Center for Biosafety Mega-Science, Wuhan Institute of Virology, Chinese Academy of Sciences, and University of Chinese Academy of Sciences, Beijing
Hao-Rui Si
Center for Biosafety Mega-Science, Wuhan Institute of Virology, Chinese Academy of Sciences
Peng Zhou
Center for Biosafety Mega-Science, Wuhan Institute of Virology, Chinese Academy of Sciences
Yan-Yi Wang
Center for Biosafety Mega-Science, Wuhan Institute of Virology, Chinese Academy of Sciences
Hong-Ping Wei
Center for Biosafety Mega-Science, Wuhan Institute of Virology, Chinese Academy of Sciences
Wei Pang
Key Laboratory of Animal Models and Human Disease Mechanisms of the Chinese Academy of Sciences, Kunming Institute of Zoology, Chinese Academy of Sciences
Zheng-Fei Hu
Kunming Primate Research Center of the Chinese Academy of Sciences, Kunming Institute of Zoology, Chinese Academy of Sciences
Long-Bao Lv
Kunming Primate Research Center of the Chinese Academy of Sciences, Kunming Institute of Zoology, Chinese Academy of Sciences
Yong-Tang Zheng
Key Laboratory of Animal Models and Human Disease Mechanisms of the Chinese Academy of Sciences, Kunming Institute of Zoology, Chinese Academy of Sciences
Zheng-Li Shi (zlshi@wh.iov.cn)
Center for Biosafety Mega-Science, Wuhan Institute of Virology, Chinese Academy of Sciences
Zhi-Ming Yuan (yzm@wh.iov.cn)
Center for Biosafety Mega-Science, Wuhan Institute of Virology, Chinese Academy of Sciences

---

Research Article

Keywords:

Posted Date: February 27th, 2020

DOI: https://doi.org/10.21203/rs.2.25200/v1

Version of Record: A version of this preprint was published at Cell Research on July 7th, 2020. See the published version at https://doi.org/10.1038/s41422-020-0364-z.

Abstract

Main Text

Coronavirus infections are common in humans and other mammals. Coronaviruses belong to the family *Coronaviridae* and possess a single strand, positive-sense RNA genome ranging from 26 to 32 kilobases in length. In December, 2019, a cluster of cases of pneumonia were reported in people associated with the Huanan Seafood Wholesale Market in Wuhan, Hubei Province. The subsequently research from the bronchoalveolar lavage fluid (BALF) of a hospitalized patient allowed the isolation of a novel coronavirus, which was named severe acute respiratory syndrome coronavirus 2 (SARS-CoV–2) and considered as the pathogen of the current outbreak of coronavirus disease (COVID–19)[1]. The common clinical features for COVID–19 include fever, cough, myalgia, fatigue, dyspnea, lymphopenia, and pneumonia, less common symptoms including sputum production, headache and haemoptysis and diarrhea[2]. As of February 19, 2020, a total of 75,204 cases had been reported in at least 25 countries with more than 10,000 in severe condition and 2,009 deaths[3], whereas a sizable portion of infected but non-symptomatic people with potential of transmissibility was also reported[4,5]. Due to the urgency of the situation, World Health Organization declared that the outbreak of SARS-CoV–2 in China constitutes a Public Health Emergency of International Concern (PHEIC).

Animal models are essential for the study of pathogenesis of the viral infection, the evaluation of potential antiviral treatments or vaccine development. Here we report a nonhuman primate disease model for SARS-CoV–2. We experimentally infected *Rhesus macaques* (RM) using SARS-CoV–2 isolation from clinical bronchoalveolar lavage fluid[6] and we evaluated the dynamics of SARS-CoV–2 in the blood, swabs and respiratory tract tissues of *Rhesus macaques.*

Six RM (1–6) between the ages of 6 and 12 years, three males and 3 females, were inoculated with 7×10^6 50% tissue-culture infectious doses (TCID50) of SARS-CoV–2 IVCAS 6.7512 through intratracheal route. The blood, oropharyngeal swab, nasal swab and anal swab were evaluated post infection (Fig. 1a). No obvious clinical signs were observed during the study course except one animal showed reduced appetite. The body weight (Fig. 1b) did not show any change from 1 to 6 day post infection (d.p.i.) for all animals investigated while 7% and 8% weight loss was noticed on 14 d.p.i. in RM1 and RM4, respectively. The body temperature (Fig. 1c) was monitored from day 1 to day 14 and no obvious changes were found.

To examine the viral replication dynamics in the RM, the blood, oropharyngeal swab, nasal swab and anal swab were collected on 1–6, 9, 11 and 14 d.p.i. from the RMs available for study. No viral RNA could be detected from the blood through out day 1 to day 14 by quantitative reverse transcriptase-polymerase chain reaction (RT-qPCR) (Fig. 1d). Two peaks were observed on 1 and 5 d.p.i. in most animals from throat samples (Fig 1e). The first peak viral load on day 1 was examined in all six animals (RM1-RM6) from oropharyngeal swab and ranged 2.08×10^4–2.85×10^7 copies/ml. Due to the euthanization of two animals on day 3 and another two on day 6 for pathological examination, the animal sample size for the

following investigation on day 4 were reduced to 4 whereas after day 6 were only two (see below). Notably, a second peak of viral load in oropharyngeal swab appeared on day 5 after infection with viral load of 1.03×10^7–3.60×10^7 copies/ml in three out of the four animals investigated (RM1, RM3 and RM4), whereas one monkey (RM5) that exhibited a very low viral RNA load (<10 copies/ml) on day 5 showed an increased viral load on day 6 after infection (around 200 copies/ml). The viral RNA levels in throat fell rapidly after day 6 in the two remaining RMs (RM1 and RM4) and reached undetectable level in these two animals by day 9. The nasal swabs also started to show positive viral RNA in 3 (RM1, RM2 and RM4) out of 6 RMs (Fig. 1f) on 1, 2 and 3 d.p.i. and maintained positive for 2–3 days. Furthermore, we evaluated the anal viral levels from 1 to 14 d.p.i. (Fig. 1g). Three out of six RMs exhibited detectable viral RNA on day 2 with RM1 showing the longest viral shedding till day 11. Overall, the viral RNA was detected from upper respiratory tract after infection. The two peaks in throat could represent the original input and viral replication in the throat, respectively. The fact that viral RNA was positive from anal swab suggested a possible occurrence of the infection in digestive tract.

The chest X-ray examination was conducted in animals on 0, 1, 3 and 6 d.p.i.. As shown in Fig. 2a (left panel), normal lungs were presented before infection, while patchy glass-ground opacity was observed in the lower parts of both left and right lungs on 1 d.p.i. (Fig. 2a middle left panel). On 3 d.p.i., multiple glass-ground opacity in left and right lungs was found (Fig. 2a, middle right panel) and the density decreased slightly on day 6 (Fig. 2a, right panel) while the scope of lung lesions extended from day 3 to day 6. Two animals (RM2 and RM6) were euthanized on day 3 while another two (RM3 and RM5) were euthanized on 6 d.p.i.. Necropsy was then performed in all the four animals. Postmortem examinations showed a variable degree of consolidation, edema, hemorrhage and congestion in bright red lesions throughout the lower respiratory tract which indicated the diffuse interstitial pneumonia (Fig.2b). After necropsy, the tissues and organs were harvested for quantification of viral RNA. RT-qPCR analysis was performed in respiratory tract tissues and other organs. The data revealed the widespread presence of SARS-CoV–2 in the respiratory tract (Fig. 2c-d). The amount of the viral RNA ranged from 3.0×10^4 to1.5×10^7 copies/g in trachea and bronchus tract on both 3 and 6 d.p.i.. In the lungs, viral RNA was detected with titre up to 2.0×10^7 copies/g and mainly localized in the lower lobes of lungs. Upon necropsy, the area of lung lobes affected by lesions was estimated by pathologists. Histopathological analysis showed damaged areas surrounding small bronchus, with the most serious injury in the inferior lobe of the left and right lungs. Thickened alveolar walls with fibroblast proliferation were observed in the majority of alveoli. Pulmonary hyaline-membrane formation, hemorrhage and edema could be seen in the alveoli (Fig. 2 e-g). Confocal microscopy analysis of lesion sites using specific antibodies (anti-RP3-CoV N protein) indicated the positive viral N protein (Fig. 2h). These results suggested that SARS-CoV–2 could infect the respiratory tract resulting in diffuse interstitial pneumonia in RMs.

To confirm the disease was caused by SARS-CoV–2, the virus was also re-isolated from bronchus, lung tissues and oropharyngeal swab. The whole genome sequence alignment analysis showed isolated viruses were >99.99% identical to the original input viral samples (Table 1). To examine whether neutralizing antibody was generated after infection, the sera from RM1 and RM4 were used for plaque

reduction neutralization test (PRNT). As shown in table 2, the titre for RM1 reached to 1:1,350 on 14 d.p.i. and increased 1:4050 on 21 d.p.i., while RM4 maintained the same titre as 1:12,150 on both 14 and 21 d.p.i..

Collectively, SARS-CoV–2 caused acute localized-to-widespread pneumonia as proved by pathological studies in all animals studied, although without obvious clinical symptoms of respiratory disease. This animal model has confirmed the causal relationship between SARS-CoV–2 and respiratory disease in RM reminiscent of the mild respiratory disease or non-symptomatic cases in COVID–19 already reported in humans[4,5], thus fulfilling Koch's postulates. The model enables detailed studies of the pathogenesis of this illness and may play a critical role in the evaluation of therapeutic drugs and vaccines.

Declarations

Acknowledgments

We thank all colleagues from National Biosafety Laboratory (Wuhan), Chinese Academy of Sciences for their support during the study. Dr. ZM Yuan was supported by National Key R&D Program of China (2020YFC0842000). Dr. ZL Shi was supported by the Strategic Priority Research Program of the Chinese Academy of Sciences (XDB29010101). Dr. XL Yang was supported by Youth Innovation Promotion Association of the Chinese Academy of Sciences (CAS) (2019328). HP Wei and J Xiong thank the financial support from the Mega-project of Infectious diseases control (No 2017ZX10302301–005. We also thank Lei Zhang from Center for Instrumental Analysis and Metrology and Xue-Fang An, Fan Zhang and He Zhao from Center for Animal Experiment, Wuhan Institute of Virology, Chinese Academy of Sciences.

Author contributions

C. S., Y. F.YX. L. Y., Y. W. Z., G. G., Y. P., L. Y., X. H., J. X., R. D. J., H. J.Z, X. X. G., C. P., J. M., Y. C. and H. P. W. performed experiments and data analysis. C. S., Y. F.Y, Y. W. Z., J. W. G. G., P. Z., Y. Y. W., W. P., Y. T. Z., Z. L. S. and Z. M. Y. designed the experiments and interpreted the results. C. S., Y. F. Y., and Z. Y. wrote the manuscript.

Conflict of interest statement

The authors have no conflict of interest in this study.

Data availability. The source data will provide as a Source Date file.

Ethics statement

All animal experiments were approved by the Institutional Animal Care and Use Committee (Ethics number: WIVA42202001) of Wuhan Institute of Virology, Chinese Academy of Sciences. The SARS-CoV–2 animal model experiments and protocols were also discussed explicitly and extensively with biosafety officers and facility managers at the Wuhan Institute of Virology. All experiments were conducted within the animal biosafety level 4 (ABSL–4) facility in National Biosafety Laboratory (Wuhan), Chinese Academy of Sciences.

Materials And Methods

Virus, cell and antibody

SARS-CoV–2 (IVCAS 6.7512) was isolated from a bronchoalveolar lavage fluid collected from a patient with viral pneumonia in December 2019 in Wuhan, China. The virus isolation was propagated in Vero E6 cells (ATCC® CRL–1586™) in DMEM supplemented with 10% fetal calf serum, 1 mM L-glutamine, 100 international units (IU)/mL penicillin, and 100 μg/mL streptomycin and cultured at 37°C in 5% CO_2. The virus was harvested on day 3 post infection. The anti-RP3-CoV N protein antibody was made in house. And Cy3-conjugated goat-anti-rabbit IgG was purchased Abcam.

Virus titration

Virus titrations were performed by endpoint titration in Vero E6 cells. Cells were inoculated with 10-fold serial dilutions of cell supernatant. One hour after inoculation of cells, the inoculum was removed and replaced with 100μl of DMEM supplemented with 2% fetal bovine serum [1 mM L-glutamine, penicillin (100 IU/ml), and streptomycin (100 μg/ml)]. Three days after inoculation, cytopathic effect was scored, and the $TCID_{50}$ was calculated.

Animal study and sample collection

Six *rhesus macaques* (three males, three females; age 6–12 years, weight 5–12 kg), were inoculated with SARS-CoV–2 (7×10^6 $TCID_{50}$) diluted in DMEM. The *rhesus macaques* (RMs) were anesthetized, and 1 ml of the inoculum was administered intratracheally. Two mock RMs were intratracheally inoculated with DMEM to serve as controls. The RMs were observed twice daily, with detailed recording of clinical signs, symptoms, morbidity, and mortality, including the nature, onset, severity, and duration of all gross or visible changes. The X-rays examination were performed on 0, 1, 3 and 6-day post infection (d.p.i.) by HF100Ha (MIKASA, Japan). Swab samples of the oropharyngeal, nasal turbinate, and anal regions were collected at 1–6 d.p.i. Swabs were placed into 1 ml of Dulbecco's modified Eagle's medium (DMEM) with penicillin (100 IU/ml) and streptomycin (100 μg/ml). Whole blood was collected in K_2EDTA tubes for viral RNA extraction and analysis. To confirm the pathogenesis and injury in the respiratory tract, two infected RMs were sacrificed at 3 d.p.i and 6 d.p.i, respectively. The trachea, right bronchus, left bronchus, all six

lung lobes and other tissues organs were collected on the day of euthanization for various pathological, virological, and immunological analysis.

Quantitative reverse transcription polymerase chain reaction

Viral RNA in the samples was quantified by one-step real-time quantitative RT-PCR[6].

The swab and blood samples were used to extract viral RNA by using the QIAamp Viral RNA Mini Kit (Qiagen), according to the manufacturer's instructions. Tissues were homogenized in DMEM (1:10, W/V), clarified by low-speed centrifugation at 4500 g for 30 minutes at 4°C and supernatant was immediately used for RNA extraction. RNA was eluted in 50 µl of elution buffer and used as the template for RT-PCR. The primers pairs were used following our previous study which is targeting S gene: RBD-qF1: 5'-CAATGGTTTAACAGGCACAGG–3'; RBD-qR1: 5'-CTCAAGTGTCTGTGGATCACG–3'. Two microliters of RNA were used to verify the RNA quantity by HiScript® II One Step qRT-PCR SYBR® Green Kit (Vazyme Biotech Co., Ltd) according to the manufacturer's instructions. The amplification was

performed as followed: 50 ℃ for 3 min, 95 ℃ for 30 s followed by 40 cycles consisting of 95 ℃ for 10 s, 60 ℃ for 30 s, and a default melting curve step in an ABI stepone machine.

Histopathology and Immunohistochemistry

Animal necropsies were performed according to a standard protocol. Samples for histological examination were stored in 10% neutral-buffered formalin for 7 days, embedded in paraffin, sectioned, and stained with hematoxylin and eosin prior to examination by light microscopy. To examine the SARS-CoV–2 antigen, paraffin dehydrated tissue sections were placed in antigen repair buffer for antigen retrieval in a microwave oven. The tissue was blocked with 5% BSA at room temperature for 1 hour, following with house-made primary antibody at 1:500 (rabbit anti- RP3-CoV N protein polyclonal antibody). After washed by PBS, the slices were slightly dried and covered with Cy3-conjugated goat-anti-rabbit IgG (Abcam) at 1:200 dilution. The slides were stained with DAPI (5µg/ml) after washing by PBS. The image was collected by Pannoramic MIDI system (3DHISTECH, Budapest, Hungary).

Virus re-isolation and sequencing

The supernatant from homogenized samples was used for re-isolating the virus. Three hundred microliter supernatant was used to infect the monolayer Vero cells in 24-well plate. After 1h inoculation, the supernatant was removed and replaced with fresh DMEM containing 2%FBS plus penicillin and streptomycin. CPE was monitored daily. The supernatant was subjected to viral RNA extraction once CPE was observed. The next generation sequencing was performed as previous reported[6].

Neutralizing antibody titre

The virus neutralization test was performed in a 12-well plate. The serum samples from RMs were heat-inactivated at 56 °C for 30 min. The serum samples were diluted to 1:50, 1:150, 1:450, 1:1350, 1:4050 and 1:12150, and then an equal volume of virus stock was added and incubated at 37 °C in a 5% CO2 incubator. After 1h incubation, 100 μL mixtures were inoculated onto monolayer Vero cells in a 12-well plate for 1 hour with shaking every 15mins. The inocula was removed and cells were incubated with DMEM supplemented with 2% FBS containing 0.9% methylcellulose 3 days before fix. The cells were fixed with 4% formaldehyde after 3 days inoculation for 30mins. Then the solution was removed and washed by tap water, followed by crystal violet staining. The plaques were counted for calculating the titre.

Reference

1WHO. *Statement on the second meeting of the International Health Regulations (2005) Emergency Committee regarding the outbreak of novel coronavirus (2019-nCoV),* 2020).

2Huang, C. *et al.* Clinical features of patients infected with 2019 novel coronavirus in Wuhan, China. *Lancet 395,* 497–506, doi:10.1016/S0140–6736(20)30183–5 (2020).

3WHO. Coronavirus disease 2019 (COVID–19) Situation Report—29. (2020).

4Guan, W.-j. *et al.* Clinical characteristics of 2019 novel coronavirus infection in China. *medRxiv,* 2020.2002.2006.20020974, doi:10.1101/2020.02.06.20020974 (2020).

5Zhe Xu, L. S., Yijin Wang, Jiyuan Zhang, Lei Huang, Chao Zhang, Shuhong Liu, Peng Zhao, Hongxia Liu, Li Zhu, Yanhong Tai, Changqing Bai, & Tingting Gao, J. S., Peng Xia, Jinghui Dong, Jingmin Zhao, Fu-Sheng Wang. Pathological findings of COVID–19 associated with acute respiratory distress syndrome. *The Lancet Respiratory Medicine,* doi:https://doi.org/10.1016/S2213–2600(20)30076-X (2020).

6Zhou, P. *et al.* A pneumonia outbreak associated with a new coronavirus of probable bat origin. *Nature,* doi:10.1038/s41586–020–2012–7 (2020).

Tables

Table 1 The genome sequencing results of re-isolated virus from tissue

Sample	Start	End	Match	Identity
Reference sequence	1	29,891	-	-
Throat	1	29,867	29,854	>99.99%
Lung	1	29,867	29,854	>99.99%
Bronchus	1	29,878	29.871	>99.99%

Reference sequence: GeneBank ID MN996528.1.

Table 2 The neutralizing antibody titres in sera from SARS-CoV-2-infected *Rhesus Macaque*

Macaque identification no.	14 dpi	21dpi
RM1	1:1,350	1:4050
RM4	1:12,150	1:12,150

Figures

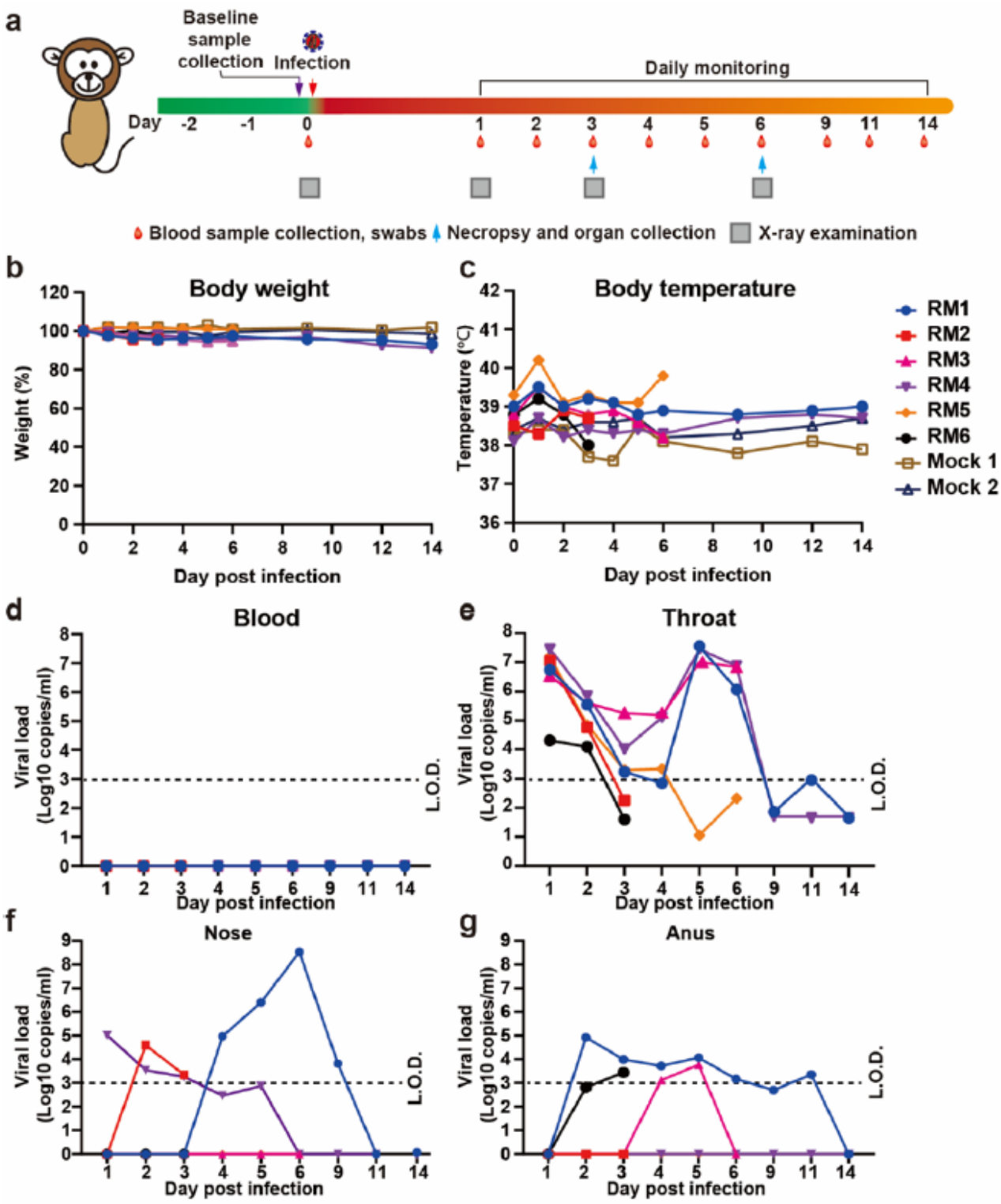

Figure 1

Experiment scheme, body weight, body temperature change and viral RNA load dynamics in SARS-CoV-2 infected rhesus macaques (RMs). (a) Experiment scheme and experimental parameters. Six RMs were intratracheally inoculated with 7×106 TCID50 of SARS- CoV-2. Mock 1 and Mock 2 were two control animals treated with DMEM. Disease parameters were measured including body weight, body temperature and swabs. Viral loads in blood and swabs were monitored to evaluate viral replication kinetics in RMs. Blood and swabs sample collection, chest X-ray examination and neprosy with organ pathological examination at indicated time points. The viral RNA was extracted by Qiagen Viral RNA kit and followed by RT- qPCR to quantify viral RNA. (b) Body weight changes of RMs after infection with SARS-CoV-2. (c) Changes of anal temperature of RMs after infection with SARS-CoV-2. (d) Absence of viral RNA in blood. (e) Viral RNA load in throat. (f) Viral RNA load in nose. (g) Viral RNA load in anus. L.O.D.: limit of detection.

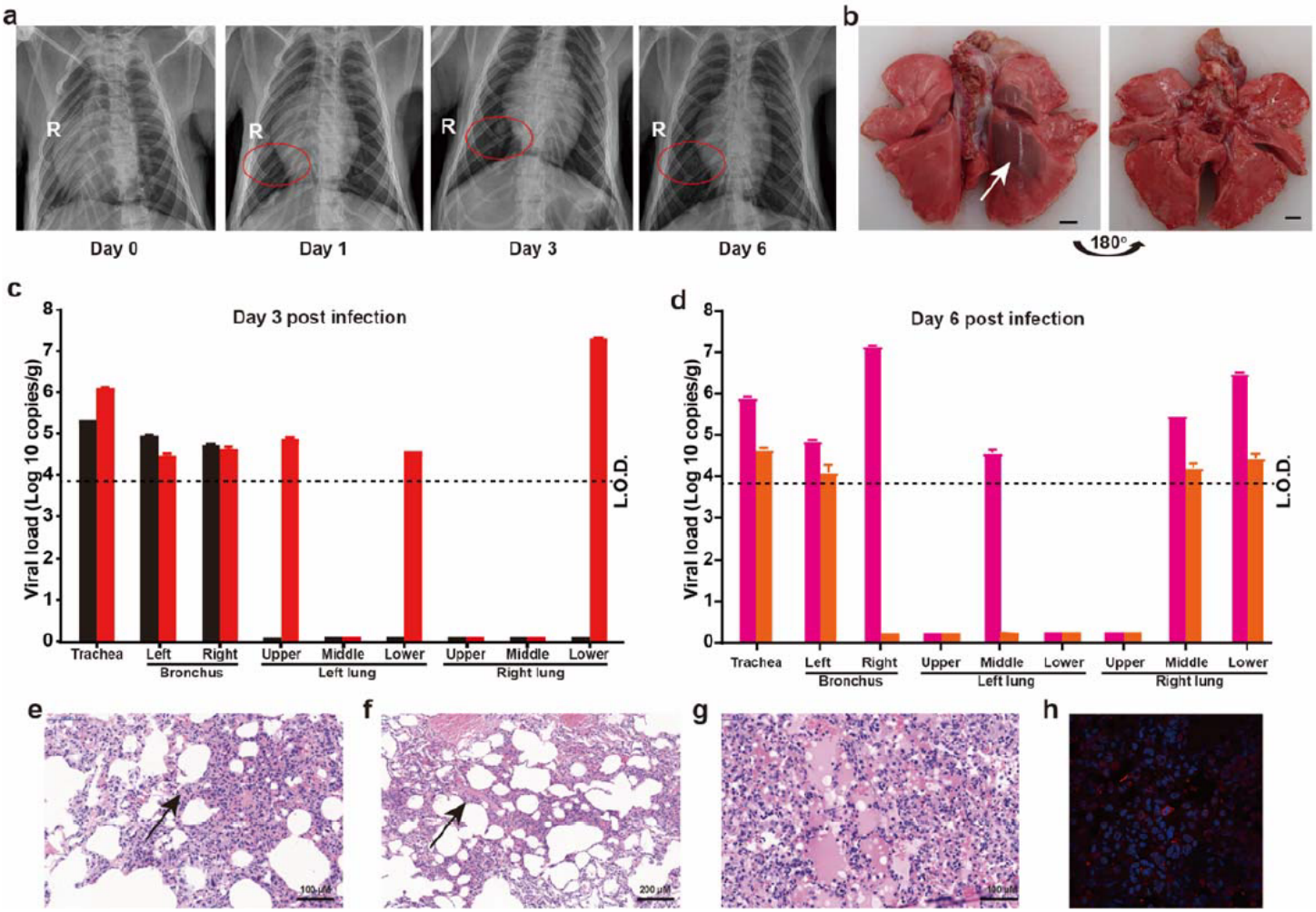

Figure 2

Characterization of the lung changes after SARS-CoV-2 infection. (a) Radiographs of the chest of RM before inoculation and on day 3 and day 6 after inoculation with SARS-CoV-2. The red circled areas are regions of interstitial infiltrates indicative of viral pneumonia. (b) Lesions in the lungs. A view of the ventral lungs of an infected animal obtained on necropsy on day 6 after inoculation, showing both normal and affected tissues. (c and d) Viral RNA load in respiratory tract and histopathological analysis

of lung tissue. Viral loads in trachea, bronchus, right and left upper, middle, and lower lung lobes on day 3 (c) and day 6 (d). (e-g) Histopathological analysis of lung tissues collected on day 3 after inoculation, with infiltrating neutrophils and macrophages associated with acute interstitial pneumonia. (h) Immunofluorescence analysis lung tissue results of SARS-CoV-2. A rabbit antibody raised against the RP3-CoV N protein was used for specific staining of SARS-CoV-2 antigen. Error bars mean standard deviation.