A novel technique of treating anterior cruciate ligament injury: combining the ACL reconstruction and repair.

Yuan Yang
Shenzhen Second People's Hospital https://orcid.org/0000-0001-6077-353X
Weimin Zhu (szhzwm@email.szu.edu.cn)
Yuxiao Lai
Shenzhen Institutes of Advanced Technology Chinese Academy of Sciences
Kang Chen
Shenzhen Second People's Hospital
Wenzhe Feng
Shenzhen Second People's Hospital

Technical advance

Keywords: ACL reconstruction, ACL reconstruction and repair , Anterior cruciate ligament (ACL)

Posted Date: March 4th, 2020

DOI: https://doi.org/10.21203/rs.3.rs-15969/v1

Abstract

If the ACL stump is strong enough and of good quality, we combine the ACL reconstruction and repair together. The main aim of this technique is to retain the autologous ACL stump to protect the proprioception and accelerate the revascularization and may even promote the healing of the bone to tendon. It is assumed that this will be better for the knee biomechanics in contrast to the simple reconstruction. This technique may also save the graft. That means we can only harvest one tendon gracilis or semitendinosus to satisfy the need of the knee stability.

Introduction

Anterior cruciate ligament (ACL) is one of the most vulnerable ligaments of athletes' knee joints, about 200,000 people suffered ACL lesions every year in the United States[1]. In the current trends, ACL reconstruction (ACLR) is the standard surgical procedure for restoring the patients' knee stability[2-4]. To the best of our knowledge, ACLR with preservation of tibial stump have been more accepted among the majority of orthopedists. Because it has some theoretical advantages, such as accelerating the reconstructed ACL revascularization, ligamentation, the restoration of proprioceptive feelings and the healing of the graft[5-9].

Since the early 1990s, ACL repair has been proposed to treat the ACL injuries[10]. Although having good outcomes in the early follow-up, not with promising mid-term results, this technique was forgotten[11]. But now ACL repair has been recommended again.

So we aim to provide a new technique of combining the ACL reconstruction and repair together which can theoretically providing the best benefits for patients. This technique is appropriate for those patients who has the proximal ACL avulsion, and is in the acute phase.

Operative techniques

ACL femoral avulsions and good quality of ACL stump tissue are confirmed on magnetic resonance imaging and the patients are in the acute stage(<3 weeks)(**Figure 1**). When the above conditions are met, we will treat it with our new technique combining the ACL reconstruction and repair (**Video and animation**).

Preparing and patient positioning

After receiving the lumbar anesthesia, the patient is in the supine position waiting for surgery. Using a tourniquet at the base of the thigh routinely, we disinfect the whole injured leg including the foot. Then the single-use sterile towel is applicated for covering the disinfected leg. When beginning the operation, the injured leg is drapped at the operating table. All cases are operated by the same surgeon.

Diagnostic arthroscopy

An anterolateral, anteromedial and parapatellar portals are made for diagnostic arthroscopy. Any chondral lesions and meniscus tears are examined under arthroscopy using the probe. Finally, the ACL femoral avulsions are confirmed (**Figure 2**).

Graft preparation

The gracilis and semitendinosus are harvested for tendon graft. The harvested tendons are weaved for 4 or 5 or 6 strands so that its diameter is approximately 8 mm. A NO.2 high strength sutures are weaving at the both free ends of the tendon. According to the length of the femoral tunnel, we choose the adjustable-loop or fixed-loop cortical suspension devices.

After passing the hamstring tendon through the loop of the endobutton, we bind the tendon graft with a 2-0 absorbable suture preventing the multi-strands graft spreading.

Tunnel creation

At the center of the femoral footprint, the 2.0mm K wire is applied to drill the femoral tunnel and then the femoral tunnel is enlarged with the proper-size reamer. When the femoral tunnel is finished, A guide pin carrying a NO.5 suture pass through the femoral tunnel. The surgeon drill the tibial tunnel through the C-type guide.

Preparation of the ACL stump

One stich on the ACL stump is applicated with PDS suture using the SutureLasso and then the PDS suture is replaced with the NO.2 high strength suture. 1-2 stiches with the NO.2 high strength suture are on the ACL stump using the SutureLasso again (**Figure 3**). When the stiches are prepared, the passage of the NO.5 suture(for traction) and the NO.2 high strength suture through the tibial tunnel are finished by a grasper.

Final procedures

Pass the two free ends of the NO.2 high strength suture through the holes on the endobutton (**Figure 4**) and both the NO.2 high strength suture and traction suture on the endobutton pass through the loop of the NO.5 suture. Pull the NO.5 suture to allow the passage of all the sutures into the bone tunnel. At last, the tendon graft is introduced into the bone tunnel and tighten the high strength suture to pull the ACL stump to the femoral footprint (**Figure 5**). Finally, the high strength suture is knotted and fastened on the endobutton which is on the lateral femoral cortex. A peek interference screw is fixed in the tibial tunnel. Finally, check the reconstructed graft tension with a probe and Lachman test and anterior drawer test is done to check the knee stability.

Postoperative rehabilitation

For the first 3 months, we recommend the patients the use of a knee brace. In order to control the swelling and pain, ice packs are also advised. The range of the knee motion is restricted to 90° in the next three

months. Nevertheless, full weight is permitted with the leg in extension when the patient can tolerate the pain without no stiches on the meniscuses. Straight leg lift exercises are encouraged. Two months after surgery, patients can go to the gym for muscle training. Three months after surgery, patients can remove braces and engage in non-confrontational activities such as jogging and swimming.

Discussion

The main aim of this technique is to retain the autologous ACL stump to protect the restoration of the proprioceptive feelings and accelerate the revascularization. It is assumed that this would be better for the knee biomechanics in contrast to the simple reconstruction. If the ACL stump is strong enough and of good quality, this technique may help reduce the tendon graft diameter. It means that we can only harvest one tendon gracilis or semitendinosus to satisfy the need of the knee stability and may even suture the ACL to the femoral footprint. Thus, the complications of donor site is correspondingly reduced.

The idea of this technique is inspired by the technique of ACL repair. In fact, the ACL repair is not a new concept, but in the previous literature, ACL repair was rarely been reported. On the one hand, few patients were operated in the acute stage. On the other hand, good quality of ACL stump is also rarely noticed in the operation. Some literatures have reported that the outcomes of ACL repair are of high failure rates[5, 12-14]. The main cause of this phenomenon is that they didn't observe the quality of ligament and ignore the operation opportunity. To improve the high failure rates of the ACL repair, we combine the reconstruction and repair. This technique includes both advantages of reconstruction and repair.

Adachi et al. [5] conducted an investigation which compared the ACL reconstruction with stump augmentation and simple reconstruction and the outcomes of augmentation group

were better. Lee et al. [19] found that the longer the ACL remnant, the functional scores and proprioception are better. A study by Zhang et al.[15] which compared the tibial tunnel widening between stump preserving and stump removing revealed that retaining the ACL stump can reduce the tibial tunnel widening. Zhang considered that the ACL remnant can offered blood supply to the ligament graft and can accelerate the healing between the graft and bone tunnel. Protecting the ACL stump may reduce the micromotion between the graft and bone tunnel and was able to allow quicker healing of the graft to the bone. But this was not proven in the literature. Trocan et al. [16] reported that the ACL stump had more CD34+ fibrocytes and could promote the revascularization compared to the normal ACL. Gohil et al. [6] designed a randomized controlled trial that revealed protecting the ACL stump can observe the early high signal in the ACL graft indicating revascularization.

The innovation point of our technique is to combine the reconstruction and repair. Indications for this technique must be proximal ACL avulsions without any interstitial ligament lesions and the time between injury to operation must be less than 3 weeks. In this technique, we assume that the ACL stump can heal the femoral footprint and incorporate in the graft. Up to now, we've done a series of cases of this technique and the patients' recovery is pretty good not only in functional scores but also in the

proprioception and revascularization. Next, we will investigate the outcomes of this technique in comparison to the simple ACL reconstruction.

Conclusions

This technique of combining the reconstruction and repair protects the knee proprioceptive feelings, accelerate the revascularization and strengthen the reconstructed ACL. This technique may also save the ligament graft and avoid the complications of the donor site. We are looking forward to comparing the outcomes of this technique to the outcomes of simple ACL reconstruction.

Declarations

Acknowledgements

Not applicable.

Authors' contributions

WMZ and YXL designed this study; YY and KC wrote the manuscript; WZF was responsible for drawing. All authors reviewed the final manuscript. All authors agreed to be accountable for all aspects of the work. All authors read and approved the final manuscript.

Funding

This study was mainly supported by Grants support from: The National Natural Science Foundation of China (no.81672234), The Shenzhen Science and Technology Project (project nos. GJHZ20180416164801042, JCYJ20160226192924528), Shenzhen Double Chain Project for Innovation and Development Industry supported by Bureau of Industry and Information Technology of Shenzhen (201806081524201510), and the Shenzhen Second People's Hospital clinical research (20173357201814)

Availability of data and materials

The datasets used and/or analyzed during the current study are available from the corresponding author on reasonable request.

Ethics approval and consent to participate

This study was approved by the Ethics Committee of the Shenzhen Second People's Hospital. Written, informed consent was obtained from each participant.

Consent for publication

Not applicable.

Competing interests

The authors declare that they have no competing interests.

References

1. Hootman, J.M., R. Dick, and J. Agel, *Epidemiology of collegiate injuries for 15 sports: summary and recommendations for injury prevention initiatives.* J Athl Train, 2007. **42**(2): p. 311-9.
2. Duquin, T.R., et al., *Current trends in anterior cruciate ligament reconstruction.* J Knee Surg, 2009. **22**(1): p. 7-12.
3. Garrett, W.E., Jr., et al., *American Board of Orthopaedic Surgery Practice of the Orthopaedic Surgeon: Part-II, certification examination case mix.* J Bone Joint Surg Am, 2006. **88**(3): p. 660-7.
4. Griffin, L.Y., et al., *Noncontact anterior cruciate ligament injuries: risk factors and prevention strategies.* J Am Acad Orthop Surg, 2000. **8**(3): p. 141-50.
5. Adachi, N., et al., *Anterior cruciate ligament augmentation under arthroscopy. A minimum 2-year follow-up in 40 patients.* Arch Orthop Trauma Surg, 2000. **120**(3-4): p. 128-33.
6. Gohil, S., P.O. Annear, and W. Breidahl, *Anterior cruciate ligament reconstruction using autologous double hamstrings: a comparison of standard versus minimal debridement techniques using MRI to assess revascularisation. A randomised prospective study with a one-year follow-up.* J Bone Joint Surg Br, 2007. **89**(9): p. 1165-71.
7. Junkin, D.M., Jr. and D.L. Johnson, *ACL tibial remnant, to save or not?* Orthopedics, 2008. **31**(2): p. 154-9.
8. Kim, S.J., et al., *A modified arthroscopic anterior cruciate ligament double-bundle reconstruction technique with autogenous quadriceps tendon graft: remnant-preserving technique.* Arch Orthop Trauma Surg, 2009. **129**(3): p. 403-7.
9. Lee, B.I., et al., *Comparison of clinical results according to amount of preserved remnant in arthroscopic anterior cruciate ligament reconstruction using quadrupled hamstring graft.* Arthroscopy, 2008. **24**(5): p. 560-8.
10. Palmer, I., *On the injuries to the ligaments of the knee joint: a clinical study. 1938.* Clin Orthop Relat Res, 2007. **454**: p. 17-22; discussion 14.
11. Engebretsen, L., S. Svenningsen, and P. Benum, *Poor results of anterior cruciate ligament repair in adolescence.* Acta Orthop Scand, 1988. **59**(6): p. 684-6.
12. Sherman, M.F., et al., *The long-term followup of primary anterior cruciate ligament repair. Defining a rationale for augmentation.* Am J Sports Med, 1991. **19**(3): p. 243-55.
13. Strand, T., et al., *Long-term follow-up after primary repair of the anterior cruciate ligament: clinical and radiological evaluation 15-23 years postoperatively.* Arch Orthop Trauma Surg, 2005. **125**(4): p. 217-21.

14. Taylor, D.C., et al., *Isolated tears of the anterior cruciate ligament: over 30-year follow-up of patients treated with arthrotomy and primary repair.* Am J Sports Med, 2009. **37**(1): p. 65-71.
15. Zhang, Q., et al., *The effect of remnant preservation on tibial tunnel enlargement in ACL reconstruction with hamstring autograft: a prospective randomized controlled trial.* Knee Surg Sports Traumatol Arthrosc, 2014. **22**(1): p. 166-73.
16. Trocan, I., et al., *Healing Potential of the Anterior Cruciate Ligament Remnant Stump.* In Vivo, 2016. **30**(3): p. 225-30.

Figures

Figure 1

preoperative MRI shows the ACL avulsion on the femoral side. The ACL stump is of good quality and the time between injury to operation is less than 3 weeks.

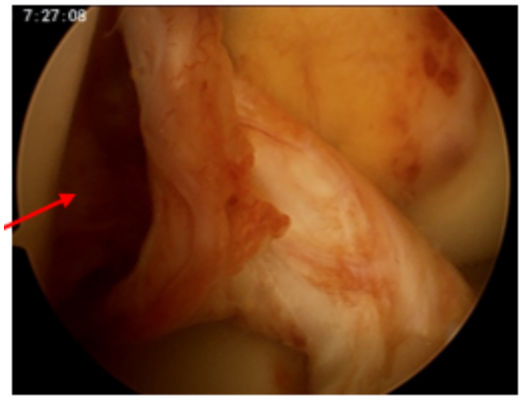

Figure 2

The ACL femoral avulsions are confirmed under arthroscopy and the remnant is of good quality.

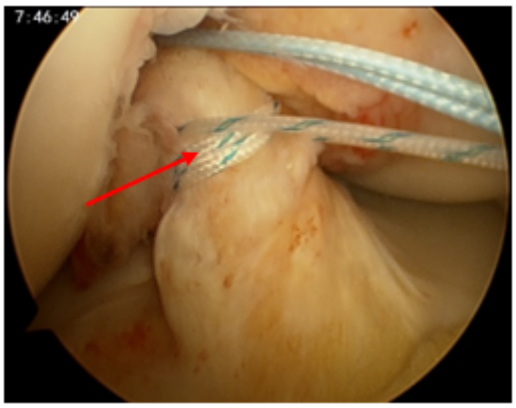

Figure 3

1-2 stiches with the NO.2 high strength suture are on the ACL stump using the SutureLasso.

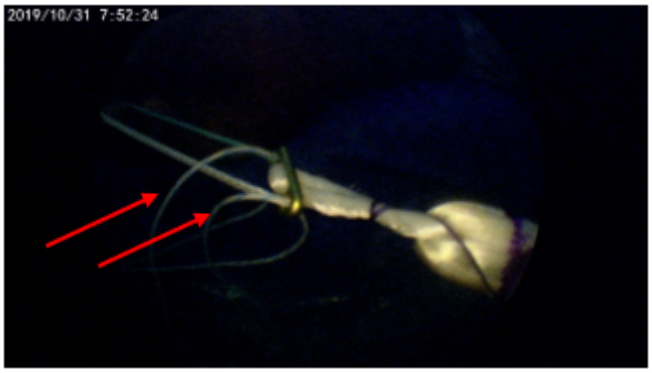

Figure 4

Pass the two free ends of the NO.2 high strength suture through the holes on the endobutton.

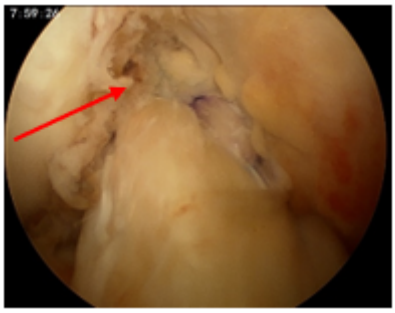

Figure 5

The tendon graft is introduced into the bone tunnel and tighten the high strength suture to pull the ACL stump to the femoral footprint.

Supplementary Files

This is a list of supplementary files associated with this preprint. Click to download.

- renamed1ad13.mp4
- renamed45abf.mp4