Blind nasogastric tube insertion performed within one minute or for a maximum of two or three attempts during resuscitation may minimize laryngopharyngeal mucosal injury: a prospective observational study

Kazuyuki Miyamoto (k-miyamoto@med.showa-u.ac.jp)
Showa University Northern Yokohama Hospital

Hiromi Takayasu
Showa University Fujigaoka Hospital

Shino Katsuki
Showa University Fujigaoka Hospital

Atsuo Maeda
Showa University Fujigaoka Hospital

Keisuke Suzuki
Showa University

Motoyasu Nakamura
Showa University

Noriko Hida
Showa University

Takehiko Sambe
Showa University

Masaharu Yagi
Showa University

Jun Sasaki
Showa University Fujigaoka Hospital

Munetaka Hayashi
Showa University Fujigaoka Hospital

Kenji Dohi
Showa University

Research Article

Keywords: Nasogastric tube, Blind insertion, Video-laryngoscope assisted insertion, Laryngopharynx mucosal injury, Insertion time, Insertion numbers, Resuscitation

Posted Date: April 29th, 2022

DOI: https://doi.org/10.21203/rs.3.rs-1601386/v1

Abstract

Background: Patients under resuscitation are at high risk for aspiration of gastric contents which causes ventilator-associated pneumonia. Therefore, blind nasogastric (NG) insertion is performed for decompression, however minimal trauma to the laryngopharynx can sometimes lead to severe bleeding in patients with a bleeding diathesis. Recently, the usefulness of NG tube placement under the assistance of a Video-laryngoscope (VLS) has reported. However, NG tube insertion is still performed blind, and insertion techniques to minimize mucosal injury during resuscitation are not well understood. We investigated laryngopharyngeal mucosal injury associated with blind NG tube insertion during resuscitation and considered practical blind NG tube insertion guidelines to minimize mucosal injury.

Methods: We included patients (n = 84) with cardio pulmonary arrest on arrival in whom blind nasogastric tube insertion was possible within 120 s in the Blind group and those in whom it was not possible in the Difficult (Dif) group. In the Dif group, VLS-assisted nasogastric tube insertion was performed. The laryngopharyngeal mucosal condition was recorded after NG tube insertion using VLS. Patient background, success rates, insertion time, the number of insertions, and injury scores were evaluated. A single regression analysis was performed, and practical blind NG tube parameters for insertion during resuscitation were assessed.

Results: Success rates in the Blind and Dif groups were 98.5% and 76.5%, respectively, and insertion times were 48.8 ± 4.0 and 54.8 ± 3.0 s, respectively. The number of insertions (2.1 ± 0.2 vs. 8.1 ± 0.8) and injury scores (1.04 ± 0.21 vs. 6.40 ± 0.64) in the Blind group were significantly lower than those in the Dif group, respectively. Mucosal injuries were most severe in the retropharyngeal wall in both groups. The number of insertions and insertion time both showed strong positive correlations with injury scores.

Conclusion: The severity of laryngopharyngeal mucosal injury increased with increased insertion time and the number of insertions. Blind nasogastric tube insertion performed within 1 min or for a maximum of two or three attempts may minimize laryngopharyngeal mucosal injury, and VLS-assisted insertion should be considered if these limits are exceeded.

Background

Nasogastric (NG) tubes are flexible double- or single-lumen tubes made of polyvinyl chloride, polyurethane, or silicone. An NG tube is usually introduced into one of the nares blindly, then passed through the oesophagus into the stomach. Nasogastric tube placement is usually easy; however, in some cases, the insertion is difficult for anatomical reasons. (1)

Cardiac arrest induces brain injury, which is the major cause of long-term disability and mortality among patients as the brain is vulnerable to hypoxia. (2) Welbourn and Efstathiou (3) have reported that a shorter duration of cardiopulmonary resuscitation (CPR) is associated with better neurological outcomes in patients with cardiac arrest. In some cases, the introduction of cardiac or pulmonary extracorporeal membrane oxygenation (ECMO) while continuing resuscitation is necessary. Resuscitation at the

emergency department (ED) requires several procedures to be performed within a limited time and with limited assistance to minimize complications. Unlike patients scheduled for surgery who are fasting, patients under resuscitation are at high risk for aspiration of gastric contents. (4, 5) Moreover, a rapid increase in intrathoracic pressure with continuous CPR and retention of air in the stomach due to ventilation increase the risk of vomiting. (6) When vomiting and regurgitation occur, gastric contents can enter the trachea (see video, Additional File 1). (7) This is more likely to occur in the supine position, and aspiration of gastric contents cannot be completely prevented, even with intubation. This is an important cause of ventilator-associated pneumonia (VAP) in mechanically ventilated patients. (8) Ventilator-associated pneumonia is associated with prolonged duration of mechanical ventilation and ICU stay. The estimated mortality rate of VAP is around 10%, and is higher in critically ill patients, including those who undergo resuscitation. (9) Nasogastric tube insertion remains the easiest and best technique for accessing the gastrointestinal tract. (10) The 16-Fr Salem Sump™ tube (COVIDIEN, USA), which is relatively stiff, is widely used for gastrointestinal decompression as it is easy to insert blindly. There have been reports of inadvertent insertion of the NG tube into the lung (see figure, Additional File 2a, b), even in intubated patients, (11) and some cases of mucosal injury of the laryngopharynx, oesophagus, and stomach caused by NG tubes. In patients with bleeding diathesis, minimal trauma to the laryngopharynx resulting from NG tube insertion may cause severe bleeding (see figure, Additional File 2c).

Recently, the number of older patients undergoing anticoagulation and antiplatelet therapy for atrial fibrillation, pulmonary embolism, stroke, and acute coronary syndrome (ACS) has been increasing owing to the aging of the population. (12) Furthermore, the anticoagulation or antiplatelet therapy often prescribed in patients with cardiac/pulmonary ECMO, thrombosis, and ACS after resuscitation can increase the risk of severe bleeding.

A video laryngoscope (VLS), which contains a miniature video camera, enables the operator to visualize the glottis indirectly. (13) The technology was introduced in the 2000s. Video laryngoscopy improves Cormack–Lehane grade and achieves the same or a higher intubation success rate in less time compared to direct laryngoscopy. (14, 15) A VLS enables visualization of the glottis, pharynx, and oesophageal entrance, and there have been several reports that NG tube (16–18) or transoesophageal echocardiography (19) probe placement under the guidance of a VLS is useful in cases where the insertion is difficult (see video, Additional File 3). In a randomized, prospective clinical trial conducted by Okabe et al., (18) VLS-assisted NG tube insertion was easy, with a success rate of 100%. All previous studies were conducted among patients under general anaesthesia in the operating room. The setting is different for resuscitation in the ED, where time and the number of personnel available for assistance are limited, compared to an operating room. Nasogastric tube insertion remains a blind technique, and the method of minimizing mucosal injury during resuscitation is not well understood. In the present study, we first investigated the occurrence of laryngopharyngeal mucosal injury with blind NG tube insertion during resuscitation and considered practical blind NG tube insertion to minimize mucosal injury. We also analysed cases of difficult NG tube insertion in which the NG tube could not be inserted blindly even after 120 s, and assessed the usefulness of VLS-assisted NG tube insertion during resuscitation.

Materials And Methods

Study protocol

The study was conducted from April 2016 to March 2019 and included patients with cardiopulmonary arrest on arrival (CPOA) who were referred to Showa University Fujigaoka Hospital (Fig. 1). Patients < 20 years and > 95 years of age or patients who were issued with a “Do Not Attempt Resuscitation” order were excluded from this study(exclusion criterion 1). Five well-trained senior emergency physicians with more than 10 years of experience performed careful intubation of patients using a direct laryngoscope or VLS (C-MAC® system, KARL STORZ, Germany). Subsequently, an NG tube with a 16-French catheter scale (Salem Sump™ tube, COVIDIEN, USA) was gently inserted to decompress the air and stomach contents. Nasogastric tubes were not inserted in patients in whom mucosal assessment could not be performed due to bleeding or the presence of foreign bodies and in patients with oesophageal varices or carcinoma (exclusion criterion 2). In patients in whom the NG tube could be inserted within 120 s (Blind group, Blind), the condition of laryngopharyngeal (retropharyngeal wall [RPW], pharynx [Px]/vocal cords [VC], and epiglottis [Eg]/vallecula [VL]) mucosa was recorded using the VLS. Video laryngoscope-assisted NG tube insertion was performed in patients in whom the NG tube could not be inserted even after 120 s (Difficult group, Dif). After the insertion, the condition of laryngopharyngeal mucosa was recorded using the same method as for the Blind group. One hundred and fifty-nine patients with CPOA were referred to our ED. Of these, 67 patients were excluded from this study based on criterion 1, and eight patients were excluded based on criterion 2. Finally, 84 patients were included in this study. Patient background and success rates were evaluated. The time taken for NG tube insertion, the number of insertions performed, and injury scores were compared between the Blind and Dif groups. Further, correlations between injury score, age, insertion time, and the number of insertions were examined. Subsequently, the regression line was obtained using a single regression analysis, and we examined the practical blind NG tube insertion technique performed during resuscitation at the ED.

Definitions of nasogastric tube insertion time and the number of nasogastric tube insertions

NG tube insertion time was defined as the time required for the emergency physician to insert an NG tube, confirm the gastric contents or auscultate over the epigastrium during air injection, and confirm that the tube was properly inserted. Finally, proper placement of the NG tube was confirmed by obtaining X-ray images and consulting with several physicians. The number of NG tube insertions was defined as the number of times the physician pulled back the NG tube after feeling resistance during insertion.

Evaluation of laryngopharyngeal mucosal injury after nasogastric tube insertion

Laryngopharyngeal mucosal injury after NG tube insertion was evaluated using injury scores (Fig. 2a; 0: no injury, 1: erythema, 2: hematoma, 3: more than 10 spots of erythema and hematoma, and 4:

laceration). (20) The three parts of the laryngopharynx (RPW, Px/VC, and Eg/VL) were evaluated separately (Fig. 2b). The highest score of each region was defined as the injury score for that region. The sum of the injury scores from the three regions was defined as the score for the patient. Two investigators (K.S. and M.N.) who were blinded to the experimental groups performed the scoring independently while watching the videos, and the average values of the scores were calculated.

Analysis of causes of failure in the Difficult group

We also analysed the causes of failure of NG tube insertion in patients in the Dif group. In these patients, VLS-assisted NG tube insertion was performed using the recorded images.

Statistical analysis

All statistical analyses were performed using JMP Pro version 16 (SAS, USA). Data are reported as the mean ± standard error of the mean (SEM). The Student's t-test was used to determine the significance of differences between the two groups. One-way analysis of variance and the Tukey–Kramer tests were used for multiple comparisons. All statistical tests were two-tailed, and a p-value < 0.05 was considered statistically significant. Pearson's correlation coefficient values were used for correlation analyses. Subsequently, a single regression analysis was performed, and a regression line was obtained.

Results

Patient characteristics

The Blind and Dif groups included 67 and 17 patients, respectively (see table, Additional file 4). The average age of patients in the Blind and Dif groups were 71.1 ± 2.2 and 75.3 ± 2.8 years, respectively. The blind group included 35 men and 32 women, and the Dif group included 13 men and four women. The success rates were 98.5% in the Blind group and 76.5% in the Dif group In the Blind group, the NG tube was inadvertently placed in the trachea of one patient. The Dif group had four cases in which NG tube insertion was not performed due to resistance felt in the middle of the oesophagus during insertion. In the Blind group, the time taken for NG tube insertion was 48.8 ± 4.0 s. On the other hand, in the Dif group, the insertion time was 54.8 ± 3.0 s after switching to VLS-assisted insertion. There was no significant difference in the insertion time between the Blind and Dif groups. The number of NG tube insertions was significantly increased in the Dif group compared with the Blind group (Blind, 2.1 ± 0.2; Dif, 8.1 ± 0.8; t-test, $p < 0.05$).

Blind nasogastric tube insertion continued for more than 120 s significantly increased the injury score, especially for the retropharyngeal wall

In both groups, laryngopharyngeal mucosal injury with NG tube insertion was most severe in the RPW, which had a significantly high injury score compared with that of Eg/VL (Blind: RPW, 0.55 ± 0.13; Eg/VL, 0.18 ± 0.03; t-test, $p < 0.05$ vs. Dif: RPW, 2.67 ± 0.29; Eg/VL, 1.60 ± 0.32; t-test, $p < 0.05$; Fig. 3a, b). Moreover, the total injury score was significantly lower in the Blind group compared to the Dif group (Dif, 6.40 ± 0.64; Blind, 1.04 ± 0.21; t-test, $p < 0.05$; Fig. 3c). A region-specific examination also revealed that the injury score was significantly lower in the Blind group compared to the Dif group (RPW: Blind, 0.55 ± 0.13; Dif, 2.67 ± 0.29; t-test, $p < 0.05$ vs. Px/VC: Blind, 0.31 ± 0.07; Dif, 2.13 ± 0.32; t-test, $p < 0.05$ vs. Eg/VL: Blind, 0.18 ± 0.07; Dif, 1.60 ± 0.32; t-test, $p < 0.05$; (see figure, Additional File 5 a–c).

Correlations among the number of nasogastric tube insertions, insertion time, and injury scores

There were strong positive correlations between the number of insertions and injury score ($r = 0.76$), insertion time and injury score ($r = 0.79$), and the number of insertions and insertion time ($r = 0.76$) (Fig. 4a). We performed a single regression analysis to elucidate the relationship between the number of insertions and injury score and between insertion time and injury score. In this analysis, the regression lines were useful in predicting the injury score ($p < 0.05$). These regression lines suggested that the predicted injury score was low (predicted damage score less than 1–2) in cases where the NG tube could be inserted blindly within 1 min or after two to three attempts (Fig. 4b, c).

Video laryngoscope-assisted nasogastric tube insertion during resuscitation was safe and effective, particularly in the Difficult group

In 10 patients, the NG tube was smoothly advanced with the assistance of a VLS, although it could not be inserted blindly. In three patients, the NG tube advanced towards the trachea (see video, Additional File 6); therefore, we twisted the tube or externally compressed the larynx and to lead the tip of the NG tube to the oesophageal entrance. Moreover, in four patients, the tip of the NG tube could be advanced towards the oesophageal entrance but could not be passed into the oesophagus (see video, Additional File 7). Therefore, we adjusted the angle of insertion into the oesophageal entrance and passed the tube into the oesophagus. In all 17 patients, the NG tube was advanced through the oesophageal entrance into the oesophagus with the assistance of a VLS. However, the procedure was discontinued in four patients due to resistance felt during the advancement of the tube (see video, Additional File 8). During VLS-assisted insertion of the NG tube, we noticed that a sharp corner was created whenever the NG tube was bent due to resistance. These sharp corners damaged the mucous membranes in addition to the injury caused by the tip of the NG tube (see video, Additional File 9a; see figure, Additional File 9b).

Discussion

Most NG tubes are inserted blindly with the patient in a seated position at the bedside. In awake patients, the procedure is easy, as patients can cooperate by swallowing. On the contrary, in intubated patients, NG tube insertion can be difficult. (21) Ozer and Benumof (20) have reported that first-attempt failure rates for blind insertion of an NG tube in an intubated patient can be as high as 50%. In the present study, in 17 of 84 (20%) patients, NG tubes could not be inserted blindly, even after more than 120 s. In contrast, in 67 of 84 (80%) patients, it could be inserted blindly and smoothly, and the time required for insertion was only 48.8 ± 4.0 s. The success rate in the Blind group was as high as 98.5%, although the patients were intubated. Our results indicated that blind NG tube insertion during resuscitation was smooth and quick in most patients.

Several methods have been proposed for insertion of NG tubes in patients who are intubated. (22) Recently, several studies have reported that VLS-assisted NG tube insertion is effective in patients in whom blind NG tube insertion is difficult. (14, 15, 18) The reported reasons for this are as follows: first, an NG tube can be inserted by observing it on the monitor, and second, the larynx may be elevated using the laryngoscope, which opens the oesophageal entrance, as the oesophageal entrance tends to be narrow due to the weight of the larynx in the supine position. (18) In the present study, the time required for VLS-assisted insertion was 54.8 ± 3.0 s. A detailed analysis of the Dif group showed that the NG tube was smoothly placed in 10 patients. However, the NG tube advanced towards the trachea in three patients, probably due to anatomical reasons. In another four patients, the NG tube could be advanced towards the oesophageal entrance, but not inserted in the oesophagus, probably due to an inappropriate angle of entry. However, in all patients, with the assistance of a VLS, we could pass the tube through the oesophageal entrance. It was impossible to insert the NG tube blindly in seven patients. Furthermore, we noticed that the sharp corners created by the bending of the NG tube could cause severe mucosal injury. This could be prevented with VLS assistance. Our results indicated that VLS-assisted NG tube insertion during resuscitation is a safe and effective method, particularly in the Dif group. However, the cost of a VLS is between $1,800 and $7,600 and the disposable blades vary in cost from $20–30. (23) Thus, VLS-assisted NG tube insertion is expensive compared to blind insertion. Moreover, preparing the VLS takes time, although the insertion time itself was not significantly different from that required for blind NG tube insertion. Therefore, we first assessed laryngopharyngeal mucosal injury due to blind NG tube insertion during resuscitation at the ED. We then examined the blind NG tube insertion technique to minimize the laryngopharyngeal mucosal injury and considered VLS-assisted NG tube insertion for suitable patients.

Previous studies reported that the most common regions for mucosal injury during NG tube insertion are the arytenoid cartilage and piriform sinus. (20) Contrastingly, in the present study, in both the Blind and Dif groups, the most severe mucosal injuries occurred in the posterior wall of the pharynx (oropharynx) compared to other regions. Previous studies had included patients undergoing general anaesthesia in an operating room. (20, 21) In contrast, the present study included patients with CPOA who were undergoing continuous CPR. Therefore, the patients' necks might have been in a hyperextended position, and passive neck movements during CPR might have had a role in RPW mucosal injury. Moreover, the present study included the number of NG tube insertions, in addition to NG tube insertion time, compared with the previous studies. Both insertion time and number of insertions showed strong positive correlations with

laryngopharyngeal mucosal damage, with longer insertion times and an increased number of insertions resulting in more severe mucosal damage. The results suggest that blind NG tube insertion performed within 1 min or a maximum of two or three attempts is useful during resuscitation at the ED.

Our study has some limitations. Our study was a single centre study and results in the difficult insertion group came from 17 patients. In addition, as most of the included patients died due to cardiopulmonary arrest, it was impossible to examine whether laryngopharyngeal injury caused haemorrhage after anticoagulation and antiplatelet therapy. Lastly, as the patients had CPOA, we could not study the effects of muscle relaxation or sedative agents. Further research is needed to clarify the optimal technique for NG tube insertion at the ED.

Conclusions

The present study demonstrated that as the blind NG tube insertion time and the number of insertions increased, the severity of laryngopharyngeal mucosal injury increased. Blind NG tube insertion performed within 1 min or for a maximum of two or three attempts minimized laryngopharyngeal mucosal injury. Video laryngoscope-assisted NG tube insertion should be considered if these limits are exceeded. We believe that our findings are clinically applicable in patients undergoing CPR and other intubated patients in the ED.

Abbreviations

NG: Nasogastric, CPR: Cardiopulmonary resuscitation, ECMO: Extracorporeal membrane oxygenation, ED: Emergency department, VAP: Ventilator-associated pneumonia, ACS: Acute coronary syndrome, VLS: Video laryngoscope, CPOA: Cardiopulmonary arrest on arrival, RPW: Retropharyngeal wall, Px: Pharynx, VC: Vocal cords, Eg: Epiglottis, VL: Vallecula, Dif: Difficult, SEM: Standard error of the mean

Declarations

Ethics approval and consent to participate:

All human research protocols were approved and supervised by the Clinical Trial Review Board of Showa University (#2016128) and adhered to the CIOMS Ethical Guidelines for Biomedical Research. Written informed consent was obtained from all participants and/or their legal guardians. The study has been performed in accordance with the tenets of the Declaration of Helsinki.

Consent for publication:

Informed consent for publication was obtained from all participants and/or their legal guardians.

Availability of data and materials:

Not applicable

Competing interests:

Authors declare no conflicts of interest.

Funding:

This work was supported by JSPS KAKENHI grants (grant numbers: 19K09442 [K.M.], 19K22779 [K.D.], and 21H03036 [K.D.], 22H03177[K.M.]). There are no conflicts of interest to declare.

Authors' contributions:

KM and HT were responsible for Conceptualization, Project administration, Investigation and contributed equally to this study. SK and AM were responsible for Investigation and Data curation. KS and MN performed Validation and NH and TS were responsible for the Formal analysis and Methodology. MY and JS were responsible for review & editing the article. MH and KD supervised this research.

Acknowledgements:

We would like to thank Editage (www.editage.com) for English language editing.

References

1. Kelly G, Lee P. Nasendoscopically-assisted placement of a nasogastric feeding tube. J Laryngol Otol. 1999;113:839–840.
2. Koenig MA. Brain resuscitation and prognosis after cardiac arrest. Crit Care Clin. 2014;30:765–783.
3. Welbourn C, Efstathiou N. How does the length of cardiopulmonary resuscitation affect brain damage in patients surviving cardiac arrest? A systematic review. Scand J Trauma Resusc Emerg Med. 2018;26:77.
4. Sellick BA. Cricoid pressure to control regurgitation of stomach contents during induction of anaesthesia. Lancet. 1961;2:404–406.
5. Green SM, Krauss B. Pulmonary aspiration risk during emergency department procedural sedation–an examination of the role of fasting and sedation depth. Acad Emerg Med. 2002;9:35–42.
6. Orlowski JP, Szpilman D. Drowning. Rescue, resuscitation, and reanimation. Pediatr Clin North Am. 2001;48:627–646.
7. Takenaka I, Aoyama K, Iwagaki T. Combining head-neck position and head-down tilt to prevent pulmonary aspiration of gastric contents during induction of anaesthesia: a volunteer and manikin study. Eur J Anaesthesiol. 2012;29:380–385.
8. Chastre J, Fagon JY. Ventilator-associated pneumonia. Am J Respir Crit Care Med. 2002;165:867–903.
9. Papazian L, Klompas M, Luyt CE. Ventilator-associated pneumonia in adults: a narrative review. Intensive Care Med. 2020;46:888–906.

10. Sanaie S, Mahmoodpoor A, Najafi M. Nasogastric tube insertion in anaesthetized patients: a comprehensive review. Anaesthesiol Intensive Ther 2017;49:57–65.
11. Wang PC, Tseng GY, Yang HB, Chou KC, Chen CH. Inadvertent tracheobronchial placement of feeding tube in a mechanically ventilated patient. J Chin Med Assoc. 2008;71:365–367.
12. Bauersachs RM, Herold J. Oral anticoagulation in the elderly and frail. Hamostaseologie. 2020;40:74–83.
13. Niforopoulou P, Pantazopoulos I, Demestiha T, Koudouna E, Xanthos T. Video-laryngoscopes in the adult airway management: a topical review of the literature. Acta Anaesthesiol Scand. 2010;54:1050–1061.
14. Griesdale DE, Liu D, McKinney J, Choi PT. Glidescope® video-laryngoscopy versus direct laryngoscopy for endotracheal intubation: a systematic review and meta-analysis. Can J Anaesth. 2012;59:41–52.
15. Cooper RM, Pacey JA, Bishop MJ, McCluskey SA. Early clinical experience with a new videolaryngoscope (GlideScope) in 728 patients. Can J Anaesth. 2005;52:191–198.
16. Kinoshita H, Minonishi T, Hatano Y. Nasogastric tube insertion assisted with the AirwayScope in a patient with cervical spine instability. Can J Anaesth. 2009;56:543–544.
17. Hunter CW, Cohen S. A new use for the GlideScope. Anesth Analg. 2006;103:509.
18. Okabe T, Goto G, Hori Y, Sakamoto A. Gastric tube insertion under direct vision using the King Vision™ video laryngoscope: a randomized, prospective, clinical trial. BMC Anesthesiol. 2014;14:82.
19. St Laurent C, Wong D, Kudrick N, Allred D The glide scope: also helpful with difficult transesophageal echocardiography probe placement. Anesth Analg. 2007;104:1004–1005.
20. Ozer S, Benumof JL. Oro- and nasogastric tube passage in intubated patients: fiberoptic description of where they go at the laryngeal level and how to make them enter the esophagus. Anesthesiology. 1999;91:137–143.
21. Furutani K, Watanabe T, Matsuda K, Kamiya Y, Baba H. SUZYTM forceps facilitate nasogastric tube insertion under McGRATHTM MAC videolaryngoscopic guidance: A randomized, controlled trial. Med (Baltim) 2020;99:e22545.
22. Ching YH, Socias SM, Ciesla DJ, Karlnoski RA, Camporesi EM, Mangar D. The difficult intraoperative nasogastric tube intubation: a review of the literature and a novel approach. SAGE Open Med. 2014;2:2050312114524390.
23. Pappu A, Sharma B, Jain R, Dua N, Sood J. A randomised comparative study of "videoendoscope" with the Truview EVO2, C-MAC D blade videolaryngoscope and the Macintosh laryngoscope. Indian J Anaesth. 2020;64(suppl 3):S186–S192.

Figures

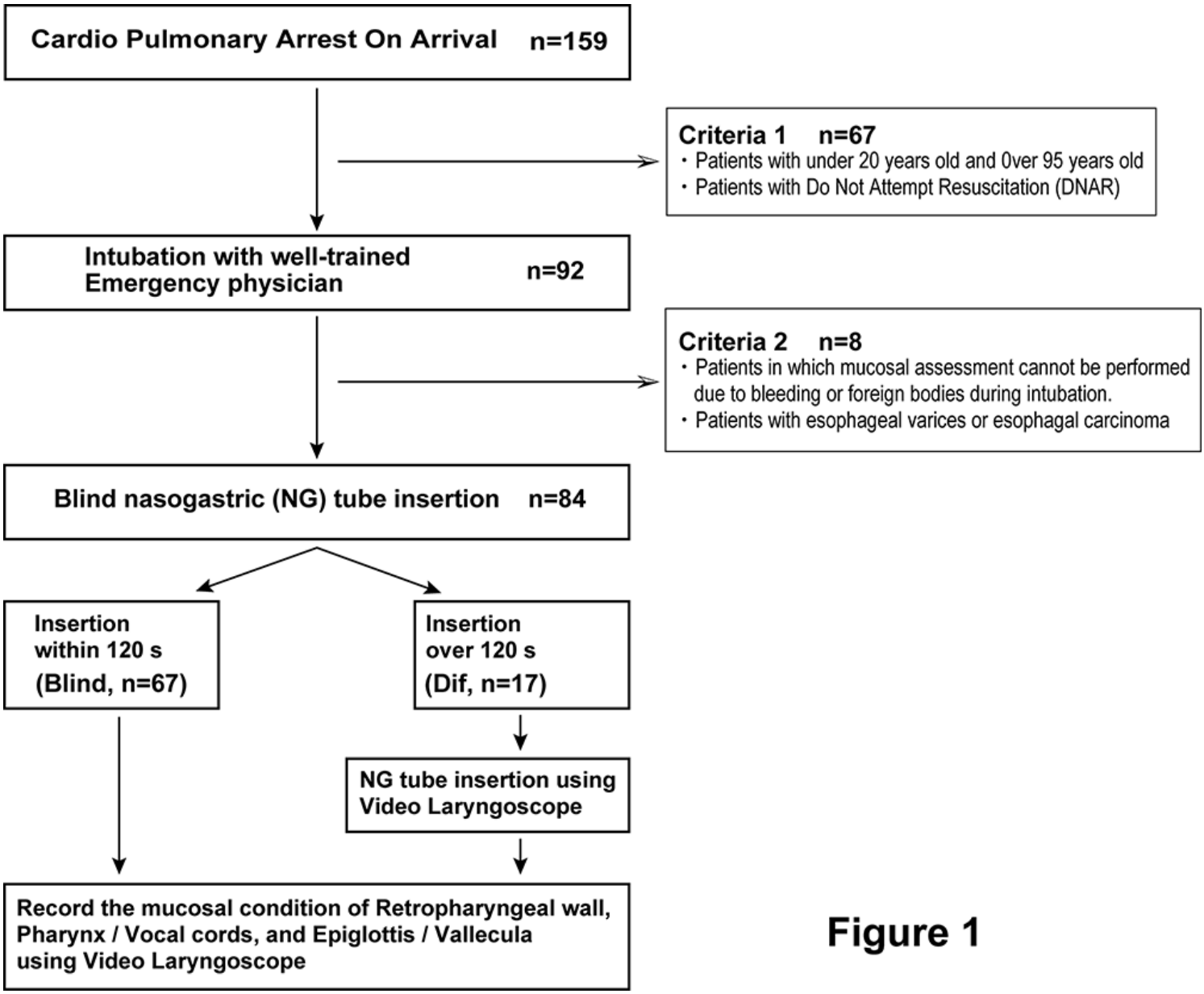

Figure 1

Study protocol

A total of 84 patients (the Blind group: n = 67; the Difficult [Dif] group: n = 17) were included in the study.

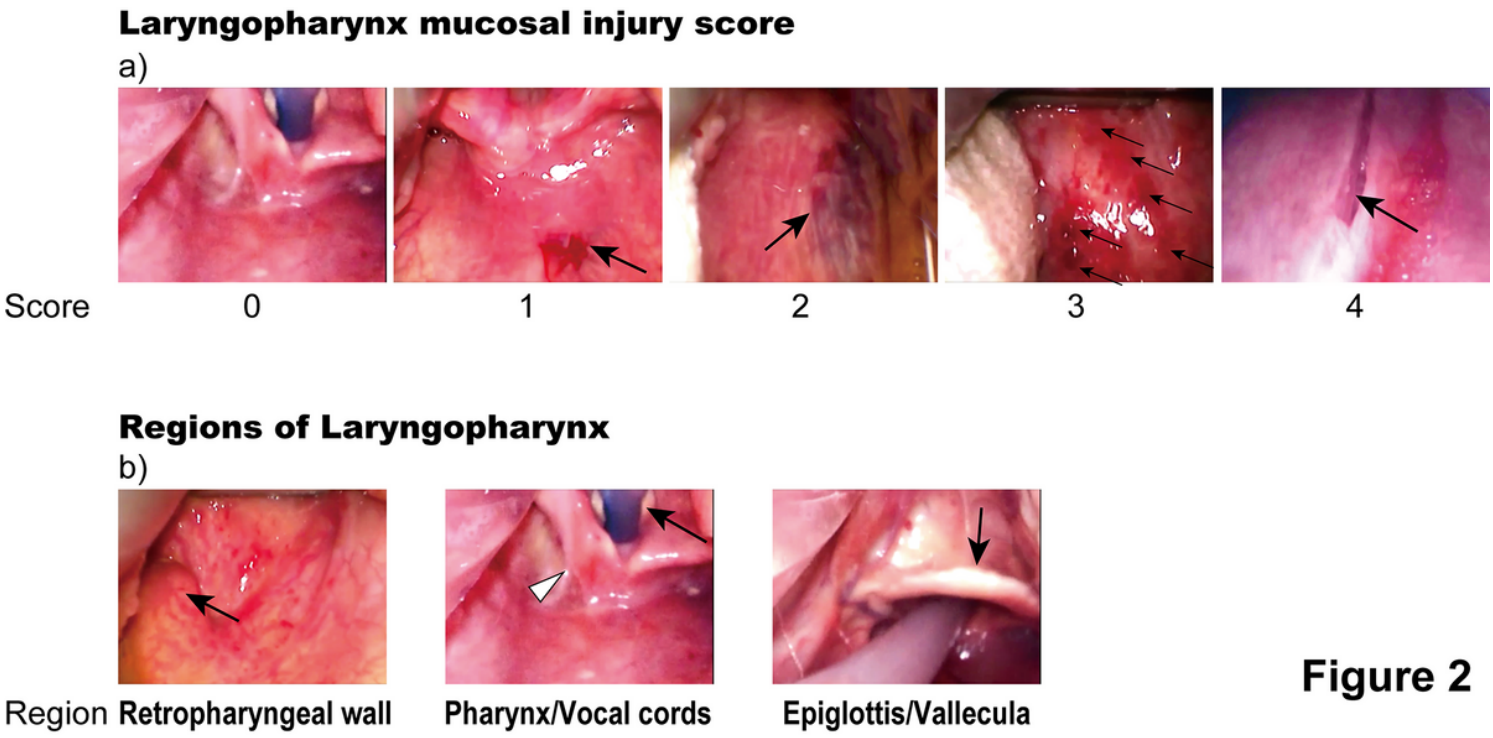

Figure 2

Evaluation of laryngopharyngeal mucosal injury after nasogastric tube insertion

(a) Laryngopharyngeal mucosal injury was evaluated using injury scores: 0, no injury; 1, erythema (arrow); 2, hematoma (arrow); 3, more than 10 spots of erythema and hematoma (arrows); 4, laceration (arrow).

(b) The three regions of the laryngopharynx (retropharyngeal wall [arrow indicates the uvula], pharynx [arrow head indicates the hypopharynx/vocal cord], and epiglottis/vallecula [arrow indicates the epiglottis]) were evaluated separately. The highest score for each region was defined as the injury score for that region. The sum of the injury scores of the three regions was used as the score for the patient.

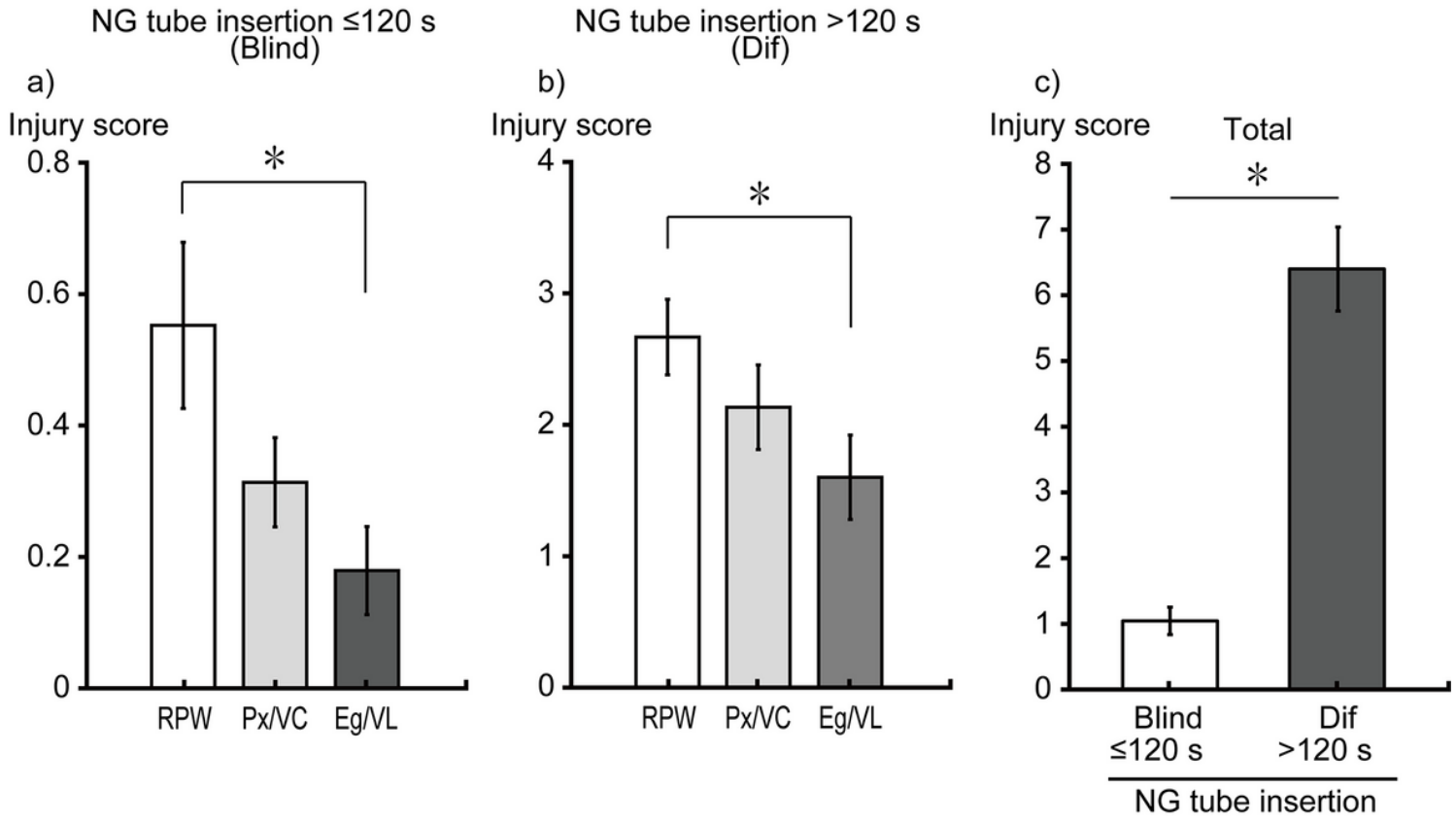

Figure 3

Figure 3

Nasogastric tube insertion continued for more than 120 s significantly increased the injury score, especially for the retropharyngeal wall

(a), (b) In both Blind and Difficult (Dif) groups, the laryngopharyngeal mucosal injury was most severe in the retropharyngeal wall. (c)The injury scores of the Dif group were significantly higher compared with the Blind group.

NG: nasogastric, RPW: retropharyngeal wall, Px: pharynx, VC: vocal cord, Eg: epiglottis, VL: vallecula.

*, $p < 0.05$ (Student's t-test and Tukey–Kramer tests).

a)

	Correlation coefficient (r)	n=84
Injury score, Age	0.11	
Injury score, Insertion time	0.79	*
Injury score, Number of insertions	0.76	*
Age, Insertion time	0.13	
Age, Number of insertions	0.18	
Insertion time, Number of insertions	0.76	*

b)

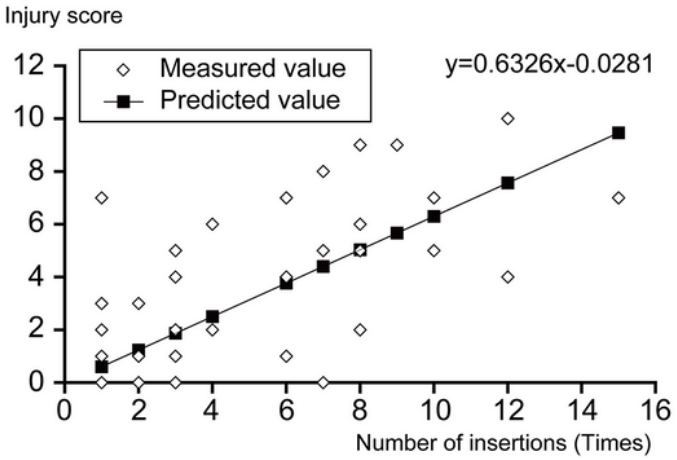

Predicted Injury score	Number of insertions
0	0.04
1	1.63
2	3.20
3	4.79
4	6.37
5	7.95
6	9.53

c)

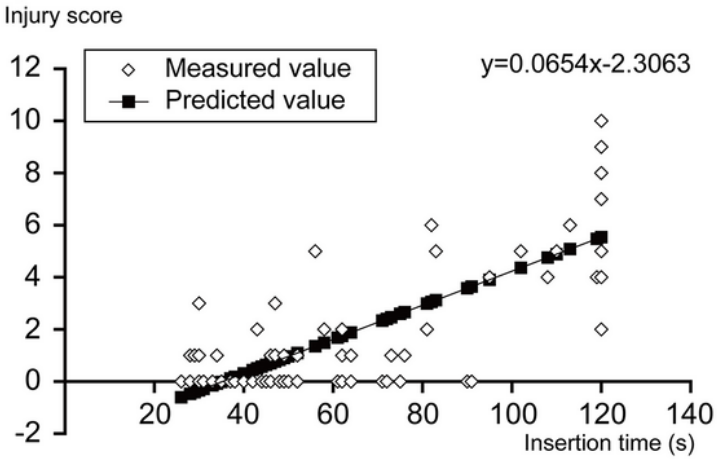

Predicted Injury score	Insertion time
0	35.3
1	50.6
2	65.8
3	81.1
4	96.4
5	111.2
6	127.0

Figure 4

Figure 4

The number of nasogastric tube insertions and insertion time both showed strong positive correlations with injury score, and blind NG tube insertion performed within 1 min or for a maximum of two or three times was associated with minimal mucosal injury

(a) Correlations between the number of insertions, injury score, insertion time, and age. Strong positive correlations were observed between the number of insertions and injury score; insertion time and injury score; and the number of insertions and insertion time. (b), (c) The regression lines of injury score and the number of insertions and injury score and insertion time, respectively. The tables below the graphs show the relationship between the predicted injury scores and the number of insertions and insertion time. It is suggested that mucosal damage is minimized (predicted damage score less than 1–2) in cases where the nasogastric tube could be inserted within 1 min or after two to three attempts.

*, $p < 0.05$, strong positive correlation (Pearson's correlation coefficient values).

Supplementary Files

This is a list of supplementary files associated with this preprint. Click to download.

- AdditionalFile1mpeg420220314.mp4
- AdditionalFile220220427.tif
- AdditionalFile3mpeg4.mp4
- AdditionalFile420220427.pdf
- AdditionalFile520220427.pdf
- AdditionalFile620220424.mp4
- AdditionalFile720220427.mp4
- AdditionalFile820220427.mp4
- AdditionalFile9a20220427.mp4
- AdditionalFile9b20220427.tif