Simultaneous Bilateral Ocular Trauma: Clinical Presentation, Epidemiology and Patterns of Injury

Rajendra prakash Maurya (mauryarp_bhu@yahoo.com)
Banaras Hindu University Institute of Medical Sciences https://orcid.org/0000-0001-9343-6003

Rajendra Prakash Maurya
Banaras Hindu University Institute of Medical Sciences

Virendra Pratap Singh
Banaras Hindu University Institute of Medical Sciences

Syeed Mehbub Ul Kadir
Bangabandhu Sheikh Mujib Medical University

Jayant Kumar Das
Sri Sankaradeva Nethralaya

Sanjay Kumar Bosak
Banaras Hindu University Institute of Medical Sciences

Manish Kumar Prajapat
Banaras Hindu University Institute of Medical Sciences

Meghna Roy
Banaras Hindu University Institute of Medical Sciences

Brijesh Kumar Kushwaha
Banaras Hindu University Institute of Medical Sciences

Anil Kumar
Banaras Hindu University Institute of Medical Sciences

Abdullah Al-Mujaini
Sultan Qaboos University Hospital

Research Article

Keywords: Assault, Bilateral ocular trauma, Injury, Polytrauma, Road traffic injury

Posted Date: March 11th, 2021

DOI: https://doi.org/10.21203/rs.3.rs-160490/v1

Abstract

Purpose

This study aimed to determine the frequency, sociodemographic profile, clinical presentation, patterns of injury, treatment and outcomes of cases of simultaneous bilateral ocular trauma.

Methods

This retrospective study was conducted from May 2015 to April 2019. The medical records of patients presenting with bilateral ocular injuries were reviewed.

Results

Among the 402 patients presenting with ocular injuries, 34 (8.46%) had simultaneous bilateral ocular trauma. The majority were male (70.59%) and the mean age was 26.82 ± 15.86 years (range: 2–70 years).Most injuries occurred away from home (64.71%), mainly in roads (32.36%) or playgrounds (14.71%), and the vast majority (91.18%) were non-occupational in nature. Mechanical injuries were most frequent (47.05%), followed by cracker (17.65%), chemical (17.65%) and thermal (11.76%) injuries. Most cases occurred due to assault (26.47%), road traffic injury(20.59%) or sports/recreational activities (17.65%). The majority of victims were not using protective devices at the time of injury (82.35%) and had associated polytrauma (58.82%).Closed and open globe injuries accounted for 29.41% and 14.71% of cases, respectively, mostly involving zones I (55.00%) and II (40.00%). Orbital fractures occurred in 27.94% of eyes. Category I and II ocular trauma scores were noted in 5.88% and 7.35% of eyes, respectively. Overall, 13.24% were blinded as a result of the trauma.

Conclusion

Simultaneous bilateral ocular trauma is rare and occurs mostly following traffic accidents, assault or recreational activities. In particular, younger males are more prone to bilateral ocular injuries, the majority of which are severe and associated with poor outcomes.

Summary

What is already known on this subject ?

Although simultaneous involvement of both eyes in ocular trauma is rare, but if present, can be very severe in nature and lead to total blindness. Unfortunately, very little information is reported and available regarding the epidemiology, injury patterns and risk factors involved in simultaneous bilateral ocular trauma. Only two studies on this field have been reported till date. The major risk factors which have been

reported for getting simultaneous bilateral ocular injuries are road traffic accidents, landmine and coalmine blast [Jovanovic et al. and Babar et al.]

What does this study add?

We found that major causes of simultaneous bilateral ocular trauma were assaults (including physical assault, acid attacks and gunshots injury) and sports or recreational activities (including cracker burn). Most of the victims had polytrauma and a multidisciplinary approach was required for management. Based on our findings, it is recommended to use ocular protective measures during potentially dangerous activities, needs of modification of violent behavior and to resolve the conflicts as early as possible.

Introduction

Ocular trauma is the leading cause of avoidable acquired blindness worldwide, with an estimated 55 million ocular injuries occurring annually, of which 19 million result in severe visual loss and blindness.[1] Worldwide, approximately 1.6 million people suffer from blindness arising from ocular injury and 2.3 million have bilateral visual impairment due to trauma.[2] While ocular trauma is a significant cause of monocular blindness, the simultaneous involvement of both eyes is rare. Bilateral ocular trauma is often associated with serious physical disability, disfigurement and visual loss, with the reported prevalence of bilateral blindness due to trauma ranging from 3.2–5.5%.[3]

Road traffic injuries (RTIs), physical assault and blast injuries are frequent causes of severe bilateral ocular injuries.[4–6] Ocular trauma can have a significant psychological and socioeconomic impact on the affected individual, their family and society at large.[7] Moreover, the treatment of severe bilateral ocular trauma is often difficult and challenging, thereby requiring strategic management. As a result, it is important to identify the epidemiology and risk factors of this type of trauma. The objective of this study was therefore to determine the frequency, sociodemographic profile, clinical presentation, patterns of injury, treatment and outcome of cases of simultaneous bilateral ocular trauma.

Methods

This retrospective study involved all patients with simultaneous bilateral ocular trauma who were diagnosed and managed between May 2015andApril 2019at the Sir Sunderlal Hospital, Institute of Medical Sciences, Banaras Hindu University, Varanasi, India. The study was approved by the institutional ethical committee of Banaras Hindu University. All study procedures adhered to the recommendations of the revised Declaration of Helsinki. Patient privacy and confidentiality was maintained using a data abstraction form.

A review of the patients' hospital records and investigation reports was conducted to collect information regarding the patients' demographic profile (i.e. age, gender, place of residence and socioeconomic status), injury profile (i.e. time, place, session, circumstances and cause of injury and type of traumatic agent), clinical profile (i.e. type, location, zone, severity and depth of injury, initial visual acuity, ocular

trauma score [OTS] and associated injuries) and outcome (i.e. management modality, time to presentation, final visual acuity and determinants for impaired vision or blindness).

Collected data were analysed using the Statistical Package for the Social Sciences (SPSS) software, version 15 (IBM Corp., Armonk, NY, USA). A student's two-tailed t-test was used to compare quantitative variables while a Chi-squared test was used to compare categorical variables. The level of statistical significance was set at $p < 0.05$.

Results

Demographic profile

A total of 402 ocular trauma cases presented during the study period, of which 34 (8.46%) constituted simultaneous bilateral ocular trauma. Of these, 24 (70.59%) were male and 10 (29.41%) were female, with an overall male-to-female ratio of2.4:1. The mean age was 26.82 ± 15.86 years (95% confidence interval: 21.29–32.36 years; range: 2–70 years). The most frequently affected age group was 16–25 years (35.29%), followed by 6–15 years (23.53%) and 26–35 years (20.59%). The least vulnerable age group was 0–5 years (2.94%). Most patients resided in rural areas (55.88%),were illiterate (58.82%) and worked outdoors(58.82%). Just under a quarter (23.53%) of the subjects were alcoholics and 17.65% were smokers. Table 1 summarises the sociodemographic characteristics of the subjects.

Table 1
Demographic profile

Characteristic	No. of cases (N = 34)	%
Age (years)		
0–5	1	2.94
6–15	8	23.53
16–25	12	35.29
26–35	7	20.59
36–45	3	8.82
> 45	3	8.82
Gender		
Male	24	70.59
Female	10	29.41
Residence		
Rural	19	55.88
Semi-urban	10	29.41
Urban	5	14.71
Education level		
Illiterate	20	58.82
Primary school or lower	8	23.53
More than primary school	6	17.65
Place of work		
Outdoors	20	58.82
Indoors	14	41.18
Habit		
Smoker	6	17.65
Alcoholic	8	23.53
Neither	20	58.82

Injury profile

The majority of patients were injured in the afternoon (50.00%), followed by the morning (23.53%) and the evening (20.59%). The remaining two cases (5.88%) were elderly patients who were injured after falling from the roof late at night. Most injuries occurred in summer (50.00%) or during the rainy season (35.29%), with few cases occurring in winter (14.71%). The most common place of injury was away from home (64.71%), including in roads (32.36%), in playgrounds/at school (14.71%) and in the workplace (11.76%). Non-occupational trauma was most common (91.18%), including assault-related trauma (26.47%), rail related injury or RTI (20.59%), sports or recreational activities (17.65%) and domestic accidents (14.71%).

Mechanical injuries accounted for 47.05% of cases. The remaining subjects had non-mechanical injuries, including cracker (17.65%), chemical (17.65%), thermal (11.76%) and radiation-induced (5.88%) injuries. In the majority of cases, the traumatic agent was solid in form (41.18%), followed by particulate matter (20.59%), fluid/gel (14.71%) and of indeterminate form (23.53%). The most common mode of injury was collision or impact (41.18%), followed by blasts or gunshots (20.59%), projectile objects (11.76%) and falling (11.76%). Three patients (8.82%) were injured due to animal bites. The majority of victims (82.35%) were not using protective devices at the time of injury and 38.24% had consumed alcohol. Table 2 shows the detailed injury profile of the sample.

Table 2
Injury profile

Characteristic	No. of cases (N = 34)	%
Time of injury		
Morning (6.00–11.59 hours)	8	23.53
Afternoon (12.00–17.59 hours)	17	50.00
Evening (18.00–23.59 hours)	7	20.59
Late night (00.00–5.59 hours)	2	5.88
Season of injury		
Summer	17	50.00
Rainy	12	35.29
Winter	5	14.71
Place of injury		
Home	12	35.29
Elsewhere	22	64.71
Circumstances of injury		
Occupational	3	8.82
Sports/recreational activity	6	17.65
Road/rail traffic accident	7	20.59
Assault	9	26.47
Domestic accident	5	14.71
Miscellaneous	4	11.76
Type of injury		
Mechanical	16	47.05
Thermal	4	11.76
Cracker	6	17.65
Radiation	2	5.88
Chemical	6	17.65
Acid	*3*	*8.83*

Characteristic	No. of cases (N = 34)	%
Alkali	*3*	*8.83*
Traumatic agent		
Fluid/gel	5	14.71
Particulate	7	20.59
Solid	14	41.18
Indeterminate	8	23.53
Mode of injury		
Fall	4	11.76
Collision/impact	14	41.18
Blast/gunshot	7	20.59
Projectile object	4	11.76
Animal bite	3	8.82
Miscellaneous	2	5.88
Use of protective devices during injury		
Yes	28	82.35
No	6	17.65
Alcohol consumption during injury		
Yes	13	38.24
No	21	61.76

Pattern of injury

Each eye was assessed separately to determine patterns of injury. Only 41.18% of eyes had isolated ocular trauma, with the remaining 58.82% having polytrauma arising from either RTIs (14.71%), assault (20.52%) or sports/recreational activities (8.82%). The most common type of ocular structure involved was the periocular tissues and eyelid (63.24%), followed by the globe (44.12%) and orbit (27.94%). In terms of periocular and lid injuries, 38.24% had lacerated wounds, 38.24% had thermal/chemical burns and 36.76% had contusions [Figure 1]. Single orbital fractures occurred in 19 eyes (27.94%), involving either the left (52.63%) or right (47.37%) eye, while 16.18% of eyes had multiple bony injuries. Three-

dimensional computed tomography showed 14 floor fractures, nine roof factures, seven medial wall fractures and six lateral wall fractures [Figure 2]. All eyes with RTIs had bony orbital fractures.

Closed globe injuries (CGIs) accounted for 29.41% of cases. Moreover, 10eyes (14.71%) had open globe injuries (OGIs), including seven (10.29%) with scleral/corneal ruptures and three (4.41%) with perforating/penetrating injuries. In terms of zone of injury, most OGI cases involved zone II (40.00%) while most CGI cases involved zones I (55.00%) or III (30.00%). The most common clinical finding was periocular or lid abrasions/lacerations (38.24%), periocular ecchymosis/oedema (36.76%) and subconjunctival haemorrhage (36.76%), followed by orbital fractures (27.94%), hyphaema (20.59%), iris injuries (20.59%), vitreous haemorrhage (14.71%) and corneal lacerations (14.71%). Lens injuries and retinal detachment occurred in 7.35% and 5.88% of cases, respectively.

In the majority of cases, OTS could not be determined (55.88%); however, the remaining cases, all of which had globe injuries, were classified as category I (5.88%), category II (7.35%), category III (10.29%), category IV (8.82%) or category V (11.76%). Overall, 35.29% of injured eyes involved less than three ocular structures, 29.41% involved three structures and 35.29% involved four or more structures; among the latter group, 20.59% were injured as a result of RTAs and 14.71% due to assault. The overall severity of the injury increased in tandem with the number of ocular structures affected. Table 3 summarises the injury patterns observed in the sample.

Table 3: Pattern of injury

Characteristic		No. of eyes (N = 68)	%
Type of trauma			
Isolated ocular trauma		28	41.18
Associated polytrauma		40	58.82
Ocular structure injured*			
Orbit		19	27.94
Periocular tissues and eyelid		43	63.24
Globe		30	44.12
Type of injury*			
Periocular and eyelid mechanical injury		30	44.12
Periocular and eyelid burn		26	38.24
Orbital fracture		19	27.94
Closed globe injury		20	29.41
Open globe injury		10	14.71
Non-mechanical globe injury		5	7.35
Clinical findings*			
Periocular contusion/ecchymosis		25	36.76
Periocular/lid abrasion/laceration		26	38.24
Orbital fracture		19	27.94
Subconjunctival haemorrhage		25	36.76
Corneal laceration		10	14.71
Hyphaema		14	20.59
Iris injury		14	20.59
Lens injury		5	7.35
Vitreous haemorrhage		10	14.71
Retinal detachment		4	5.88
Zone of injury			
Closed globe injury	I	11	16.18
	II	3	4.41
	III	6	8.82
Open globe injury	I	3	4.41
	II	4	5.88
	III	3	4.41
No. of ocular structures injured			
<3		24	35.29
3		20	29.41
≥4		24	35.29
Ocular trauma score			
Not applicable		38	55.88
Category I		4	5.88
Category II		5	7.35
Category III		7	10.29
Category IV		6	8.82
Category V		8	11.76

**Percentages do not add up to 100% as some eyes may have had multiple injuries.*

Table 4: Initial and final visual acuity

Acuity	Initial		Final		p value*
	No. of eyes (N = 68)	%	No. of eyes (N = 68)	%	
>6/12	22	32.35	38	55.88	0.001
6/18 to 6/60	18	26.47	17	25.00	
<6/60 to CF	18	26.47	3	4.41	
HM to PL	3	4.41	2	2.94	
No PL	5	7.35	4	5.88	
Could not be assessed	2	2.94	4	5.88	

CF = counting fingers; HM = hand motion; PL = perception of light.

**Correlation coefficient=0.724, R^2=52.4%,adjustedR^2=40.56%, two-tailed upper critical t-score= ±2.78 at 0.05 level of significance.*

Treatment and outcomes

Most patients (41.71%) presented 24–48 hours after injury, 29.41% within 24 hours and 14.71% only after several days. The majority were managed using both medical and surgical modalities; however, 35.29% of patients required several multidisciplinary surgeries. In terms of visual acuity, each eye was categorised as either having good vision (≥ 6/12), visual impairment (6/18 to 6/60) or blindness (< 6/60 to no perception of light). Initial best-corrected visual acuity (BCVA) was good in 32.35% of eyes and impaired in 26.47% of eyes, while 26 were blind (38.24%). Vision could not be assessed in two eyes (2.94%).

Determinants for impaired vision or blindness included globe rupture, zone III injuries, retinal detachment and multiple orbital fractures. Seven eyes with OGIs demonstrated low OTS values (i.e. categories I to II), whereas higher OTS values (i.e. categories III to V) were noted in 16 eyes with CGIs. Higher OTS values tended to indicate a better prognosis. After six months, final visual acuity was deemed good in 55.88%and impaired in 25.00% of eyes. Blindness was noted in 13.24% of eyes. However, vision could not be assessed in four cases (5.88%) due to a lack of follow-up. There was a statistically significant improvement in visual acuity at the end of the six-month follow-up period compared to initial assessments ($p < 0.001$).Table 4presents a comparison of initial and final visual acuity in the sample.

Discussion

Ocular trauma is an under-recognised and under-reported cause of vision loss; moreover, while bilateral ocular trauma is comparatively uncommon, it can lead to severe visual impairment and long-term disability. [2, 3, 7] Unfortunately, little information is currently available regarding the magnitude, epidemiology and injury patterns of this condition. To our best knowledge, this is the third study to report clinical and epidemiological data regarding cases of simultaneous bilateral ocular trauma. These findings provide insight into the epidemiology, clinical characteristics and outcomes of cases of simultaneous ocular injuries presenting to the largest tertiary referral hospital in Eastern Uttar Pradesh, India.

The incidence of bilateral ocular injuries depends on a wide variety of factors, including geographical location, climate, culture, social values, common occupations, rates of crime and violence and common types of trauma and traumatic agents. In our study, simultaneous bilateral injuries occurred in 8.46% of patients presenting with ocular trauma over a six-year period. Sabaci et al. reported bilateral involvement in 16 (7.55%) of 212 patients with weapon-related OGIs.[8] In a previous study carried out at the Sir Sunderlal Hospital, 22.9% of university students with ocular injuries were affected in both eyes, with ocular injuries most commonly attributed to assault, RTAs and recreational activities.[4] In contrast, other studies have reported lower rates of bilateral ocular injuries(0.69–3.0%).[5, 9, 10] In contrast, according to an interview-based survey in Nepal, the prevalence of trauma-related bilateral blindness was 20%.[7]

There was a male predominance in the current study, with the male-to-female ratio being 2.4:1. This finding is comparable to that reported in other studies [6, 10]. Moreover, young adults (i.e. 16–25 and 26–35 years old) and older children and adolescents (i.e. 6–15 years old) represented the most vulnerable age groups. In general, young men tend to spend more time outdoors, are often employed in occupations involving manual labour and are more likely to be involved in violence or risky behaviours, factors which place them at greater risk of injury and trauma.[11, 12] In this study, the majority of patients resided in rural areas, demonstrated poor literacy and were of low socioeconomic status; furthermore, such patients were more likely to have poor outcomes due to a lack of eye protection and delays in seeking medical care. These individuals should therefore be considered a high-risk group in terms of prognosis.

The majority of bilateral ocular injuries in our study occurred during summer and the rainy season; similar results have been reported by other researchers.[13, 14] In contrast, Canavan et al. reported that ocular injuries in Ireland usually transpired during the winter season as a result of the increased prevalence of dangerous sporting activities and domestic accidents.[15] Several reasons are proposed for the high incidence of injury in summer and low incidence in the winter season noted in the present study. Many college and university students engage in outdoor games and activities during their summer holidays, potentially making them more injury prone. Secondly, summer is culturally considered marriage season in India and people are therefore often exposed to fireworks and travel-related injuries. Finally, the cold, foggy climate and the occurrence of annual college examinations in the winter season would limit involvement in outdoor activities.

In this study, most patients were injured in the afternoon between 12:00 and17.59 hours (50.00%); this is to be expected given that this interval represents the peak time for outdoor activities. In addition, the most common place of injury was away from home (64.71%), including in the street, at school/college and in the playground. This is consistent with results reported in other studies. [5, 8, 9, 16] In comparison, the commonest place for monocular injuries is reportedly at home, particularly among children and women. [17–21]. However, Tok et al. reported that paediatric ocular injuries were less prevalent at home compared to elsewhere [22].

In our study, mechanical injuries (47.05%) accounted for the majority of simultaneous bilateral ocular injuries, with most cases being non-occupational in nature (91.18%). The most common cause of injury

was assault (26.47%), including physical assault, acid attacks and gunshots. Similar incidence rates of assault-related ocular trauma have been previously reported (22–30%).[5, 23, 24] However, other researchers have reported much higher incidence rates of assault-related ocular injury(34–53%).[17, 25, 26] Other common causes of ocular injuries in the present study included RTIs (20.59%), sports/recreational activities (17.65%) and cracker blasts (17.65%). Blomdahl et al. reported similar findings [27]. In order to avoid or prevent severe eye injuries, MacEwen et al. recommended that children wear appropriate protective eyewear while taking part in sporting activities.[19] Babar et al. recorded bilateral involvement in 46 (2.9%) of 1,551 hospitalised ocular trauma patients in Pakistan, with the most common cause being landmine blasts (54.3%), dynamite blasts (10.8%) and firearms (6.5%), with RTIs and physical assault being responsible in only 4.3% and 2.1% of cases, respectively.[2]

Traumatic agents in the present study were mostly solid in nature (41.18%), with the most common mode of injury being collision/impact (41.18%), followed by blast/gunshots (20.59%). Over one-third of the victims (38.24%) were under the influence of alcohol at the time of injury. Moreover, 82.35% were not using a protective device, a major risk factor for severe ocular injury. When analysing the period of time elapsed between injury and seeking medical care, the majority of the patients presented one day after injury (41.17%). Of the 14.71% of victims who reported to hospital several days after the traumatic incident, the majority came from rural backgrounds and were of low socioeconomic status. Previous studies have indicated that delayed hospital presentation is a major risk factor for poor visual outcomes in patients with serious ocular injuries.[28, 29]

The majority of our patients had polytrauma (58.82%),while 41.18% had isolated ocular trauma, thus indicating that the management of bilateral ocular trauma requires a multidisciplinary approach. In particular, assault, RTIs and falls were common causes of polytrauma; similar findings have been reported previously [25, 30]. In our study, the most common ocular structure involved was the periocular tissues and eyelid (63.24%), followed by the globe (44.12%). Periocular burns with or without foreign bodies occurred in 29.11% of patients, while chemical burns accounted for 8.83% of cases. The commonest type of globe injury were CGIs (29.41%) in zones I, II and III, while OGIs were present in 14.71% of cases, most commonly in zone II.

Bilateral ocular OGIs area rare occurrence (1.6–5.4%).[31, 32] Jovanovic et al. reported that 66.7% of 36 cases of simultaneous bilateral ocular injuries due to RTIs were OGIs.[6] In particular, globe ruptures in zone III are associated with poor initial visual acuity, while poor final visual acuity is likely in cases of OGIs with wound sizes of > 10 mm.[29] Our results demonstrated that zone III OGIs, poor initial visual acuity, the presence of associated intraocular haemorrhage (i.e. hyphaema and vitreous haemorrhage), injury to the lens or uveal tissue, retinal detachment and low OTS values (categories I or II) were poor prognostic factors. Similar observations have been reported in other studies.[22, 33–39].

The results of this study should be considered in light of certain limitations. The study was retrospective in nature and not randomised, with data collection limited to the information available in the patients' medical records. Moreover, the sample size was relatively small for the purposes of subgroup

comparison. Finally, it is likely that the findings underestimated the actual incidence of bilateral ocular injuries given that the study was restricted to cases treated at a single teaching hospital in North India. Nevertheless, this study provides important demographic, clinical and epidemiological information regarding the frequency, presentation and outcomes of cases of simultaneous bilateral ocular trauma.

Conclusion

Simultaneous bilateral ocular trauma is rare. This study highlights the demographic characteristics, injury profile, risk factors and visual outcomes of simultaneous bilateral ocular trauma cases presenting to a hospital in North India. Major causes of trauma included assault, RTIs, sports/recreational activities and crackers, with the victims being mostly young men. In light of the severe nature and poor outcomes associated with such injuries, the use of ocular protective measures during potentially dangerous activities is recommended.

Declarations

Conflict of Interest

The authors declare no potential conflicts of interest.

Author Contributions

RPM and VPS designed the study; BKK, SB ,MP and MR procured the samples and performed the experiments; AK designed and performed the statistical analyses; JKD and AM provided critical input; RPM and MK interpreted the results; SB, BKK and MR wrote the first draft of the manuscript with inputs from all authors; JKD, MK and AM critically appraised the manuscript; and all authors reviewed and approved the final version of the manuscript prior to submission.

Funding Support

No funding was received for this study.

Data Availability: The clinical data of patient available can be provided on demond.

Ethical Clearance

The study was approved by "*Ethical Committee*" of Institute of medical Sciences, Banaras Hindu University (EC Registration No. ECR/526/Inst/UP/2014 Dt. 31.1.14) with the reference No. Dean/2014-15/EC/1157dated:21.05.2015.(Copy attached).

Animal Research: Study not related to Animal Research.

Consent to Participate & to Publish:

Informed consent was obtained from the patients / parents of the patients regarding participation in research study, review of their medical records/reports and to have their data including clinical images published.

References

1. Ababneh LT, Mohidat H, Abdelnabi H et al (2019) Hospital-based ocular trauma: factors, treatment and impact outcome. Clin Ophthalmol 13:2119–2126. doi:10.2147/OPTH.S223379
2. Babar TF, Khan MN, Jan SU et al (2007) Frequency and causes of bilateral ocular trauma. J Coll Physicians Surg Pak 17:679–682
3. Bućan K, Matas A, Lovrić JM et al (2017) Epidemiology of ocular trauma in children requiring hospital admission: a 16-year retrospective cohort study. J Glob Health 7:010415. doi:10.7189/jogh.07.010415
4. Maurya RP, Sinha K, Sen PR et al (2013) A clinico-epidemiological study of ocular trauma in Indian university students. Pak J Ophthalmol 29:80–88
5. Dannenberg AL, Parver LM, Fowler CJ (1992) Penetrating eye injuries related to assault: The National Eye Trauma System Registry. Arch Ophthalmol 110:849–852. doi:10.1001/archopht.1992.01080180121039
6. Jovanovic M, Hentova-Sencanic P, Vukovic D et al (2011) Simultaneous injuries to both eyes in traffic accidents. Graefes Arch Clin Exp Ophthalmol 249:1761–1764. doi:10.1007/s00417-010-1473-z
7. Brilliant LB, Pokherel RP, Grasset NC et al (1985) Epidemiology of blindness in Nepal. Bull World Health Organ 63:375–386
8. Sabaci G, Bayer A, Mutlu FM et al (2002) Endophthalmitis after deadly-weapon-related open-globe injuries: risk factors, value of prophylactic antibiotics, and visual outcomes. Am J Ophthalmol 133:62–69. doi:10.1016/s0002-9394(01)01320-4
9. Georgouli T, Pountos I, Chang BYP et al (2011) Prevalence of ocular and orbital injuries in polytrauma patients. Eur J Trauma Emerg Surg 37:135–140. doi:10.1007/s00068-010-0029-6
10. Heering SL, Shohat T, Heering AS et al (1992) Civil unrest and ocular trauma. Mil Med 157:297–298. doi:10.1093/milmed/157.6.297
11. Sorenson SB (2011) Gender disparities in injury mortality: consistent, persistent, and larger than you'd think. Am J Public Health 101:S353–S358. doi:10.2105/AJPH.2010.300029
12. Byrnes JP, Miller DC, Schafer WD (1999) Gender differences in risk taking: a meta-analysis. Psychol Bull 125:367–383. doi:10.1037/0033-2909.125.3.367
13. Klopfer J, Tielsch TM, Vitale S et al (1992) Ocular trauma in the United States: eye injuries resulting in hospitalization, 1984 through 1987. Arch Ophthalmol 110:838–842. doi:10.1001/archopht.1992.01080180110037
14. Kuhn F, Morris R, Witherspoon CD et al (2006) Epidemiology of blinding trauma in the United State Eye Injury Registry. Ophthalmic Epidemiol 13:209–216. doi:10.1080/09286580600665886

15. Canavan YM, O'Flaherty MJ, Archer DB, et al. A 10-year survey of eye injuries in Northern Ireland, 1967-76. Br J Ophthalmol 1980;64:618–625. doi:10.1136/bjo.64.8.618
16. Lewallen S, Courtright P (2001) Blindness in Africa: present situation and future needs. Br J Ophthalmol 85:897–903. doi:10.1136/bjo.85.8.897
17. Liggett PE, Pince KJ, Barlow W et al (1990) Ocular trauma in an urban population: review of 1132 cases. Ophthalmology 97:581–584. doi:10.1016/s0161-6420(90)32539-3
18. Luff AJ. Hodgkins PR, Baxter RJ et al (1993) Aetiology of perforating eye injury. Arch Dis Child 68:682–683. doi:10.1136/adc.68.5.682
19. MacEwen CJ, Baines PS, Desai P (1999) Eye injuries in children: the current picture. Br J Ophthalmol 83:933–936. doi:10.1136/bjo.83.8.933
20. Mackiewicz J, Machowicz-Matejko E, Sałaga-Pylak M et al (2005) Work-related, penetrating eye injuries in rural environments. Ann Agri Environ Med 12:27–29
21. Maurya RP, Srivastava T, Singh VP et al (2019) The epidemiology of ocular trauma in Northern India: a teaching hospital study. Oman J Ophthalmol 12:78–83. doi:10.4103/ojo.OJO_149_2018
22. Tok O, Tok L, Ozkaya D et al (2011) Epidemiological characteristics and visual outcome after open globe injuries in children. J AAPOS 15:556–561. doi:10.1016/j.jaapos.2011.06.012
23. Niiranen M (1979) Perforating eye injuries caused by occupational accidents treated at Helsinki University Eye Hospital in 1970 to 1977. Acta Ophthalmol 57:822. doi:10.1111/j.1755-3768.1979.tb01848.x
24. Gilbert CM, Soong HK, Hirst LW (1987) A two-year prospective study of penetrating ocular trauma at the Wilmer Ophthalmological Institute. Ann Ophthalmol 19:104–106
25. Scherf J, Zonis S (1976) Perforating injuries of the eye. Eye Ear Nose Throat Mon 55:32–40
26. Gordon YJ, Mokete M (1981) Adult ocular injuries in Lesotho. Doc Ophthalmol 51:187–192. doi:10.1007/BF00143882
27. Blomdahl S, Norell S (1984) Perforating eye injury in the Stockholm population: an epidemiological study. Acta Ophthalmol (Copenh) 62:378–390. doi:10.1111/j.1755-3768.1984.tb08418.x
28. May DR, Kuhn FP, Morris RE et al (2000) The epidemiology of serious eye injuries from the United States Eye Injury Registry. Graefes Arch Clin Exp Ophthalmol 238:153–157. doi:10.1007/PL00007884
29. Rofail M, Lee GA, O'Rourke P (2006) Prognostic indicators for open globe injury. Clin Exp Ophthalmol 34:783–786. doi:10.1111/j.1442-9071.2006.01309.x
30. El-Sebaity DM, Soliman W, Soliman AM et al (2011) Pediatric eye injuries in upper Egypt. Clin Ophthalmol 5:1417–1423. doi:10.2147/OPTH.S24679
31. Meng Y, Yan H (2015) Prognostic factors for open globe injuries and correlation of ocular trauma score in Tianjin, China. J Ophthalmol 2015:345764.doi. 10.1155/2015/345764
32. Ozturk T, Dora GC, Ayhan Z et al (2019) Etiology and visual prognosis in open globe injuries: results of a tertiary referral center in Turkey. Sci Rep 9:17977. doi:10.1038/541598-019-54598-w

33. Yasu U, Vasnaik A, Batta RR et al (2001) Occupational open globe injuries. Indian J Ophthalmol 49:43–47
34. KaragözIK, Sarı ES, Kubaloğlu A et al (2018) Characteristics of pediatric and adult cases with open globe injury and factors affecting visual outcomes: a retrospective analysis of 294 cases from Turkey. Ulus Travma Acil Cerrahi Derg 24:31–38. doi:10.5505/tjtes.2017.03607
35. Cheung CA, Rogers-Martel M, Golas L et al (2014) Hospital-based ocular emergencies: epidemiology, treatment, and visual outcomes. Am J Emerg Med 32:221–224.doi:10.1016/j.ajem.2013.11.015
36. Cardillo JA, Stout JT, LaBree L et al (1997) Post-traumatic proliferative vitreoretinopathy: the epidemiologic profile, onset, risk factors, and visual outcome. Ophthalmology 104:1166–1173. doi:10.1016/s0161-6420(97)30167-5
37. Hutton WL, Fuller DG (1984) Factors influencing final visual results in severely injured eyes. Am J Ophthalmol 97:715–722. doi:10.1016/0002-9394(84)90503-8
38. Dandona L, Dandona R, Srinivas M et al (2000) Ocular trauma in an urban population in southern India: the Andhra Pradesh Eye Disease Study. Clin Exp Ophthalmol 28:350–356. doi:10.1046/j.1442-9071.2000.00334.x
39. Agrawal R, Wei HS, Teoh S (2013) Prognostic factors for open globe injuries and correlation of ocular trauma score at a tertiary referral eye care centre in Singapore. Indian J Ophalmol 61:502–506. doi:10.4103/0301-4738.119436

Figures

Figure 1

(A) A 28-year-old man with an assault-related bilateral closed globe injury. (B) A middle-aged man with fall-related bilateral orbital trauma showing ecchymosis and epistaxis. (C) A young man with multiple oculofacial lacerations following a injury. (D) A 30-year-old man with assault-related bilateral thermal burns on the eyelids. (E) A 10-year-old boy with facial burns following accidental flame exposure. (F) An 8-year-old boy with bilateral periocular burns due to a cracker blast.

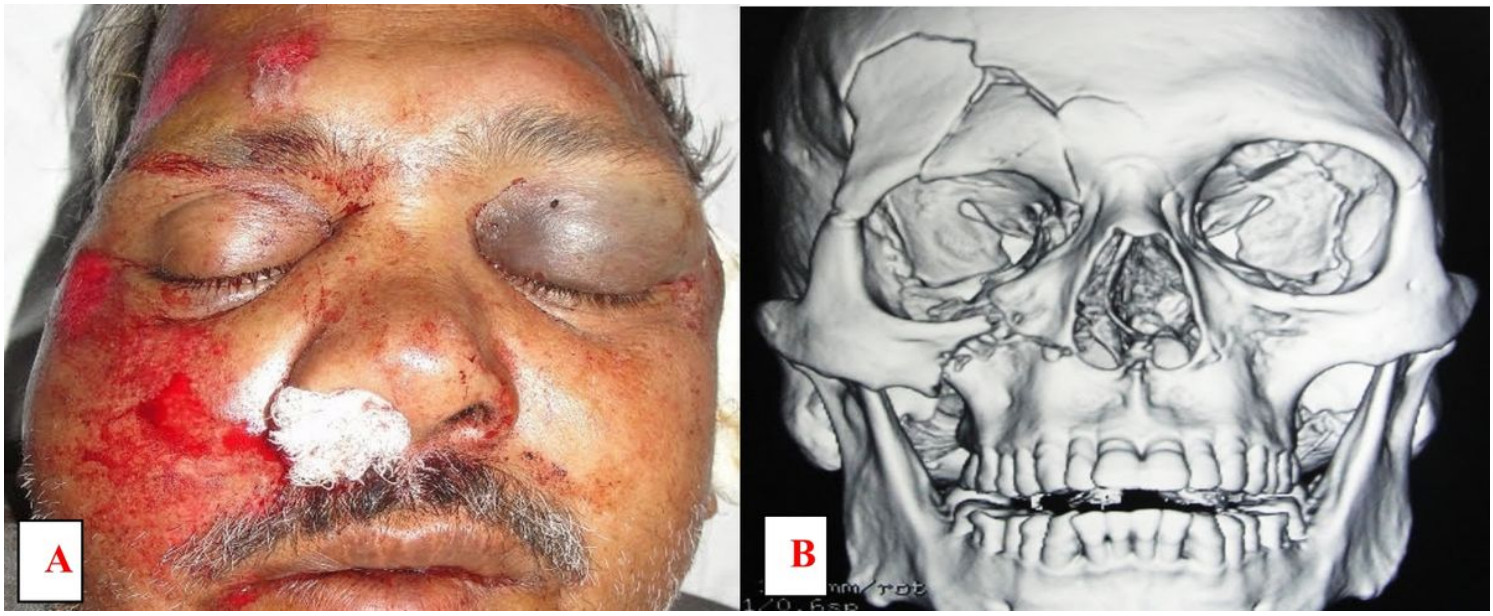

Figure 2

A) A middle-aged man with cranio-orbito-facial trauma due to a road traffic injury showing facial asymmetry and swelling and periocular abrasions. (B) Three-dimensional computed tomography scan showing multiple displaced fractures of the right frontal bone and the roof, floor and lateral walls of both orbits.