Angiolipoma tissue analysis based on color-based segmentation using L * a * b * color space

Mahyar Radak (m_radak@physics.iust.ac.ir)

Department Physics Iran University of Science and Technology, Tehran https://orcid.org/0000-0002-9655-8396

Research Article

Keywords: H&E stains, Angiolipoma, Tissue segmentation, Tissue analysis

Posted Date: May 2nd, 2022

DOI: https://doi.org/10.21203/rs.3.rs-1617162/v1

Abstract

Texture analysis refers to the description of areas in an image with their texture content. Texture analysis attempts to determine visual qualities described in terms such as rough, smooth, silky, or uneven as a function of spatial variations in pixel intensity. This article shows how to identify different colors in angiolipoma tissue by analyzing the color space L * a * b *. Texture analysis can be useful when objects are identified more closely by their texture in an image than by intensity, and traditional thresholding techniques can not be used effectively.

1. Introduction

Hematoxylin and eosin staining (abbreviated as H&E staining or HE staining) is one of the major tissue stains used in histology [1–3]. In addition to routine H&E staining, other specific histochemical stains are often requested to confirm suspicious structures or findings on H&E stained slides [4]. Hematoxylin and eosin staining [5] principally stains thenuclei of cells blue or dark-purple [6],[7],[8]. Angiolipoma usually appears as multiple and painful subcutaneous nodules. The peak is between the second and third decade of life. They often affect the upper limbs (approximately two-thirds of the forearm) [9–12]. A variety of clinical methods have been used to diagnose angiolipoma tissue [13–14], and this article, the amount of color distribution in this particular tissue, shows that this algorithm can show the amount of color distribution in each image stained with HE.

2. Materials And Methods

1. First, we read the angiolipoma tissue images entered in the software.

2. We display three main colors in the image: background color, purple, and magenta. The color space L * a * b * (also known as CIELAB or CIE L * a * b *) minimizes these visual differences. The color space L * a * b * is derived from the values of tristimulus CIE XYZ. The space L * a * b * consists of a layer of luminosity "L *" or a layer of light, the color layer "a *" which indicates the placement of the color along the red-green axis, and the colored layer "b *" which indicates the placement of the color in the extension is composed. The approach is to select a small sample area for each color and calculate the average color of each sample area in the space 'a * b *'. We use these color markers to classify each pixel.

3. Classify Each Pixel Using the Nearest Neighbor Rule.

4. Display Results of Nearest Neighbor Classification.

One of the statistical methods for examining texture that considers the spatial relationship of pixels is the gray surface event matrix (GLCM), also known as the gray surface spatial dependence matrix. GLCM functions determine the texture of an image by calculating the number of times a pair of pixels of a certain value occurs in a given spatial relationship in an image, generate a GLCM, and then extract statistical metrics from this matrix.

After creating GLCM, several statistics can be extracted from them using the graycoprops function. This statistic provides information about the texture of an image. The table below shows the statistics.

3. Conclusions

Tissue analysis is used in a variety of applications including remote sensing, automated inspection and medical image processing. Tissue analysis can be used to find tissue boundaries, which is called tissue segmentation. We isolated and detected three images of angiolipoma tissue stained with HE using the L * a * b * color space algorithm, purple and magenta colors present in a part of the tissue. This algorithm weaves and separates color areas with high accuracy and quality for all HE stain images.

Declarations

4. ACKNOWLEDGEMENT

Simulations and algorithms were implemented in MATLAB software.

5. Competing interests

There is NO Competing Interest.

References

1. Titford, M. "The long history of hematoxylin." Biotechnic & histochemistry 80.2 (2005): 73–78.
2. Smith, Cristina. "Our debt to the logwood tree: the history of hematoxylin." MLO: medical laboratory observer 38.5 (2006): 18–22.
3. Dapson, R. W., and R. W. Horobin. "Dyes from a twenty-first century perspective." Biotechnic & Histochemistry 84.4 (2009): 135–137.
4. Pai, Rish K. "Surgical Pathology of the GI Tract, Liver, Biliary Tract, and Pancreas." (2009): 1581.
5. Llewellyn, B. D. "Nuclear staining with alum hematoxylin." Biotechnic & Histochemistry 84.4 (2009): 159–177.
6. Bancroft, John D., and Marilyn Gamble, eds. Theory and practice of histological techniques. Elsevier health sciences, 2008.
7. Kiernan, J. A. "Does progressive nuclear staining with hemalum (alum hematoxylin) involve DNA, and what is the nature of the dye-chromatin complex?." Biotechnic & Histochemistry 93.2 (2018): 133–148.
8. Chan, John KC. "The wonderful colors of the hematoxylin–eosin stain in diagnostic surgical pathology." International journal of surgical pathology 22.1 (2014): 12–32.
9. Van Der Graaf, Winette TA, et al. "Pazopanib for metastatic soft-tissue sarcoma (PALETTE): a randomised, double-blind, placebo-controlled phase 3 trial." The Lancet 379.9829 (2012): 1879–

1886.
10. Renshaw, Andrew. "Practical Soft Tissue Pathology." (2013): 440.
11. VERTINSKY, TALIA, MAHESH V. JAYARAMAN, and BARTON LANE. "Evaluation of Spinal Canal Tumors." Tumors of the Spine E-Book (2008): 184.
12. Ruengwanichayakun, Poosit, et al. "Parosteal osteosarcoma: a monocentric retrospective analysis of 195 patients." Human Pathology 91 (2019): 11–18.
13. Radak, Mahyar. "Detection of angiolipoma nuclei in H&E staining image by tissue segmentation using tissue filters." (2022). DOI: 10.21203/rs.3.rs-1489230/v1
14. Radak, Mahyar. "Isolation of angiolipoma tissue sections with Color-Based Segmentation Using K-Means Clustering." (2022). DOI: 10.21203/rs.3.rs-1495322/v1

Image Sources

Image sources are available in the Supplementary Files section.

Figures

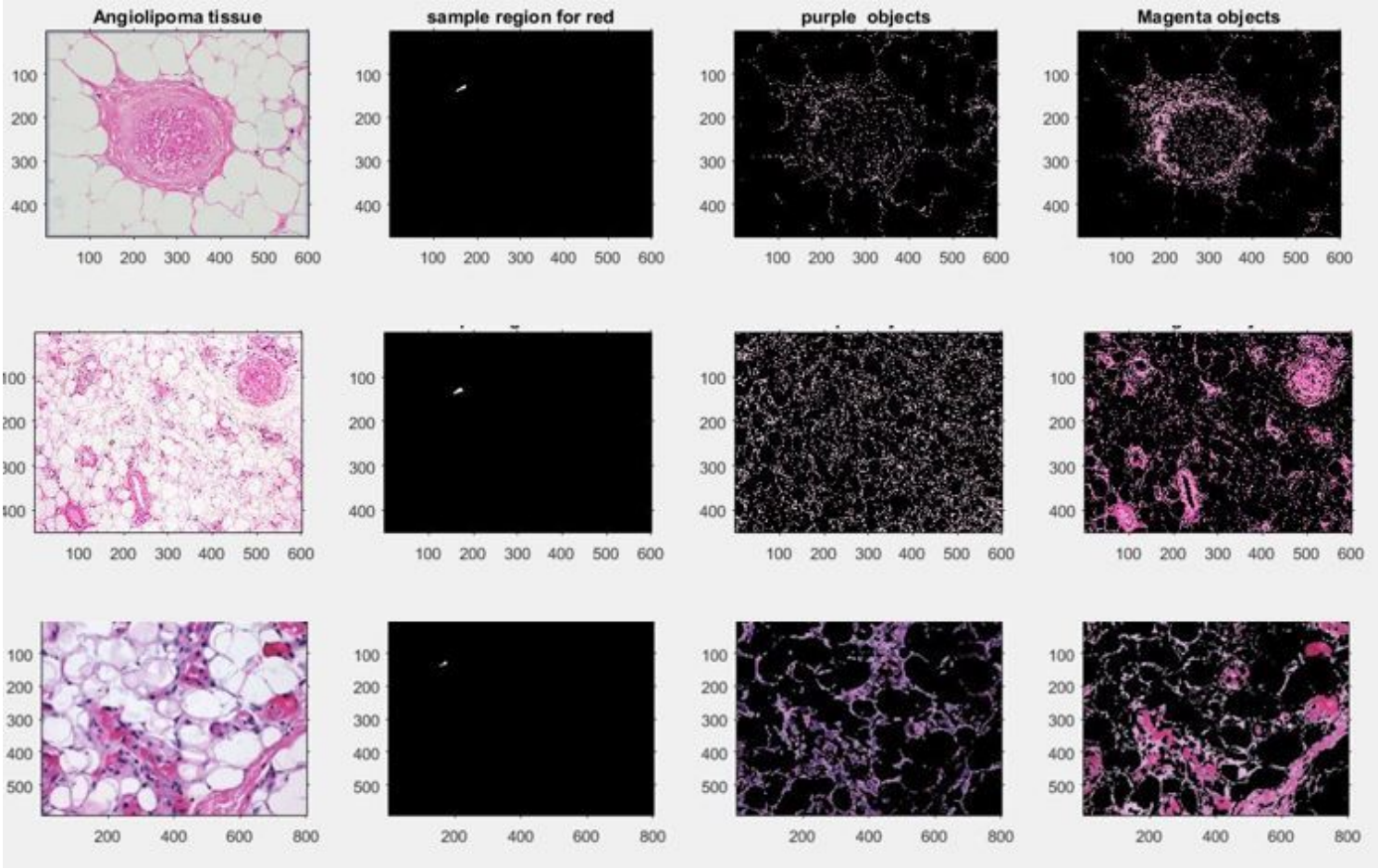

Figure 1

A) Images of angiolipoma tissue with HE stained, **B)** Small sample area for each HE color in the texture, **C, D)** Detection and separation of spots stained with purple and magenta

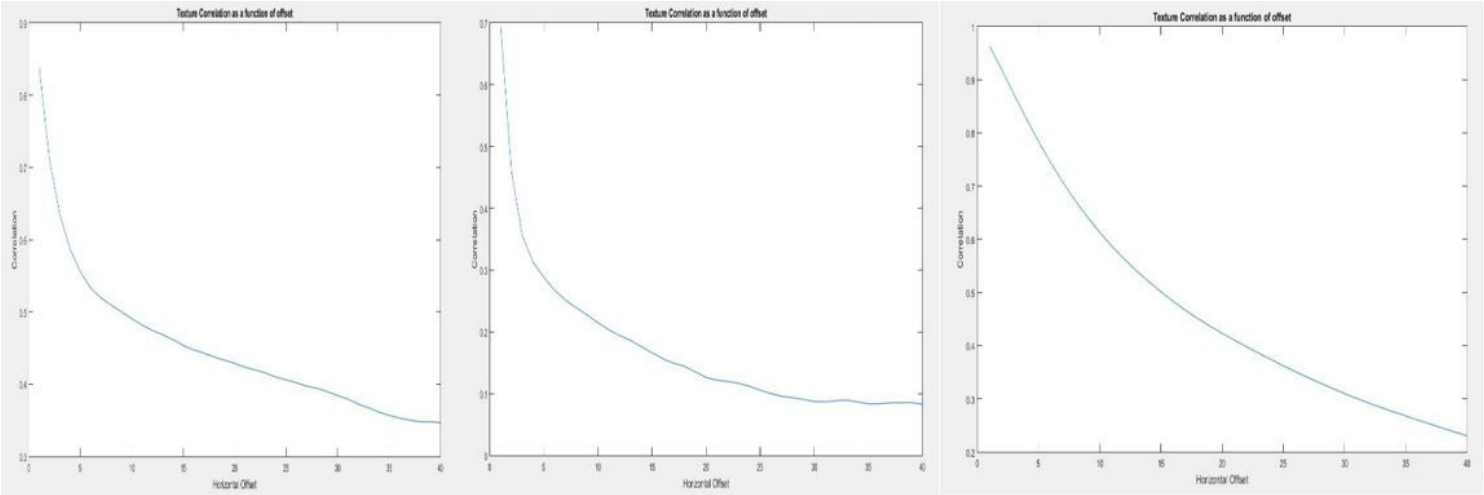

Figure 2

Chart correlation as a function of offset for three angiolipoma tissue images

Supplementary Files

This is a list of supplementary files associated with this preprint. Click to download.

- 7Imagesources.docx