Cervical kyphosis was reversed into lordosis by cervical manipulation: A case report with 9 months follow-up

Shuai Pei
https://orcid.org/0000-0002-8035-820X
Junyi You
Yuwei Li
Xiaofeng Shen
Jie Yu
Minshan Feng
Xunlu Yin
Pengfei Yu (stqg1020@163.com)
Hong Jiang

Case report

Keywords: Case report, Cervical kyphosis reversed, Cervical manipulation therapy

Posted Date: May 11th, 2022

DOI: https://doi.org/10.21203/rs.3.rs-1618318/v1

Abstract

Background

Cervical kyphosis (CK) is an abnormal structure that accelerates cervical disc degeneration and causes neck pain. Nearly a quarter of young people have CK, yet its treatment remains controversial.

Case presentation

We present an interesting case of CK; In this case report, a 32-year-old male patient with neck pain was seen in our hospital, whose cervical sagittal alignment was kyphotic and was given a cervical manipulation therapy (CMT). CK was subsequently reversed into lordosis in one day after the treatment along with the patient's clinical symptoms alleviated. Three months later, the patient complained his neck pain had come back, so we scheduled him a second X-ray. We gave him a second CMT because the radiograph showed he got CK again. A follow-up after 6 months showed that the patient's neck pain relieved and the cervical spine was still lordotic.

Conclusions

It suggested that CK can be reversed into CL by CMT immediately, but requires continuous treatment at the early stage; neck pain may relate to CK.

Background

Cervical lordosis (CL) is the basis of cervical functions, and it helps distribute stress evenly on each disc. On the contrary, cervical kyphosis (CK) accelerates cervical disc degeneration [1, 2], causing neck pain and spinal cord symptoms [3]. As lifestyles change, more and more people are experiencing degenerative CK without neurological symptoms, and about 25% of people and 70% of patients with neck pain are suffering from it [4, 5]. Since the mechanism of CK is not yet clear, there is no accepted treatment currently.

CK has a variety of causes, including degeneration, infection, trauma, inflammation, iatrogenic and is usually determined by the C2-7 Cobb angle. This article focuses on kyphosis after degeneration, which are the most numerous. Degenerative changes in the cervical spine involving multiple levels can lead to CK. As the spine ages, spinal bone density decreases. The axial force is offset, resulting in a larger moment arm at the point of rotation. Further axial loading will lead to further development of kyphosis if the balance of kyphosis and cervical loading is not restored.

Relevant studies showed that rehabilitation therapy can reverse CK into lordosis, however, that requires a long-term treatment for 10–18 weeks, which places a heavy burden on doctors and patients [6, 7]. Cervical manipulation therapy (CMT) is an effective way to relieve neck pain by promoting the gliding of small synovial joints and increasing the mobility of the cervical spine[8], and can also be used to restore CL.

Case Report/case Presentation

The patient, a 32-year-old male, had neck pain for 2 years, aggravated for 2 days and came to our outpatient clinic on May 6, 2020. The patient had not taken any medication or received any physical therapy for the last 3 months. Before this visit, the patient had not had a cervical spine radiograph. Physical examination: stiff bilateral neck muscles; tenderness between the C5/6 spinous processes; no other positive signs. The visual analogue score (VAS) was 4 and the radiograph showed he had CK (Fig.1). Combining the patient's history, signs, and radiograph, the current diagnosis is neck pain. Cervical spine manipulation is a routine treatment for neck pain, and many studies have reported its effectiveness and safety. Prior to manipulation, we sought the patient's consent and informed him of the possible benefits (cervical pain relief) and risks (increased pain, nerve and even spinal cord injury) of undergoing manipulation, and the patient gave informed consent and requested manipulation. Ethics approval was obtained from Suzhou TCM hospital and its ethics committee before the treatment.

Therapeutic intervention

CMT was conducted on the patient, it is a single, low-amplitude, high-velocity manipulation. Steps: Firstly, the index finger of the operator's left hand is pressed against the patient's C5 left vertebral plate, which is chosen based on the x-ray, while the palm of the operator's right hand is used to stabilize the patient's head and help it rotate to the right. Secondly, push the patient's cervical spine forward with the index finger of the left hand and guide the patient's cervical spine to rotate to the right with the right palm, which required a high velocity and low amplitude. (Fig.2). At the end of the treatment, we told the patient to reduce the time spent with his head down at work and recommended a second radiograph to assess the effect of CMT on CK, which had been shown to be possible in previous case reports[6, 7]. The patient's VAS was 1 then, and the second radiograph showed CK was reversed into lordosis (Fig.3).

Follow up

2020-08, the patient came to our hospital for a follow-up and complained of neck pain coming back. We scheduled him for another sagittal cervical spine radiograph and evaluated the pain level. The VAS score was 5 and radiograph showed the reappearance of CK in the patient, and after communication with the patient, CMT was given again (Fig.4). After the treatment, the patient’s VAS was 1, but we did not take further radiograph due to the amount of radiation.

2021-02, the patient went to the outpatient clinic of our hospital again with no obvious neck pain and the VAS score was 0. Radiograph showed the cervical spine was lordotic (Fig.5).

During the course of CMT treatment and follow-up, the patient did not show or mention any discomfort.

Discussion/conclusion

This article introduces an effective treatment for CK and CK was reversed into lordosis after CMT and maintained for several months. Few studies have reported this phenomenon, especially for cervical curvature recovery on the same day of treatment. During this period, the patient's neck pain symptoms relieved significantly compared to that 9 months ago, indicating that cervical sagittal alignment may be related to neck pain. Although some studies have demonstrated there is a correlation between CK and neck pain[9], the relationship between them is still unclear[10], and there is no longitudinal follow-up research of the same patient.

The mechanism of CK is still unclear. Some scholars believe CK is caused by cervical disc degeneration[11], which reduces the height of the disc and eventually causes the disc to collapse. However, in our observations, some young neck pain patients with CK had no obvious disc degeneration. Another point of view insists that the spine is an organic whole, CK is caused by pelvis or thoracolumbar deformity[12]. In order to maintain upright and level vision, people with a large lumbar curvature usually have a large thoracic curvature and cervical curvature. However, excessive cervical lordosis reduces the area of the intervertebral foramina and can easily cause nerve entrapment. Therefore, excessive CL is also a sign of imbalance. Muscle imbalance is also an important view supported by many scholars that will cause cervical imbalance[13]. We believe that patients with CK have a problematic vertebra that produces abnormal sliding with the articular processes of adjacent vertebrae, thereby affecting the positional relationship of that spinal motion unit, further contributing to the creation of CK.

There are many schools of CMT, however, few studies have considered the influence of force point and direction on cervical sagittal alignment. The cervical facet joints and intervertebral discs are the main parts of the vertebral body connection. The intervertebral disc who has a creep characteristic means that it can hardly be transformed immediately by a sudden thrust[14], while the facet joints who has a micro-motion characteristic may explain how CK reversed happen. Therefore, when we are performing CMT, we consciously select the force point and direction according to the cervical spine lateral radiograph (Fig.6). We speculate that the mechanism of manipulation restoring cervical lordosis could be that the upper and lower articular processes slide relative by mechanical stimulation.

The limitations of this study are as follow: A single CMT may not be sufficient because the patient's CK coming back 3 months after his first treatment. Continuous CMT may sustain cervical lordosis, which requires further validation. In future studies, we will evaluate the effect of treatment cycle of CMT on the reversion of CK. Currently, CMT is much dependent on operator’s proficiency and still cannot be standardized, which hinders the research of CMT. The invention of CMT robot may solve this problem.

Abbreviations

CK Cervical kyphosis

CL Cervical lordosis

CMT Cervical manipulation therapy

VAS Visual analogue scale

Declarations

Ethics approval and consent to participate

The experimental protocol was established, according to the ethical guidelines of the Helsinki Declaration and was approved by the Human Ethics Committee of Suzhou TCM hospital. Written informed consent was obtained from individual or guardian participants.

Consent for publication

Written consent to publish this information was obtained from the study participant.

Availability of data and materials

All data generated or analyzed during this study are included in this article.

Competing interests

We declare that we have no financial and personal relationships with other people or organizations that can inappropriately influence our work, there is no professional or other personal interest of any nature or kind in any product, service and/or company that could be construed as influencing the position presented in, or the review of, the manuscript entitled, “Cervical kyphosis was reversed into lordosis by cervical manipulation: A case report with 9 months follow-up.”

Funding

There was no funding for the research for this manuscript for either author.

Authors’ contributions

*Shuai Pei and *Junyi You contributes equally to this work. The study was designed by Shuai Pei and Junyi You. The cervical manipulation was made by Shuai Pei. The manuscript writing was performed by Xiaofeng Shen, Jie Yu and Minshan feng. Patient follow-up is done by Yuwei Li and Xunlu Yin. The manuscript was finalized by Pengfei Yu and Hong Jiang. All authors have read and revised the manuscript critically.

Acknowledgements

Not applicable

References

1. DAIMON K, FUJIWARA H, NISHIWAKI Y, et al. A 20-Year Prospective Longitudinal Study of Degeneration of the Cervical Spine in a Volunteer Cohort Assessed Using MRI: Follow-up of a Cross-Sectional Study[J]. J Bone Joint Surg Am, 2018, 100 (10): 843-849.
2. LEE H J, JEON D G, PARK J H. Correlation between kinematic sagittal parameters of the cervical lordosis or head posture and disc degeneration in patients with posterior neck pain[J]. Open medicine (Warsaw, Poland), 2021, 16 (1): 161-168.
3. ZHU C, YANG X, ZHOU B, et al. Cervical kyphosis in patients with Lenke type 1 adolescent idiopathic scoliosis: the prediction of thoracic inlet angle[J]. BMC Musculoskelet Disord, 2017, 18 (1): 220.
4. KIM S W, KIM T-H, BOK D H, et al. Analysis of cervical spine alignment in currently asymptomatic individuals: prevalence of kyphotic posture and its relationship with other spinopelvic parameters[J]. Spine J, 2018, 18 (5): 797-810.
5. YU M, ZHAO W-K, LI M, et al. Analysis of cervical and global spine alignment under Roussouly sagittal classification in Chinese cervical spondylotic patients and asymptomatic subjects[J]. Eur Spine J, 2015 Jun, 24 (6): 1265-1273.
6. DENNIS A K, OAKLEY P A, WEINER M T, et al. Alleviation of neck pain by the non-surgical rehabilitation of a pathologic cervical kyphosis to a normal lordosis: a CBP case report[J]. Journal of physical therapy science, 2018, 30 (4): 654-657.
7. FORTNER M O, OAKLEY P A, HARRISON D E. Non-surgical improvement of cervical lordosis is possible in advanced spinal osteoarthritis: a CBP case report[J]. Journal of physical therapy science, 2018, 30 (1): 108-112.
8. ANDERST W J, GALE T, LEVASSEUR C, et al. Intervertebral kinematics of the cervical spine before, during, and after high-velocity low-amplitude manipulation[J]. Spine J, 2018, 18 (12): 2333-2342.
9. LI J, ZHANG D, SHEN Y. Impact of cervical sagittal parameters on axial neck pain in patients with cervical kyphosis[J]. J Orthop Surg Res, 2020, 15 (1): 434.
10. OKADA E, DAIMON K, FUJIWARA H, et al. Twenty-year Longitudinal Follow-up MRI Study of Asymptomatic Volunteers: The Impact of Cervical Alignment on Disk Degeneration[J]. Clinical spine surgery, 2018, 31 (10): 446-451.
11. OKADA E, MATSUMOTO M, ICHIHARA D, et al. Does the sagittal alignment of the cervical spine have an impact on disk degeneration? Minimum 10-year follow-up of asymptomatic volunteers[J]. Eur Spine J, 2009 Nov, 18 (11): 1644-1651.
12. OE S, YAMATO Y, HASEGAWA T, et al. Deterioration of sagittal spinal alignment with age originates from the pelvis not the lumbar spine: a 4-year longitudinal cohort study[J]. Eur Spine J, 2020 Sep, 29 (9): 2329-2339.
13. KIM T-H, LEE S Y, KIM Y C, et al. T1 slope as a predictor of kyphotic alignment change after laminoplasty in patients with cervical myelopathy[J]. Spine, 2013, 38 (16): E992-E997.
14. CASTRO A P G, WILSON W, HUYGHE J M, et al. Intervertebral disc creep behavior assessment through an open source finite element solver[J]. Journal of biomechanics, 2014, 47 (1): 297-301.

Figures

Figure 1

The cervical sagittal alignment is kyphotic before Cervial manipulation therapy

Figure 2

Cervial manipulation therapy

Figure 3

Cervical kyphosis was reversed into lordosis after the first Cervial manipulation therapy

Figure 4

Cervical kyphosis came back 3 months after the first Cervial manipulation therapy

Figure 5

Cervical lordosis maintained 6 months after the second Cervial manipulation therapy

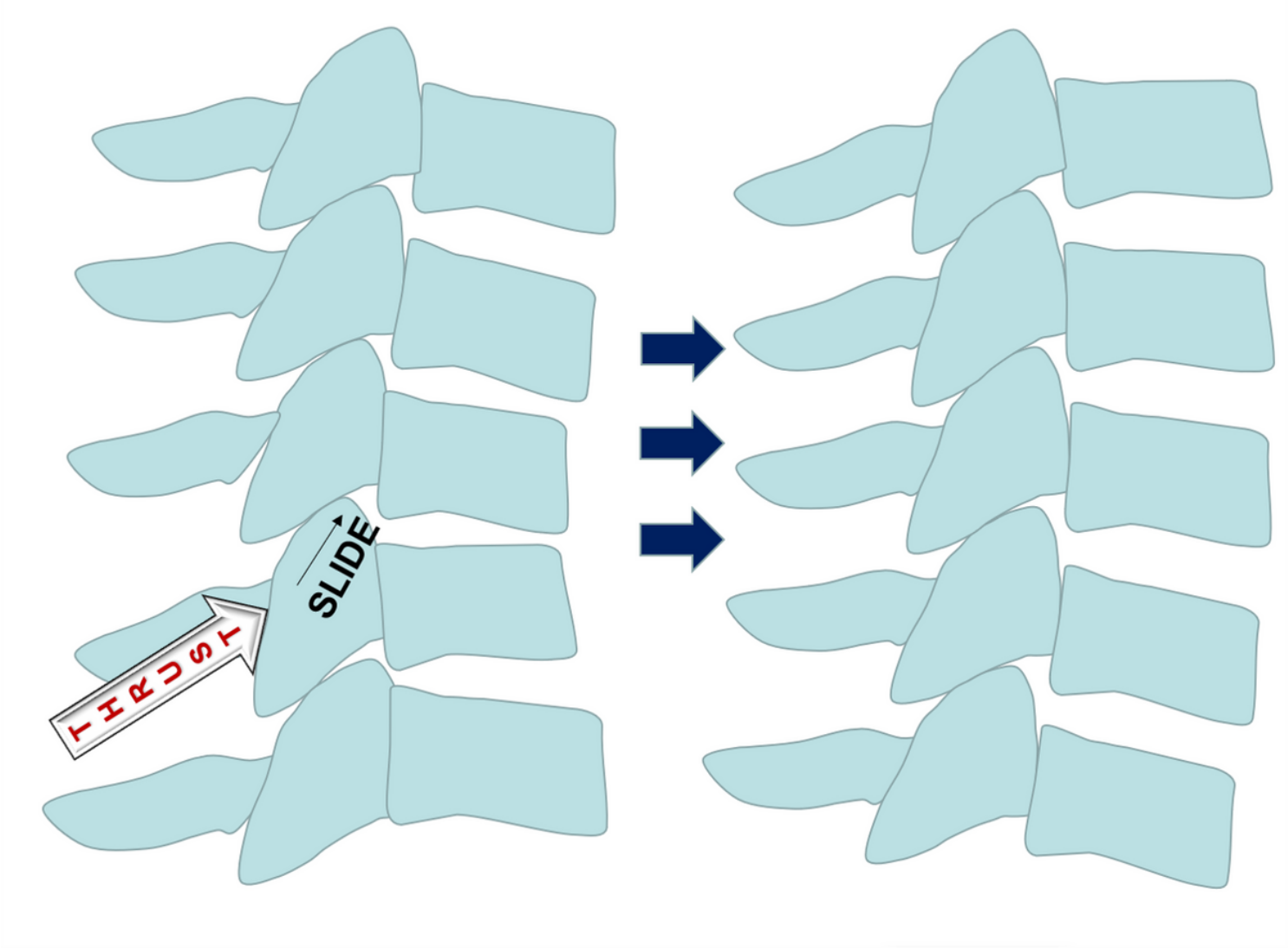

Figure 6

The possible mechanism by which cervical kyphosis is reversed into lordosis