Research Square

Preprints are preliminary reports that have not undergone peer review. They should not be considered conclusive, used to inform clinical practice, or referenced by the media as validated information.

Open reduction internal fixation (ORIF) for supination-external rotation type IV ankle fractures via anterolateral and posterolateral approaches

Jie Shen
The Second Affiliated Hospital of Soochow University
Jiaju Zhao
The Second Affiliated Hospital of Soochow University
Nan Yi
The Second Affiliated Hospital of Soochow University
Yong Zhang
The Second Affiliated Hospital of Soochow University
Zhicheng Zuo
The Second Affiliated Hospital of Soochow University
LuLu Chai
The Second Affiliated Hospital of Soochow University
Bo Jiang (jiangbo082611@163.com)
The Second Affiliated Hospital of Soochow University

Research Article

Keywords: anterolateral approach, posterolateral approach, supination-external rotation (SER), ankle fracture, clinical efficacy

Posted Date: May 11th, 2022

DOI: https://doi.org/10.21203/rs.3.rs-1619344/v1

License: This work is licensed under a Creative Commons Attribution 4.0 International License. Read Full License

Abstract

Background: The present study aimed to analyze and compare the efficacy of the anterolateral and posterolateral approaches for surgical treatment of supination-external rotation type IV ankle fractures.

Methods: This retrospective study enrolled 60 patients (60 feet) with supination-external rotation type IV ankle fractures, including 30 patients (30 feet) treated via the anterolateral approach and 30 patients (30 feet) treated via the posterolateral approach. Postoperative clinical efficacy was compared between the groups based on operation time, intraoperative blood loss, postoperative complications, fracture healing time, visual analog scale (VAS) scores, Short Form-36 Health Survey (SF-36) scores, and American Orthopedic Foot and Ankle Society (AOFAS) scores. Comparisons between the two groups were performed using independent-samples t-tests and analyses of variance. Intra-group differences were compared using paired t-tests, and the Chi-square test was used to compare categorical variables.

Results: All 60 included patients completed follow-up ranging from 12 to 18 months (mean duration: 14.8±3.5 months). Although baseline characteristics were similar in the two groups, there were significant differences in operation time (86.73±17.44 min vs. 111.23±10.05 min, P<0.001) and intraoperative blood loss (112.60±25.05 ml vs. 149.47±44.30 ml, P<0.001). Although fracture healing time (10.90±0.66 weeks vs. 11.27±0.94 weeks, P=0.087) was shorter in the anterolateral group than in the posterolateral group, the difference was not significant. Postoperative complications occurred in one and three patients in the anterolateral and posterolateral approach groups, respectively. VAS scores were significantly lower in the anterolateral group than in the posterolateral group (1.43±0.50 vs. 1.83±0.75, P=0.019), although there was no significant difference in SF-36 scores between the groups (73.63±4.07 vs. 72.70±4.04, P=0.377). However, AOFAS scores were higher in the anterolateral group than in the posterolateral group (80.43±4.32 vs. 75.43±11.32, P=0.030).

Conclusion: Both the anterolateral and posterior lateral approaches can achieve good results in the treatment of supination-external rotation type IV ankle fractures. Compared with the posterolateral approach, the anterolateral approach is advantageous for the treatment of supination-external rotation type IV ankle fractures given its safety and ability to reduce trauma, provide clear exposure, and allow for exploration and repair of the inferior tibiofibular anterior syndesmosis within the same incision.

Introduction

Ankle fracture is a common type of lower limb fracture encountered in the clinic, most often occurring due to indirect trauma following an ankle sprain. Clinically, ankle fractures are divided into four types according to the position of the foot at the time of injury and the direction of trauma: supination-adduction, supination-external rotation, pronation-abduction, and pronation-external rotation. Among these, the supination-external rotation type is most common, accounting for approximately 50% of all cases [1, 2]. Supination-external rotation type IV ankle fractures involve multiple injuries to the medial, lateral, and/or posterior aspects. In such fractures, the ankle joint of the affected limb exhibits

mechanical instability, and ankle dislocation may occur without prompt and effective treatment. Such dislocation can lead to severe dysfunction and affect an individual's ability to perform normal activities [3]. As such, supination-external rotation type IV ankle fractures are the considered the most severe, treatment mainly involves surgery [4].

The main surgical approach for ankle fractures is the posterolateral approach. A posterolateral approach combined with a medial incision has traditionally been the most common strategy for trimalleolar fractures, as it can well expose the posterior malleolar fracture and provide a clear surgical field. Complete exposure of the posterior malleolar fracture also allows for reduction and fixation under direct vision, and the posterolateral approach enables simultaneous reduction and fixation of the posterior and lateral malleolar fractures through the same incision [5, 6]. However, the posterolateral approach also has certain disadvantages in cases of supination-external rotation type IV ankle fractures, including a greater risk of injury to the sural nerve and branches of the peroneal artery. Furthermore, the anterior inferior tibiofibular ligament (AITLF) and anterior talofibular ligament (ATFL) cannot be probed and repaired within the same incision, and the lower tibiofibular joint cannot be explored, reduced, or fixed under direct vision. The posterolateral approach also involves more muscle denudation and trauma than the anterolateral approach. In addition, The posterolateral approach causes adhesion contracture of great flexor long muscle and mallet toe deformity easily.

In the present study, we aimed to compare the clinical efficacy and value of the anterolateral and posterolateral approaches for the surgical treatment of supination-external rotation type IV ankle fractures.

Methods

Ethical statement

The authors are accountable for all aspects of the work in ensuring that questions related to the accuracy or integrity of any part of the work are appropriately investigated and resolved. The trial was conducted in accordance with the Declaration of Helsinki (as revised in 2013). The study was reviewed approved by the ethics committee of the Second Affiliated Hospital of Soochow University, and informed consent was taken from all individual participants.

Baseline clinical data

Sixty patients with supination-external rotation type IV ankle fractures treated in our hospital from February 2018 to August 2020 were enrolled. According to the different surgical approaches, they were divided into anterolateral approach group and posterolateral approach group. The baseline clinical characteristics of the two groups are shown in Table 1.

Inclusion and exclusion criteria

Inclusion criteria were as follows:

1. Unilateral fresh closed fracture
2. Supination-external rotation type IV ankle fracture
3. All procedures performed by the same surgeon (Bo Jiang)
4. Complete follow-up data
5. Approval by the medical ethics committee of our hospital
6. Patient's understanding of the purpose and significance of the study and voluntary participation

Exclusion criteria were as follows:

1. Soft tissue/skin damage or open fracture
2. Inability to tolerate surgery
3. Other fresh fractures or neuromuscular injuries on the affected side of foot
4. Metabolic or pathological fractures

Surgical technique in the anterolateral approach group

Continuous epidural or general anesthesia was administered. Patients were placed in the supine position, and routine disinfection of the surgical area was performed. In air bag tourniquet was used for all procedures. A longitudinal incision was made at the anterior edge of the distal fibula, with the distal end of the incision pointing to the base of the fourth metatarsal (Fig. 1). The length of the incision was determined based on the fracture site and degree of comminution. The fractured end of the lateral malleolus was exposed layer by layer and cleaned thoroughly, following which it was reduced and fixed with plates and screws. The posterior malleolus fracture was then reduced and fixed, and the posterior malleolus fragment was pressed in a posterior-to-anterior direction using a periosteal stripper through the posterior edge of the lateral malleolus (between the lateral malleolus and the long and short tendons of the fibula) in the same incision. Posterior malleolar fracture was fixed with Kirschner wires in an anterior-to-posterior direction. After satisfactory C-arm fluoroscopy, a cannulated screw was used to fix the posterior malleolus fracture. The fractured end of the medial malleolus was exposed via a curved incision of the medial malleolus and fixed with a hollow lag screw following reduction. After fracture reduction and fixation, the anterior inferior tibiofibular ligament (AITLF) and anterior talofibular ligament (ATFL) were repaired via routine exploration using the anterolateral approach.

Surgical technique in the posterolateral approach group

Continuous epidural or general anesthesia was administered. Patients were placed in a prone or contralateral position, and routine disinfection and preparation of the surgical area was performed. Balloon tourniquets were used for all procedures. A longitudinal incision was made between the long and short tendons of the fibula and the Achilles tendon to protect the sural nerve. The muscle of the peroneus longus brevis was pulled posteriorly and medially, and the lateral skin flap was pulled anteriorly and laterally to expose the fractured end of the lateral malleolus, which was then fixed with plates and screws. The flexor pollicis longus muscle was gently pulled inwards to expose the fractured of the posterior

malleolus, which was then reduced with the help of ligaments and temporarily fixed with Kirschner wire. After satisfactory C-arm fluoroscopy, the fractured end was fixed with steel plates or screws. A supine position was then adopted in favor of the prone position, and the lower extremities in the contralateral position were rotated externally. A curved incision was used to expose the fractured end of the medial malleolus while taking care to protect the great saphenous vein when exposed, following which the fractured end was fixed with a hollow lag screw after reduction.

Assessment indices

Operation time, intraoperative blood loss, fracture healing time, number of complications, preoperative and postoperative VAS scores, postoperative SF-36 scores, and American Orthopedic Foot and Ankle Society (AOFAS) scores for at least 1 year of follow-up were compared between the two groups. The AOFAS score includes 40 points for pain, 50 points for function, and 10 points for alignment, with a maximum score of 100. Total scores of 90–100, 75–89, 50–75, and <50 indicate excellent, good, fair, and poor outcomes, respectively.

Table 1. Baseline clinical data of the two groups

	Anterolateral approach	Posterolateral approach	t/X^2	*P*
Age (year)	**52.0±13.8**	**54.2±11.7**	**0.7**	**0.7**
Sex			**0.35**	0.72
Male	17	19		
Female	13	11		
Side			0.33	0.74
Right	17	14		
Left	13	16		
Etiology			0.039	0.998
Car accident-related injury	17	16		
Sprain	8	7		
Fall-related injury	3	4		
Others	2	3		

Statistical analysis

Statistical analyses were performed using SPSS Statistics software (version 23.0; SPSS Inc., Chicago, IL, USA). Quantitative variables are expressed as the mean ± standard deviation (SD) and were compared using t-tests. Qualitative variables are expressed as numbers (N) and percentages (%) and were compared using the chi-square test P values <0.05 were considered statistically significant.

Table 2. Comparison of clinical outcomes between two groups

Outcomes	Anterolateral approach	Posterolateral approach	*P*
Operation time (min)	86.73±17.44	111.23±10.05	<0.001
Intraoperative blood loss (ml)	112.60±25.05	149.47±44.30	<0.001
Fracture healing time (weeks)	10.90±0.66	11.27±0.94	0.087
VAS score			
Preoperative	6.33±0.61	6.27±0.64	0.680
Postoperative	1.43±0.51	1.83±0.75	0.020
SF-36 score	73.63±4.07	72.70±4.04	0.458
AOFAS score	80.43±4.32	75.43±11.32	0.030

VAS: visual analog scale; SF-36: Short Form-36 Health Survey; AOFAS: American Orthopedic Foot and Ankle Society

Results

Comparison of general condition after surgery

The anterolateral approach resulted in significantly reduced operation time, intraoperative blood loss, and complication number when compared with the posterolateral approach (P<0.05). In the anterolateral group, the operation time was 86.73±17.44 min, the intraoperative blood loss was 112.60±25.05 ml, and one patient experienced incision-related complications (skin edge necrosis). The corresponding values in the posterolateral group were 111.23±10.05 min, 149.47±44.30 ml, and three cases involving complications (skin edge necrosis: 2; nerve injury=1), respectively. Fracture healing time was also shorter in the anterolateral group (10.90±0.66 weeks) than in the posterolateral group (11.27±0.94 weeks), although this difference was not significant (P=0.087) (Tables 2 and 3).

Table 3. Comparison of postoperative complications between the groups

Complications	Anterolateral approach		Posterolateral approach	
	N	%	N	%
Skin edge necrosis	1	3.33	2	6.67
Nerve injury	0	0	1	3.33

Comparison of inferior tibiofibular syndesmosis instability

There were three cases of inferior tibiofibular syndesmosis instability in the anterolateral group and two cases in the posterolateral group.

Comparison of VAS scores before and after surgery

Preoperative VAS scores were 6.33±0.61 in the anterolateral group and 6.27±0.64 in the posterolateral group, respectively (P=0.680). The postoperative VAS scores were 1.43±0.51 in the anterolateral group and 1.83±0.75 in the posterolateral group, respectively (P=0.019).

Table 4. AOFAS scores for the ankle joint and rate of excellent outcomes in each group

	Scoring criteria (cases)				Percentage of cases with good and excellent outcomes among all cases (%)	AOFAS score (points)
	Excellent	Good	Fair	Poor		
Anterolateral approach	11	13	4	2	80.00	80.43±4.32
Posterolateral approach	11	12	5	2	76.67	75.43±11.32
P					0.754	0.030

Comparison of SF-36 scores

Postoperative SF-36 scores were 73.63±4.07 in the anterolateral group and 72.70±4.04 in the posterolateral group (P=0.377), and there were no significant differences between the two groups.

Comparison of clinical efficacy

Both groups were followed up for 12 to 18 (14.8±3.5) months. The mean postoperative AOFAS score was 80.43±4.32 in the anterolateral group, which was significantly better than that in the posterolateral group (75.43±11.32; P=0.030) (Table 4). A typical case is shown in Figure 1.

Discussion

In this study, we assessed the clinical efficacy of the anterolateral and posterolateral approaches for the surgical treatment of supination-external rotation type IV ankle fractures. Our analysis indicated that the anterolateral approach resulted in significantly reduced operation time, intraoperative blood loss, and complication number when compared with the posterolateral approach. Postoperative VAS and AOFAS scores were also better in the anterolateral group than in the posterolateral group.

Birnie et al. studied 252 patients with ankle fractures, observing that 25.8% of patients had AITFL injuries [7]. The repair of AITFL is of great significance for the restoration of ankle stability. In our study, the experimental group underwent conventional exploration and repair of AITFL, while the control group underwent mini-incision exploration and repair of the AITFL when preoperative MRI indicated AITFL injury.

The anterolateral approach allows for reduction and fixation of possible anterior malleolus avulsion fractures (mainly Tillaux–Chaput fractures) in patients with supination-external rotation type IV ankle fractures. Some scholars have reported that the ATFL is the most frequently injured ligament after ankle injury [8]. Faqi et al. also noted that some patients with Weber B-type ankle fractures had ATFL injuries [9]. In this study, the ATFL was explored and repaired through the same incision via suturing or anchoring in four patients of the anterolateral approach group. Furthermore, for cases in which the Hook test reveals instability of the inferior tibiofibular syndesmosis following fixation of the medial and lateral malleolar fractures, the anterolateral approach allows for direct exploration and fixation of the inferior tibiofibular. In our study, there were three cases of inferior tibiofibular syndesmosis instability in the anterolateral group and two cases in the posterolateral group, all of which were fixed with tibiofibular screws. Meanwhile, when preoperative ankle CT confirms that there are bone fragments or osteophytes in the anterior ankle joint space, the anterolateral approach enables more convenient clean-up of these debris. Based on these advantages, we argue that the anterolateral approach is a better choice for supination-external rotation type IV ankle fractures in patients who also exhibit injury to the ATFL and inferior tibiofibular joint.

In the current study, the anterolateral approach for supination-external rotation type IV ankle fractures began at the anterior edge of the fibula, and the distal end of the incision pointed to the base of the fourth metatarsal. Esposito et al. observed that the posterolateral approach is associated with a higher risk of injury to the sural and peroneal arteries than the anterolateral approach in the treatment of tibial pilon fractures [10]. However, Jowett et al. reported that the sural nerve is more susceptible to injury when treating ankle fractures using the posterolateral approach [11]. Our findings suggest that use of the anterolateral approach for the treatment of supination-external rotation type IV ankle fractures is less likely to damage the anterior tibial blood vessels and the sensory branch of the deep peroneal nerve. Clear exposure of the superficial peroneal nerve also protects the nerve from damage. While complications occurred in one and three patients in the anterolateral (skin edge necrosis) and posterolateral groups (2 cases of skin edge necrosis and 1 case of sural nerve injury) of our study, respectively, all three patients with skin edge necrosis achieved good healing after timely dressing changes, proper removal of necrotic tissue, and use of a warming lamp. In the case of sural nerve injury in the posterolateral group, the patient

received neurotrophic treatment and local physical therapy, and complete recovery was observed at the 3-month postoperative follow-up.

Supination-external rotation type IV ankle fractures are often accompanied by posterior malleolar fractures, and Lee et al. found that posterior malleolar fractures associated with trimalleolar fractures are an important risk factor for postoperative ankle instability [12]. According to current guidelines for AO treatment of posterior malleolus fragments, if the posterior malleolus fragment is greater than 25% of the medial surface of the involved joint and there is no long proximal extension, lag screw fixation should be performed [13]. Erdem et al. reported no difference in functional outcomes after fixation of the posterior malleolar fragment with screws or plates [14]. In the current study, the operator exposed part of the anterior malleolus via the anterolateral approach, used a periosteal stripper to press the posterior malleolus fragment in the posterior-to-anterior direction through the back of the lateral malleolus, and fixed the posterior malleolar fracture with Kirschner wire from the anterior to posterior malleolus. After satisfactory C-arm fluoroscopy, the posterior malleolus fragment was easily fixed with lag screws. Our findings indicated that intraoperative blood loss was significantly lower in the anterolateral group (112.60±25.05 ml) than in the posterolateral group (149.47±44.30 ml). This may be the result of the limited soft tissue dissection required when reducing the posterior malleolus fragment through the anterolateral approach, which decreases damage to the posterior soft tissue and the associated intraoperative blood loss [15].

Although preoperative VAS scores were similar in the two groups, postoperative scores were significantly lower in the anterolateral group (1.43±0.51) than in the posterolateral group (1.83±0.75) (P=0.019). This may be because the posterolateral approach requires more extensive stripping of soft tissues such as muscles and tendons when applied for the treatment of supination-external rotation type IV ankle fractures, resulting in greater soft tissue damage. Furthermore, use of the posterolateral approach for the treatment of supination-external rotation type IV ankle fractures requires a change in position during the operation, which is not necessary when using the anterolateral approach. The supine position is used throughout the procedure when utilizing the anterolateral approach, which reduces operation time and is advantageous in terms of anesthesia management and intraoperative fluoroscopy. The position is also relatively comfortable for patients and more convenient for operators.

Our study had some limitations of note. First, the incision scar was located on the anterolateral ankle in patients who had undergone surgery using the anterolateral approach, which has a certain impact on aesthetics. Further, in contrast to the posterolateral approach, the anterolateral approach does not allow for reduction and fixation of the posterior ankle under direct vision. Other limitations include the small sample size, which highlights the need for high-quality multicenter randomized controlled trials to accurately compare the clinical effects of the two surgical approaches. The anterolateral approach is also only suitable for supination-external rotation type III and IV ankle fractures; however, data regarding its use remains limited, and further studies are required to compare the medium- and long-term clinical effects of the anterolateral approach between type III and type IV fractures.

Conclusion

The current findings demonstrate that both the anterolateral and posterolateral approaches can achieve good results in the treatment of supination-external rotation type IV ankle fractures. However, compared with the posterolateral approach, the anterolateral approach reduces soft tissue dissection and allows for effective exposure, reduction, fixation, repair, and reconstruction of important ankle structures in such patients. Further large-scale studies are required to fully elucidate the clinical effects of the two surgical approaches.

Abbreviations

VAS
visual analog scale
SF-36
Short Form-36 Health Survey
AOFAS
American Orthopedic Foot and Ankle Society
SER
supination-external rotation
AITFL
anterior inferior tibiofibular ligament
ATFL
anterior talofibular ligament.

Declarations

Acknowledgments

We acknowledge all the patients participating in this study and appreciate the support from The Second Affiliated Hospital of Soochow University and State Key Laboratory of Radiation Medicine and Protection of Soochow University on this study.

Author contributions

JS designed the study; YZ, NY, ZZ and LC followed up the patients and collected the relevant data; BJ and JS analyzed and interpreted the data; JS and JZ wrote the manuscript and all the authors read and approved the final manuscript.

Funding

This research received financial support from the Program of Suzhou Clinical Key Disease

Diagnosis and Treatment Technology Foundation (Grant No. LCZX201708), Technology and Planning Program of Suzhou (Grant No. SYS2019063),Technology and Planning Program of Suzhou (Grant No. SYS2020127),Project of State Key Laboratory of Radiation Medicine and Protection,Soochow University (No. GZK1202133) and Medical Application project of Nuclear Technology in subject Construction Lifting Project of the Second Affiliated Hospital of Soochow University (Grant No. XKTJ-HRC2021008).

Availability of data and materials

All the data will be available upon motivated request to the corresponding author of the present paper.

Ethics approval and consent to participate

The study was approved by the ethics committee of the Second Affiliated Hospital of Soochow University, and informed consent was taken from all individual participants.

Consent for publication

Written informed consent was obtained from each patient to authorize the publication of their data.

Competing interests

The authors declare that they have no competing interests.

References

1. Liu Z, Tang G, Guo S, et al. Therapeutic effects of internal fixation with support plates and cannulated screws via the posterolateral approach on supination external rotation stage IV ankle fracture. Pakistan J Med Sci 2020;36:438–44.
2. Li B, Wang S, Zhang Z, et al. Transarticular external fixation versus deltoid ligament repair in treating SER IV ankle fractures: a comparative study. BMC Musculoskel Dis 2019;20:1–7.
3. Paez CJ, Lurie BM, Upasani VV, et al. Functional outcomes of unstable ankle fractures with and without syndesmotic fixation in the adolescent population. J Child Orthop 2021;15:418–25.
4. Wang X, Zhang C, Yin JW, et al. Treatment of medial malleolus or pure deltoid ligament injury in patients with supination-external rotation type IV ankle fractures. Orthop Surg 2017;9:42–8.
5. Pagliaro AJ, Michelson JD, Mizel MS. Results of operative fixation of unstable ankle fractures in geriatric patients. Foot Ankle Int 2001;22:399–402.
6. Kołodziej Ł, Boczar T, Bohatyrewicz A, et al. [Outcome of operative treatment for supination-external rotation Lauge-Hansen stage IV ankle fractures]. Chirurgia Narzadow Ruchu I Ortopedia Polska 2010;75:231–5.
7. Birnie MF, van Schilt KL, Sanders FR, et al. Anterior inferior tibiofibular ligament avulsion fractures in operatively treated ankle fractures: a retrospective analysis. Arch Orthop Trauma Surg 2019;139:787–93.

8. Shimozono Y, Hoberman A, Kennedy JG, et al. Arthroscopic anterior talofibular ligament repair with use of a 2-portal technique. JBJS Essent Surg Tech 2019;9(4).
9. Faqi MK, AlJawder A, Alkhalifa F, et al. Weber B fracture of the lateral malleolus with concomitant anterior talofibular ligament injury following an ankle supination injury. Case Rep Orthop 2016;2016:8035029.
10. Esposito JG, van der Vliet QM, Heng M, et al. Does surgical approach influence the risk of postoperative infection after surgical treatment of tibial pilon fractures? J Orthop Trauma 2020;34:126–30.
11. Jowett AJ, Sheikh FT, Carare RO, et al. Location of the sural nerve during posterolateral approach to the ankle. Foot Ankle Int 2010;31:880–3.
12. Lee SH, Cho H, Yang J. Predisposing factors for chronic syndesmotic instability following syndesmotic fixation in ankle fracture: Minimum 5-year follow-up outcomes. Foot Ankle Surg 2021;27:777–83.
13. Verhage SM, Krijnen P, Schipper IB, et al. Persistent postoperative step-off of the posterior malleolus leads to higher incidence of post-traumatic osteoarthritis in trimalleolar fractures. Arch Orthop Trauma Surg 2019; 139: 323–9.
14. Erdem MN, Erken HY, Burc H, et al. Comparison of lag screw versus buttress plate fixation of posterior malleolar fractures. Foot Ankle Int 2014;35:1022–30.
15. Sandelin H, Tukiainen E, Ovaska M. Amputation following internal fixation of an ankle fracture via the posterolateral approach–a case report. Acta Orthopaedica 2017;88:358–60.

Figures

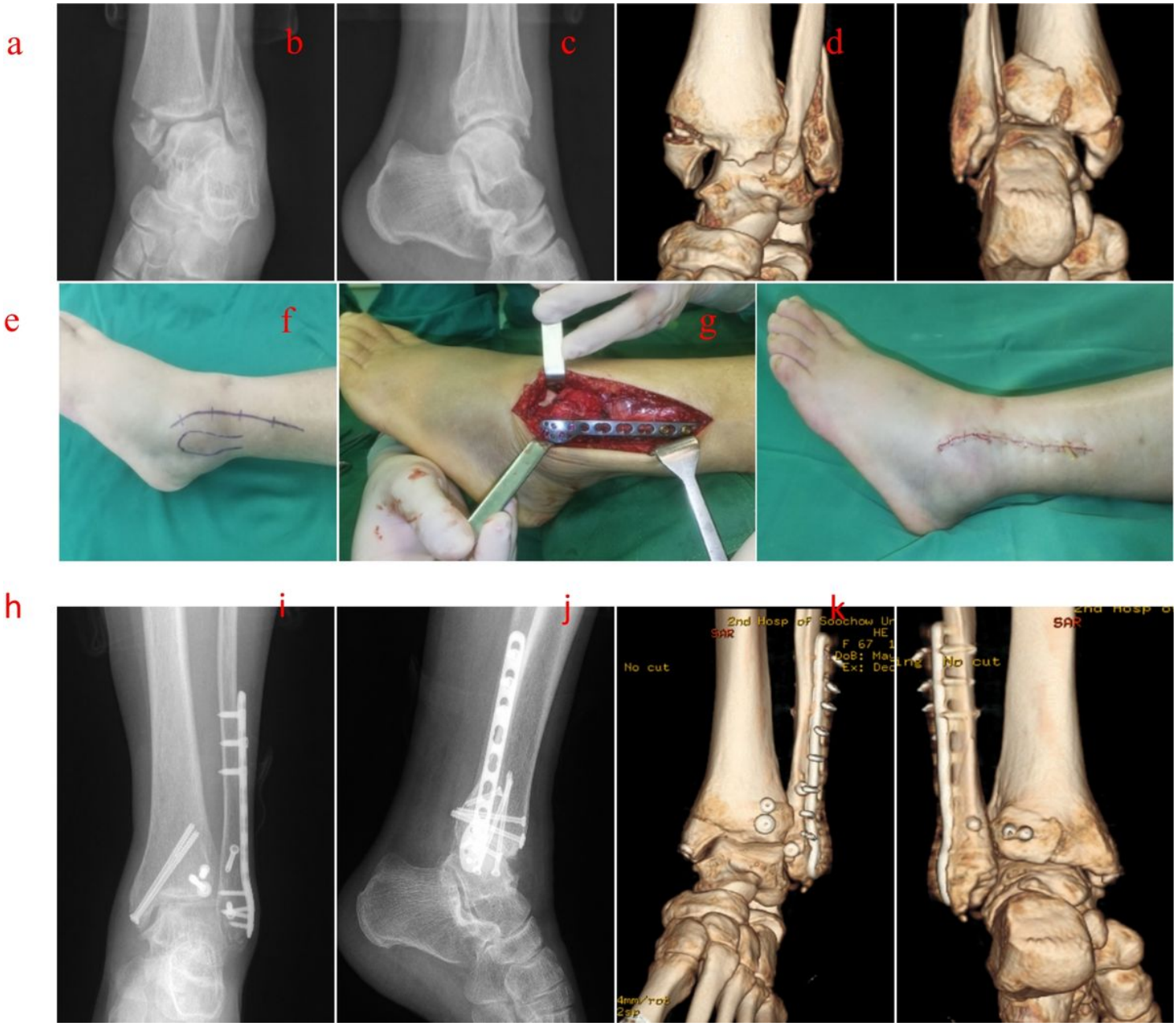

Figure 1

Images for a 67-year-old woman with a left supination-external rotation type IV ankle fracture. **(A-D)** Preoperative X-rays and three-dimensional computed tomography images. **(E)** Anterolateral approach. **(F, G)** Intraoperative exposure of the anterior lateral incision and suture of the incision. **(H-K)** Postoperative X-rays and three-dimensional computed tomography images.