Effectiveness of Leksell gamma knife hypophysectomy on cancer-related intractable pain – a single-center experience

Jaromir May (jaromir.may@homolka.cz)
Na Homolce Hospital

Roman Liščák
Na Homolce Hospital

Research Article

Keywords: radiosurgery, gamma knife, hypophysectomy, pain

Posted Date: May 10th, 2022

DOI: https://doi.org/10.21203/rs.3.rs-1626044/v1

Abstract

Purpose: Hypophysectomy is a method used in analgesia in patients with painful bone metastases. The pain relief after this procedure is not pathophysiologically fully understood. In only a few studies Leksell gamma knife (LGK) was used for radiosurgical hypophysectomy. In our study, we performed the LGK hypophysectomy in patients with intractable cancer-related pain due to bone metastases and evaluated the impact of this method on pain relief.

Methods: From 1994 to 2020 we enrolled 20 patients with the diagnosis of disseminated carcinoma. All patients underwent radiosurgical hypophysectomy on LGK. The prescription dose was 75-100Gy on the 50% isodose line, and the maximal dose on the optic pathways was 9,8Gy on average.

Results: In all 10 evaluated patients pain relief was achieved (0-50% of pre-procedural pain). The hypophysectomy effect lasted for the rest of their lives (the mean follow-up period was 12,6 months). In three patients we observed hormonal disbalance - hypocortisolism and diabetes insipidus with good response to substitutional therapy, one patient developed a temporary abducens nerve palsy. No other adverse events were observed.

Conclusion: Our results suggest that the LGK hypophysectomy is an effective and safe procedure to reduce cancer-related intractable pain, especially in bone metastases of hormonally dependent tumors.

Introduction

The prevalence of cancer noticeable increases nowadays despite sophisticated oncological prevention, screening, and treatment options.[1] Two-thirds of patients with advanced cancer are prone to bone metastases.[2] Intractable cancer-related pain due to bone metastases significantly impacts the quality of life and its treatment remains challenging.[3] More than 70% of patients in an advanced stage of cancer are treated with opioids and despite it, 30% of them suffer from medical refractory pain.[1] Opioid therapy is also related to moderate and serious side effects such as nausea, sedation, constipation, physical dependence, tolerance, and respiratory depression.[4] Surgical treatment of bone metastases is expanding but still has limitations in indications and the improvement of quality of life in these patients.[5]

Hypophysectomy in the treatment of intractable cancer-related pain was introduced in 1953 by Luft and Olivercona who performed this surgical procedure via an endonasal transsphenoidal approach with excellent pain relief but with high morbidity and mortality.[6] In 1978 LaRossa et al. presented 15 patients with breast cancer with bone metastases after endonasal transsphenoidal hypophysectomy.[7] All of these patients had pain level decrease 24 hours after the surgical intervention. It was also proved that only transection of the pituitary stalk leads to pain relief and decreases the risk of hormonal disbalance.[8] Tindall published excellent results of hypophysectomy in patients with carcinoma of the pancreas, ureter, testes, and the adrenal gland. [9] Levin reported a 93% reduction of cancer-related pain after chemical hypophysectomy. [10] Moricca supported this result with 98,1% success of chemical

hypophysectomy. [11] Similar results were achieved by cryohypophysectomy or the application of Yttrium90. [12–15] Dvorak and Rozsival performed hypophysectomy using thermocoagulation with excellent results. [15, 16] All these methods were accompanied by a relatively high complication rate. Between 1954 and 1972 Levy et. al presented a radiosurgical hypophysectomy in 183 patients with breast cancer. In 1972 Backlund et al. described the first radiosurgical hypophysectomy using a Leksell gamma knife (LGK) and confirmed this method as efficacious and safer than previous invasive methods. [17, 18] From this time there are only a few studies of radiosurgical hypophysectomy and this method became neglected in oncological palliative medicine. [18–20] Nowadays there is a renaissance of this method due to the increase of patients with malignant diagnoses and prolonged survival of patients with cancer.

In this single-center study, we performed the radiosurgical LGK hypophysectomy in patients with intractable cancer-related pain due to bone metastases and evaluated the impact of this method on pain relief.

Methods

Between 1994 and 2020 we enrolled 20 patients (12 females, 8 males), mean age was 59,4years (46–73) who suffered from cancer-related pain and fulfilled two inclusion criteria: 1) pain related to bone metastases; 2) insufficient effect of previous analgetic treatment. The primary tumor histology included breast cancer (40%; 8), prostate cancer (20%; 4), lung cancer (15%; 3), rectal cancer (5%; 1), laryngeal cancer (5%; 1) and kidney cancer (5%; 1).

On the day of the treatment, we applied a Leksell stereotactic G-frame on the head of the patient parallelly to the optic pathway in local anesthesia. All patients underwent MRI scans (1,5 Tesla, T1 weighted images in axial and coronal planes with 1.0mm slice thickness and T2 weighted images in the coronal plane with 2.0mm slice thickness). Using LGK Perfexion, we created a treatment plan using Leksell Gamma Plan software (Elekta instrument). 50% isodose involved the whole pituitary gland. The 8mm collimator was used. We modified collimators in segments 2 and 8 to 4mm in diameter to maximal reduce the dose on the optic tract. (Fig. 1) The prescription dose was on average 88Gy (75-100Gy) on 50% isodose, the maximal dose was on average 176Gy (150-200Gy). The maximal dose on the optic pathway was 9,8Gy (7-15Gy). (Fig. 2) The patients were discharged the same day with a scheduled follow-up 2 months after the treatment.

The pain was evaluated before the treatment and after the treatment on regular follow-ups (the first was two months after the procedure). We used the Visual Analogue Scale (VAS) and the percentage of remaining pain (%) for pain level measurement.

Results

From 20 patients we included 10 patients in our retrospective analysis (7 females and 3 males). Six patients died in consequence of the cancer progression before the first follow-up so the effect could not be evaluated. We did not receive any information from four patients after the treatment. Six of the ten patients suffered from breast cancer, two from prostate cancer, and two from lung cancer. In all 10 patients, we achieved a pain reduction, which resulted in an average of 24% (0–50%) of remaining pain. (Fig. 3 and Table 1)

The mean follow-up was 12,6 months (2-34months). The pain level decrease was achieved from 2 to 4 weeks after the procedure and was permanent, no pain recurrence from bone metastases was observed.

In two patients the hypocortisolism was present with the need for substitutional therapy 5 and 12 months after radiosurgical hypophysectomy. In one patient the diabetes insipidus occurred 3 months after the treatment with the success of substantial therapy. One patient developed temporary abducens nerve palsy with full recovery after 5 months. No other adverse events were observed.

Discussion

This study evaluates the effect of radiosurgical LGK hypophysectomy on pain relief in patients with intractable cancer-related pain with multiple bone metastases. Our study confirms, that LGK hypophysectomy is an effective and safe treatment modality in this group of patients where the effect of analgesic treatment was insufficient.

The analgesic mechanism of radiosurgical hypophysectomy remains poorly understood. [21] Because of its effect on hormonally dependent bone metastases, the disruption of hormonal pathways was the first theory.[22, 23] This theory does not explain the immediate pain relief (hours) in many patients. Moreover, pain relief persists despite tumor growth and normal function of the pituitary gland, and patients with non-hormonal tumors also experienced pain relief. [10, 22, 24] Another theory considers an increased activity of pre-pro-opiomelanocortin (precursor to β-endorphin) as the reason for pain relief after hypophysectomy which was supported by a higher level of β-endorphin in cerebrospinal fluid and blood. Nevertheless, this elevation takes only 72 hours, and administration of naloxone after LGK hypophysectomy did not influence the analgesic effect of the procedure.[23] Recent theory suggests that the hypothalamus and its afferent nociceptive pathways have a key role in pain relief.[25] To better understand the pathophysiological changes after hypophysectomy more studies still have to be done.

Pain relief was achieved in all our analyzed patients (10 from 20) and persisted the whole life. We are by previous studies by Backlund et al., Hayashi et al., and Kwon et al. who evaluated the effect of LGK hypophysectomy in similar series of patients (8; 9 and 7 patients).[17, 26, 27] Moreover, in previous studies radiosurgical hypophysectomy was effective even in the treatment of non-hormonal cancer pain without bone metastases and non-malignant thalamic pain.[21, 24] The effect occurs from several hours to four weeks after the treatment which is much earlier than in other indications for LGK radiosurgery.[17, 26, 28, 29] Permanent duration of pain relief is the advantage over the other analgetic radiosurgical methods (e.g., cingulotomy and thalamotomy).[30]

The maximal dose on the pituitary gland has been applied from 150 to 250Gy.[17, 26–28] In our study the maximal dose was on average 176Gy which is close to the lower limit of the range. This result confirms that the maximal dose of 150Gy is sufficient for pain relief and there is no need to elevate the maximal dose over this limit. The dose to the optic tract was 9,8Gy on average and no visual complication was reported. Other critical structures obtained much less dose than their tolerance.

Despite the relatively high administrated dose, we recorded only a few side effects of irradiation. Hormonal disbalance occurred in three patients. One patient developed the diabetes insipidus 3 months after the treatment with the success of substantial therapy. In two patients hypocortisolism was present with the need for substitutional therapy 5 and 12 months after hypophysectomy. One patient developed temporary abducens nerve palsy with full recovery after 5 months. The higher incidence of hormonal disbalance in the study of Backlund et all might be caused by a higher maximal dose which was 200-250Gy.[17] In a study of Hayashi, no side effects occurred and in the study of Kwon, only one patient with pre-existing panhypopituitarism get worse.[26, 27] In these two studies the maximal dose was up to 200Gy. No other side effect was present.

In our study, the mean follow-up was 12,6 months and the longest follow-up was 26 months. In previous studies, the maximal follow-up was 12 months.[12] Four of the ten patients in our study have lived more than 12 months after the hypophysectomy with permanent pain levels decreased from 50–100%. Two patients suffered from breast cancer and two from prostate cancer. This highlights that LGK hypophysectomy is well established in hormonally dependent bone metastases. Unfortunately, patients with lung, kidney, rectal and laryngeal cancer died due to primary disease before the first follow-up, or we did not receive any information from them after the treatment. That is the reason why we could not evaluate the effectiveness of this procedure for non-hormonally dependent tumors.

In conclusion, our study confirms radiosurgical hypophysectomy as an effective and safe palliative method for pain relief in patients with multiple bone metastases of hormone-dependent cancers who suffer from intractable medically refractory pain.

Declarations

Author Contributions:

JM created the study design, he did the data analysis, and he is the main author of this manuscript. RL indicated patients, created and approved treatment plans, and revised the manuscript. Both authors participated in follow-ups.

Funding:

Supported by MH CZ – DRO (NHH, 00023884)

Data Availability:

The datasets generated during and analyzed during the current study are available from the corresponding author on reasonable request

Conflict of interest:

The authors have no relevant financial or non-financial interests to disclose.

Consent to participate:

Informed consent was obtained from all individual participants included in the study.

Ethical approval:

We declare that our study complies with the guidelines for human studies and was conducted ethically by the World Medical Association Declaration of Helsinki. The patient signed informed consent, and the study protocol was approved by the local committee on human researc

References

1. WORLD HEALTH ORGANIZATION: REGIONAL OFFICE FOR EUROPE. WORLD CANCER REPORT: cancer research for cancer development. Place of publication not identified: IARC; 2020.
2. Reale C, Turkiewicz AM, Reale CA. Antalgic treatment of pain associated with bone metastases. Crit Rev Oncol Hematol. 2001 Jan;37(1):1–11.
3. Rodriguez C, Ji M, Wang H-L, Padhya T, McMillan SC. Cancer Pain and Quality of Life. J Hosp Palliat Nurs. 2019 Apr;21(2):116–23.
4. Benyamin R, Trescot AM, Datta S, Buenaventura R, Adlaka R, Sehgal N, et al. Opioid complications and side effects. Pain Physician. 2008 Mar;11(2 Suppl):S105-120.
5. Manabe J, Kawaguchi N, Matsumoto S, Tanizawa T. Surgical treatment of bone metastasis: indications and outcomes. Int J Clin Oncol. 2004 Feb;10(2):103–11.
6. Luft R, Olivecrona H. Experiences With Hypophysectomy in Man. J Neurosurg. 1953 May;10(3):301–16.
7. LaRossa JT, Strong MS, Melby JC. Endocrinologically incomplete transethmoidal trans-sphenoidal hypophysectomy with relief of bone pain in breast cancer. N Engl J Med. 1978 Jun;298(24):1332–5.
8. Ehni G, Eckles NE. Interruption of the Pituitary Stalk in the Patient with Mammary Cancer. J Neurosurg. 1959 Nov;16(6):628–52.
9. Tindall GT, Nixon DW, Christy JH, Neill JD. Pain relief in metastatic cancer other than breast and prostate gland following transsphenoidal hypophysectomy. A preliminary report. J Neurosurg. 1977 Nov;47(5):659–62.

10. Levin AB, Katz J, Benson RC, Jones AG. Treatment of Pain of Diffuse Metastatic Cancer by Stereotactic Chemical Hypophysectomy: Long Term Results and Observations on Mechanism of Action. Neurosurgery. 1980 Mar;6(3):258–62.
11. Miyazaki H, Gotoh T, Okamoto K, Utsunomiya T, Morioka T, Yamamuro M. [Chemical hypophysectomy for intractable cancer pain by Moricca–1. Fundamental basis and method of the transnasal puncture of the hypophysis (author's transl)]. Masui. 1978 Dec;27(13):1606–12.
12. Conway LW, Collins WF. Results of trans-sphenoidal cryohypophysectomy for carcinoma of the breast. N Engl J Med. 1969 Jul;281(1):1–7.
13. Fergusson JD, Hendry WF. PITUITARY IRRADIATION IN ADVANCED CARCINOMA OF THE PROSTATE: ANALYSIS OF 100 CASES. Br J Urol. 1971 Oct;43(5):514–9.
14. Morales A, Blair DW, Steyn J. YTTRIUM ^{90} PITUITARY ABLATION IN ADVANCED CARCINOMA OF THE PROSTATE. Br J Urol. 1971 Oct;43(5):520–2.
15. Rozsíval V, Petr R, Kubícek J, Noziïka Z. Some aspects of hypophysectomy in cases of hormone-dependent mammary carcinoma. Sb Vedeckych Pr Lek Fak Karlovy Univ V Hradci Kralove. 1975;18(4–5):273–84.
16. Dvorák P, Dvorák M. Stereotaxic hypophysectomy for breast cancer. Acta Univ Palacki Olomuc Fac Med. 1987;117:177–80.
17. Backlund EO, Rähn T, Sarby B, De Schryver A, Wennerstrand J. Closed stereotaxic hypophysectomy by means of 60 Co gamma radiation. Acta Radiol Ther Phys Biol. 1972 Dec;11(6):545–55.
18. Levy RP, Fabrikant JI, Frankel KA, Phillips MH, Lyman JT, Lawrence JH, et al. Heavy-Charged-Particle Radiosurgery of the Pituitary Gland: Clinical Results of 840 Patients. Stereotact Funct Neurosurg. 1991;57(1–2):22–35.
19. Lipton S, Miles J, Williams N, Bark-Jones N. Pituitary injection of alcohol for widespread cancer pain. Pain. 1978 Jun;5(1):73–82.
20. Misfeldt D. Hypophysectomy Relieves Pain Not via Endorphins. N Engl J Med. 1977 Dec;297(22):1236–7.
21. Chernov MF, Hayashi M, Chen CC, McCutcheon IE, editors. Gamma knife neurosurgery in the management of intracranial disorders II. Cham: Springer; 2021. DOI: 10.1007/978-3-030-69217-9
22. Ramirez LF, Levin AB. Pain relief after hypophysectomy. Neurosurgery. 1984 Apr;14(4):499–504.
23. Yanagida H, Corssen G, Ceballos R, Strong E. Alcohol-Induced Pituitary Adenolysis: How Does It Control Intractable Cancer Pain????An Experimental Study Using Tooth Pulp-Evoked Potentials in Rhesus Monkeys. Anesth Analg. 1979 Jul;58(4):279???287.
24. Hayashi M, Taira T, Chernov M, Izawa M, Liscak R, Yu CP, et al. Role of pituitary radiosurgery for the management of intractable pain and potential future applications. Stereotact Funct Neurosurg. 2003;81(1–4):75–83.
25. Larkin MB, Karas PJ, McGinnis JP, McCutcheon IE, Viswanathan A. Stereotactic Radiosurgery Hypophysectomy for Palliative Treatment of Refractory Cancer Pain: A Historical Review and Update.

Front Oncol. 2020 Dec;10:572557.

26. Hayashi M, Taira T, Chernov M, Fukuoka S, Liscak R, Yu CP, et al. Gamma knife surgery for cancer pain-pituitary gland-stalk ablation: a multicenter prospective protocol since 2002. J Neurosurg. 2002 Dec;97(5 Suppl):433–7.
27. Kwon KH, Nam TK, Im YS, Lee JI. Pituitary Irradiation by Gamma Knife in Intractable Cancer Pain. J Korean Neurosurg Soc. 36(4):286–90.
28. Liscák R, Vladyka V. [Radiosurgical hypophysectomy in painful bone metastases of breast carcinoma]. Cas Lek Cesk. 1998 Mar;137(5):154–7.
29. Golanov AV, Kostjuchenko VV, Antipina NA, Isagulyan ED, Makashova ES, Abuzarova GR, et al. Radiosurgical hypophysectomy in cancer pain treatment. Literature review and clinical case. Vopr Neirokhirurgii Im NN Burdenko. 2020;84(5):102.
30. Roberts DG, Pouratian N. Stereotactic Radiosurgery for the Treatment of Chronic Intractable Pain: A Systematic Review. Oper Neurosurg. 2017 Oct;13(5):543–51.

Table

Table 1 is available in the Supplementary Files section

Figures

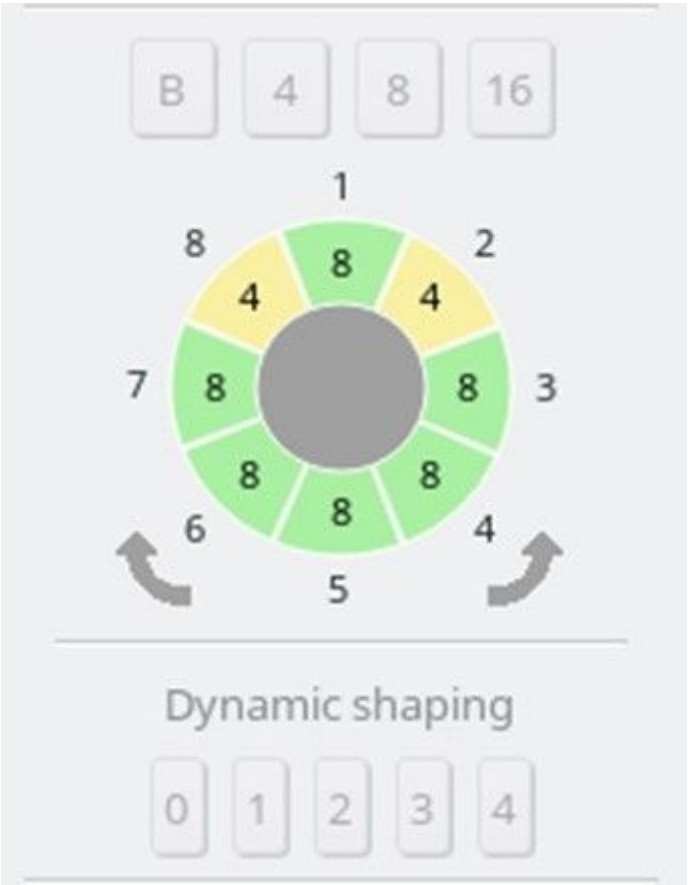

Figure 1

Collimators setting used for hypophysectomy to minimize a dose on the optic tract

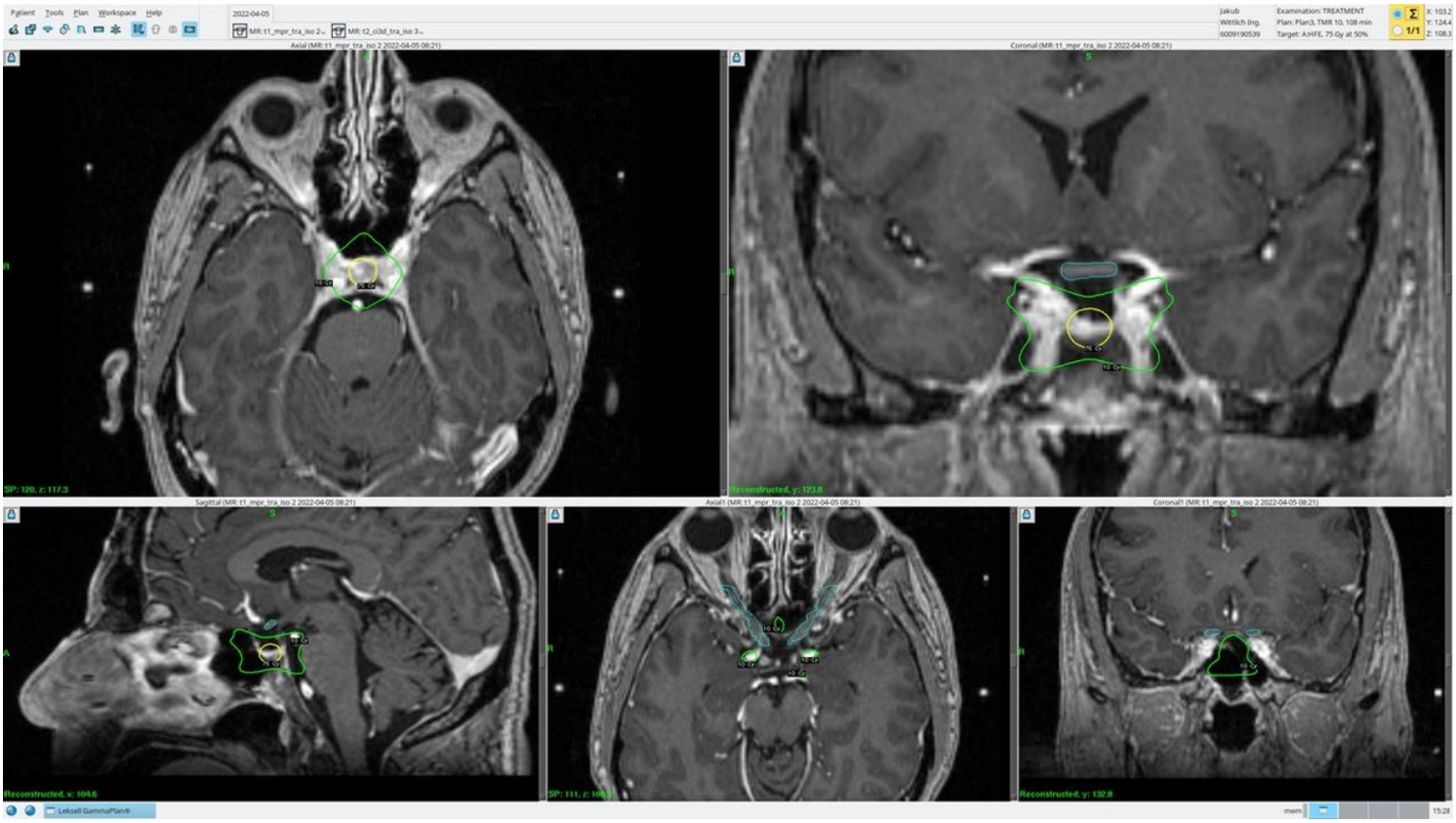

Figure 2

Example of treatment plan; green line - 10Gy isodose; blue line – optic tract contour; yellow line - 50% isodose (75Gy), the maximal dose to the optic tract is 6,7Gy

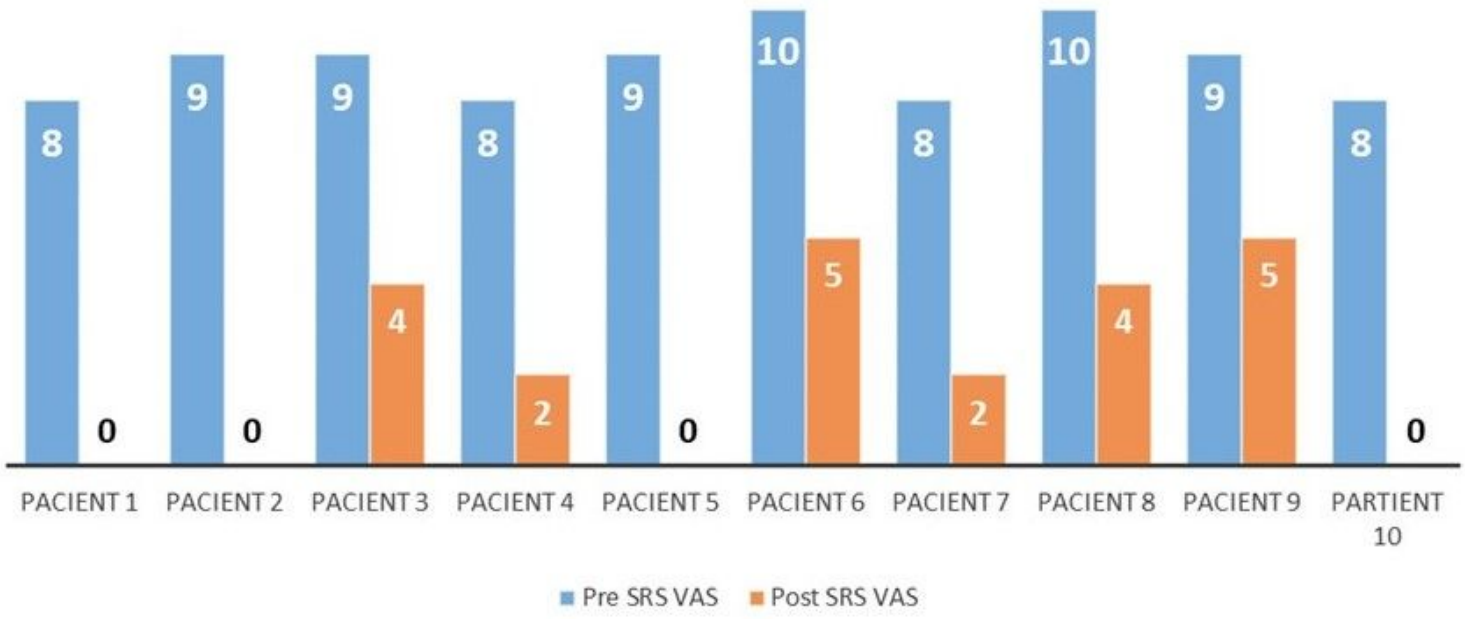

Figure 3

Graph of pain relief in followed-up patients. SRS – stereotactic radiosurgery; VAS – visual analog scale;

Supplementary Files

This is a list of supplementary files associated with this preprint. Click to download.

- Table1.jpg